

AperTO - Archivio Istituzionale Open Access dell'Università di Torino

Fetal adenocarcinoma of the lung in a 25-year-old woman

This is the author's manuscript

Original Citation:

Availability:

This version is available <http://hdl.handle.net/2318/27869> since

Published version:

DOI:10.1097/JTO.0b013e318169cd9a

Terms of use:

Open Access

Anyone can freely access the full text of works made available as "Open Access". Works made available under a Creative Commons license can be used according to the terms and conditions of said license. Use of all other works requires consent of the right holder (author or publisher) if not exempted from copyright protection by the applicable law.

(Article begins on next page)

Fetal Adenocarcinoma of the Lung in a 25-Year-Old Woman

Marina Longo, MD,* Matteo Giaj Levra, MD,* Enrica Capelletto, MD,* Andrea Billè, MD,†
 Francesco Ardisson, MD,† Ubaldo Familiari, MD,‡ and Silvia Novello, MD, PhD*

Abstract: We report the case of a 25-year-old woman with a chance detection at x-ray of a well-defined mass in the right upper lobe during a medical examination. The patient suffered from a modest flu syndrome, with cough and fever. She was a current smoker. CT scan showed a homogeneous well-defined perihilar mass without calcifications, located in the right upper lobe and fully surrounded by aerated parenchyma. A right upper lobectomy with mediastinal lymph node sampling was performed. A pathologic diagnosis of well-differentiated fetal adenocarcinoma of the lung was made and staged as T2N0. Few cases of this type of malignancy have been reported in literature.

Key Words: Fetal adenocarcinoma, Lung cancer.

(*J Thorac Oncol.* 2008;3: 441–443)

In July 2007, a 25-year-old woman was referred to University of Turin, after a chance detection on chest x-ray of a well-defined mass in the right upper lobe during a medical examination for eligibility in the Italian army. The patient was a moderate, current smoker (10 cigarettes a day for 9 years). At the time of the medical visit, she reported a modest flu syndrome, with cough and fever.

Before the patient was referred to our hospital for examination, a computed tomography scan of the chest was performed, which demonstrated a homogeneous well-defined perihilar mass without calcifications located in the right upper lobe and fully surrounded by aerated parenchyma. No hilar or mediastinal node enlargement or additional parenchymal lesions were detected (Figures 1 and 2).

At the time of hospitalization, the results of the physical examination of the patient were completely normal. The fiberoptic bronchoscopy performed the next day was completely normal, as well as pulmonary function tests and arterial blood

gas analyses. A cardiologic examination including 12-channel electrocardiography excluded any contraindication to surgery. After having informed the patient, it was decided to proceed directly to surgical exploration and resection without performing additional investigations. A right upper lobectomy with mediastinal lymph node sampling was performed on July 12, 2007.

Gross examination revealed a single, white, 4-cm well-defined mass (Figure 3). At light microscopy, the tumor revealed sharp borders fully surrounded by normal lung tissue. The tumor was composed of well differentiated glands lined by a single row of columnar cells, with occasionally subnuclear vacuolization, resembling endometrial glands (Figures 4 and 5). Focal squamous metaplasia and a desmoplastic stroma with no immature cells were observed. The definitive diagnosis of well-differentiated fetal adenocarcinoma of the lung was made and pathologic staging was T2N0. Immunohistochemistry showed strong positivity for cytokeratin 8, 18 and beta-catenin expression, and was negative for estrogen and progesterone receptor, CEA, alpha-feto protein, cromogranin A, NSE, p-53, and S100.

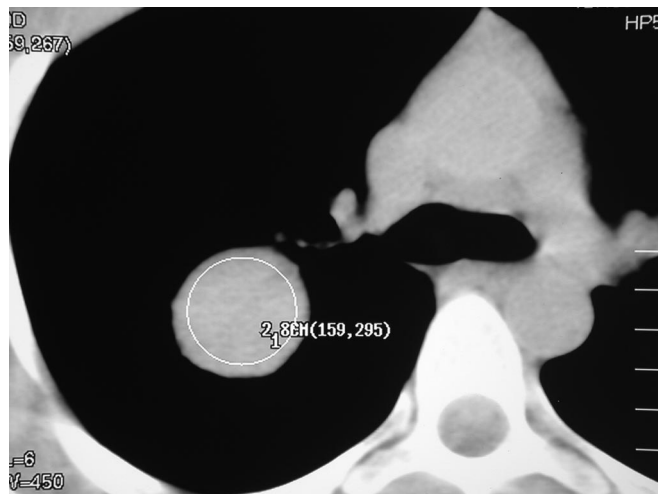


FIGURE 1. The chest computed tomographic scan shows a homogeneous well-defined perihilar mass without calcification in the right upper lobe.

*Thoracic Oncology Unit, Department of Biological and Clinical Sciences, †Division of Thoracic Surgery and ‡Division of Pathology, Department of Biological and Clinical Sciences, University of Turin, Italy.

Disclosure: The authors declare no conflicts of interest.

Address for correspondence: Silvia Novello, MD, PhD, University of Turin, San Luigi Hospital, Regione Gonzole 10, 10043, Orbassano, Turin, Italy.

E-mail: silvia.novello@unito.it

Copyright © 2008 by the International Association for the Study of Lung Cancer

ISSN: 1556-0864/08/0304-0441

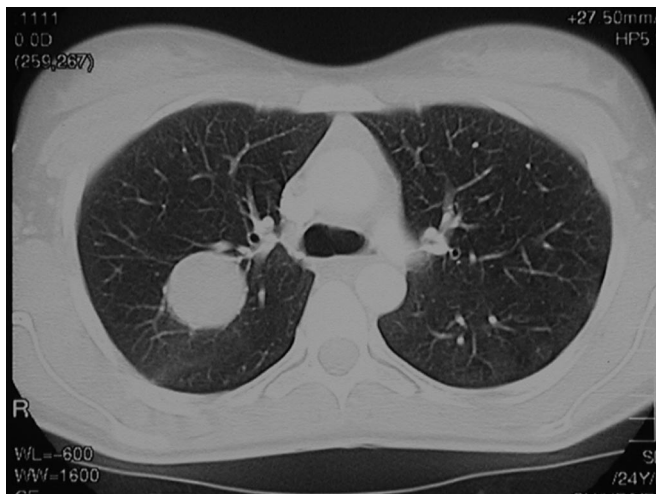


FIGURE 2. Baseline CT scan of the chest.

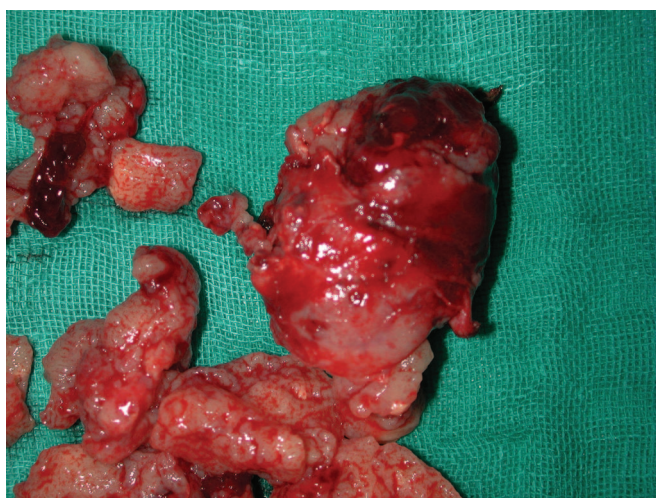

FIGURE 3. Intraoperative specimen. Fragmented mass with encephaloid features.

DISCUSSION

Well-differentiated fetal adenocarcinoma is a rare type of lung tumor, first described by Koss et al. in 1991.¹ It appears as a fetal lung at 10 to 15 weeks of gestation, resembling pulmonary blastoma, but the adjacent mesenchymal tissue is histologically benign.²

In the current classification of lung tumors, the World Health Organization separated this tumor from the pulmonary blastoma category and it is now classified as a variant of adenocarcinoma with a good prognosis (ICD-O 8333/3).³ No specific immunohistochemical pattern has been described for this tumor type.

There are few published reports describing this tumor.^{4,5} It is generally detected in young subjects, and is clinically characterized by a low-grade malignancy and with a 5-year mortality rate of 15 to 20%.^{6,7} Most of reported cases were coded as pathologic stage I, and the above-mentioned survival data are mainly related to this stage of disease. For the few patients

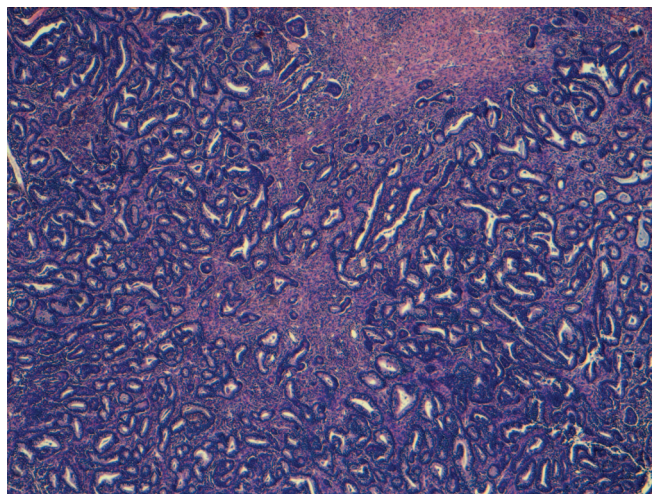


FIGURE 4. Fetal adenocarcinoma of the lung. At low magnification a growth of densely packed irregular glands, lined by columnar cells, in a cellular stroma is observed.

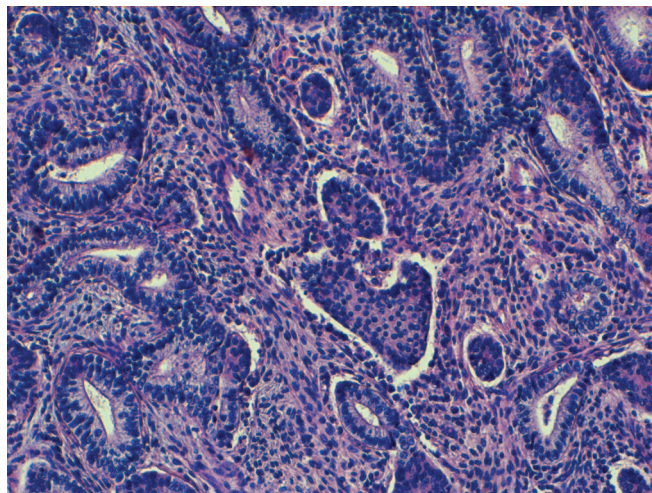


FIGURE 5. Fetal adenocarcinoma of the lung. Irregular glands are observed in a cellular pattern lacking atypia and made of elongated cells with bland nuclei. The glands are lined by columnar cells, with a basal partially polarized nucleus and scant mucinous cytoplasm. A central nest of squamoid looking cells is present.

reported with stage II or greater, no survival data has been published and adjuvant chemotherapy or radiotherapy have seldom been performed.

Based on current information about the disease, no additional treatment was recommended and the patient was discharged. In October (3 months after the surgical resection), a total body CT scan was negative. Follow up is planned for every 3 months for the first year, then every 6 months from the second to the fifth year, and then annually.

REFERENCES

1. Koss MN, Hochholzer L, O'Leary T, et al. Pulmonary blastomas. *Cancer* 1991;67:2368-2381.

2. Nakatani Y, Kitomura H, Inayama Y, et al. Pulmonary adenocarcinomas of the fetal lung type. *Am J Surg Pathol* 1998;22:399–411.
3. Colby TV. Adenocarcinoma. In: Travis WD, Brambilla E, Harris CC (Eds). World Health Organisation Classification of Tumours: Tumors of the Lung, Pleura, Thymus and Heart. Lyon: IARC Press, 2004. Pp. 35–44.
4. Sheehan KM, Curran J, Kay EW, et al. Well differentiated fetal adenocarcinoma of the lung in a 29 year old woman. *J. Clin Path* 2003;56: 468–469.
5. Fujino S, Asada Y, Konishi T, et al. Well differentiated fetal adenocarcinoma of lung. *Lung Cancer* 1995;13:311–316.
6. Sato S, Koike T, Tsukada H, et al. Resected well differentiated fetal adenocarcinoma and summary of 25 cases reported in Japan. *JPN J Thorac Cardiovasc Surg* 2006;54:539–542.
7. Kodama T, Shimosato Y, Watanabe S, et al. Six cases of well differentiated adenocarcinoma simulating fetal lung tubules in the pseudoglandular stage. *Am J Surg Pathol* 1984;8:735–744.