

AperTO - Archivio Istituzionale Open Access dell'Università di Torino

A novel family with Lamin B1 duplication associated with adult-onset leucoencephalopathy

This is the author's manuscript

Original Citation:

Availability:

This version is available <http://hdl.handle.net/2318/58033> since

Published version:

DOI:10.1136/jnnp.2008.147330

Terms of use:

Open Access

Anyone can freely access the full text of works made available as "Open Access". Works made available under a Creative Commons license can be used according to the terms and conditions of said license. Use of all other works requires consent of the right holder (author or publisher) if not exempted from copyright protection by the applicable law.

(Article begins on next page)



UNIVERSITÀ DEGLI STUDI DI TORINO

This is an author version of the contribution published on:

Questa è la versione dell'autore dell'opera:

*[J Neurol Neurosurg Psychiatry. 2009 Feb;80(2):237-40. doi:
10.1136/jnnp.2008.147330.]*

The definitive version is available at:

La versione definitiva è disponibile alla URL:

[<http://jnnp.bmj.com/content/80/2/237.long>]

A NOVEL FAMILY WITH LAMIN B1 DUPLICATION ASSOCIATED WITH ADULT-ONSET LEUKOENCEPHALOPATHY

Alessandro Brussino ¹, MD, Giovanna Vaula ², MD, Claudia Cagnoli ¹, PhD, Alessandro Mauro ³, MD, Luca Pradotto ⁴, MD, Dino Daniele ⁵, MD, Eleonora Di Gregorio ¹, MSc, Marco Barberis ¹, PhD, Carlo Arduino ¹, MD, Stefania Squadrone ⁶, PhD, Maria Cesarina Abete ⁶, MSc, Nicola Migone ¹, MD, Olga Calabrese ⁷, MD, Alfredo Brusco ¹, PhD.

¹ *Department of Genetics, Biology and Biochemistry, University of Torino, and S.C.D.U. Medical Genetics, Az. Osp. San Giovanni Battista, Torino, Italy*

² *S.C.D.U. Neurologia II, Az. Osp. San Giovanni Battista, Torino*

³ *Department of Neurosciences, University of Torino*

⁴ *Department of Neurology, IRCCS Istituto Auxologico Italiano, Piancavallo (VB), Italy*

⁵ *S.C.D.U. Neuroradiology, Az. Osp. San Giovanni Battista, Torino*

⁶ *C.Re.A.A., Istituto Zooprofilattico Sperimentale del Piemonte, Liguria e Valle d' Aosta, Torino, Italy*

⁷ *Department of Experimental Medicine and Diagnostics, Medical Genetics Unit, University of Ferrara, Italy*

* Corresponding author: Alfredo Brusco, *Department of Genetics, Biology and Biochemistry, University of Torino, via Santena, 19 - 10126 Torino, Italy. Fax: +39 011 670 5668; e-mail: alfredo.brusco@unito.it*

Keywords: LMNB1; lamin; leukodystrophy; leukoencephalopathy; myelin

Running head: LMNB1 duplication

Financial Disclosure: None reported.

Word count: 2962 words

ABSTRACT

Background and aim: Lamin B1 duplication has recently been described in a rare form of autosomal dominant adult-onset leukoencephalopathy associated with autonomic dysfunction. Aim of our work was to evaluate the presence of lamin B1 gene defects, in a series of eight patients with adult-onset hereditary diffuse leukoencephalopathy.

Methods: Six probands were compatible with an autosomal dominant transmission. The clinical picture was represented by a variable combination of pyramidal, cerebellar, cognitive, and autonomic dysfunction. Neuroradiological (MRI) data showed symmetrical and diffuse white matter lesions in six, and multifocal confluent lesions in two. Lamin B1 full deletion/duplication and point mutations were searched using Taqman real-time PCR assay and direct sequencing of all coding exons.

Results: One patient carried a 140-190 Kb duplication involving the entire *LMNB1* gene, the *AX748201* transcript and the 3' end of *MARCH3*. Clinical and neuroimaging data of this proband and an affected relative, overlapped with the features of the *LMNB1* duplication described by Padiath et al. (2006). Lamin B1 expression was found increased in lymphoblasts. No *LMNB1* gene defects were identified in the remaining seven probands

Conclusions: *LMNB1* duplication appears to be associated only to a subset of the adult-onset autosomal dominant leukoencephalopathies, sharing the following features: onset with autonomic dysfunction, diffuse T2-hyperintensity of supra- and infra-tentorial white matter, sparing of U-fibers and optic radiations. The more variable phenotypes in the seven families lacking *LMNB1* defects suggests that other genes might be involved in the autosomal dominant leukoencephalopathies.

INTRODUCTION

Hereditary leukoencephalopathies are rare disorders characterized by progressive degeneration of myelin in the brain, with variable degree of involvement in the peripheral nervous system.[1] They can be classified in primary forms, where the disorder affects predominantly the white matter, and secondary leukoencephalopathies, where a more diffuse process leads to the destruction of both axons and myelin. The most common forms include autosomal recessive (e.g., Metachromatic leukodystrophy, Krabbe disease, Canavan disease, Vanishing White Matter disorder) or X-linked patterns (e.g., Adrenoleukodystrophy, Pelizaeus-Merzbacher disease).[2] Typically, the onset is in infancy or childhood.[1]

Autosomal dominant forms include Alexander disease, due to mutations in the *GFAP* gene, CADASIL (Cerebral Autosomal Dominant Arteriopathy with Subcortical Infarcts and Leukoencephalopathy), the most common form of hereditary stroke disorder, and the recently described adult-onset autosomal dominant leukodystrophy (ADLD, OMIM#169500), due to duplication of the *LMNB1* gene. This latter was reported in four families, two Irish-American and two Japanese kindreds, and it is characterized by a homogeneous phenotype with onset between 40-50 yr with initial autonomic dysfunctions.[3-5] A limited number of families with or without autonomic dysfunctions and autosomal dominant inheritance are present in the literature, but the involvement of the *LMNB1* gene is unknown.[6-13]

The duplication of the *LMNB1* gene probably acts through a gain of function mechanism, because increased brain expression of the *LMNB1* gene and its protein have been demonstrated.[5] The pathogenic mechanisms leading to the phenotype are still unknown, and it has not been clarified if the duplication is associated with different clinical phenotypes, as happens with the *PLP1* gene duplication causing a wide clinical

spectrum of Pelizaeus-Merzbacher disease,[14] nor if point mutations in the *LMNB1* gene may mimic the phenotype of the duplication.

Aim of our work was to evaluate the presence of full *LMNB1* gene deletion/duplication, as well as point mutations in the coding region, in a selected a group of eight unrelated cases with an adult-onset form of leukoencephalopathy. One of these patients had a phenotype completely overlapping ADLD.

MATERIALS AND METHODS

Clinical and neuroradiological features of ADLD patients

We collected eight unrelated Italian cases with a hereditary form of adult-onset leukoencephalopathy (Table 1). All patients had in common the onset above 30 yr., the slowly progression of neurological symptoms, MRI suggestive for white matter pathology, and at least one first-degree relative affected by a similar disorder. Seven patients (28, 41, 43, 69, 89, 94, and 109) were referred to this study after a molecular test for exclusion of CADASIL (DHPLC analysis of exons 2-23 of the *NOTCH3* gene), whereas patient G769 was sent by a Medical Genetics Unit in Ferrara with a diagnosis of “ADLD compatible with *LMNB1* duplication”.

Adult-onset Alexander disease was excluded on the basis of the neuroradiological pattern of the white matter involvement.[15, 16]

*Analysis of the *LMNB1* duplication by quantitative real-time PCR.*

Gene dosage analysis was performed in a quantitative duplex PCR assay. Amplification was performed in a total of 20 µl containing 10 µl of Taqman Universal PCR Master mix (P/N 4324018, Applied Biosystems), 1 µl of RNase P kit (20X, VIC dye, P/N 4316844), 2 µl of forward (5'-gccaaaaaacagtttagcagatgaa)₅ and reverse (5'-cgaaactccaagtcctcagtaagg) specific primers (5 pmol/µl each), and 2 µl of MGB probe (6FAM-acttaaagtagattggagaatc-

MGBNFQ, 100 μ M) mapping within exon 3 of the human *LMNB1* gene; genomic DNA was between 50-100 ng in 3 μ l. For each sample a triplicate mix was prepared and aliquoted in three different wells of a 96-well plate. The thermal cycling conditions were: 2 min at 50°C, 10 min at 95°C, followed by 40 cycles 15 min 95°C and 1 min 60°C. The PCR was performed in a 96-well clear optical reaction plate 5700 apparatus (Applied Biosystems).

The gene dosage strategy was based on the relative amplification of the target sequence (*LMNB1*) and the coamplified internal standard RNase P. The number of *LMNB1* copies was calculated using the comparative delta Ct method described by Livak and Schmittgen.[17]

Analysis of the relative peak height ratio.

We compared, in patients vs. normal subjects, the sequencing profiles of heterozygous Single Nucleotide Polymorphism (SNP) or heterozygous Short Tandem Repeats (STRs).[5] In patients carrying a duplication a relative increase of the peak corresponding to the duplicated allele was easily identified by visual inspection. This strategy was used to define the boundary of the duplicated region.

Screening for LMNB1 point mutations

The lamin B1 gene (*LMNB1*, 5q23.2, 11 exons; physical position at chr5: 126,140,732-126,200,608, NM_005573.2) was screened for point mutations in the coding region, using primers designed to flank each exon, in eight affected index cases (conditions available upon request). Amplified products were purified using ExoSap (GE-Healthcare Lifescience, Milan, Italy) and directly sequenced using the Big Dye Terminator Cycle Sequencing kit ver.1.1 on an ABI Prism 3100 Avant automatic sequencer (Applied Biosystems, Foster City, CA, USA).

Expression analysis of the LMNB1 gene

TaqMan real-time quantitative PCR analysis was used to measure levels of expression of *LMNB1* in one affected individual (III-4) and three healthy controls. mRNA was extracted from the lymphoblastoid cell lines and retrotranscribed using the “TaqMan gene expression cells-to-ct” kit under the conditions specified by the manufacturer (Applied Biosystems). The expression levels of *LMNB1* and two different reference genes were measured with pre-designed Taqman gene expression assays, each containing two gene specific primers and an internal FAM™ dye-labeled TaqMan® MGB probe (*LMNB1*, Hs01059210_m1, *TBP*, Hs00427620_m1, *G6PDH*, Hs00188728_m1). Reference genes were selected based on.[18] Reactions were carried out on an ABI 7500 real-time PCR machine using the ABI 2x TaqMan universal PCR master mix according to the manufacturer’s instructions (Applied Biosystems). Samples were run in triplicate and the mean Ct value was used for calculation.[17]

RESULTS

Screening for lamin B1 duplication and point mutations

We screened eight unrelated patients with an adult-form of familial leukoencephalopathy for duplications of the *LMNB1* gene. Clinical and MRI features of these subjects are summarized in table 1. Using gene dosage real-time PCR and sequencing analysis of heterozygous SNP profiles, we found a positive case, whose four generations pedigree showed a clear autosomal dominant pattern (Figure 1, III-6; Table 1, G769). The duplication was confirmed in a second affected member of the family (III-4). Using the analysis of relative peak height ratio of heterozygous microsatellite markers and SNPs, we defined a duplicated segment of $\frac{140-190}{7}$ kb (Figure 2). This region contains the *LMNB1* gene, the uncharacterized transcript *AX748201*, and the 3’ end of the

MARCH3 gene (Figure 2). The precise characterization of the breakpoints was not possible, although, using published primers, we excluded that this is one of the two large duplications, whose breakpoints were already characterized (families K4233, K2685 and K50069).[5] However, this duplication is similar to that described in family K4975, of Japanese origin, whose boundaries were approximate (duplication >150 kb).[5]

No point mutation was found screening the coding exons and flanking introns of the *LMNB1* gene in the remaining series of seven cases.

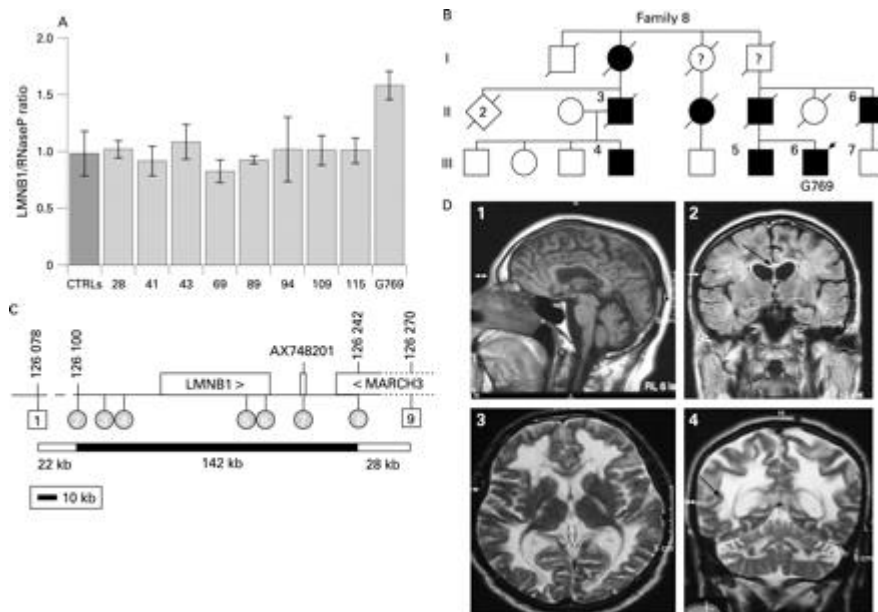


Figure 1 Results of the lamin B1 gene (*LMNB1*) duplication analysis. (A) TaqMan real-time PCR copy number analysis. y Axis: ratio of *LMNB1* vs *RNaseP* gene copies (normal, ~1.0; duplication ~1.5). x Axis: subjects tested; CTRLs are 100 normal subjects. Error bars indicate SD. (B) Patient's G769 (arrowhead) pedigree. Three generations are represented; black symbols indicate affected cases. Question marks inside the symbol indicate the absence of clinical records. (C) Duplicated segment in family 8. *LMNB1*, *MARCH3* and *AX748201* transcripts are shown as rectangles (arrowhead inside indicates the direction of transcription). Positions are indicated in kb (<http://www.genome.ucsc.edu>, assembly March 2006). Grey dots are SNPs markers that showed an unbalanced pattern compatible with a duplication; white squares are STR markers that showed a non-duplicated pattern (see supplementary fig 3). The minimal duplicated segment extends from position ~126 100 kb to ~126 242 kb (black bar), with an uncertain region of 22 kb upstream and 28 kb downstream (hyphenated line and white bar). (D) Cranial MRI of patient III-4. T1 spin echo sagittal (1), T2 Flair coronal (2), T2 weighted TSE axial, and coronal (3, 4): atrophy in medulla oblongata in (1); hyperintensity of the cerebellum, supratentorial and posterior limb of the internal capsulae with sparing of the periventricular white-matter rim (arrow in 4); partial involvement of corpus callosum (arrow in 2).

Clinical and neuroradiological phenotype in family 8

Patient III-6, clinics and neuroradiology

The proband (G769 in table 1), a male aged 56 yr., was born from non consanguineous parents. He had a positive family history for neurological diseases. His father died at 57

yr., unable to walk; his brother had a diagnosis of primary progressive Multiple Sclerosis (MS); a paternal uncle (II-6) had been diagnosed in mid 1980 as having pseudobulbar syndrome and “vascular subcortical encephalopathy”.

Patient’s III-6 birth, neonatal period and youth were uneventful. He started to complain from micturition disorder (urgency and retention) at 45 yr. A few years later, he developed slight and not disabling gait disturbances. He was admitted to a neurological department and received a diagnosis of “leukoencephalopathy of unknown metabolic deficit”. At that time, a CSF exam was unremarkable and MRI demonstrated a diffuse and symmetrical involvement of the white matter of centrum semiovalis, posterior brachia of internal capsula and corticospinal tracts. The infratentorial white matter was also involved. Moreover, MRI of the spinal cord showed a diffuse atrophy of the cervical and dorsal segments.

At 51 yr., the patient experienced an acute worsening of motor function with severe paresis of the legs and areflexia, following a gastrointestinal infection. He was hospitalized and a new CSF exam revealed increased protein levels. The EMG examination was suggestive for Acute Motor Axonal Neuropathy (AMAN). The patient underwent a treatment with high dose of intra-venous immunoglobulins with partial recovery.

At present, the patient can stand with minimal monolateral support, he is unable to walk autonomously, does not show any cranial nerve involvement, has a slightly decreased strength at both hands, moderate-severe paresis of the legs with no increase of muscular tone, areflexia at both arms and legs. Babinski sign is bilaterally present and no cerebellar signs are detectable. Urgency and incontinence are also present.

Recently, the patient underwent a new cerebral MRI. T1, T2, DP weighted images, in sagittal, axial and coronal planes, coronal T2W FLAIR images and T1W images after

Gadolinium injection were obtained. A diffuse T2 hyperintensity was present in the cerebellar hemispheres white matter, as well as in the posterior limbs of the internal capsules, and the white matter of centrum semiovalis. A thin rim of periventricular white matter was spared. Corpus callosum was minimally involved. Optic radiations and U-fibers were spared (Figure 3).

Hypointensity of the centrum semiovalis on T1W images was present; no contrast enhancement followed Gadolinium injection (see figure 3). There was evidence of atrophy of corpus callosum, pons and medulla oblongata without signal anomaly, whereas ventricular volume and sulci were normal. No calcifications or cystic degeneration were detectable.

Patient III-4, clinics and neuroradiology

The disease onset at 35 yr. with urinary retention, foecal incontinence and sexual disturbances gradually evolving to impotence. A first neurologic and neuroradiologic examination was made in 1987 and a diagnosis of possible MS was suggested. Four years later he noticed impairment in walking due to gait imbalance and weakness of the legs. Spastic crying and laughing were also present. The patient was admitted to a neurological department and underwent an extensive workup to exclude both a demyelinating disorder and leukodystrophies of known metabolic defects. Lysosomal enzyme activities (Exosaminidase A and B, Arylsulphatase A, galactosylcerebrosidase, α and β mannosidase) were normal. CSF exam was unremarkable and oligoclonal bands were not detected. No anomalies were evident at the electroneurographyc exam. At that time, a neuropsychological evaluation failed to detect any deficits in cognitive functions. The disease slowly progressed and fifteen years after the onset the patient was wheel-chaired. A neurological examination showed marked pyramidal signs (hyperreflexia, spastic hypertonus, bilateral Babinski sign), cerebellar dysfunction

(intentional tremor, bilateral asymmetrical dysmetria, dysarthria); sensation was normal. A mild cognitive impairment with deficit in frontal functions was detected at the neuropsychological exam (Wisconsin Card Sorting Test, Stroop test). The vegetative nervous system was evaluated (tilt test, Valsalva test and deep breathing test) confirming the involvement of orthosympathetic function.

The cerebral MRI showed a diffuse T2 hyperintensity of the white matter of cerebellar hemispheres, posterior limbs of the internal capsules, centrum semiovalis, corpus callosum with sparing of optic radiations and subcortical U-fibers. Pons, medulla oblongata and vermis appeared mildly hypotrophic. A slight supratentorial atrophy was present.

Patient II-6

We collected clinical records of patient II-6, paternal uncle of III-6, who was discharged at 61 yr. from a neurological department with a diagnosis of “pseudobulbar syndrome”. His clinical history was unremarkable until 51 yr., when he developed urinary retention and incontinence, and underwent an urological surgery without any improvement. Five years later, a difficulty in walking appeared as an increased weakness of the legs and motor impairment.

Later, he showed dysarthria and dysphagia. No deficits in cognitive function, nor psychiatric symptoms were reported from clinicians. An EMG was normal, whereas a CT scan revealed a diffuse hypodensity of periventricular and subcortical white matter, interpreted as of ischemic origin. His general conditions progressively worsened, at 68 yr. the patient was confined to bed, and died three years later (71 yr.). DNA was not available for molecular confirmation of the *LMNB1* gene duplication testing.

Five out of seven probands (see table 1) had a pedigree compatible with an autosomal dominant inheritance (the father or the mother was affected). In two families (patients 89 and 94) one brother was affected, and the clinical/MRI status of the parents was unknown.

Five probands showed a diffuse damage of the white matter, whereas two had multifocal confluent lesions. The cerebellum was involved in four. One patient complained impotence; orthostatic hypotension was the onset symptom of another patient. In four cases a psychiatric disorder co-existed: in two cases bipolar disorder was present, major depression in one and organic psychosis in another case. Patients 41, 69, and 89 had a cognitive impairment with the MMSE (Mini Mental State Examination) score of 16, 22 e 14 (normal values 24-30). Inflammatory alterations in blood or cerebrospinal fluid as well as oligoclonal Ig bands in CSF were absent in all.

Expression analysis of LMNB1 in a duplicated patient

We analysed levels of *LMNB1* expression in lymphoblastoid cell lines of one duplicated patient (III-4) (Fig. 4). In all the assays, the normal controls showed a limited variability of *LMNB1* expression, whereas there was a marked increase in expression levels in subject III-4 (around 5-fold) relative to control samples. To verify that expression changes were not due to the reference gene used in the experiments, we performed the analysis with two different reference genes (*TBP* and *GA6PDH*), obtaining similar results (Fig. 4).

DISCUSSION

Duplication of the *LMNB1* gene has recently been associated with adult-onset autosomal dominant leukodystrophy (ADLD) in four families with different ethnic origin (Irish-American and Japanese).[5] All affected subjects display similar clinical features, with onset in the 4th - 5th decade of life and initial involvement of the autonomic

nervous system, including bowel and bladder dysfunction, impotence, orthostatic hypotension and decreased sweating. These symptoms are followed by motor impairment due to pyramidal and cerebellar involvement.[3-5, 19] The MRI shows a diffuse alteration of the white matter signal both supra- and infratentorially, with involvement of the cerebellum, the corticospinal tracts, the corpus callosum, relative preservation of periventricular white matter and sparing of U-fibers without a significant atrophy. One further family with adult-onset autosomal dominant leukodystrophy mapped by linkage in 5q23 has been reported. [12, 13] As far as we know, there is no information on the *LMNB1* genetic testing in this family.

In our series of eight unrelated probands with adult-onset hereditary leukoencephalopathies (six with an autosomal dominant pattern of inheritance), one *LMNB1* duplicated patient was found (G769). The patient belonged to a large four-generation family with eight affected members. We collected clinical and neuroradiologic data from two of the three patients still alive. The onset and progression of the disease overlapped with those reported in the affected members of the families with *LMNB1* duplication, although the neuroimaging findings in the youngest patient were slightly different, showing relative sparing of corpus callosum. Therefore, the *LMNB1* duplication seems to be associated with a characteristic homogeneous phenotype highly suggestive for ADLD with autonomic dysfunction.

The duplication spans 140-190 kb, and contains the full length (and likely functional) *LMNB1* gene, the *AX748201* transcript of unknown significance, and the 3' portion of *MARCH3*. Thus, *LMNB1* is the only functional gene within the duplicated segment. The duplication breakpoints are different from the two characterized so far at the nucleotide level,[5] suggesting that duplications of *LMNB1* originated from independent mutational events.

We have also shown that *LMNB1* expression levels are increased in lymphoblasts from one patient with the duplication (~5 fold higher in our sample), as already observed by Padiath et al. (2006). This suggests a complex regulation of the lamin B1 expression, not only dependent upon gene copy number.

The expression analysis of *LMNB1* in lymphoblast cell lines may reveal useful to search for *LMNB1* dosage increase in other forms of leukodystrophies, that could be due to mutations in this gene different from duplications.

Because a whole spectrum of genetic defects, including point mutations and genomic duplications/deletions, have been identified in the *PLP1* gene associated with the X-linked form of Pelizaeus-Merzbacher disease,[14] we sequenced the entire *LMNB1* gene in the seven probands lacking *LMNB1* duplication. Although we did not find any mutation, this finding cannot rule out the possibility that point mutations in the *LMNB1* gene cause ADLD. The study of larger series of patients is needed to clarify this point, and to verify whether the ADLD phenotype with dysautonomic symptoms is invariably associated with the *LMNB1* duplication.

The only other forms of autosomal dominant leukodystrophy/leukoencephalopathy, whose genetic basis is known, are CADASIL and Alexander disease, which were excluded in the seven non-duplicated patients because of the MR characteristics, and, for CADASIL, also the absence of mutations in the *NOTCH3* gene.[16, 20, 21] Finally, two clinical/nosographic entities with an autosomal dominant pattern of inheritance, and specific white matter pathology and/or clinical features have been reported: a vanishing white matter-like leukoencephalopathy with onset in the mid-age and a pathognomonic MRI picture;[22] a hereditary diffuse leukoencephalopathy with spheroids associated with extrapyramidal signs, seizures, and cognitive impairment.[23] Both these forms, genetically orphan, were excluded on the clinical/MRI bases.

Our seven patients, negative for *LMNB1* mutations and without specific clinical and/or neuroradiological features, demonstrate that genetic heterogeneity is present among familial cases of leukoencephalopathy, despite their rarity.[6, 7]

Finally, due to the late age at onset, the slow progression, and the paucity of initial symptoms of the disease associated with *LMNB1* duplication, we may also suggest to consider the diagnosis of ADLD in all patients with autonomic dysfunction and milder non-specific white matter changes at the MRI, also known as “leukoaraiosis”.

ACKNOWLEDGMENTS

This work was supported by the “Associazione E.E. Rulfo per la Genetica Medica”, MURTS 60% to A.B.. We thank the technical assistance of P. Pappi and V. Giangarrà. We are gratefully indebted to the families and patients who participated in this study.

LEGEND TO FIGURES

Figure 1. Pedigree of the family 8. Four generations of the family are represented; black symbols indicate patients affected. Question mark inside the symbol indicates the absence of clinical records or patients below 40 yr., who may manifest the disease in the following decades. Black arrow indicates the proband (G769 in table 1).

Figure 2. Duplicated segment in the family 8. *LMNB1*, *MARCH3* and *AX748201* transcripts are shown as rectangles (arrowhead inside indicates the direction of transcription). Positions are indicated in kb (www.genome.ucsc.edu, assembly march 2006). Gray dots are SNPs markers that showed an unbalanced pattern compatible with a duplication; white squares are STR markers that showed a non-duplicated pattern. The minimal duplicated segment extends from position ~126,100 kb to ~126,242 kb on chromosome 5 (black bar), with an uncertain region of 22 kb upstream and 28 kb downstream (hyphenated line and white bar). On the right SNPs and STRs codes retrievable at www.gdb.org, and genome.ucsc.edu.

Figure 3. Cranial MRI of patients III.6 (panels a-d) and III.4 (panels e-h). (a,g) T2 Flair coronal; (b, d, f) T2 weighted TSE axial, and (h) coronal; (c) T1 spin echo axial, and (e) sagittal. Hyperintensity of cerebellar, supratentorial and posterior limb of internal capsulae are visible in panels a, b, d and f. T1 hypointensity is visible in panel c. A white arrow indicates sparing of U-fibers (panel a), optic radiations (panel b) and involvement of corpus callosum (panel g). A black arrow indicates the thin rim of preserved periventricular white matter in panel h. In panel e, the atrophy of medulla oblongata is evident.

Figure 4. Expression analysis of the $_{17}LMNB1$ gene in lymphoblasts of patient G769 by TaqMan real-time quantitative PCR. The histograms show the expression of *LMNB1* vs

two different reference genes (*G6PDH* and *TBP*) in the affected subject (gray square) and the controls (white square). Expression is normalized to the average value of the three controls. Each sample was run in triplicate.

REFERENCES

1. Schiffmann R, van der Knaap MS. The latest on leukodystrophies. *Curr Opin Neurol*. 2004;**17**:187-192.
2. Lyon G, Fattal-Valevski A, Kolodny EH. Leukodystrophies: clinical and genetic aspects. *Top Magn Reson Imaging*. 2006;**17**:219-242.
3. Eldridge R, Anayiotos CP, Schlesinger S *et al*. Hereditary adult-onset leukodystrophy simulating chronic progressive multiple sclerosis. *N Engl J Med*. 1984;**311**:948-953.
4. Asahara H, Yoshimura T, Sada S *et al*. [A Japanese family with probably autosomal dominant adult-onset leukodystrophy]. *Rinsho Shinkeigaku*. 1996;**36**:968-972.
5. Padiath QS, Saigoh K, Schiffmann R *et al*. Lamin B1 duplications cause autosomal dominant leukodystrophy. *Nat Genet*. 2006;**38**:1114-1123.
6. Abe K, Ikeda M, Watase K *et al*. A kindred of hereditary adult-onset leukodystrophy with sparing of the optic radiations. *Neuroradiology*. 1993;**35**:281-283.
7. Quattrocchio G, Leombruni S, Vaula G *et al*. Autosomal dominant late-onset leukoencephalopathy. Clinical report of a new Italian family. *Eur Neurol*. 1997;**37**:53-61.
8. Autti T, Mutttilainen M, Raininko R *et al*. Extensive cerebral white matter abnormality without clinical symptoms: a new hereditary condition? *Ann Neurol*. 1999;**45**:801-805.
9. Fukazawa T, Sasaki H, Kikuchi S *et al*. Dominantly inherited leukodystrophy showing cerebellar deficits and spastic paraparesis: a new entity? *J Neurol*. 1997;**244**:446-449.
10. Tagawa A, Ono S, Inoue K *et al*. A new familial adult-onset leukodystrophy manifesting as cerebellar ataxia and dementia. *J Neurol Sci*. 2001;**183**:47-55.
11. Nomoto N, Iwasaki Y, Arasaki K *et al*. Autosomal dominant childhood onset slowly progressive leukodystrophy--a Japanese family with spastic paraparesis, ataxia, mental deterioration, and skeletal abnormality. *J Neurol Sci*. 2004;**221**:35-39.
12. Marklund L, Melin M, Melberg A *et al*. Adult-onset autosomal dominant leukodystrophy with autonomic symptoms restricted to 1.5 Mbp on chromosome 5q23. *Am J Med Genet B Neuropsychiatr Genet*. 2006;**141**:608-614.
13. Melberg A, Hallberg L, Kalimo H *et al*. MR characteristics and neuropathology in adult-onset autosomal dominant leukodystrophy with autonomic symptoms. *AJNR Am J Neuroradiol*. 2006;**27**:904-911.
14. Inoue K. PLP1-related inherited dysmyelinating disorders: Pelizaeus-Merzbacher disease and spastic paraplegia type 2. *Neurogenetics*. 2005;**6**:1-16.
15. van der Knaap MS, Naidu S, Breiter SN *et al*. Alexander disease: diagnosis with MR imaging. *AJNR Am J Neuroradiol*. 2001;**22**:541-552.
16. van der Knaap MS, Ramesh V, Schiffmann R *et al*. Alexander disease: ventricular garlands and abnormalities of the medulla and spinal cord. *Neurology*. 2006;**66**:494-498.
17. Livak KJ, Schmittgen TD. Analysis of relative gene expression data using real-time quantitative PCR and the 2(-Delta Delta C(T)) Method. *Methods*. 2001;**25**:402-408.
18. Radonic A, Thulke S, Mackay IM *et al*. Guideline to reference gene selection for quantitative real-time PCR. *Biochem Biophys Res Commun*. 2004;**313**:856-862.
19. Coffeen CM, McKenna CE, Koeppen AH *et al*. Genetic localization of an autosomal dominant leukodystrophy mimicking chronic progressive multiple sclerosis to chromosome 5q31. *Hum Mol Genet*. 2000;**9**:787-793.
20. Singhal S, Rich P, Markus HS. The spatial distribution of MR imaging abnormalities in cerebral autosomal dominant arteriopathy with subcortical infarcts and leukoencephalopathy and their relationship to age and clinical features. *AJNR Am J Neuroradiol*. 2005;**26**:2481-2487.

21. van der Knaap MS, Salomons GS, Li R *et al.* Unusual variants of Alexander's disease. *Ann Neurol.* 2005;**57**:327-338.
22. Labauge P, Fogli A, Castelnovo G *et al.* Dominant form of vanishing white matter-like leukoencephalopathy. *Ann Neurol.* 2005;**58**:634-639.
23. Baba Y, Ghetti B, Baker MC *et al.* Hereditary diffuse leukoencephalopathy with spheroids: clinical, pathologic and genetic studies of a new kindred. *Acta Neuropathol.* 2006;**111**:300-311.

Table 1. Features of the eight patients with adult-onset leukoencephalopathy examined for *LMNB1* mutations.

Family	Proband	Sex	Onset	Other affected	Clinical symptoms						MRI signs	
					<i>Pyramidal dysfunction</i>	<i>Cerebellar dysfunction</i>	<i>Psychiatric disorder</i>	<i>Cognitive impairment</i>	<i>Autonomic dysfunctions</i>	<i>Axonal neuropathy</i>	<i>White matter lesions</i>	<i>Involvement of cerebellum</i>
1	28	M	34 yr.	mother, brother	Yes	-	-	-	Yes	-	Diffuse subcortical	Yes
2	41	M	30 yr.	mother	Yes	Yes	Yes	Yes	-	-	Diffuse subcortical	Yes
3	43	F	53 yr.	father	-	Yes	-	-	-	-	Diffuse subcortical	Yes
4	69	F	55 yr.	mother	Yes	Yes	Yes	Yes	-	-	Diffuse subcortical	Yes
5	89	M	54 yr.	brother ^a	Yes	-	Yes	Yes	-	-	Multifocal confluent with subcortical localization	No
6	94	F	50 yr.	brother ^a	Yes	Yes	-	-	-	-	Diffuse subcortical	No
7	109	M	38 yr.	father	-	-	Yes	-	-	-	Multifocal confluent with subcortical localization	No
8	G769	M	45 yr.	several ^b	Yes	-	-	-	Yes	Yes ^c	Diffuse subcortical	Yes

Note: ^a the parents could not be examined ^b see pedigree in fig. 1; patient G769 is III-6; ^c axonal neuropathy is acquired (see text).