

AperTO - Archivio Istituzionale Open Access dell'Università di Torino

Vulvar Paget Disease: One Century After First Reported.

This is the author's manuscript

Original Citation:

Availability:

This version is available <http://hdl.handle.net/2318/39322> since

Terms of use:

Open Access

Anyone can freely access the full text of works made available as "Open Access". Works made available under a Creative Commons license can be used according to the terms and conditions of said license. Use of all other works requires consent of the right holder (author or publisher) if not exempted from copyright protection by the applicable law.

(Article begins on next page)

Vulvar Paget Disease: One Century After First Reported

Mario Preti, MD,¹ Leonardo Micheletti, MD,¹ Marco Massobrio, MD,¹
Shin-ichi Ansai, MD, PhD,² and Edward J. Wilkinson, MD³

¹Department of Gynecology and Obstetrics, University of Turin, Turin, Italy; ²Department of Dermatology, Akita University School of Medicine, Akita City, Japan; and ³Department of Pathology, Immunology and Laboratory Medicine, College of Medicine, University of Florida, Gainesville, FL

■ Abstract

Objectives. To provide a critical assessment of the published literature on vulvar Paget disease and to allow individualized approaches to affected patients.

Materials and Methods. A computerized search for studies published in the literature up to June 2002 was carried out using Ovid® and Medline databases. We excluded single case reports, letters to editors, and abstracts.

Results. Historical and epidemiological aspects of vulvar Paget disease are summarized. Clinical and histopathological data support a recent proposal to classify vulvar Paget disease into two categories, primary and secondary, with significant clinical and prognostic implications. The treatment for primary vulvar Paget disease is wide and deep surgical excision. Inguinofemoral lymphadenectomy is added in the management of invasive neoplasms. In the presence of secondary Paget disease, therapy must be directed toward treatment of associated carcinoma.

Conclusions. The subclassification of vulvar Paget disease is essential for correct clinical management and treatment. Immunohistochemistry may assist in this important distinction. ■

Key Words: vulvar Paget disease, immunohistochemistry

Reprint requests to: Mario Preti, MD, Department of Obstetrics and Gynecology, University of Turin, Via Don Grioli, 6 10 137, Turin, Italy. E-mail: mario.preti@tin.it

© 2003, American Society for Colposcopy and Cervical Pathology
Journal of Lower Genital Tract Disease, Volume 7, Number 2, 2003, 122-135

Extramammary Paget disease is a group of rare cutaneous neoplasms with different localization and natural history [1]. In 1874 Sir James Paget, describing the disease of the breast that now bears his name, alluded to the possibility that the same entity might also involve other parts of the body [2]. The occurrence of extramammary Paget disease involving the penis and scrotum was first reported in 1888 by Crocker [3], for the perineal and anal region along with the scrotum by Darier and Couillaud in 1893 [4], and in 1901 Dubreuilh published the first instance of vulvar Paget disease in the *British Journal of Dermatology* [5].

Extramammary Paget disease is primarily a women's disease, with men constituting approximately 20% of cases. Lesions are usually found in sites with a high density of apocrine glands: vulva, penis, scrotum, anus, perianal region, and axilla. Other regions where apocrine or modified apocrine sweat glands are located, such as Moll's glands of the eyelids and ceruminous glands of the external ear canal, may be extramammary Paget disease sites. The term "ectopic" extramammary Paget disease [6] has been applied to locations where apocrine glands are not usually found, such as the buttock, the lateral aspect of the back, or the lower portion of the chest.

The most common location for extramammary Paget disease in women is the vulva; more than 600 cases have been reported to date. The second most common site is the perianal region. Simultaneous presentations at distant sites are rare [7, 8].

Intraepithelial vulvar Paget disease was classified as a

nonsquamous intraepithelial neoplasia of the vulva by the International Society for the Study of Vulvar Disease Terminology Committee in 1986 [9].

OBJECTIVE

The rarity of vulvar Paget disease makes it difficult to understand its different clinicopathological and prognostic characteristics from a single reported series. A critical assessment of the studies on vulvar Paget disease was carried out to update diagnostic concepts and to allow individualized management strategies of affected patients.

SOURCES, STUDIES SELECTION, AND INTEGRATION

We conducted a computerized search using Ovid® (Ovid Technologies®, Inc., New York, NY) and PubMed (<http://www.ncbi.nlm.nih.gov/PubMed/>) Medline database for studies published from January 1966 to June 2002 with the search terms “Paget disease.” References were limited to studies published in English, pertaining to humans, and more specifically females. A cross search using the terms “vulvar neoplasms and perineum” was performed to avoid the inclusion of Paget disease of sites other than the vulvoperineal region. We excluded single case reports, letters to editors, and abstracts. Evaluation of the bibliographies of retrieved articles and consultation with experts in the field provided additional references.

Relevant features were extracted from each study and divided into the following groups: clinical aspects, histopathological aspects, vulvar Paget disease and invasive neoplasms, and treatment. The review was focused on data useful to optimize patient care.

CLINICAL ASPECTS

Patient Characteristics

Vulvar Paget disease is uncommon and accounts for 2.5% of all vulvar malignancies [10]. It affects mainly white patients aged between 40 and 80 years. The median age is approximately 70 [10–13] both for intraepithelial and invasive vulvar Paget disease patients [14]. No element in patients’ family, environmental, or social histories suggested an etiology or propensity for developing vulvar Paget disease.

Symptomatology

Symptoms are not specific; most patients report itching, burning, and soreness. A small subset of patients may be asymptomatic. Presence of vulvar pain, bleeding, and tumor formation are reported to be more common in patients affected by invasive disease [14, 15].

Macroscopic Appearance

Vulvar Paget disease presents as a variety of clinical lesions that may occur over a protracted course. Initially it is velvety, soft, and red or bright pink with scattered white islands of hyperkeratosis (Figure 1). The lesions become erythematous, plaque like, and desquamating especially when located in dry areas. Rarely the appearance is ulcerated (Figure 2). Cases of pigmented vulvar Paget disease are reported [16]. The borders appear irregular, slightly elevated, and sharply demarcated [17, 18]. The visible borders of vulvar Paget disease are often misleading as Paget cells may spread along the basal layers of normal appearing skin with multicentric foci [18–22]. Involvement may be extensive including the perianal region, genitocrural, and inguinal folds [23]. Clinical examination should determine the presence of periurethral and perianal lesions (Figure 3). In these cases an involvement of the skin by a noncutaneous internal neoplasm may occur (see below).

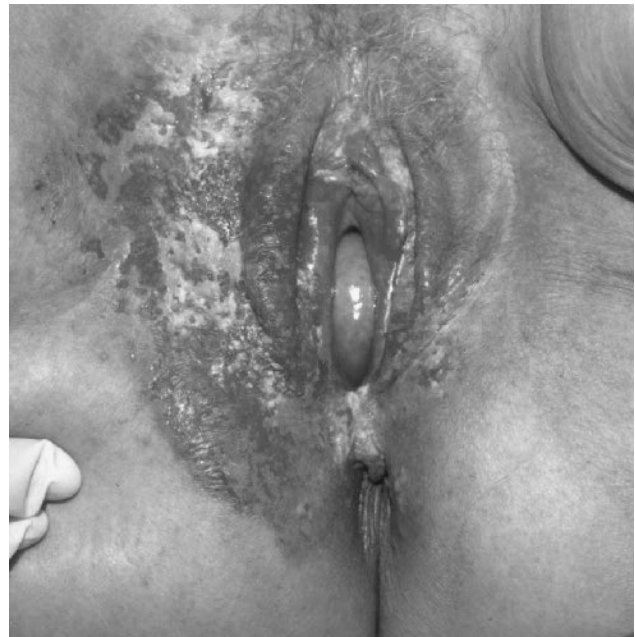

Figure 1. Clinical aspect of intraepithelial primary vulvar Paget disease: an extensive erythematous slightly raised lesion with areas of hyperkeratosis involves the external genitalia and the right genitocrural fold.

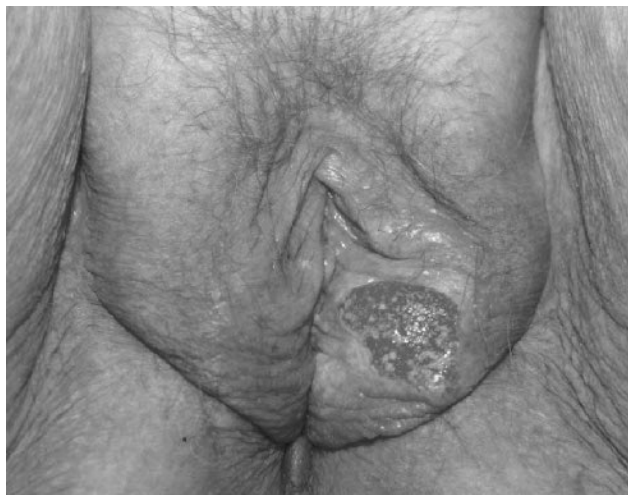

Figure 2. Clinical aspect of primary vulvar Paget disease with stromal invasion: ulcerated area on the left labium majus.

Differential Diagnosis

Macroscopic aspects of vulvar Paget disease lesions are often confused with lichen sclerosus, dermatophytosis, candidiasis, contact dermatitis, psoriasis, seborrheic dermatitis, and squamous vulvar intraepithelial neoplasia. An accurate anamnesis, a clinical examination to search for similar lesions elsewhere on the body and a biopsy with the appropriate use of immunohistochemistry, will confirm a vulvar Paget disease diagnosis.

HISTOPATHOLOGICAL ASPECTS

Histogenesis

Among the theories discussed in the literature regarding the histogenesis of vulvar Paget disease [11, 24, 25] the multifocal origin was generally accepted. This assumption was based on concepts of skin embryology. Woodruff and Kaufman hypothesized that Paget cells derive from undifferentiated basal cells of the stratum germinativum [26, 27], the stem cells that, except for the melanocytes, are the origin of all the cells of the epidermis and its appendages [28]. This embryology-based hypothesis explained the multifocal primary origin of intraepithelial Paget disease with or without associated underlying adenocarcinoma and does not contradict the fact that intraepithelial disease can remain in situ for a long period of time before invading the dermis [17, 24, 25, 29, 30].

The origin of vulvar Paget disease from supernumerary mammary glands has also been suggested [31]. Current evidence, however, supports that these mammary-like glands are not supernumerary mammary glands but

rather vulvar specialized anogenital glands closely related to eccrine glands [32].

Recently Wilkinson and Brown have proposed a classification of vulvar Paget disease that takes into account its heterogeneous origin. This classification defines two distinct groups of vulvar Paget disease, those of cutaneous origin and those of noncutaneous origin. The latter group includes Paget disease of urothelial, anorectal, and other noncutaneous sites [33]. This classification is supported by immunohistochemical studies to distinguish these Paget lesions and aids in understanding the otherwise apparent conflicting findings in various reports of Paget disease.

Histopathology

Vulvar Paget disease diagnosis is established through the histologic examination of a biopsy. Pathognomonic is the finding of atypical glandular type cells, the Paget cells, scattered or grouped in nests within the surface squamous epithelium [34, 35]. In routine hematoxylin and eosin stained histologic sections, Paget cells are rounded or polygonal elements of relatively large size with abundant clear pale eosinophilic cytoplasm (Figure

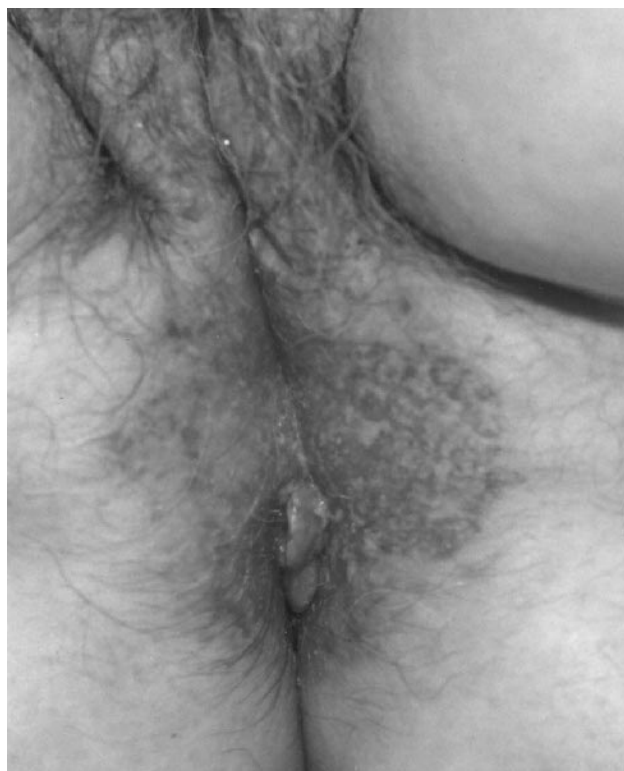

Figure 3. Clinical aspect of intraepithelial primary vulvar Paget disease: perineal and perianal extension of eczematous appearing lesion.

4). The cytoplasm contains neutral and acid mucopolysaccharides that stain positively with mucicarmine, aldehyde fuchsin, Alcian blue at pH 2.5, Periodic acid/Schiff, which is resistant to diastase digestion [17, 36], and it is usually also positive to colloidal iron and sialomucin staining [37]. Mitotic figures do not frequently occur [38].

Involvement of the pilosebaceous units and sweat glands may be seen [34, 39–41]. The occurrence of epidermal lesions adjacent to anogenital Paget disease has been recently studied [42].

As opposed to intraepithelial vulvar Paget disease, invasive disease shows a discontinuous basement membrane in the area of invasion with groups of Paget cells protruding into the underlying stroma [38]. These cells appear more anaplastic and react weakly with mucicarmine stain [39, 41].

Differential Diagnosis

Histologic differential diagnosis of vulvar Paget disease includes pagetoid melanoma, vulvar squamous intraepithelial neoplasia, sebaceous carcinoma, Merkel cell carcinoma with pagetoid intraepidermal spread, eccrine porocarcinoma, tricholemmal carcinoma, cutaneous T-cell lymphoma, Pagetoid Spitz nevus, and histiocytosis X [43–45].

It is crucial to exclude stromal invasion, underlying invasive adenocarcinoma, and vulvar pagetoid spread of associated adjacent noncutaneous adenocarcinoma that severely affect patients' prognosis. On routine histology some differences can be found between Paget cells of

primary vulvar cutaneous origin and those of anorectal and urothelial origin, with secondary vulvar spread [33]. Immunohistochemistry will help in the diagnosis.

Immunohistochemistry

The immunohistochemical characteristics of Paget cells in primary intraepithelial vulvar Paget disease are summarized in Table 1 together with the characteristics of normal skin [24, 29, 43, 46–53]. From these findings, intraepidermal Paget cells are proved to be differentiated mainly toward the ductal portion (CEA, II-7, B6.2 positivity), although in some instances partially toward the secretory portion of the sweat glands (GCDFP-15, CD15, PKK1 positivity). The question of whether Paget cells show apocrine differentiation is still controversial, but they do not show complete apocrine differentiation nor do they show eccrine differentiation.

Immunohistochemistry provides reliable assistance in the differential diagnosis of vulvar Paget disease against pagetoid melanoma using S100 (a calcium-binding protein), HMB45 (a melanoma-specific cytoplasmic antigen), and Melan-A as melanocytic markers [16, 54–56] and against vulvar squamous intraepithelial neoplasia as the panel of keratins expressed by Paget cells differs from the cells of adjacent epidermis [57]. In particular the strong immunoreactivity for keratins 7 and 19 facilitates the identification of small foci of intraepithelial and invasive vulvar Paget disease lesions [58–60].

Data from the literature underline that Paget cells in primary cutaneous vulvar Paget disease are for the most part immunoreactive for cytokeratin 7, CEA, and GCDFP-15 (Figure 5). Less frequently they are focally reactive for cytokeratin 20. This immunophenotype (CK 7⁺, CK 20^{-/+}, GCDFP 15⁺) assists in the distinction between primary vulvar Paget disease and less common pagetoid involvement of vulvar skin by a noncutaneous internal neoplasm. This distinction is of utmost clinical importance as therapeutic approaches and prognoses of these diseases are quite different, despite their similar clinical and routine histopathologic findings.

The most common cause of noncutaneous vulvar pagetoid involvement is perianal spread from an associated anorectal adenocarcinoma. These cases, different from primary vulvar Paget disease, typically express cytokeratin 20 and, at the same time, immunohistochemical reactions for GCDFP15 are negative [57, 60–72].

The second most common cause of noncutaneous Paget disease is related to direct extension or intraepithelial epidermotropic extension to the vulvar skin or

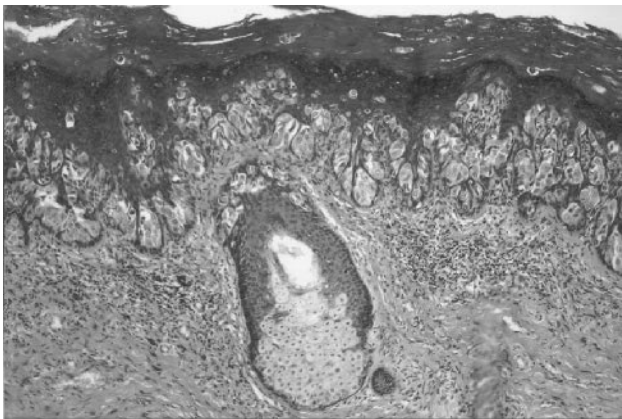


Figure 4. Histologic aspect of intraepithelial primary vulvar Paget disease: typical Paget's cells are present singly and clustered in nests throughout the whole thickness of the epidermis. The pale cytoplasm easily differentiates them from surrounding keratinocytes (hematoxylin and eosin, original magnification $\times 40$).

Table 1. Immunohistochemical Characteristics of Paget Cells in Primary Vulvar Intraepithelial Paget Disease and in Normal Skin

Reagent	Clone name	Paget cell	Apocrine secretory differentiation	Ecrrine secretory differentiation	Ductal differentiation	Sebaceous differentiation	Epidermal differentiation	Pretreatment
Anticarcinoembryonic antigen (CEA)	Polyclonal	++	+	+	+	–	–	
Anticarcinoembryonic antigen (CEA)	II-7	++	–	–	+	–	–	Microwave
Antibreast carcinoma associated antigen	B6.2	++	–	–	+	–	–	
Antihuman milk fat globules subclass 1 (HMFG-1)	HMFG 1	++	+	+	+	+	–	
Antihuman milk fat globules subclass 2 (HMFG-2)	HMFG 2	++	+	+	+	+	–	
Anti-BCA 225	CU18	++	+	+	+	+	–	
Antigross cystic disease fluid protein 15 (GCDFP-15)	D6	+	+	+	–	–	–	
Anti-CD 15	Leu M1	+	+	–	–	–	–	
Anti-epithelial membrane antigen (EMA)	E29	++	+	+	+	–	–	
Antilysozyme	Polyclonal	–	+	–	–	–	–	Protease
Antikeratin (K1)	34βB4	–	–	–	–	–	+Suprabasal	
Antikeratin (K8)	35βH11	+	+	+	+	–	–	Protease
Antikeratin (K19)	Ks19.1	++	+	+	+	–	–	Protease
Antikeratin	PKK1	+	+	+	–	–	+Basal	Protease
Antikeratin	KL1	++	+	+	+	–	+Suprabasal	
Antikeratin	AE1	++	+	+	+	–	+Basal	Protease
Anticytokeratin	LP34	–	–	–	+	–	+Suprabasal	Protease
Anti-Ca19.9	116-NS-19.9	–	–	+	+	–	–	Microwave
Anti Ca 15.3	DF3	++	+	+	+	+	–	Microwave

++, cells positive in 80–100% of the cases; +, cells positive in 10–80% of the cases; –, cells negative in almost all cases.

mucosa by urothelial neoplasia (Paget disease secondary to transitional cell carcinoma of the bladder or urethra, also referred to as pagetoid intraepithelial urothelial neoplasia) [33, 71, 73–76]. The cells of urothelial origin

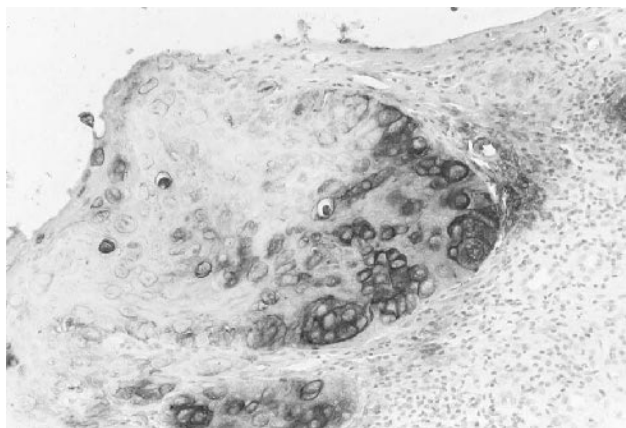


Figure 5. Immunohistochemical aspect of intraepithelial primary vulvar Paget disease: positive reaction for carcinoembryonic antigen in the cytoplasm of Paget cells but not in surrounding keratinocytes (immunoperoxidase stain, original magnification $\times 100$).

are not GCDFP-15 positive as are the Paget cells of primary cutaneous vulvar Paget disease, but they are immunoreactive for cytokeratin 7 and often for cytokeratin 20 and Uroplakin III like transitional cell carcinomas of the urinary tract [71, 77–80]. Immunoreactivity for Uroplakin III was not found in any cases of primary cutaneous vulvar disease [80].

Other cases of vulvar secondary involvement from adenocarcinoma of the cervix, endometrium, and ovary are described as single case reports.

Electron Microscopy

Electron microscopy shows that vulvar Paget disease cells differ markedly in structure from the keratinocytes of the surrounding epidermis, and cell cytoplasm appears more electron lucent. Two cell variants are present, secretory and nonsecretory, the former being more common with abundant secretory granules, well-developed Golgi complex, and profiles of endoplasmic reticulum. A small number of cells do not contain se-

cretory vacuoles and have scanty cytoplasmic organelles [29, 81]. Cells of invasive vulvar Paget disease show the same features as those of intraepithelial vulvar Paget disease, with fewer secretory granules. Small desmosomes, which attach Paget cells to each other and to adjacent keratinocytes, are absent in invasive neoplasms [41, 81]. These findings are consistent with the recent report of reduced expression of desmoglein I and plakoglobin (cell-cell adhesion molecules) in invasive vulvar Paget disease [82].

DNA Ploidy

The prognostic role of ploidy in vulvar Paget disease has been analyzed in four different series [59, 83–85]. Twenty-five of 59 cases of intraepithelial vulvar Paget disease (42%) were nondiploid and 8 of 21 invasive lesions (38%) were diploid. The recurrence rate was 26% (11/42) in diploid lesions and 31% (12/38) in nondiploid lesions. From these data we cannot infer a significant value of tumor DNA ploidy in predicting either recurrence or invasion.

Viruses, Oncogenes, and Tumor Markers

Some of the characteristics of vulvar Paget disease, such as multicentricity, a tendency to recur, and rare invasiveness, recall virus-associated epithelial atypia. No study has evidenced human papillomavirus (HPV) antigen or HPV DNA in the cells of vulvar Paget disease specimens [42, 86–89], so that the participation of HPV infection in the pathogenesis of the disease is unlikely. On the other hand neither p53 gene mutations nor loss of heterozygosity at selected loci were detected in Paget cells [89]. Immunohistochemical analyses for c-erb-B2 antigen [22, 30, 90], bcl2, and p53 protein expression [59, 84, 91, 92] have revealed conflicting and inconclusive results. The role of these oncogenes is still undetermined and without an actual role in indicating patients at greater risk of recurrence or invasive neoplasm. No data support the use of serum tumor markers SCC, LSA, and Ca 19–9 to predict disease occurrence or recurrence [93].

The underlying genetic defects in extramammary Paget disease are probably different from those in other epithelial malignancies. Further molecular genetic studies may help to cast light on the peculiar biological behavior of vulvar Paget disease.

VULVAR PAGET DISEASE PROPOSED SUBCLASSIFICATION

Wilkinson and Brown have applied data on histogenesis, histopathological, and immunohistochemical methods as well as clinical features to subclassify vulvar Paget disease into two main categories [33].

1. PRIMARY (of cutaneous origin) vulvar Paget disease is subclassified:
 - 1a) Paget disease as a primary intraepithelial neoplasm
 - 1b) Paget disease as an intraepithelial neoplasm with stromal invasion
 - 1c) Paget disease as a manifestation of an underlying primary adenocarcinoma of a skin appendage or a subcutaneous vulvar gland
2. SECONDARY vulvar Paget disease (involvement of the vulvar skin by a noncutaneous internal neoplasm) is subclassified in:
 - 2a) Paget disease secondary to anal or rectal adenocarcinoma
 - 2b) Paget disease secondary to urothelial neoplasia
 - 2c) Paget disease secondary to adenocarcinomas or related tumors of other sites

The following paragraphs will illustrate the clinical and pathological importance of distinction between the different vulvar Paget lesions.

VULVAR PAGET DISEASE AND INVASIVE NEOPLASMS

In the past decades there was considerable confusion about the relationship between vulvar Paget disease and associated malignancies. This term has been used to indicate: 1) the presence of dermal invasion; 2) association with underlying skin appendage invasive adenocarcinoma; and 3) association with carcinoma of adjacent structures (vulva-vagina), regional internal organ (colon-rectum, urinary tract), unrelated visceral organ (uterus, ovary, stomach), or carcinomas at a distant site (breast, lung) occurring before, contemporaneously, or after vulvar Paget disease diagnosis.

In Table 2 the studies where a distinction among the above-cited subgroups was feasible are reported [11, 13–15, 20, 23, 24, 35, 39–41, 59, 66, 67, 83–85, 93–105].

Table 2. Vulvar Paget Disease: Stromal Invasion, Association with Underlying Adenocarcinomas, and Other Carcinomas Reported in the Literature

Author	Ref.	y	No. of cases	No. cases with stromal invasion ^a		No. cases with underlying adenocarcinomas ^b		No. cases with other carcinomas ^c		Site ^d						
				%	%	%	%	Colon rectum	Urinary tract	Ovary	Uterus	Vulva vagina	Breast	Other		
Koss	[39]	1968	8	0	0	2	25	4	50		1		1	1	1	1
Fenn	[35]	1971	7	2	29	0	0	3	43	1	2				1	
Creasman	[94]	1975	15	0	0	5	33	4	27							
Taylor	[95]	1975	18	4	22	2	11	4	22			1	1	1	1	
Tsukada	[40]	1975	8	0	0	1	13	3	38						2	1
Lee	[41]	1977	13	1	8	3	23	4	31		1	1	1			1
Breen	[11]	1978	13	0	0	0	0	5	38				2	1	1	1
Stacy	[96]	1986	13	0	0	0	0	5	38	3					1	1
Bergen	[23]	1989	14	0	0	0	0	1	7						1	
Curtin	[97]	1990	36	1	3	5	14	9	25		1	1	2		4	3
Feuer	[20]	1990	19	2	11	1	5	6	32			1	2		2	2
Ewing	[98]	1991	6	0	0	1	17	0	0							
Olson	[24]	1991	16	6	38	3	19	1	6		1					
Garzetti	[99]	1992	4	1	25	0	0	0	0							
Helm	[100]	1992	21	0	0	2	10	5	24		5		1			
Molinie	[101]	1993	36	0	0	1	3	5	14	2	1		1		1	1
Baehrendtz	[102]	1994	28	3	11	0	0	6	21		1	1		1	1	2
Cotton	[83]	1995	14	2	14	2	14	3	21						2	1
Fishman	[93]	1995	14	1	7	2	14	7	50	1	1		1	1	2	1
Kodama	[14]	1995	30	9	30	11	37	2	7				1			1
Kohler	[66]	1996	19	0	0	0	0	2	11	2						
Tsai	[103]	1996	5	1	20	2	40	0	0							
Goldblum	[67]	1997	19	6	32	0	0	2	11		1				1	
Scheistrøen	[84]	1997	34	0	0	5	15	8	24		1		2	1	5	1
Tågsjö	[85]	1997	16	2	13	5	31	0	0							
Crawford	[59]	1999	21	10	48	0	0	8	38	1	2	1	3		2	1
Fanning	[13]	1999	100	12	12	4	4	20	20				4		6	16
Piura	[104]	1999	5	1	20	1	20	0	0							
Parker	[15]	2000	76	9	12	13	17	8	11		1	1	4		3	1
Zollo	[105]	2000	22	6	27	1	5	8	36	1			1		5	3
Total			650	79	12	72	11	133	20	11	19	7	27	6	42	38

^aAt diagnosis or during follow-up for intraepithelial disease.

^bVulvar Paget disease as a manifestation of an underlying primary adenocarcinoma of a skin appendage or a subcutaneous vulvar gland.

^cOccurring before, contemporaneously, or after vulvar Paget disease diagnosis.

^dMultiple sites in the same patients are reported, sites are not specified in some studies.

Primary Vulvar Paget Disease with Stromal Invasion

Dermal invasion may evolve from primary vulvar intraepithelial Paget disease over time. The subset of minimally invasive vulvar Paget disease (stromal invasion \leq 1 mm) [20, 104] represents direct histologic evidence that intraepithelial vulvar Paget disease has the potential to invade as intraepithelial and that invasive components are composed of the same cells with identical immunophenotype [59]. The development of invasive vulvar Paget disease is reported up to 10 years after initial treatment for intraepithelial vulvar Paget disease [20]. In most invasive vulvar Paget disease an extensive intraepithelial skin involvement (\geq 10 cm in diameter) is reported [13], and invasion does appear to develop in an undifferentiated area of intraepithelial disease [106].

The differing proportion of invasive vulvar Paget disease in the various series (from 0% to 48%) (Table 2) may reflect referral bias of cases more likely to be re-

ferred to tertiary centers. Furthermore the identification of invasive disease may be a result of more thorough histologic sampling of the tumor [59].

Vulvar Paget Disease as a Manifestation of Primary Underlying Adenocarcinoma of the Vulva

In mammary Paget disease almost all cases reflect the extension of malignant cells into the epidermis, via lactiferous ducts, from an underlying mammary carcinoma: the so-called epidermotropic metastasis [1]. This relationship is generally absent in vulvar Paget disease and association with invasive underlying adenocarcinoma is present in approximately 10% of cases (range = 0–40%) (Table 2). Selection bias in different series may result from the differing surgical procedures used. Wide vulvar excision may underestimate the presence of underlying adenocarcinoma with respect to total vulvectomy. A more reliable prevalence of concurrent adeno-

carcinoma (4%) may be reported from large series where all surgical procedures were included [13]. Furthermore some reports showing a high prevalence of underlying adenocarcinoma may have included cases of invasive vulvar Paget disease.

Primary underlying vulvar adenocarcinoma may originate from adenocarcinoma of the Bartholin gland, specialized anogenital glands, or other vulvar glandular structures. Underlying adenocarcinomas are usually clinically apparent. However, this is not invariable [20], and thus the underlying dermis, beneath the clinically visible Paget disease, should be removed for appropriate histologic evaluation.

Association with Other Neoplasms

Patients with vulvar Paget disease are also reported to be at increased risk of other primary neoplasms. The list of associated malignancies includes anal, rectal, colonic, endometrial, cervical ovarian and stomach adenocarcinoma, vaginal and vulvar squamous cell carcinoma, papillary transitional cell carcinoma of the renal pelvis, ureter, bladder and urethra, basal cell skin cancer, lung, breast, and thyroid carcinoma. The reported frequency of associated malignancy is highly variable by site, type, and temporal relationship, and it ranges from 0% to 50% (mean 20%) (Table 2). The prevalence of cancer in these elderly patients is not significantly different from published data for patients from their demographic group [107], and the association of vulvar Paget disease with cancer may be, for the most part, a secondary effect of the advanced age of these patients [13]. To truly evaluate whether the risk of another malignancy in women with Paget disease is increased, one would need to design a specific study to address this hypothesis. Moreover, the search for additional malignancy would have to be systematic, which it was not in most parts of the series examined.

It should be stressed that perianal or periurethral Paget disease may represent involvement of the vulvar skin by pagetoid extension of a regional neoplasm including anorectal adenocarcinoma or urothelial neoplasia. In these cases of secondary vulvar Paget disease immunohistochemical analysis demonstrates distinctive features.

A systemic work-up for an associated malignancy should be reserved for selected cases. An evaluation including colon-sigmoidoscopy, urethrocytostomy, chest roentgenogram, intravenous pyelogram, mammogram, cervicovaginal Pap smear, urine cytology, and CAT scan

[101] appears too extensive to be applied routinely to patients with only vulvar localization of Paget disease.

TREATMENT

Ideal therapy aims at minimal tissue destruction and low recurrence rate, but some features of vulvar Paget disease interfere with these goals. The treatment and prognosis are closely related to pathologic characteristics of the disease.

Primary Vulvar Intraepithelial Paget Disease

The treatment is wide and deep surgical excision as recommended by most authors [23, 25, 93, 108]. Wide local excision, including a peripheral margin of 1.5–2 cm of skin with normal appearance, is not always easy to achieve while preserving sexual function, normal anatomy, and body image, particularly for excision of lesions at the vaginal side near the urethral orifice. At the same time, deep resection of the lesion is mandatory. Not only the dermis but also all skin appendages that could potentially contain Paget cells should be resected. As no hair follicles or sweat glands extend more than 4.0 mm below the surface of the epidermis [23], excision deeper than this is not recommended. Complete inclusion of skin appendages and histologic examination to search for underlying neoplasms are two reasons that exclude laser vaporization as the sole treatment of vulvar Paget disease [98, 109, 110]. Recently photodynamic therapy [111] has been proposed as a primary treatment of vulvar Paget disease using topical 20% δ -aminolevulinic acid and Argon dye laser [105].

Primary Vulvar Paget Disease with Stromal Invasion

Most studies have reported that foci of superficial dermal invasion associated with predominantly intraepithelial vulvar Paget disease did not adversely affect prognosis [14, 20, 59, 67]. The rare reports of metastatic minimally invasive vulvar Paget disease probably describe un-sampled deeper foci of invasion [20, 104] and, up to now, a conservative approach in the treatment of minimally invasive vulvar Paget disease is recommended. It should be emphasized that in the literature there is no consensus for the method of measurement for depth of invasion in vulvar adenocarcinoma.

Vulvar Paget Disease as a Manifestation of an Underlying Primary Cutaneous Adenocarcinoma of the Vulva

These patients, as well as patients with stromal invasion exceeding 1 mm, should be treated with vulvar excision to the fascia of the clinically involved area and

bilateral inguinofemoral lymphadenectomy. The clinical course of these patients is much different from intraepithelial vulvar Paget disease. They recur soon after the initial treatment, frequently showing general metastases [14]. It is clear that surgical treatment alone is not enough for these patients because micrometastases seem to exist at the time of surgical excision [14, 94]. For these patients effective systemic therapy is indicated.

Vulvar Paget Disease as Involvement of the Vulvar Skin by a Noncutaneous Internal Neoplasm

In such cases therapy is directed toward treatment of the associated carcinoma, and vulvar Paget disease can be treated with a conservative approach like an intraepithelial lesion. The prognosis depends on the stage and prognostic factors of the associated adenocarcinoma.

Integrated Therapies

There are few data in the literature on radiotherapeutic or chemotherapeutic approaches to locally advanced, recurrent, or invasive vulvar Paget disease. The small

Table 3. Intraepithelial Vulvar Paget Disease and Local Recurrence after Therapy (not considered patients lost to follow-up or that refused primary treatment)

Author	Ref.	y	No. of cases	No. cases recurred	% Recurrences	No. cases dead of disease
Koss	[39]	1968	5	0	0	0
Fenn	[35]	1971	7	1	14	0
Taylor	[95]	1975	14	7	50	0
Tsukada	[40]	1975	7	1	14	0
Lee	[41]	1977	9	2	22	0
Breen	[11]	1978	13	2	15	0
Stacy	[96]	1986	13	1	8	0
Bergen	[23]	1989	14	3	21	0
Curtin	[97]	1990	28	6	21	0
Feuer	[20]	1990	15	8	53	0
Olson	[24]	1991	10	2	20	2 ^a
Garzetti	[99]	1992	4	1	25	0
Molinie	[101]	1993	29	11	38	0
Baehrendtz	[102]	1994	21	11	52	3 ^a
Cotton	[83]	1995	10	3	30	0
Fishman	[93]	1995	14	5	36	0
Kodama	[14]	1995	10	3	30	0
Kohler	[66]	1996	14	9	64	0
Tsai	[103]	1996	2	0	0	0
Goldblum	[67]	1997	14	4	29	1 ^a
Scheistrøen	[84]	1997	29	8	28	0
Tågsjö	[85]	1997	10	4	40	0
Crawford	[59]	1999	11	5	45	0
Fanning	[13]	1999	84	30	36	0
Piura	[104]	1999	3	1	33	0
Parker	[15]	2000	44	16	36	0
Zollo	[105]	2000	15	5	33	0
Louis-Sylvestre	[110]	2001	49	22	45	0
Total			498	171	34	6 ^a

^aPatients progressed to invasive adenocarcinoma during follow-up for intraepithelial vulvar Paget disease.

Table 4. Vulvar Paget Disease with Stromal Invasion or Associated with Underlying Invasive Adenocarcinoma and Local Recurrence after Therapy (not considered patients lost to follow-up or that refused primary treatment)

Author	Ref.	y	No. of cases	No. cases recurred	% Recurrences	No. cases dead of disease	% Dead of disease
Koss	[39]	1968	2	2	100	0	0
Parmley	[106]	1975	7	5	71	5	71
Taylor	[95]	1975	4	4	100	4	100
Lee	[41]	1977	4	1	25	0	0
Curtin	[97]	1990	5	3	60	2	40
Feuer	[20]	1990	2	1	50	1	50
Olson	[24]	1991	6	3	50	1	17
Baehrendtz	[102]	1994	3	3	100	3	100
Cotton	[83]	1995	4	1	25	0	0
Kodama	[14]	1995	20	10	50	7	35
Tsai	[103]	1996	2	1	50	1	50
Goldblum	[67]	1997	5	1	20	0	0
Scheistrøen	[84]	1997	5	3	60	3	60
Tågsjö	[85]	1997	6	3	50	2	33
Crawford	[59]	1999	10	3	30	1	10
Fanning	[13]	1999	16	4	25	0	0
Piura	[104]	1999	2	1	50	0	0
Parker	[15]	2000	22	13	59	1	5
Zollo	[105]	2000	5	3	60	0	0
Total			130	65	50	31	24

number of patients treated with chemotherapy (topical bleomycin, mitomycin-C, 5-fluorouracil, cyclophosphamide, doxorubicin, cisplatin, carboplatin, vincristine) as yet allows for no final conclusions about the regimens proposed [14, 112]. Clear inclusion criteria and adequate follow-up time are required to clarify the role of radiation therapy for patients who are not surgical candidates [113–115]. The clinical evidence does not support the use of chemotherapy and radiotherapy for patients with intraepithelial vulvar Paget disease not associated with invasive carcinoma.

A recent study demonstrated that vulvar Paget disease cells express androgen receptors rather than estrogen or progesterone receptors [116]. Further studies are needed to determine whether androgen receptor status could aid in the therapy of recurrent and invasive vulvar Paget disease.

Margin Control

In primary vulvar Paget disease the clinical visible borders do not completely define the histologically involved area. Therefore a balance between the extent of surgical resection and the probability of leaving Paget cells in the remaining vulvar tissue is difficult to determine. Various types of margin controls have been proposed to reduce local recurrence, including colposcopic

cally directed multiple biopsies, intraoperative intravenous fluorescein with ultraviolet light scanning, and frozen section. All of these techniques have been reported as successful methods and all have limitations [19, 21, 96, 117, 118]. A false-negative rate of approximately 35% in delineating surgical margins is reported for both frozen sections and visual observation [93] because of the presence of irregular boundaries and skip lesions [19, 96]. There is, however, no evidence that intraoperative frozen section margin assessment reduces recurrence or improves survival [93]. Even antibodies to carcinoembryonic antigen, epithelial membrane antigen, and low molecular weight cytokeratins, used to improve Paget cell detection sensitivity, add no value in identifying Paget cells in resection margins that are negative on routine hematoxylin and eosin staining [119].

Recurrences

The difficulty in defining the margins of vulvar Paget disease lesion extension is closely related to the problem of recurrences: an apparently complete excision of intraepithelial vulvar Paget disease is followed by recurrences, even in skin grafts used to cover the wound after vulvectomy [120]. Patients with recurrent disease are characterized by multiple recurrences [97]. Almost half of the recurrences appear within 18 months from initial treatment [102] with a range from a few months to more than 15 years [13, 15, 83, 101].

Difficulties in comparing reports arise from the different types of surgical procedures performed and from the state of operative margins, which are often not detailed. The recurrence rate of 15–20% in cases with negative margins increases to 50% or more if surgical margins are involved. Furthermore the mean time to recurrence for patients with negative margins is longer than for those with positive margins [14, 15, 59, 93, 101]. The surgical resection of visibly involved skin and mucosa, with visibly normal skin margins of resection, without frozen section assessment, is a reasonable and effective approach to vulvar cutaneous Paget disease [93]. As the frequency of local recurrence is strongly correlated with the presence of invasive disease [15] we reported in separate tables intraepithelial (Table 3) [11, 13–15, 20, 23, 24, 35, 39–41, 59, 66, 67, 83–85, 93, 95–97, 99, 101–105, 110] and invasive (Table 4) [13–15, 20, 24, 39, 41, 59, 67, 83–85, 95, 97, 102–106] vulvar Paget disease series.

Because most recurrences of intraepithelial vulvar Paget disease consist entirely of intraepidermal disease,

which does not affect survival [7], and the extent of the initial operation does not correlate with disease recurrence, conservative local excision for intraepithelial lesions is a reasonable consideration in young and old patients.

CONCLUSION

The use of biopsies for any unclear vulvar abnormality gives valuable information at a reasonable cost and prevents delay of diagnosis. When diagnostic difficulty occurs, immunohistochemical studies can be used. The recently proposed vulvar Paget disease subclassification will contribute to the correct diagnosis and appropriate treatment for affected patients. Prognosis is closely related to pathologic characteristics of the disease. Additional molecular genetic studies are needed to better understand the biological behavior of vulvar Paget disease.

Acknowledgments

The authors thank Professor Rainer Kürzl (Department of Gynecology and Pathology, Frauenklinik University of Munich, Germany) for critical revision of the first version of the manuscript and Doctor Sebastiana Privitera (Department of Pathology, St. Anna Hospital, Turin, Italy) for providing histologic photographs.

REFERENCES

1. Heymann WR. Extramammary Paget's disease. *Clin Dermatol* 1993;11:83–7.
2. Paget J. On disease of the mammary areola, preceding cancer of the mammary gland. *St Bartholomew's Hosp Rep* 1874;10:87–9.
3. Crocker HR. Paget's disease affecting the scrotum and the penis. *Trans Pathol Soc London* 1888;40:187–91.
4. Darier J, Couillaud P. Sur un cas de maladie de Paget de la region perineo-anale et scrotale. *Ann Dermatol Syphiligr (Paris)* 1893;4:25–31.
5. Dubreuilh W. Paget's disease of the vulva. *Br J Dermatol* 1901;13:407–13.
6. Saida T, Iwata M. "Ectopic" extramammary Paget's disease affecting the lower anterior aspect of the chest. *J Am Acad Dermatol* 1987;17:910–3.
7. Balducci L, Crawford ED, Smith GF, Lambuth B, McGehee R, Hardy C. Extramammary Paget's disease: an annotated review. *Cancer Invest* 1988;6:293–303.
8. Farrell AM, Charnock FM, Millard PR, Wojnarowska F. Paget's disease of the vulva associated with local adenocarcinoma and previous breast adenocarcinoma: report of two cases. *Br J Dermatol* 1999;141:146–9.
9. Wilkinson EJ, Kneale BL, Lynch PJ. Report of the

- ISSVD Terminology Committee. *J Reprod Med* 1986;31:973-4.
10. Ferenczy A. Intraepithelial Neoplasia of the Vulva. In: Copleson M, Monaghan JM, Morrow CP, Tattersall MHN, eds. *Gynecologic Oncology, Fundamental Principles and Clinical Practice*. 2nd ed. London: Churchill Livingstone; 1992:443.
 11. Breen JL, Smith CI, Gregori CA. Extramammary Paget's disease. *Clin Obstet Gynecol* 1978;21:1107-15.
 12. Jones RE Jr, Austin C, Ackerman AB. Extramammary Paget's disease. A critical reexamination. *Am J Dermatopathol* 1979;1:101-32.
 13. Fanning J, Lambert L, Hale TM, Morris PC, Schuerch C. Paget's disease of the vulva: prevalence of associated vulvar carcinoma, invasive Paget's disease, and recurrence after surgical excision. *Am J Obstet Gynecol* 1999;180:24-7.
 14. Kodama S, Kaneko T, Saito M, Yoshiya N, Honma S, Tanaka K. A clinicopathologic study of 30 patients with Paget's disease of the vulva. *Gynecol Oncol* 1995;56:63-70.
 15. Parker LP, Parker JR, Bodurka-Bevers D, Deavers M, Bevers MW, Shen-Gunther J, et al. Paget's disease of the vulva: pathology, pattern of involvement, and prognosis. *Gynecol Oncol* 2000;77:183-9.
 16. Chiba H, Kazama T, Takenouchi T, Nomoto S, Tago O, Ito M. Two cases of vulvar pigmented extramammary Paget's disease: histochemical and immunohistochemical studies. *Br J Dermatol* 2000;142:1190-4.
 17. Helwig EB, Graham JH. Anogenital (extramammary) Paget's disease. A clinicopathological study. *Cancer* 1963;16:387-403.
 18. Friedrich EG Jr. Management of neoplasia. In: Friedrich EG Jr, ed. *Vulvar Disease*. 2nd ed. Philadelphia: WB Saunders Company; 1983:95-8.
 19. Gunn RA, Gallager HS. Vulvar Paget's disease: a topographic study. *Cancer* 1980;46:590-4.
 20. Feuer GA, Shevchuk M, Calanog A. Vulvar Paget's disease: the need to exclude an invasive lesion. *Gynecol Oncol* 1990;38:81-9.
 21. Coldiron BM, Goldsmith BA, Robinson JK. Surgical treatment of extramammary Paget's disease. A report of six cases and a reexamination of Mohs micrographic surgery compared with conventional surgical excision. *Cancer* 1991;67:933-8.
 22. Wolber RA, Dupuis BA, Wick MR. Expression of c-erbB-2 oncoprotein in mammary and extramammary Paget's disease. *Am J Clin Pathol* 1991;96:243-7.
 23. Bergen S, DiSaia PJ, Liao SY, Berman ML. Conservative management of extramammary Paget's disease of the vulva. *Gynecol Oncol* 1989;33:151-6.
 24. Olson DJ, Fujimura M, Swanson P, Takashi O. Immunohistochemical features of Paget's disease of the vulva with and without adenocarcinoma. *Int J Gynecol Pathol* 1991;10:285-95.
 25. Kürzl RG. Paget's disease. *Semin Dermatol* 1996;15:60-6.
 26. Woodruff JD, Williams TF. The DOPA reaction in Paget's disease of the vulva. *Obstet Gynecol* 1959;14:86-90.
 27. Kaufman RH, Boice EH, Knight WR. Paget's disease of the vulva. *Am J Obstet Gynecol* 1960;79:451-4.
 28. Stenn KS. The skin. In: Weiss L, ed. *Cell and Tissue Biology: A Textbook of Histology*. 6th ed. Baltimore: Urban & Schwarzenberg; 1988:541-72.
 29. Roth LM, Lee SC, Ehrlich CE. Paget's disease of the vulva. A histogenetic study of five cases including ultrastructural observations and review of the literature. *Am J Surg Pathol* 1977;1:193-206.
 30. Keatings L, Sinclair J, Wright C, Corbett IP, Watchorn C, Hennessy C, et al. c-erbB-2 oncoprotein expression in mammary and extramammary Paget's disease: an immunohistochemical study. *Histopathology* 1990;17:243-7.
 31. Urabe A, Matsukuma A, Shimizu N, Nishimura M, Wada H, Hori Y. Extramammary Paget's disease: comparative histopathologic studies of intraductal carcinoma of the breast and apocrine adenocarcinoma. *J Cutan Pathol* 1990;17:257-65.
 32. Van der Putte SC. Mammary-like glands of the vulva and their disorders. *Int J Gynecol Pathol* 1994;13:150-60.
 33. Wilkinson EJ, Brown HM. Vulvar Paget disease of urothelial origin: a report of three cases and a proposed classification of vulvar Paget disease. *Hum Pathol* 2002;33:549-54.
 34. Fu YS, Reagan JW. Benign and malignant epithelial tumors of the vulva. In: Fu YS, Reagan JW, Bennington JL, eds. *Pathology of the Uterine Cervix, Vagina, and Vulva*. Philadelphia: WB Saunders Company; 1989:158-66.
 35. Fenn ME, Morley GW, Abell MR. Paget's disease of vulva. *Obstet Gynecol* 1971;38:660-70.
 36. Belcher RW. Extramammary Paget's disease. Enzyme histochemical and electron microscopic study. *Arch Pathol* 1972;94:59-64.
 37. Lever WF, Schaumburg-Lever G. Tumors and cysts of the epidermis. In: Lever WF, Schaumburg-Lever G, eds. *Histopathology of the Skin*. 7th ed. Philadelphia: JB Lippincott; 1990:523-77.
 38. Wilkinson EJ. Premalignant and malignant tumors of the vulva. In: Kurman RJ, ed. *Blaustein's Pathology of the Female Genital Tract*. 4th ed. New York: Springer-Verlag; 1994:87-129.
 39. Koss LG, Ladinsky L, Brokunier A. Paget's disease of the vulva: report of 10 cases. *Obstet Gynecol* 1968;31:513-20.
 40. Tsukada Y, Lopez RG, Pickren JW, Piver MS, Barlow JJ. Paget's disease of the vulva: a clinicopathologic study of eight cases. *Obstet Gynecol* 1975;45:73-8.
 41. Lee SC, Roth LM, Ehrlich C, Hall JA. Extramammary Paget's disease of the vulva. A clinicopathologic study of 13 cases. *Cancer* 1977;39:2540-9.

42. Brainard JA, Hart WR. Proliferative epidermal lesions associated with anogenital Paget's disease. *Am J Surg Pathol* 2000;24:543-52.
43. Reed W, Oppendal BF, Eeg Larsen T. Immunohistology is valuable in distinguishing between Paget's disease, Bowen's disease, and superficial spreading malignant melanoma. *Histopathology* 1990;16:583-8.
44. Kohler S, Rouse RV, Smoller BR. The differential diagnosis of pagetoid cells in the epidermis. *Mod Pathol* 1998; 11:79-92.
45. Williamson JD, Colome MI, Sahin A, Ayala Ag, Me-deiros LJ. Pagetoid Bowen disease. A report of 2 cases that express cytokeratin 7. *Arch Pathol Lab Med* 2000;124: 427-30.
46. Guarner J, Cihen C, De Rose PB. Histogenesis of extramammary and mammary Paget cell. An immunohistochemical study. *Am J Dermatopathol* 1989;11:313-8.
47. Ansai S. Immunohistochemical studies of normal sweat glands, sweat gland tumors and extramammary Paget's disease. I. Immunohistochemical studies of normal sweat glands. *Nippon Hifuka Gakkai Zasshi* 1990;100:121-32. Japanese.
48. Ansai S. Immunohistochemical studies of normal sweat glands, sweat gland tumors and extramammary Paget's diseases. II. Immunohistochemical studies of sweat gland tumors and extramammary Paget's diseases. *Nippon Hifuka Gakkai Zasshi* 1990;100:133-46. Japanese.
49. Ansai S, Katagata Y, Yoshikawa KI, Hozumi Y, Aso K. Keratin specificity analyses of eight anti-keratin monoclonal antibodies, and their immunostaining patterns in normal skin using formalin-fixed and paraffin-embedded tissue specimens. *Arch Dermatol Res* 1993;285:6-12.
50. Ansai S, Katagata Y, Yoshikawa K, Hashimoto H, Hozumi Y, Kondo S, et al. An immunohistochemical study of sebaceous carcinoma with anti-keratin monoclonal antibodies: comparison with other skin cancers. *J Dermatol* 1994;21: 553-9.
51. Ansai S, Koseki S, Hozumi Y, Kondo S. An immunohistochemical study of lysozyme, CD-15 (Leu M1), and gross cystic disease fluid protein-15 in various skin tumors. Assessment of the specificity and sensitivity of markers of apocrine differentiation. *Am J Dermatopathol* 1995;17:249-55.
52. Demirkesen C, Hoede N, Moll R. Epithelial markers and differentiation in adnexal neoplasms of the skin: an immunohistochemical study including individual cytokeratins. *J Cutan Pathol* 1995;22:518-35.
53. Tsuji T. Mammary and extramammary Paget's disease: expression of Ca 15-3, Ka-93, Ca 19-9 and CD44 in Paget cells and adjacent normal skin. *Br J Dermatol* 1995;132: 7-13.
54. Rosen L, Amazon K, Frank B. Bowen's disease, Paget's disease, and malignant melanoma in situ. *South Med J* 1986;79:410-3.
55. Bacchi CE, Goldfogel GA, Greer BE, Gown AM. Paget's disease and melanoma of the vulva. Use of a panel of monoclonal antibodies to identify cell type and to microscopically define adequacy of surgical margins. *Gynecol Oncol* 1992;46:216-21.
56. Ramachandra S, Gillett CE, Millis RR. A comparative immunohistochemical study of mammary and extramammary Paget's disease and superficial spreading melanoma, with particular emphasis on melanocytic markers. *Virchows Arch* 1996;429:371-6.
57. Battles OE, Page DL, Johnson JE. Cytokeratins, CEA, and mucin histochemistry in the diagnosis and characterization of extramammary Paget's disease. *Am J Clin Pathol* 1997; 108:6-12.
58. Smith KJ, Tuur S, Corvette D, Lupton GP, Skelton HG. Cytokeratin 7 staining in mammary and extramammary Paget's disease. *Mod Pathol* 1997;10:1069-74.
59. Crawford D, Nimmo M, Clement PB, Thomson T, Benedet JL, Miller D, et al. Prognostic factors in Paget's disease of the vulva: a study of 21 cases. *Int J Gynecol Pathol* 1999;18:351-9.
60. Lundquist K, Kohler S, Rouse RV. Intraepidermal cytokeratin 7 expression is not restricted to Paget cells but is also seen in Toker cells and in Merkel cells. *Am J Surg Pathol* 1999;23:212-9.
61. Mazoujian G, Pinkus G, Haagensen DE. Extramammary Paget's disease-evidence for an apocrine origin: an immunoperoxidase study of gross cystic disease fluid protein-15, carcinoembryonic antigen and keratin proteins. *Am J Surg Pathol* 1984;8:43-50.
62. Jensen SL, Sjølin KE, Shokouh-Amiri MH, Hagen K, Harling H. Paget's disease of the anal margin. *Br J Surg* 1988; 75:1089-92.
63. Armitage NC, Jass JR, Richman PI, Thomson JPS, Phillips RKS. Paget's disease of the anus: a clinicopathological study. *Br J Surg* 1989;76:60-3.
64. Miettinen M. Keratin 20: immunohistochemical marker for gastrointestinal, urothelial and Merkel cell carcinomas. *Mod Pathol* 1995;8:384-8.
65. Ormsby AH, Snow JL, Su WPD, Goeller JR. Diagnostic immunohistochemistry of cutaneous metastatic breast carcinoma: a statistical analysis of the utility of gross cystic disease fluid protein-15 and estrogen receptor proteins. *J Am Acad Dermatol* 1995;32:711-6.
66. Kohler S, Smoller BR. Gross cystic disease fluid protein-15 reactivity in extramammary Paget's disease with and without associated internal malignancy. *Am J Dermatopathol* 1996;18:118-23.
67. Goldblum JR, Hart WR. Vulvar Paget's disease: a clinicopathologic and immunohistochemical study of 19 cases. *Am J Surg Pathol* 1997;21:1178-87.
68. Goldblum JR, Hart WR. Perineal Paget's disease. A histologic and immunohistochemical study of 11 cases with and without associated rectal adenocarcinoma. *Am J Surg Pathol* 1998;22:170-9.

69. Nowak MA, Guerriere-Kovach P, Pathan A, Campbell TE, Deppisch LM. Perianal Paget's disease. Distinguishing primary and secondary lesions using immunohistochemical studies including gross cystic disease fluid protein-15 and cytokeratin 20 expression. *Arch Pathol Lab Med* 1998;122:1077-81.
70. Scott MP, Helm KF. Cytokeratin 20: a marker for diagnosing Merkel cell carcinoma. *Am J Dermatopathol* 1999; 21:16-20.
71. Onishi T, Watanabe S. The use of cytokeratin 7 and 20 in the diagnosis of primary and secondary extramammary Paget's disease. *Br J Dermatol* 2000;142:243-7.
72. Ramalingam P, Hart WR, Goldblum JR. Cytokeratin subset immunostaining in rectal adenocarcinoma and normal anal glands. *Arch Pathol Lab Med* 2001;125:1074-7.
73. Powell FC, Bjornsson J, Doyle JA, Cooper AF. Genital Paget's disease and urinary tract malignancy. *J Am Acad Dermatol* 1985;13:84-90.
74. Fukutani K, Kawabe K, Nijima T, Oohara-K. Transitional cell carcinoma of the urinary tract associated with vulvar Paget's disease: a report of two cases. *Urol Int* 1987; 42:71-3.
75. Orozco RE, Vander Zwaag R, Murphy WM. The pagetoid variant of urothelial carcinoma in situ. *Hum Pathol* 1993;24:1199-202.
76. Boardman CH, Webb MJ, Chevillie JC, Lerner SE, Zinke H. Transitional cell carcinoma of the bladder mimicking recurrent Paget's disease of the vulva: report of two cases, with one occurring in a myocutaneous flap. *Gynecol Oncol* 2001;82:200-4.
77. Moll R, Wu XR, Lin JH, Sun TT. Uroplakins, specific membrane proteins of urothelial umbrella cells, as histological markers of metastatic transitional cell carcinomas. *Am J Pathol* 1995;147:1383-97.
78. Harnden P, Eardley I, Joyce AD, Southgate J. Cytokeratin 20 as an objective marker of urothelial dysplasia. *Br J Urol* 1996;78:870-5.
79. Kaufman O, Volmerig J, Dietel M. Uroplakin III is a highly specific and moderately sensitive immunohistochemical marker for primary and metastatic urothelial carcinomas. *Am J Clin Pathol* 2000;113:683-7.
80. Brown HN, Wilkinson EJ. Uroplakin-III to distinguish primary vulvar Paget disease from Paget disease secondary to urothelial carcinoma. *Hum Pathol* 2002;33:545-8.
81. Koss LG, Brockunier A Jr. Ultrastructural aspects of Paget's disease of the vulva. *Arch Pathol* 1969;87:592-600.
82. Tada H, Hatoko M, Tanaka A, Kuwahara A, Muramatsu T. Expression of desmoglein and plakoglobin in skin carcinomas. *J Cutan Pathol* 2000;27:24-9.
83. Cotton J, Kotylo PK, Michael H, Roth LM, Sutton GP. Flow cytometric DNA analysis of extramammary Paget's disease of the vulva. *Int J Gynecol Pathol* 1995;14:324-30.
84. Scheistrøen M, Tropé C, Kærn J, Pettersen EO, Alfseu GC, Nesland JM. DNA ploidy and expression of p53 and c-erbB-2 in extramammary Paget's disease of the vulva. *Gynecol Oncol* 1997;64:88-92.
85. Tägsjö EB, Schmidt H, Malmström H, Simonsen E. Extramammary Paget's disease of the vulva. *Eur J Gynaecol Oncol* 1997;18:61-2.
86. Bornstein J, Kaufman RH, Adam E, Burek J, Adler-Storh K. Paget's disease of the vulva: search for herpes simplex virus antigens and human papillomavirus antigen and DNA. *Gynecol Oncol* 1988;31:384-8.
87. Snow SN, Desouky S, Lo JS, Kurtycz D. Failure to detect human papillomavirus DNA in extramammary Paget's disease. *Cancer* 1992;69:249-51.
88. Taddei GL, Moncini D, Cattaneo A, Carli P, Baroni G. Extra-mammary Paget's disease. An HPV-correlated neoplasia? *Pathologica* 1993;85:645-8.
89. Takata M, Hatta N, Takehara K. Tumor cells of extramammary Paget's disease do not show either p53 mutation or allelic loss at several selected loci implicated in other cancers. *Br J Cancer* 1997;76:904-8.
90. Takata M, Fujimoto A, Aoki H, Hatta N, Ooi A, Takehara K. ErbB-2 overexpression but no activation of β -catenin gene in extramammary Paget's disease. *J Invest Dermatol* 1999;113:258-62.
91. Kanitakis J, Thivolet J, Claudy A. p53 protein expression in mammary and extramammary Paget's disease. *Anticancer Res* 1993;13:2429-33.
92. Wienecke R, Eckert F, Kaudewitz P, de Viragh PA, Heidl G, Volkenandt M. p53 protein in benign and malignant sweat gland tumors. *Am J Dermatopathol* 1994;16:126-9.
93. Fishman DA, Chambers SK, Schwartz PE, Kohorn EI, Chambers JT. Extramammary Paget's disease of the vulva. *Gynecol Oncol* 1995;56:266-70.
94. Creasman WT, Gallager HS, Rutledge F. Paget's disease of the vulva. *Gynecol Oncol* 1975;3:133-48.
95. Taylor PT, Stenwig JT, Klausen H. Paget's disease of the vulva. *Gynecol Oncol* 1975;3:46-60.
96. Stacy D, Burrell MO, Franklin EW III. Extramammary Paget's disease of the vulva and anus: use of intraoperative frozen-section margins. *Am J Obstet Gynecol* 1986;155: 519-23.
97. Curtin JP, Rubin SC, Jones WB, Hoskins WJ, Lewis JL. Paget's disease of the vulva. *Gynecol Oncol* 1990;39: 374-7.
98. Ewing TL. Paget's disease of the vulva treated by combined surgery and laser. *Gynecol Oncol* 1991;43:137-40.
99. Garzetti GG, Bertani A, Tranquilli AL, Tiriduzzi M, Valensise H, Romanini C. Paget's disease of the vulva: advantages of demolitive surgery. *Eur J Gynaecol Oncol* 1992;13: 74-7.
100. Helm KF, Goellner JR, Peters MS. Immunohistochemical stains in extramammary Paget's disease. *Am J Dermatopathol* 1992;14:402-7.
101. Molinie V, Paniel BJ, Lessana-Leibowitch M, Moyal-

- Barracco M, Pelisse M, Escande JP. Maladie de Paget vulvaire: 36 cas. *Ann Dermatol Venereol* 1993;120:522-7.
102. Baehrendtz H, Einhorn N, Pettersson F, Silfverswärd C. Paget's disease of the vulva: the Radiumhemmet series 1975-1990. *Int J Gynecol Cancer* 1994;4:1-6.
103. Tsai CW, Lin HH, Chang DY, Huang SC. Paget's disease of the vulva: report of five cases. *Acta Obstet Gynecol Scand* 1996;75:946-9.
104. Piura B, Rabinovich A, Dgani R. Extramammary Paget's disease of the vulva: report of five cases and review of the literature. *Eur J Gynecol Oncol* 1999;20:98-101.
105. Zollo JD, Zeitouni NC. The Roswell Park Cancer Institute experience with extramammary Paget's disease. *Br J Dermatol* 2000;142:59-65.
106. Parmley TH, Woodruff JD, Julian CG. Invasive vulvar Paget's disease. *Obstet Gynecol* 1975;46:341-6.
107. Landis SH, Murray T, Bolden S, Wingo PA. Cancer statistics 1998. *CA Cancer J Clin* 1998;48:6-29.
108. Homesley HD. Management of vulvar cancer. *Cancer* 1995;76:2159-70.
109. Reid R. Superficial laser vulvectomy III. A new surgical technique for appendage-conserving ablation of refractory condylomas and vulvar intraepithelial neoplasia. *Am J Obstet Gynecol* 1985;152:504-9.
110. Louis-Sylvestre C, Haddad B, Paniel BJ. Paget's disease of the vulva: results of different conservative treatments. *Eur J Obstet Gynecol Reprod Biol* 2001;99:253-5.
111. Gannon MJ, Brown SB. Photodynamic therapy and its applications in gynecology. *Br J Obstet Gynecol* 1999;106:1246-54.
112. Watring WG, Roberts JA, Lagasse LD, Berman ML, Ballon SC, Moore JC, et al. Treatment of recurrent Paget's disease of the vulva with topical bleomycin. *Cancer* 1978;41:10-1.
113. Brierley JD, Stockdale AD. Radiotherapy: an effective treatment for extramammary Paget's disease. *Clin Oncol* 1991;3:3-5.
114. Besa P, Rich TA, Delclos L, Edwards CL, Ota DM, Wharton JT. Extramammary Paget's disease of the perineal skin: role of radiotherapy. *Int J Radiat Oncol Biol Phys* 1992;24:73-8.
115. Burrows NP, Jones DH, Hudson PM, Pye RJ. Treatment of extramammary Paget's disease by radiotherapy. *Br J Dermatol* 1995;132:970-2.
116. Diaz de Leon ED, Carcangiu ML, Prieto VG, McCue PA, Burchette JL, To G, et al. Extramammary Paget disease is characterized by the consistent lack of estrogen and progesterone receptors but frequently expresses androgen receptor. *Am J Clin Pathol* 2000;113:572-5.
117. Shelley WB. Mohs: microscopically oriented histographic surgery. *Arch Dermatol* 1978;114:1097-8.
118. Misas JE, Cold CJ, Hall FW. Vulvar Paget's disease: fluorescein-aided visualization of margins. *Obstet Gynecol* 1991;77:156-9.
119. Ganjei P, Giraldo KA, Lampe B, Nadji M. Vulvar Paget's disease. Is immunocytochemistry helpful in assessing the surgical margins? *J Reprod Med* 1990;35:1002-4.
120. DiSaia PJ, Dorion GE, Cappuccini F, Carpenter PM. A report of two cases of recurrent Paget's disease of the vulva in a split-thickness graft and its possible pathogenesis-labeled "retrodissemination". *Gynecol Oncol* 1995;57:109-12.