

AperTO - Archivio Istituzionale Open Access dell'Università di Torino

**Pasteurized tumoral autograft as a novel procedure for limb sparing in the dog: A clinical report.**

**This is the author's manuscript**

*Original Citation:*

*Availability:*

This version is available <http://hdl.handle.net/2318/53080> since

*Terms of use:*

Open Access

Anyone can freely access the full text of works made available as "Open Access". Works made available under a Creative Commons license can be used according to the terms and conditions of said license. Use of all other works requires consent of the right holder (author or publisher) if not exempted from copyright protection by the applicable law.

(Article begins on next page)

# Pasteurized Tumoral Autograft as a Novel Procedure for Limb Sparing in the Dog: A Clinical Report

PAOLO BURACCO, DVM, Diplomate ECVS, EMANUELA MORELLO, PhD, MARINA MARTANO, PhD, and MARIA ELISABETTA VASCONI, DVM

**Objective**—To evaluate use of a pasteurized tumoral autograft prepared from the resected primary bone neoplasm for limb sparing in a dog with distal radial osteosarcoma (OSA).

**Study Design**—Clinical case report.

**Animals**—A 9-year-old male Maremma shepherd dog.

**Methods**—After right distal radial OSA removal, the tumoral autograft was pasteurized. The excised bone segment was placed in a sterile watertight box containing sterile saline solution preheated to 65°C in a water bath. The box was kept immersed in the water bath at 65°C for 40 minutes to kill the tumor cells. The autograft was then fixed in the host with a plate and screws based on standard AO/ASIF technique for carpal arthrodesis. Three doses of cisplatin (70 mg/m<sup>2</sup> intravenously) were administered, 3 weeks apart; the initial dose was administered the day after surgery.

**Results**—The autograft was incorporated in a manner comparable to an allograft, and after 708 days, the metallic implants were removed. A 1-month activity restriction as well as spoon splint to protect the leg from a full loading were used thereafter. Limb function was fair to good, and the dog remains disease free after 56 months.

**Conclusions**—A pasteurized autograft consisting of the resected primary bone neoplasm is a valid alternative to a cortical bone allograft for limb sparing in dogs with appendicular OSA in terms of feasibility and pattern of healing.

**Clinical Relevance**—This procedure can be an alternative method of limb sparing when difficulties are encountered in establishing and maintaining a canine bone allograft bank.

© Copyright 2002 by The American College of Veterinary Surgeons

**O**STEOSARCOMA (OSA) is the most common canine bone tumor (85%) and represents 3% to 4% of all canine tumors.<sup>1</sup> It is more prevalent in giant and large dogs, with a median age of 7 years.<sup>2</sup> It can develop anywhere in the skeleton, but the preferential location is the metaphysis of long bones (75%), in particular the distal radius.<sup>3</sup> Approximately 10% of dogs have radiologic evidence of lung metastasis at the time of presentation, but up to 90% of dogs may already have micrometastasis.<sup>3</sup> Therefore, treatment should be aggressive and addressing both control of the local disease and the systemic metastasis. Current

treatment protocols are based on a combination of radical surgery (limb amputation or limb salvage) and adjuvant chemotherapy.<sup>3</sup> We report a limb-sparing procedure where the excised neoplastic bone was used after pasteurization as an autograft instead of using a banked cortical bone allograft.

## MATERIALS AND METHODS

A 9-year-old male Maremma shepherd dog (48 kg) was admitted with a 2-month history of right foreleg lameness. Other than swelling of the right distal radius/carpus region,

From the Department of Animal Pathology, School of Veterinary Medicine, Turin, Italy.

Presented in part at the 18th Annual Conference of the Veterinary Cancer Society, Estes Park, CO, October, 1998.

Address reprint requests to Paolo Buracco, DVM, Dipartimento di Patologia Animale, School of Veterinary Medicine, Via Leonardo da Vinci 44, 10095 Grugliasco, Turin, Italy.

© Copyright 2002 by The American College of Veterinary Surgeons

0161-3499/02/3106-0004\$35.00/0

doi:10.1053/jvet.2002.34674

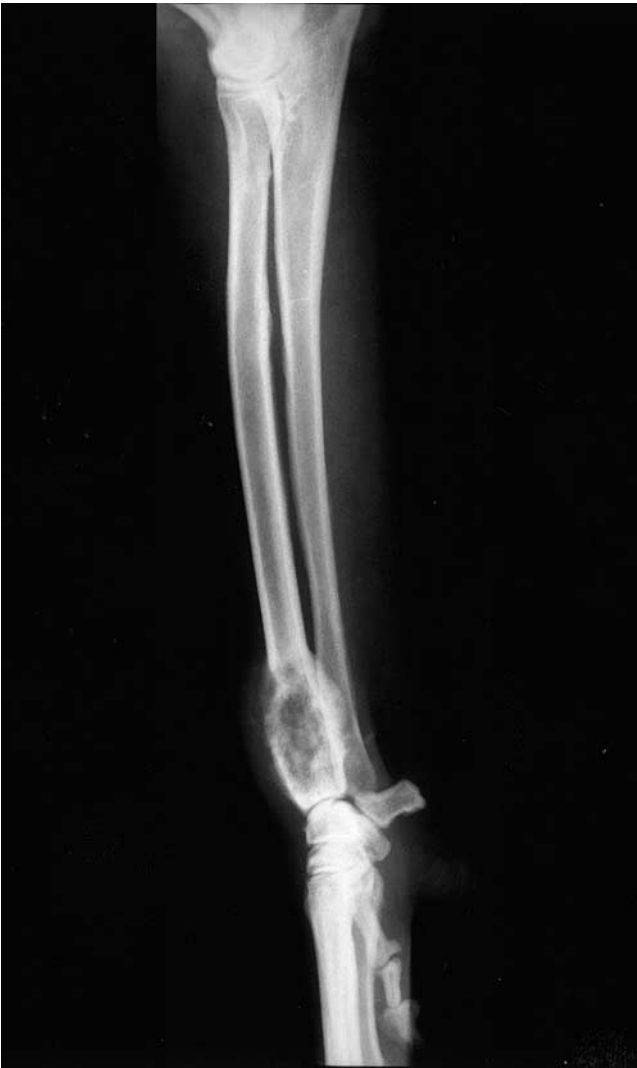the dog was in good health, with no lymphadenopathy, and complete blood count, serum biochemical profile, and urinalysis results were within the normal range. On radiographs, there was a lytic lesion involving the distal part of the right radius (Fig 1). Histopathologic examination of a bone biopsy identified the lesion as a fibroblastic OSA. No abnormalities were noted on thoracic radiographs. The tumor was staged as IIB.<sup>1</sup>

Treatment options were presented to the owner who elected to have the dog undergo a limb-sparing procedure using the excised tumor specimen as an autograft after it had been pasteurized. The dog was premedicated with acepromazine (0.025 mg/kg intramuscularly [IM]), atropine (0.02 mg/kg IM), and buprenorphine (0.006 mg/kg IM), and then anesthesia was induced with thiopental sodium (8 mg/kg intravenously [IV]) and maintained with isoflurane in oxygen. Cefazolin (22 mg/kg IV) was administered at

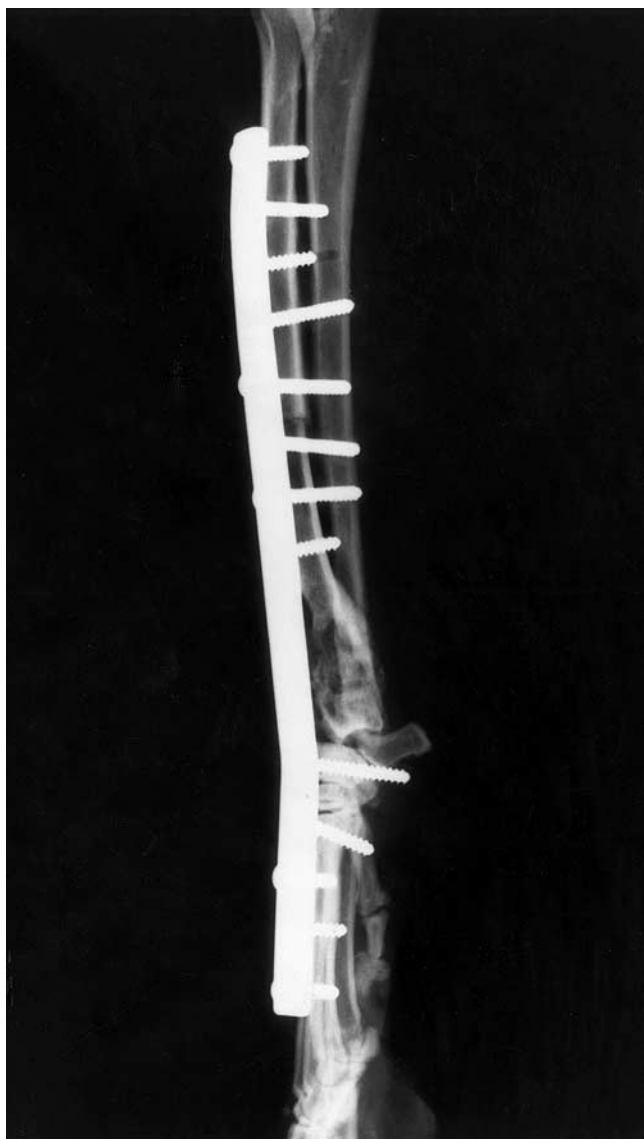
induction of anesthesia and then every 2 hours during surgery. Care was taken to aseptically prepare the limb widely to limit bacterial contamination during surgery.

With the dog positioned in right lateral recumbency, an incision was made along the medial aspect of the antebrachium and extended dorsally over the carpal and metacarpal region. Careful dissection was performed around the distal radius to isolate the tumor without penetrating it. The medial branch of the cephalic vein was ligated and transected. The extensor carpi radialis muscle was transected proximal to the tumor<sup>1</sup>; the common digital extensor tendons were also transected proximal and distal to the tumor. Care was taken during dissection to preserve structures of the caudal aspect such as ulnaris lateralis muscle, flexor muscle digitorum superficialis and profundus, flexor muscle carpi radialis and ulnaris, mediana artery, ulnaris nerve, and medianus nerve. Radial osteotomy was performed with an oscillating saw 4 cm proximal to the proximal extent of the tumor, determined preoperatively from radiographs. Finally, the distal radius containing the tumor was removed by disarticulation of the radiocarpal joint. The radial segment excised was 9.5 cm long; proximal and distal transverse sections were about 1.5 and 3 cm, respectively. The ulna was not excised because there was no radiographic evidence of involvement.

No neoplastic cells were identified in blade-scraping material collected at the contact points of the 2 pairs of bones. On cytologic examination of bone marrow collected from the proximal stump of the neoplastic specimen, no neoplastic cells were identified, suggesting an adequate proximal margin. The tumor specimen was cleaned, removing most of the surrounding soft tissues, and then pasteurized. The excised bone segment was placed in a sterile watertight box containing sterile saline (0.9% NaCl) solution preheated to 65°C in a water bath. The box was kept immersed in the water bath at 65°C for 40 minutes to kill the tumor cells.<sup>4,5</sup> During autograft pasteurization, the carpus was prepared for arthrodesis by removing all joint cartilage, then protected by sterile drapes until the autograft was ready. The articular cartilage was removed from the distal radius, the periosteum was stripped by scraping, and the bone marrow was removed by flushing with sterile saline solution through a pin inserted into the medullary cavity. Exuberant necrotic tumor was trimmed off the specimen before final washing in saline solution. The graft was then repositioned in the leg and stabilized with a 4.5-mm broad dynamic compression plate and screws using AO/ASIF technique. Proximally, 5 screws were inserted in the radius, 3 of which also engaged the ulna. Five screws were positioned distally, 1 in the radial carpal bone and 4 in the third metacarpus. Three screws were placed into the proximal portion of the autograft, 2 of which also engaged the ulna (Fig 2). After copious saline lavage, the wound was closed and a modified Robert Jones bandage was applied



**Fig 1.** Lateral projection. A lytic lesion is noted at the distal radius.



**Fig 2.** Lateral projection, after surgery. Five screws have been inserted in the radius, 3 of which engage the ulna (2 completely and 1 partially). Five screws are positioned distally, 1 in the radial carpal bone and 4 in the third metacarpal bone. The autograft is fixed to the plate only in its proximal part with 3 screws, 2 of which engage the ulna.

and maintained for 10 days. Cefazolin (20 mg/kg intramuscularly, every 12 hours) was administered for 10 days. The day after surgery, cisplatin chemotherapy (70 mg/m<sup>2</sup> IV) was administered in the middle of a 6-hour hydration period (17 mL/kg/h saline solution IV). Cisplatin administration was repeated 2 more times, 21 days apart. Only 3 of the 5 doses of cisplatin normally administered in our treatment protocol were given because the owner refused further chemotherapy. Activity was restricted during the first 2 months to short leash walks. The dog was reexamined 10 days after surgery for suture removal, then monthly for the

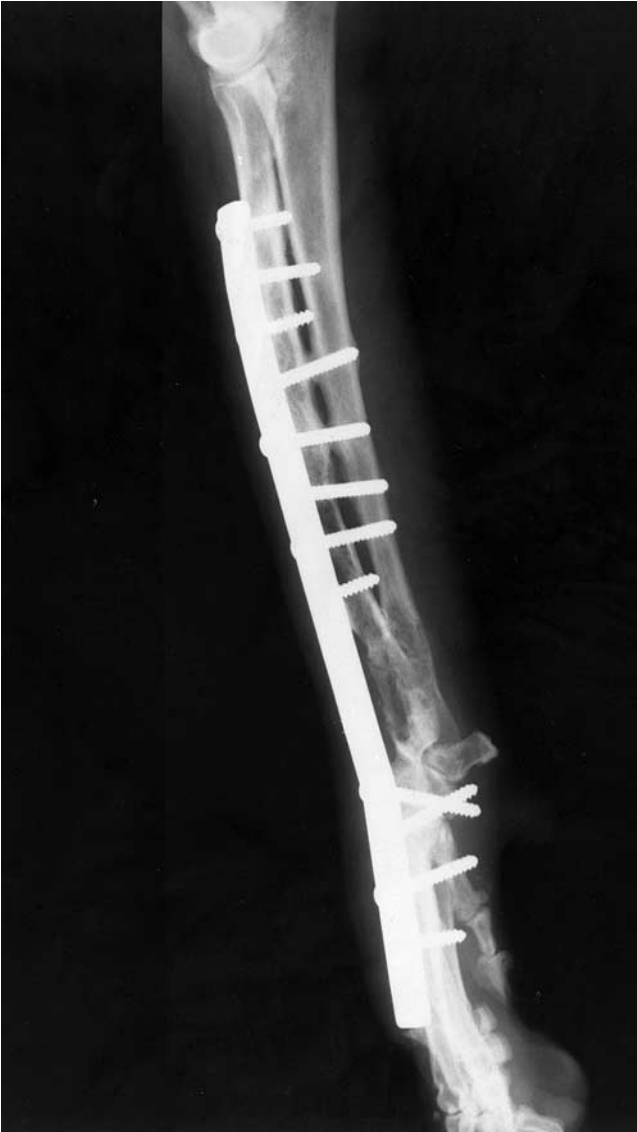
first 3 months, and every 3 months thereafter for the first year. Limb and thoracic radiographs and evaluation of limb function were performed at each examination. After 1 year, reexamination was scheduled every 6 months. Limb function was evaluated according to a grading system: excellent (slight or no lameness), good (mild lameness), fair (evident lameness), and poor (severe lameness or no use of the limb).<sup>6</sup>

## RESULTS

Cisplatin therapy was tolerated without any serious toxicity. Nausea and vomiting were controlled with metoclopramide (0.2 to 0.4 mg/kg SC). The neutrophil count did not decrease below  $3 \times 10^3$ /mL (range, 3 to  $11.5 \times 10^3$ /mL), and no nephrotoxicity was observed.

Limb function was excellent after 1 month. Although the owner was advised to control the dog's activity, this goal was not achieved. This unrestricted activity stressed the implant system, and at 76 days, the distal screw became loose and was removed. At 187 days, the proximal 3 of the 4 remaining distal screws were removed and replaced (Fig 3) because they were loose or broken. Samples were obtained from the screws for microbial culture as 2 fistulas had developed; *Staphylococcus* spp. was isolated. After the screws were replaced, the wound was copiously lavaged. Amoxicillin-clavulanic acid (15 mg/kg orally, every 8 hours) was administered for 15 days, based on antibiotic susceptibility test results. The fistulas resolved after 1 week. Local infection periodically recurred and was treated with antibiotics. The limb was bandaged at these times to prevent licking.

Incorporation of autograft and progression of the carpal arthrodesis was monitored radiographically during follow-up examinations. Bone union was complete at 11 months for the intercarpal and carpo-metacarpal level; however, there was no sign of incorporation of the autograft, proximally or distally. At 21 months, there was slight cranial displacement of the autograft that likely occurred before fusion, and it appeared deformed but increased in density and was fused both proximally and distally to the host bone and to the ulna. Because the plate had loosened and 2 screws had backed out, the implants were removed (708 days after surgery, 23.5 months); both host-autograft interfaces appeared fused (Fig 4). A spoon splint was applied for 1 month, and activity was severely restricted. At day 785 (26 months), limb function was good; however, there were signs of licking over the dorsal region of



**Fig 3.** Lateral projection, 6 months after surgery. The most distal screw has been removed, and the proximal 3 of the 4 remaining distal screws have been replaced to maintain stability. Lytic changes compatible with infection are evident in the ulna.

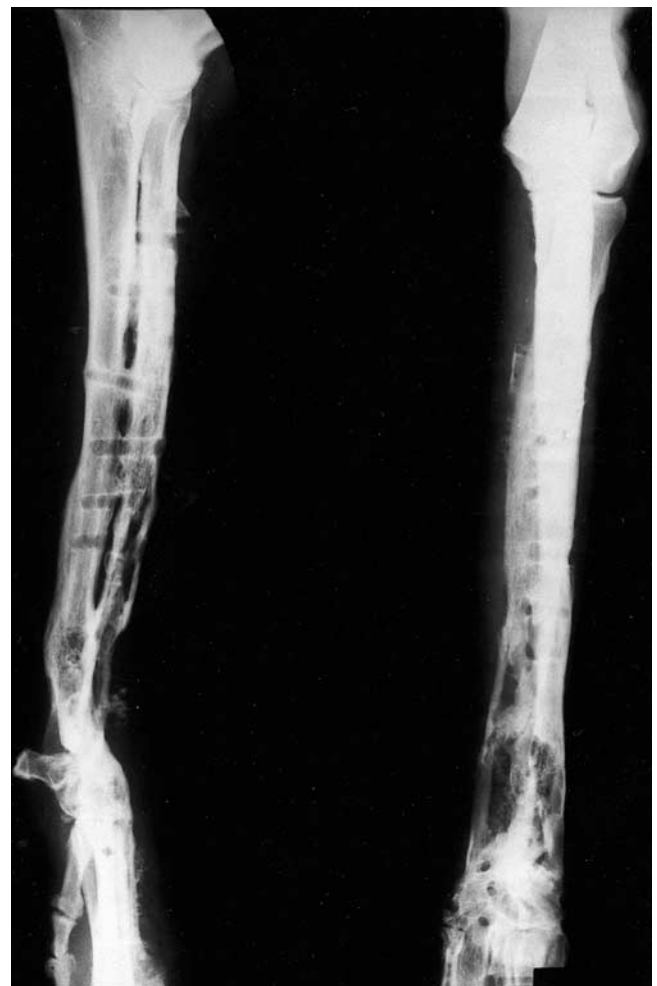the carpus. At 48 months, we were informed by the referring veterinarian that trauma had occurred to the spared limb and that the carpal arthrodesis had likely broken. Unfortunately, no radiographs were taken because the owner declined to have the dog evaluated further; however, we were informed that the dog was still partially loading the limb and that function was progressively improving.

At 56 months, on a craniocaudal projection, there was a large sequestrum corresponding to the old neoplastic site that was surrounded by a substantial

bone reaction; the distal ends of radius and ulna were free (Fig 5). Clinically, the dog was in good health; limb function was fair to good, and there was evidence, by palpation and on limb loading, of pain-free hyperextension of the manus (Fig 6). These findings were compatible with atrophic pseudoarthrosis. The owner declined any further treatment because he considered the quality of life of his dog's life to be good. Current overall survival time and disease-free interval is 1,683 days (56 months).

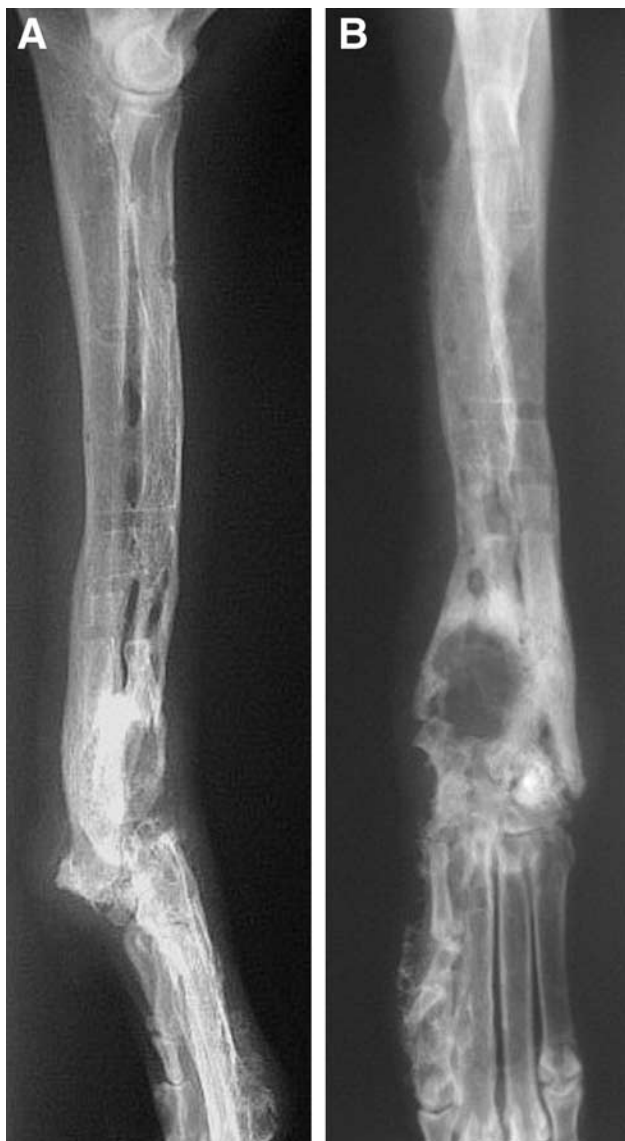## DISCUSSION

OSA is the most frequent primary bone tumor in dogs. Its cause is incompletely understood, but seemingly body weight may play a role in the pathogenesis of OSA, explaining why most cases are found at the



**Fig 4.** Lateral and craniocaudal projections. The plate and screws have been removed, 708 days (23.5 months) after surgery.





**Fig 5.** Lateral (A) and craniocaudal (B) projections at 56 months. (A) The distal end of radius is free. (B) A sequestrum corresponding to the old neoplastic lesion surrounded by a thick bone reaction is evident; the distal end of ulna appears free.

distal radius of dogs weighing more than 20 kg.<sup>7</sup> Limb amputation may not always be an option because of concomitant orthopedic or neurologic problems or simply because of the owners interest. For these reasons, several techniques of limb sparing have been used in dogs.<sup>8-11</sup> The most common technique involves the use of fresh-frozen cortical bone allograft fixed to the host bone with a dynamic compression plate and screws.<sup>1,6,8,12</sup> Arthrodesis of the nearby joint is usually performed. OSA of the distal radius is the most common site for use of this technique because

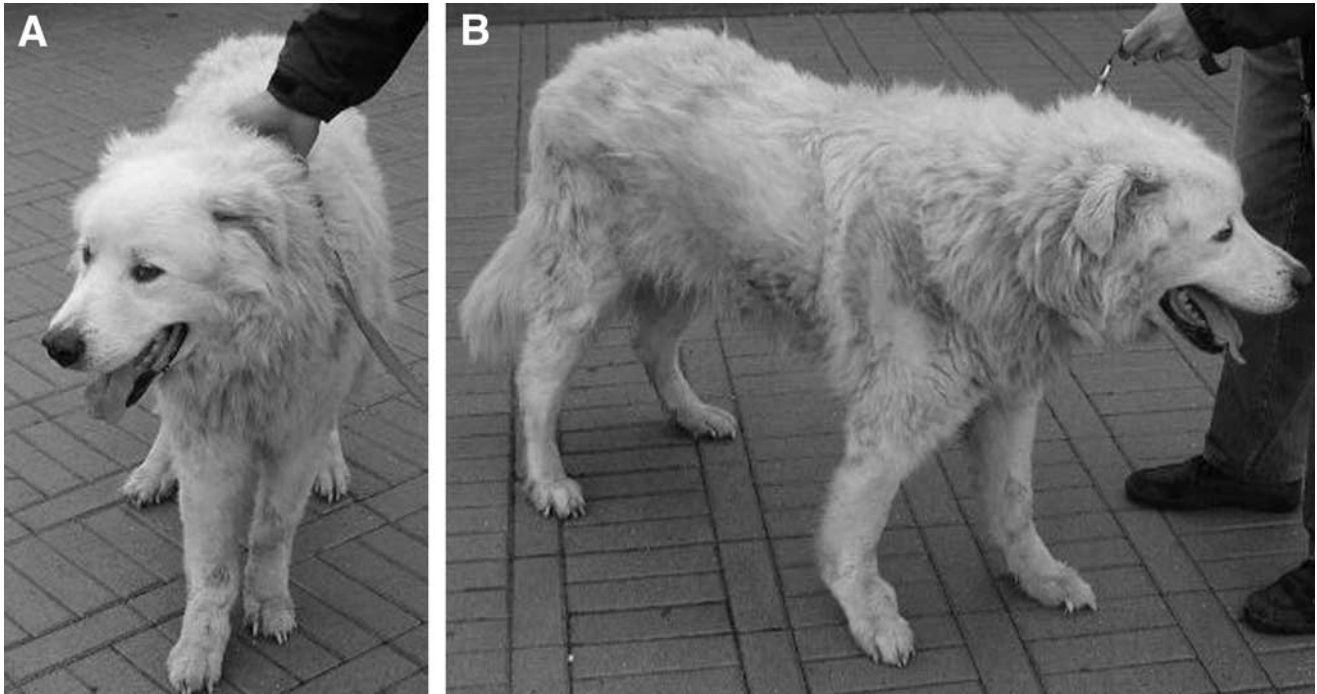
both the soft tissue coverage over the allograft and function after carpal arthrodesis are good.

Limb sparing in dogs with OSA located at the proximal humerus, tibia, or distal femur is controversial because arthrodesis of the shoulder or stifle results in poor or very poor limb function.<sup>1,13</sup> For OSA at these sites and also for the proximal femur, complete prosthetic replacement has been suggested.<sup>1,12</sup> The distal aspect of the tibia is not an optimal site for limb sparing because adequate soft tissue coverage over the allograft is difficult, even if function is acceptable, when a hock arthrodesis is performed.<sup>13</sup> Finally, osteochondral allografts have been advocated but, at present, no procedure for preparation and storage is able to maintain viable chondrocytes.<sup>14</sup>

Bone transport osteogenesis involving the use of the Ilizarov apparatus has also been used as a limb-sparing procedure for distal radial OSA. Initial reports indicate that this is a promising technique.<sup>15</sup>

Each technique has advantages and disadvantages. In general, all limb-sparing techniques are delicate surgical procedures that require expertise, knowledge of the potential complications, a dedicated owner, a treatable animal, and cooperation between surgeon, chemotherapist, and owner. The use of cortical bone allografts requires periodic maintenance of a bank of sterile frozen bone that must be aseptically harvested from dogs free of contagious and neoplastic diseases; such dogs may not always be available. Bone banking may also not be allowed in certain countries. A minimum of 15 days of freezing has been suggested to decrease the immunogenicity of a bone allograft that has been cleaned of all soft tissues, periosteum, and bone marrow.<sup>16,17</sup> If stored at  $-20^{\circ}\text{C}$ , the allograft should be used within 1 year because biomechanical properties begin to deteriorate after that time.<sup>18</sup> Cortical bone allografts prepared by freezing, freeze drying, or decalcification do not provide living cells. The healing process depends on the allograft's ability to induce osteoinduction in the recipient<sup>14</sup>; the allograft also provides a mechanical support to the new bone growth (osteoconduction).<sup>19</sup> Firstly, the bone graft undergoes centripetally, intense osteoclastic activity with tunnel formation, and enlargement of Howships' lacunae; then vascular buds and ossification fronts invade the resorption sites. Finally, new bone is formed so that it partially substitutes and partially overlaps the necrotic bone of the graft (creeping substitution).<sup>20,21</sup>

Other techniques of bone graft preparation also have



**Fig 6. Frontal (A) and lateral (B) view at 56 months. Note the hyperextension of the manus of the right forelimb.**

disadvantages. Osteoinductivity seems to decrease or be eliminated when boiling, autoclaving, or high-dose radiation are used.<sup>14,18</sup> It has been suggested that chemicals used for chemical sterilization may act as carcinogens.<sup>14</sup> In general, all preparation techniques, including freezing, result in decreased graft strength.<sup>22</sup>

Successful use of pasteurized autografts from the bone tumor have been reported in humans.<sup>4,5</sup> Because of these reports and our difficulty identifying dogs as bone donors for our own frozen allograft bank, we modified our limb-sparing protocol to include use of the pasteurization procedure. The healing we observed in this dog was comparable to that observed in our dogs with frozen allografts.<sup>6</sup> We have had good experience with this technique in other dogs<sup>23</sup> but are only reporting on this dog in detail because it has the longest follow-up, is still alive, has not had local recurrence or lung metastasis, and had plate removal. Based on our clinical experience and low recurrence rate, we can affirm that pasteurization is able to kill tumor cells as reported in humans.<sup>4,5</sup> Healing as observed in this dog may also imply a preserved, although decreased, osteoinductivity, but this needs further investigation.

Local infection is the most common non-tumor-related complication after limb sparing. Rarely does it result in complete failure of the procedure. Local

infection results from extensive surgical resection and vascular damage, duration of the procedure, implantation of nonvascularized bone and metallic devices, limited soft tissue coverage, chemotherapy, presence of undetected foci of infection somewhere in the body before surgery, and licking.<sup>24</sup> Measures to prevent infection include the adoption of strict aseptic surgical technique, perioperative and intraoperative administration of intravenous antibiotics, and prevention from licking and any other postsurgical trauma. Variable degrees of infection are observed. Recurrent wound drainage is the most frequent form and is usually controlled with systemic antibiotics and basic wound management, as occurred in this dog. Pasteurization did not limit this complication, although it did not seriously impede bone healing.

Implant failure is the second most frequent non-tumor-related complication associated with limb sparing. Causes may be an uncontrollable infection or implant instability. The latter may be caused by resection of more than 50% of the length of the bone and substitution with a long bone graft causing technical problems such as the positioning of an insufficient number of proximal or distal screws, depending on tumor location.<sup>24</sup> Another cause for implant failure may be an excess of activity of the animal, as occurred in our dog. Loosening of the implants necessitated

their removal, which also resulted in improvement of both the chronic bone infection and the skin lesions caused by licking.

The limited number of screws that were placed in the autograft because of the extensive bone destruction caused by the tumor may represent a major drawback for this technique because of resultant implant instability. The outcome in this dog and in others<sup>23</sup> does not suggest that it is a limiting factor when the orthopedic devices are in place, but problems may arise when they are removed. However, it is the authors' conviction that similar problems may also arise when other limb-sparing procedures are used. Consideration might be given to the use of polymethylmethacrylate and autologous cancellous bone grafts to increase stability. It is possible that a cancellous bone graft may have improved the strength of the radiocarpal arthrodesis.

Local recurrence is the major tumor-related local complication of limb sparing. Complete excision of OSA is not always achieved because of undetected extension into the surrounding soft tissue and incomplete removal of neoplastic bone by ostectomy. Local recurrence is certainly a distressing event, but it is not necessarily a life-threatening problem because limb amputation can be performed. A reduction of local recurrence in limb sparing (from 27% to 17%) has been achieved through the use of a slow-release cisplatin product in the surgical wound.<sup>25</sup> Evaluation of recent radiographs to determine the extent of radial ostectomy,<sup>26</sup> combined with intraoperative cytologic examination of surrounding tissues and bone marrow at the resection site, is useful to establish that a clean resection occurred. In this dog, the ulna was not removed because it appeared radiographically not to be involved and neoplastic cells were not identified on intraoperative cytologic examination. Sparing the ulna provided increased stability to the implant system. Finally, lack of recurrence in this dog may indicate that the pasteurization process killed the tumor.

Adjuvant chemotherapy is indicated because surgery alone should only be considered palliative. Survival is not affected by the surgical procedure (amputation v limb sparing) if adjuvant chemotherapy is used.<sup>1</sup> Commonly administered chemotherapeutic drugs are cisplatin,<sup>1,27</sup> doxorubicin,<sup>28</sup> cisplatin alternated with doxorubicin,<sup>29,30</sup> and carboplatin.<sup>31</sup> Because of the owner's refusal to pursue the standard protocol (5 doses), this dog received only 3 doses of

cisplatin; however, there was no evidence of lung metastasis.

We conclude that the use of a pasteurized bone graft derived from the resected primary bone neoplasm is a valid alternative to the use of a frozen cortical bone allograft for limb sparing in dogs with distal radial OSA. This procedure is indicated when difficulty is encountered establishing and maintaining a canine bone allograft bank.

## REFERENCES

1. Straw RC: Tumors of the skeletal system, in Withrow SJ, MacEwen EG (eds): *Small Animal Clinical Oncology* (ed 2). Philadelphia, PA, Saunders, 1996, pp 287-315
2. Brodey RS, Riser W: Canine osteosarcoma: A clinicopathological study of 194 cases. *Clin Orthop* 62:54-64, 1969
3. O'Brien MG, Straw RC, Withrow SJ: Recent advances in the treatment of canine appendicular osteosarcoma. *Compend Contin Educ Pract Vet* 15:939-946, 1993
4. Manabe J, Kawaguchi N, Matsumoto S, et al: Pasteurized autogenous bone grafts for osteosarcoma and Ewing's sarcoma. Proceedings from the 2nd Osteosarcoma Research Conference, Bologna, Italy, November 19-22, 1996, p 18
5. Manabe J: Experimental studies on pasteurized autogenous bone graft. *J Jpn Orthop Assoc* 67: 255-266, 1993
6. Morello E, Buracco P, Martano M, et al: Bone allografts and adjuvant cisplatin as treatment of canine appendicular osteosarcoma: 18 dogs (1991-1996). *J Small Anim Pract* 42:61-66, 2001
7. Ogilvie GK, Moore AS: Bone tumors, in Ogilvie GK, Moore AS (eds): *Managing the Veterinary Cancer Patient: A Practice Manual*. New Brunswick, NJ, Veterinary Learning Systems, 1995, pp 451-472
8. La Rue SM, Withrow SJ, Powers BE, et al: Limb-sparing treatment for osteosarcoma in dogs. *J Am Vet Med Assoc* 195:1734-1744, 1989
9. Withrow SJ, Thrall DE, Straw RC, et al: Intra-arterial cisplatin with or without radiation in limb-sparing for canine osteosarcoma. *Cancer* 71:2484-2490, 1993
10. Burchardt H, Jones H, Glowczewskie F, et al: Freeze-dried allogeneic segmental cortical-bone grafts in dogs. *J Bone Joint Surg Am* 60:1082-1090, 1978
11. Johnson AL, Shokry MM, Stein LE: Preliminary study of ethylene oxide sterilization of full-thickness cortical allografts used in segmental femoral fracture repair. *Am J Vet Res* 46:1050-1056, 1985
12. Vasseur P: Limb preservation in dogs with primary bone tumors. *Vet Clin North Am Small Anim Pract* 17:889-903, 1987
13. Buracco P, Peirone B, Pozzi L, et al: Amputation, limb sparing and cisplatin: 35 canine sarcomas. Proceedings from the 14th Annual Conference Veterinary Cancer Society, Townsend, TN, October 23-25, 1994, pp 49-50
14. Brown KLB, Cruess RL: Bone and cartilage transplantation in orthopaedic surgery. *J Bone Joint Surg Am* 64:270-279, 1982



15. Tommasini Degna M, Ehrhart N, Ferretti A, et al: Bone transport osteogenesis for limb salvage following resection of primary bone tumors: Experience with six cases (1991-1996). *Vet Comp Orthop Traumatol* 13:18-22, 2000
16. Friedlaender GE, Strong DM, Sell KV: Studies on the antigenicity of bone. 1. Freeze-dried and deep-frozen allografts in rabbits. *J Bone Joint Surg Am* 58:854-858, 1976
17. Friedlaender GE: Immune responses to osteochondral allografts. Current knowledge and future directions. *Clin Orthop Relat Res* 174:58-68, 1983
18. Pelker RR, Friedlaender GE, Markham TC: Biochemical properties of bone allografts. *Clin Orthop Relat Res* 174: 54-57, 1983
19. Alexander JW: Use of a combination of cortical bone allografts and cancellous bone autografts to replace massive bone loss in fresh fractures and selected nonunions. *J Am Anim Hosp Assoc* 19: 671-678, 1983
20. Sinibaldi KR: Evaluation of full cortical allografts in 25 dogs. *J Am Vet Med Assoc* 194:1570-1577, 1989
21. Johnson A: Principles of bone grafting. *Semin Vet Med Surg* 6:90-99, 1991
22. Roe SC, Pijanowski GJ, Johnson AL : Biochemical properties of canine cortical allografts: Effects of preparation and storage. *Am J Vet Res* 49:873-876, 1988
23. Buracco P, Morello E, Martano M, et al: Results of the use of auto- and allo-bone grafts for the treatment of the canine appendicular osteosarcoma. Proceedings 18th Annual Conference Veterinary Cancer Society, Estes Park, CO, October 3-6, 1998, p 57
24. Straw RC, Withrow SJ: Limb-sparing surgery versus amputation for dogs with bone tumors. *Vet Clin North Am Small Anim Pract* 26:135-143, 1996
25. Straw RC, Withrow SJ, Douple EB, et al: The effect of cis-diamminedichloroplatinum II released from D,L,-polylactic acid implanted adjacent to cortical allografts in dogs. *J Orthop Res* 12: 871-877, 1994
26. Leibman NF, Kunz CA, Steyn PF, et al: Accuracy of radiography, nuclear scintigraphy, and histopathology for determining the proximal extent of distal radius osteosarcoma in dogs. *Vet Surg* 30: 240-245, 2001
27. Straw RC, Withrow SJ, Richter SL, et al: Amputation and cisplatin for treatment of canine osteosarcoma. *J Am Vet Med Assoc* 5:205-210, 1991
28. Berg J, Weinstein MJ, Springfield DS, et al: Results of surgery and doxorubicin chemotherapy in dogs with osteosarcoma. *J Am Vet Med Assoc* 206:1555-1560, 1995
29. Mauldin GN, Matus RE, Withrow SJ, et al: Canine osteosarcoma treatment by amputation versus amputation and adjuvant chemotherapy using doxorubicin and cisplatin. *J Am Vet Med Assoc* 2:177-180, 1988
30. Chun R, Kurzman ID, Couto GC, et al: Cisplatin and doxorubicin combination chemotherapy for the treatment of canine osteosarcoma: A pilot study. *J Vet Intern Med* 14:495-498, 2000
31. Bergman PJ, MacEwen EG, Kurzman ID, et al: Amputation and carboplatin for treatment of dogs with osteosarcoma: 48 cases (1991-1993). *J Am Vet Med Assoc* 10:76-81, 1996