

AperTO - Archivio Istituzionale Open Access dell'Università di Torino

**Vaccine-associated-like fibrosarcoma at the site of a deep nonadsorbable suture in a cat.**

**This is the author's manuscript**

*Original Citation:*

*Availability:*

This version is available <http://hdl.handle.net/2318/52529> since

*Terms of use:*

Open Access

Anyone can freely access the full text of works made available as "Open Access". Works made available under a Creative Commons license can be used according to the terms and conditions of said license. Use of all other works requires consent of the right holder (author or publisher) if not exempted from copyright protection by the applicable law.

(Article begins on next page)



## Short Communication

# Vaccine-associated-like Fibrosarcoma at the Site of a Deep Nonabsorbable Suture in a Cat

P. BURACCO\*, M. MARTANO\*, E. MORELLO\* and A. RATTO†

\*School of Veterinary Medicine, Dipartimento di Patologia Animale, Grugliasco (TO), Italy, †IST (Istituto Nazionale per la Ricerca sul Cancro), Laboratorio di Oncologia Comparata, Genoa, Italy

KEYWORDS: Cat; vaccine-associated-like sarcoma; nonabsorbable suture.

An 8-year old short-haired neutered female cat was presented at the School of Veterinary Medicine, Turin, with two nodules of 1 and 2 cm diameter, adherent to the abdominal wall. These nodules had developed during the previous 15 days, after the referring veterinarian had marginally resected an encapsulated 4 cm mass along the ventral midline 2 months previously. The mass had been identified histologically as a grade II fibrosarcoma. The history indicated that the cat had been neutered 7 years previously through a midline celiotomy. No further trauma had been reported at this site. Physical and laboratory evaluation revealed no enlarged regional lymph nodes and all laboratory tests were normal, including negative tests for Feline Immunodeficiency and Feline Leukemia Viruses. Lateral and dorsoventral chest radiographs excluded visible lung metastasis. A tru-cut biopsy was performed on the lesions and histopathology confirmed the previous diagnosis.

The cat was submitted to a second surgery. Pre-medication consisted of acepromazine (0.0025 mg/kg, i.m.), atropine (0.02 mg/kg, i.m), and ketamine (15 mg/kg, i.m.); the cat was intubated and inhalation anaesthesia maintained with halotane.

Buprenorphine (0.006 mg/kg) was administered i.m. at induction of anaesthesia, together with i.v. cefazolin (20 mg/kg). Surgery consisted in full thickness excision of the abdominal wall with a margin of at least 2 cm all around the lesions; reconstruction was with a Vicryl mesh sutured to the remaining fascia and further reinforcement was provided with the dorsal leaf of the omentum emerging from the abdominal incision cranially to the mesh. Definitive closure was with a cutaneous advancement flap.

The excised material was examined grossly and some polyester sutures were found on the ventral midline. After excision margin identification, the specimen was fixed in 10% buffered formalin and submitted for histological examination.

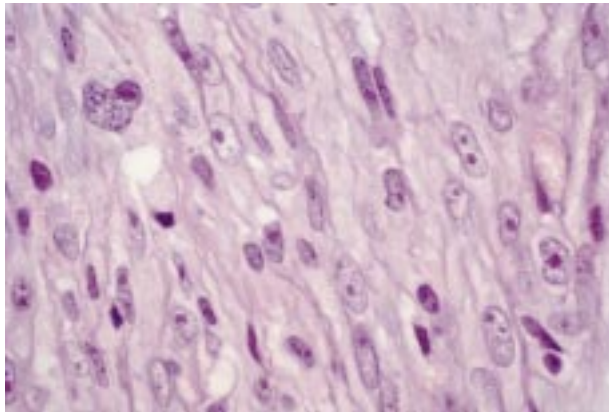
After 95 days, a rapidly growing 4 cm mass was found adherent to the sternum, about 12 cm cranial to the original lesions. The evaluation of May-Grünwald Giemsa stained slides from several fine-needle aspirates confirmed the sarcomatous origin of the lesion. Even though chest radiographs excluded lung metastasis, the owner declined any further treatment and the cat was euthanased 25 days later because of progressive disease. The owner refused autopsy and no histopathology was performed on the recurrence.

Feline vaccine-associated sarcoma (VAS) was firstly described by Hendrick and Goldschmidt (1991). This neoplasm originates at the site of subcutaneous administration of vaccines (Hendrick, 1998) and long acting drugs (Esplin *et al.*, 1999).

Correspondence to: Paolo Buracco, full Professor of Surgery, Dipl. ECVS, Dipartimento di Patologia Animale, Facoltà di Medicina Veterinaria, Via Leonardi da Vinci, 44, 10095 Grugliasco (Turin), Italy. Tel.: +39 (0) 11 6709063; Fax: +39 (0) 11 6709057; E-mail: [paolo.buracco@unito.it](mailto:paolo.buracco@unito.it)

Cats demonstrate a peculiar predisposition to neoplasms at the site of injury, as in case of ocular sarcoma after eye trauma (Dubielzig, 1984; Dubielzig *et al.*, 1990). VASs, including fibrosarcoma, chondrosarcoma, malignant fibrous histiocytoma, rhabdomyosarcoma, liposarcoma, osteosarcoma, and undifferentiated sarcoma, usually grow at the sites more frequently used for subcutaneous injections. The tumour can be solid or cystic, movable or fixed to the underlying tissues, and it can become as large as 4 cm. On rare occasions VASs have spread at presentation, but they have a high tendency to recur if marginally resected (Hershey *et al.*, 2000). The pathogenesis is unclear, but the stimulus is likely to be the inflammatory process generated by the subcutaneous introduction of a 'foreign body'. This is evidenced by the presence of lymphocytes, macrophages (Hendrick & Brooks, 1994; Doddy *et al.*, 1996) and necrotic material all around the neoplasm, usually absent in non-injection-site sarcomas; the latter are also differently localized (Doddy *et al.*, 1996). Microscopic particles of aluminium compounds have also been observed within the macrophages, strengthening the hypothesis of vaccine adjuvants' role in the development of the tumour. However, it is now believed that vaccines are not the unique cause of sarcoma at the injection site (Macy, 1999).

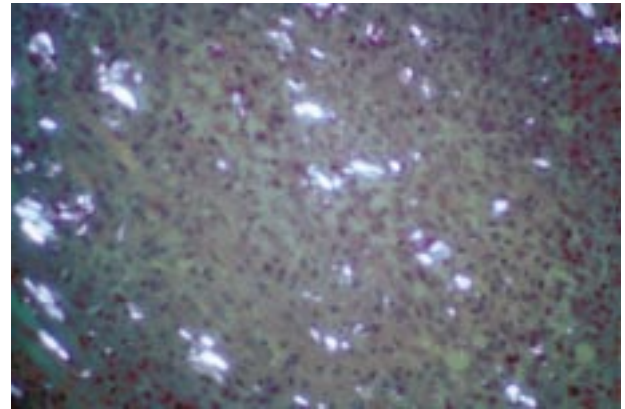
The neoplastic tissue excised at the time of both the first and second surgeries was composed of densely arranged, interlacing sheets and bundles of spindle-shaped cells admixed with small numbers of lymphocytes. Multinucleated giant cells were also present. Neoplastic cells exhibited moderate to marked anisocytosis and anisokariosis with prominent nucleoli (Fig. 1); mitotic index was 4 to



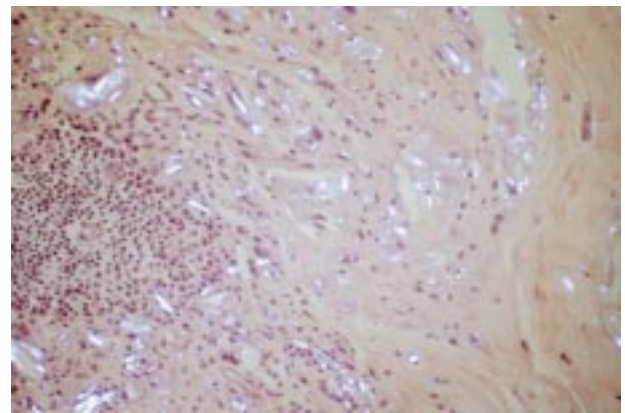
**Fig. 1.** Neoplastic cells exhibited vesicular, oval to fusiform nuclei with prominent nucleoli. (H & E stain); 100 $\times$ .

8 per 400 $\times$  field. Adjacent to the tumour there were zones of eosinophilic necrosis rimmed by macrophages and lymphoid aggregates. Pale granular to crystalline foreign material was seen mainly in the necrotic areas and within macrophages cytoplasm, and among neoplastic cells; this material showed birefringence under polarised light microscope (Figs 2 and 3). This foreign material was considered to be the remnants of the nonadsorbable suture. Excision margins resulted clean.

According to these VAS-like histological features, we believe this foreign material, applied 7 years before, may have played a role in the tumour development. Such reports, as far as we know, have not been documented previously. An uncoated braided nonadsorbable material located deeply may evoke a chronic inflammatory response (granuloma). A



**Fig. 2.** Remnants of foreign material among neoplastic cells were observed under polarized light microscope (H & E stain); 20  $\times$  1,25.



**Fig. 3.** Granulomatous reaction rimmed by mononuclear inflammation. Crystalline foreign material showed birefringence under polarized light microscope (H & E stain); 20  $\times$  1,25.

granuloma, as it is known for VAS, can evolve in malignancy in some cats. The referring veterinarian had only used polyglactin 910 (absorbable and violet) as a deep suture material during his surgery and the polyester (nonabsorbable and green) was not noticed as excision had been along the tumoral pseudocapsula.

Multiple therapies have been attempted to treat VASs (Davidson *et al.*, 1997; Cronin *et al.*, 1998; Macy, 1999), but none has proved to be completely satisfactory. The major problem is the high local recurrence rate and the treatment of choice is wide surgical excision; more recent protocols have included the association with radiation and/or chemotherapy (Couto & Macy, 1998). At the time of the evaluation of this case, our protocol was based on aggressive surgery alone. Recurrences of VASs may be due to an incomplete surgery without any pre-operative diagnosis, as occurred in this case at the first relapse, but it could also represent a further evolution of an 'activated' site localized at the periphery of the original lesion (Richards, 1998). If true, the extension of the wide margin excision of VASs could always be underestimated. This could explain tumours that only apparently recur but that actually develop far away from the original lesion, despite a wide excision, and could potentially justify the second relapse observed here.

## ACKNOWLEDGEMENTS

We would like to acknowledge Dr. Pleitavino Massimiliano (the referring veterinarian) and Dr. Domenis Lorenzo (the first pathologist).

## REFERENCES

COUTO, G. C. & MACY, D. W. (1998). Review of treatment options for vaccine-associated feline sarcoma. *Journal of the American Veterinary Association* **213**, 1426–1427.

- CRONIN, K., PAGE, R. L., SPODNICK, G., DODGE, R., HARDIE, E. N., PRICE, G. S., RUSLANDER, D. & THRALL, D. E. (1998). Radiation therapy and surgery for fibrosarcoma in 33 cats. *Veterinary Radiology and Ultrasound* **39**, 51–56.
- DAVIDSON, E. B., GREGORY, C. R. & KASS, P. H. (1997). Surgical excision of soft tissue fibrosarcomas in cats. *Veterinary Surgery* **26**, 265–269.
- DODDY, F. D., GLICKMAN, L. T., GLICKMAN, N. W. & JANOVITZ, E. B. (1996). Feline fibrosarcomas at vaccination sites and non-vaccination sites. *Journal of Comparative Pathology* **114**, 165–174.
- DUBIELZIG, R. R. (1984). Ocular sarcoma following trauma in three cats. *Journal of the American Veterinary Association* **184**, 578–581.
- DUBIELZIG, R. R., EVERITT, J. A., SHADDUCK, J. A. & ALBERT, D. M. (1990). Clinical and morphologic features of post-traumatic ocular sarcomas in cats. *Veterinary Pathology* **27**, 62–65.
- ESPLIN, D. G., BIGELOW, M., MCGILL, L. D. & WILSON, S. R. (1999). Fibrosarcoma at the site of a Lufenuron injection in a cat. *Veterinary Cancer Society Newsletter* **23** (2), 8–9.
- HENDRICK, M. J., & GOLDSCHMIDT, M. H. (1991). Do injection site reactions induce fibrosarcomas in cats. *Journal of the American Veterinary Association* **99**, 968.
- HENDRICK, M. J. & BROOKS, J. J. (1994). Postvaccinal sarcomas in the cat: histology and immunohistochemistry. *Veterinary Pathology* **31**, 126–129.
- HENDRICK, M. J. (1998). Historical review and current knowledge of risk factors involved in feline vaccine-associated sarcoma. *Journal of the American Veterinary Association* **213**, 1422–1423.
- HERSHEY, E. A., SORENMO, K. U., HENDRICK, M. J., SHOFRER, F. S. & VAIL, D. M. (2000). Prognosis for presumed feline vaccine-associated sarcomas after excision: 61 cases (1986–1996). *Journal of the American Veterinary Association* **216**, 58–61.
- MACY, D. W. (1999). Current understanding of vaccination site-associated sarcomas in the cat. *Journal of Feline Medicine and Surgery* **1**, 15–21.
- RICHARDS, J. R. (1998). Vaccine-associated feline sarcoma task force awards research grants. *Journal of the American Veterinary Association* **212**, 162–163.

(Accepted for publication 7 June 2001)