

AperTO - Archivio Istituzionale Open Access dell'Università di Torino

Nonexposed Variant of Bisphosphonate-associated Osteonecrosis of the Jaw: A Case Series.

This is the author's manuscript

Original Citation:

Availability:

This version is available <http://hdl.handle.net/2318/82941> since

Published version:

DOI:10.1016/j.amjmed.2010.04.033

Terms of use:

Open Access

Anyone can freely access the full text of works made available as "Open Access". Works made available under a Creative Commons license can be used according to the terms and conditions of said license. Use of all other works requires consent of the right holder (author or publisher) if not exempted from copyright protection by the applicable law.

(Article begins on next page)

Nonexposed Variant of Bisphosphonate-associated Osteonecrosis of the Jaw: A Case Series

Stefano Fedele, DDS, PhD,^a Stephen R. Porter, MD, PhD,^a Francesco D'Aiuto, MDM, MSc, PhD,^a Suad Aljohani, DDS, MSc,^a Paolo Vescovi, MD, PhD,^b Maddalena Manfredi, DDS, PhD,^b Paolo G. Arduino, DDS, MSc,^c Roberto Broccoletti, DDS, MSc,^c Anna Musciotto, DDS, PhD,^d Olga Di Fede, DDS, PhD,^d Tony S. Lazarovici, DMD,^e Giuseppina Campisi, DDS, PhD,^d Naom Yarom, DDS, MSc^{e,f}

^aUniversity College London Eastman Dental Institute, London, UK; ^bUnit of Oral Medicine Pathology Laser-Assisted Surgery—Parma, University of Parma, Parma, Italy; ^cDepartment of Biomedical Sciences and Human Oncology, Oral Medicine Section, University of Turin, Lingotto Dental Institute, Turin, Italy; ^dOral Medicine Section, Department of Stomatological Sciences, University of Palermo, Palermo, Italy; ^eDepartment of Oral & Maxillofacial Surgery, Sheba Medical Center, Tel-Hashomer, Israel; ^fDepartment of Oral Pathology and Oral Medicine, School of Dental Medicine, Tel-Aviv University, Tel Aviv, Israel.

ABSTRACT

PURPOSE: To report a case series of patients with the nonexposed variant of bisphosphonate-associated osteonecrosis of the jaw—a form of jaw osteonecrosis that does not manifest with necrotic bone exposure/mucosal fenestration.

METHODS: Among 332 individuals referred to 5 clinical centers in Europe because of development of jawbone abnormalities after or during exposure to bisphosphonates, we identified a total of 96 patients who presented with the nonexposed variant of osteonecrosis. Relevant data were obtained via clinical notes; radiological investigations; patients' history, and referral letters.

RESULTS: The most common clinical feature of nonexposed osteonecrosis was jaw bone pain (88/96; 91.6%); followed by sinus tract (51%), bone enlargement (36.4%); and gingival swelling (17.7%). No radiological abnormalities were identified in 29.1% (28/96) of patients. In 53.1% (51/96) of the patients; nonexposed osteonecrosis subsequently evolved into frank bone exposure within 4.6 months (mean; 95% confidence interval; 3.6-5.6).

CONCLUSIONS: Clinicians should be highly vigilant to identify individuals with nonexposed osteonecrosis, as the impact on epidemiological data and clinical trial design could be potentially significant. Although the present case series represents approximately 30% of all patients with bisphosphonates-associated osteonecrosis observed at the study centers, further population-based prospective studies are needed to obtain robust epidemiological figures.

© 2010 Elsevier Inc. All rights reserved. • *The American Journal of Medicine* (2010) 123, 1060-1064

KEYWORDS: Avascular necrosis; Bisphosphonates; Jawbones; Jaws; Mandible; Maxilla; Osteochemonecrosis; Osteonecrosis

Funding: The authors declare no funding sources for preparation of this manuscript.

Conflict of Interests: Dr. Yarom received lecture fees from Novartis and Bayer; all other authors declare no conflicts of interest.

Authorship: All authors had access to the data and a significant role in writing the manuscript.

Requests for reprints should be addressed to Stefano Fedele, DDS, PhD, Oral Medicine Unit, Division of Maxillofacial, Diagnostic, Medical and Surgical Sciences, UCL Eastman Dental Institute, 256 Gray's Inn Road, London WC1X 8LD, UK.

E-mail address: s.fedele@eastman.ucl.ac.uk

Osteonecrosis of the jaws is an increasingly common and clinically significant complication of bisphosphonate medications.¹⁻³ Since 2003, more than 1000 cases of bisphosphonate-associated osteonecrosis of the jaw have been documented in the literature,¹⁻¹² and more than 3500 cases have been reported to the Food and Drug Administration in the US alone.^{4,5} Reported prevalence ranges substantially from 0.01% to 28%,¹⁻⁹ and high variability persists after correction for type/potency of bisphosphonates and underlying diseases (high-potency intravenous in cancer patients vs. low-potency oral bisphosphonates in osteoporosis patients).¹⁻⁹ This is more likely to reflect inconsistency and

flaws in the collection of data rather than real variations in the prevalence among populations.⁷

The lack of specific diagnostic criteria and a unanimously accepted definition of bisphosphonate-associated osteonecrosis of the jaw is possibly the major cause of this epidemiological inconsistency.

Usually, bisphosphonate-associated osteonecrosis of the jaw is defined as an area of exposed bone in the maxillofacial region that does not heal within 6-8 weeks in a patient who is receiving or has been exposed to bisphosphonate medications (but not to radiotherapy to the head and neck).^{1-8,13} It has been described as avascular bone necrosis from histopathology reports, although biopsy is usually not required for its diagnosis.^{1-3,13} More recently, however, there have been reports suggesting that bisphosphonate-associated osteonecrosis of the jaw, especially in its early stages, can manifest signs and symptoms in absence of bone exposure.^{2,14-16} Jaw bone pain, sinus tract and gingival/bone swelling in the absence of obvious dental or jawbone disease other than osteonecrosis have occasionally been reported weeks or months before the onset of frank bone exposure.¹⁴⁻¹⁶ Transient, early-stage “possible bisphosphonate-associated osteonecrosis of the jaws” and a “nonexposed variant of osteonecrosis” have been proposed as terms for describing this manifestation.^{2,14-16} There remain, however, few studies describing in detail such clinical features and little evidence regarding their frequency and natural history.

We studied a series of patients who, after exposure to bisphosphonates, developed jawbone symptoms/signs in absence of obvious bone exposure for whom no cause other than osteonecrosis could be identified.

METHODS

Between 2007 and 2009, 332 individuals had been referred to 5 clinical centers in Europe with possible diagnosis of bisphosphonate-associated osteonecrosis of the jaw because of development of jawbone abnormalities after/during exposure to bisphosphonate medications. A total of 96 patients (29.8%) presented jawbone manifestations that fulfilled the description of presumed nonexposed variant of bisphosphonate-associated osteonecrosis of the jaws, as described in previous reports.^{2,14-16} Relevant clinical features included: 1) jaw pain, 2) jaw bone enlargement/gingival swelling, and 3) sinus tract, which could not be related to dental disease or another local or systemic disorder other than osteonecrosis.

Exclusion of dental or primary bone disease other than osteonecrosis was based on clinical and radiological assessment. Patients' characteristics are presented in Table 1.

Relevant details of nonexposed bisphosphonate-associated osteonecrosis of the jaws were obtained via clinical notes, patients' histories, and referral letters. The average follow-up from osteonecrosis diagnosis to final data collection was 12.6 months (range 6-24 months). Presence of radiological abnormalities detected with an orthopantomogram or computed tomography, and subsequent development of transmucosal necrotic bone exposure, where present, were also recorded.

Hospital and primary care records were reviewed to collect details of medical and drug history (including underlying disease, type and duration of bisphosphonate therapy), as well as surgical procedure to the jaw bones before osteonecrosis development. We used the definition of spontaneous nonexposed bisphosphonate-associated osteonecrosis of the jaws when there was no history of dental surgery to

the affected area over the 6 months preceding osteonecrosis development.

RESULTS

Ninety-six (28.9%) of 332 (71.1%) patients were diagnosed with nonexposed bisphosphonate-associated osteonecrosis of the jaws (Table 1). Thirty were male and 66 female, and their age ranged from 38 to 90 years (mean: 68 years, 95% confidence interval [CI], 66-71). The underlying diseases that required treatment with bisphosphonate included multiple myeloma (43 patients, 44.8%), osteoporosis (25 patients, 26.04%), metastasizing breast cancer (19 patients, 19.8%), prostate cancer (5 patients, 5.2%), and renal cancer (4 patients, 4.2%) (Table 1).

Eighteen patients (18.8%) had been exposed to alendronate only, whereas 39 had zoledronate (40.6%) and 12 patients had pamidronate (12.5%) monotherapies. Four patients were exposed to clodronate (4.2%), 12 individuals (12.5%) used both pamidronate and zoledronate, and the remaining patients were exposed to various associations of alendronate, zoledronate, pamidronate, clodronate, and ibandronate (Table 1).

The mean duration of bisphosphonate therapy before diagnosis of nonexposed osteonecrosis was 37.0 months (range 5-120 months; 95% CI, 31.6-42.5). In 21 patients (21.8%) the duration was 5-12 months, while 23 individuals (23.9%) had taken bisphosphonates for 13-24 months before nonexposed bisphosphonate-associated

CLINICAL SIGNIFICANCE

- Bisphosphonates-associated osteonecrosis of the jaws can present with no clinical evidence of necrotic bone exposure.
- Clinical features of nonexposed osteonecrosis include persistent jaw bone pain, bone enlargement, gingival swelling, or sinus tract in absence of relevant dental disease.
- Up to half of the patients with nonexposed osteonecrosis may never progress to develop frank bone exposure; up to one third would show no obvious radiological abnormalities.

Table 1 Characteristics of Patients and Type and Duration of Bisphosphonate Therapy before Development of Osteonecrosis

Disease	Patients n (%)	Sex and Mean Age, Years (Range)	Bisphosphonate Therapy (No. of Patients)	Mean and Median Duration of Bisphosphonate Therapy before Osteonecrosis Development (Months)
Multiple myeloma	43 (44.8%)	22 F 21 M 68.9 (50-82)	Zoledronate (23) Pamidronate (8) Pamidronate + zoledronate (8) Clodronate (1) Alendronate + zoledronate (1) Pamidronate + clodronate (1) Alendronate + pamidronate (1)	Mean: 35.02 Median: 25
Osteoporosis	25 (26.0%)	24 F 1 M 68.96 (38-88)	Alendronate (18) Clodronate (3) Zoledronate (1) Pamidronate (2) Ibandronate (1)	Mean: 57.28 Median: 60
Metastasizing breast cancer	19 (17.85%)	19 F 64.2 (43-85)	Zoledronate (8) Pamidronate + zoledronate (3) Pamidronate (3) Zoledronate + clodronate (2) Zoledronate + ibandronate (2) Pamidronate + zoledronate + Alendronate + ibandronate (1)	Mean: 38.94 Median: 24
Metastasizing prostate cancer	5 (5.2%)	5 M 76 (72-90)	Zoledronate (4) Pamidronate + zoledronate (1)	Mean: 23.0 Median: 27
Metastasizing renal cancer	4 (4.2%)	3 M 1 F 67.5 (56-69)	Zoledronate (4)	Mean: 20.52 Median: 18

osteonecrosis of the jaw was diagnosed. Exposure to 25-36 and 37-60 months of bisphosphonate therapy was associated with jaw osteonecrosis in 12 (12.5%) and 20 (20.8%) patients, respectively. Twenty-one individuals (21.8%) had used bisphosphonate for more than 60 months before bisphosphonate-associated osteonecrosis of the jaw occurred. In total, 44 (45.8%) individuals had a history of bisphosphonate exposure ≤ 24 months before the development of symptoms or signs of nonexposed osteonecrosis (Table 1, Figure).

In the subgroup of patients who had used only alendronate, we observed that the length of therapy before diagnosis of bisphosphonate-associated osteonecrosis of the jaw ranged from 12 to 96 months (mean 62.8; 95% CI, 47.1-78.5). Patients who developed nonexposed jaw osteonecrosis after exposure to zoledronic acid or pamidronate only did so after 8-62 (mean 24.1; 95% CI, 16.1-32.0) and 5-120 months of therapy (mean 45.3; 95% CI, 18.6-65.9), respectively.

Overall, the most common clinical feature of nonexposed osteonecrosis was jaw bone pain, which was reported by 88 patients (91.6%), followed by sinus tract formation (49 patients, 51%), bone enlargement (35 patients, 36.4%), and gingival enlargement (17 patients, 17.7%) (Table 2). These symptoms/signs developed spontaneously in all patients,

with no history of dental surgery during the previous 6 months having been reported.

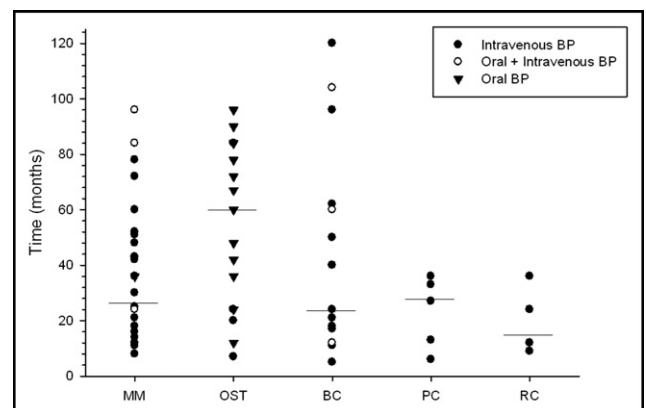


Figure Scatter plot of patients affected by nonexposed osteonecrosis categorized by underlying disease and with detail of bisphosphonate agents (oral vs. intravenous) and therapy duration. The horizontal lines indicate the median values of therapy duration in each disease group. BC = breast cancer; MM = multiple myeloma; OST = osteoporosis; PC = prostate cancer; RC = renal cancer.

Table 2 Summary of Clinical and Radiological Features of Nonexposed BONJ

Center	Total Cases of Nonexposed BONJ (n Patients)	Manifestations					Radiological Abnormalities (n Patients)	Progression to Frank Bone Exposure (n Patients)
		Jaw Bone Pain (n Patients)	Bone Enlargement (n Patients)	Gingival Swelling (n Patients)	Sinus Tract (n Patients)			
UCL EDI	8	6	1	2	6	1	Yes (3) No (5)	
OSP	20	20	19	1	1	1	Yes (18) No (2)	
OMSI	28	25	13	13	24	8	Yes (21) No (7)	
OMT	6	5	2	1	2	4	Yes (5) No (1)	
UOMPLAS-PR	34	32	0	0	16	14	Yes (4) No (30)	
Total, n (%)	96	88 (91.6%)	35 (36.4%)	17 (17.7%)	49 (51%)	28 (29.1%)	Yes (51; 53.2%) No (45; 46.8%)	

BONJ = bisphosphonate-associated osteonecrosis of the jaws; OMSI = Department of Oral and Maxillofacial Surgery, Sheba Medical Center, Tel-Hashomer, Israel; OMT = Department of Oral Medicine, Lingotto Dental Institute, Turin, Italy; OSP = Department of Oral Sciences of Palermo University, Italy; UCL EDI = University College London Eastman Dental Institute, UK; UOMPLAS-PR = Unit of Oral Medicine Pathology Laser-Assisted Surgery-Parma.

Twenty-eight patients (29.1%) had no demonstrable radiological abnormalities (orthopantomogram or computed tomography scan), whereas 68 (70.9%) had evidence of osteolysis with/without osteosclerosis (Table 2).

In 51 patients (53.1%) nonexposed osteonecrosis subsequently progressed into frank bone exposure over a period of time ranging from 0.5 to 14 months (mean 4.6; 95% CI, 3.6-5.6). Such a progression was not observed in the remaining 45 patients (46.9%), who did not develop obvious evidence of bone exposure throughout the observation period (up to 2 years).

DISCUSSION

The present observational study is the largest published series of patients who had been exposed to bisphosphonates and developed jaw bone symptoms/signs in the absence of bone exposure. These patients were classified as being affected by nonexposed bisphosphonate-associated osteonecrosis of the jaw because: 1) there was no obvious evidence of dental infection or other jaw bone disease (eg, metastases) that could cause those symptoms/signs, and 2) some of them subsequently developed frank bone exposure.

Although most studies define bisphosphonate-associated osteonecrosis of the jaws as an area of long-lasting exposed necrotic bone, the existence of a nonexposed variant of osteonecrosis has been recently suggested.^{2,14-16} The rationale behind this definition is based on the hypothesis that the osteonecrosis might develop within the bone marrow, potentially causing pain, bone enlargement/gingival swelling, and sinus tract due to intrabony edema/inflammation, in the absence of frank mucosal fenestration and bone exposure.¹² Necrotic bone exposure could then occur spontaneously or following exposure to local triggering factors, such as surgery or trauma.

Models of osteonecrosis of the hip¹⁷ and other long bones¹⁸ provide evidence for this hypothesis, which is also supported by recent experimental demonstration of development of nonexposed intrabony medullar necrosis in dogs exposed to bisphosphonates.^{19,20} Only 2 clinical human studies have reported a small number (n = 7) of patients with a nonexposed variant of bisphosphonate-associated osteonecrosis of the jaw. Mawardi et al¹⁵ and Junquera and Gallego¹⁶ described 5 and 2 patients, respectively, who had been exposed to bisphosphonates and subsequently developed pain, bone enlargement/gingival swelling, and tooth mobility with no evidence of necrotic bone exposure and no obvious dental disease. All patients but one showed radiological abnormalities and developed subsequently frank bone exposure.^{15,16} In addition, a transient early stage of bisphosphonate-associated osteonecrosis of the jaws described as nonexposed variant was included in recent classifications.²¹⁻²³

The present case series differs from previous reports because abnormal radiological findings were not considered a necessary diagnostic criterion for bisphosphonate-associated osteonecrosis of the jaws and the nonexposed variant proved to be a separate entity per se in approximately 50% of patients. However, we cannot draw firm conclusions as it cannot be excluded that frank bone exposure would occur at a later time following the onset of nonexposed osteonecrosis. Similarly, as more advanced diagnostic tests such as magnetic resonance imaging and bone scintigraphy were not consistently available, we cannot exclude that early radiological abnormalities could be identified in the affected areas.

Nevertheless, our observations would suggest that the relative frequency of nonexposed versus traditional exposed bisphosphonate-associated osteonecrosis of the jaw is clinically relevant (one third of all osteonecrosis cases observed

at the 5 clinical centers), although further prospective population-based studies are required.

Clinicians should be aware that a significant proportion of patients with bisphosphonate-associated osteonecrosis of the jaw could present with persistent jaw bone pain, bone enlargement, gingival swelling, or sinus tract before or instead of frank bone exposure. Further, only 50% of the cases of nonexposed bisphosphonate-associated osteonecrosis of the jaws would subsequently progress to frank exposed osteonecrosis, and up to one third would show no obvious radiological abnormalities. The impact of these findings upon epidemiological data and the design of future studies could be significant.

ACKNOWLEDGMENT

This work was undertaken at University College London/University College London Hospital, which received a proportion of funding from the Department of Health's National Institute for Health Research Biomedical Research Centre funding scheme.

References

- Migliorati CA, Siegel MA, Elting LS. Bisphosphonate-associated osteonecrosis: a long-term complication of bisphosphonate treatment. *Lancet Oncol.* 2006;7:508-514 (Erratum in: *Lancet Oncol.* 2006;7:533).
- Silverman SL, Landesberg R. Osteonecrosis of the jaw and the role of bisphosphonates: a critical review. *Am J Med.* 2009;122:S33-S45.
- Woo SB, Hellstein JW, Kalmar JR. Narrative (corrected) review: bisphosphonates and osteonecrosis of the jaws. *Ann Intern Med.* 2006;144:753-761 (Erratum in: *Ann Intern Med.* 2006;145:235).
- Edwards BJ, Gounder M, McKoy JM, et al. Pharmacovigilance and reporting oversight in US FDA fast-track process: bisphosphonates and osteonecrosis of the jaw. *Lancet Oncol.* 2008;9:1166-1172.
- Research on Adverse Drug Reactions and Reporting (RADAR). Bisphosphonate associated osteonecrosis of the jaw: FDA AERS search. Available at: <http://cancer.northwestern.edu/radar/yearsONJforadarwebsite.pdf>. Accessed December 13, 2009.
- Vahntsevanos K, Kyrgidis A, Verrou E, et al. Longitudinal cohort study of risk factors in cancer patients of bisphosphonate-related osteonecrosis of the jaw. *J Clin Oncol.* 2009;27:5356-5362.
- Boonyapakorn T, Schirmer I, Reichart PA, et al. Bisphosphonate-induced osteonecrosis of the jaws: prospective study of 80 patients with multiple myeloma and other malignancies. *Oral Oncol.* 2008;44:857-869.
- Bamias A, Kastiris E, Bama C, et al. Osteonecrosis of the jaw in cancer after treatment with bisphosphonates: incidence and risk factors. *J Clin Oncol.* 2005;23:8580-8587.
- Badros A, Terpos E, Katodritou E, et al. Natural history of osteonecrosis of the jaw in patients with multiple myeloma. *J Clin Oncol.* 2008;26:5904-5909.
- Kyrgidis A, Vahntsevanos K. Osteonecrosis of the jaw in patients receiving oral bisphosphonates. *Osteoporos Int.* 2010;21:535-536.
- Assael LA. Oral bisphosphonates as a cause of bisphosphonate-related osteonecrosis of the jaws: clinical findings, assessment of risks, and preventive strategies. *J Oral Maxillofac Surg.* 2009;67:35-43.
- Pazianas M, Miller P, Blumentals WA, Bernal M, Kothawala P. A review of the literature on osteonecrosis of the jaw in patients with osteoporosis treated with oral bisphosphonates: prevalence, risk factors, and clinical characteristics. *Clin Ther.* 2007;29:1548-1558.
- Marx RE, Sawatari Y, Fortin M, et al. Bisphosphonate-induced exposed bone (osteonecrosis/osteopetrosis) of the jaws: risk factors, recognition, prevention, and treatment. *J Oral Maxillofac Surg.* 2005;63:1567-1575.
- Bagan JV, Jimenez Y, Diaz JM, et al. Osteonecrosis of the jaws in intravenous bisphosphonate use: proposal for a modification of the clinical classification. *Oral Oncol.* 2009;45:645-646.
- Mawardi H, Treister N, Richardson P, et al. Sinus tracts—an early sign of bisphosphonate-associated osteonecrosis of the jaws? *J Oral Maxillofac Surg.* 2009;67:593-601.
- Junquera L, Gallego L. Nonexposed bisphosphonate-related osteonecrosis of the jaws: another clinical variant? *J Oral Maxillofac Surg.* 2008;66:1516-1517.
- Malizos KN, Karantanas AH, Varitimidis SE, et al. Osteonecrosis of the femoral head: etiology, imaging and treatment. *Eur J Radiol.* 2007;63:16-22.
- Harreld KL, Marker DR, Wiesler ER, et al. Osteonecrosis of the humeral head. *J Am Acad Orthop Surg.* 2009;17:345-355.
- Allen MR, Kubek DJ, Burr DB. Cancer treatment dosing regimens of zoledronic acid result in near-complete suppression of mandible intracortical bone remodeling in beagle dogs. *J Bone Miner Res.* 2010;25(1):98-105.
- Burr DB, Allen MR. Mandibular necrosis in beagle dogs treated with bisphosphonates. *Orthod Craniofac Res.* 2009;12:221-228.
- American Dental Association Council on Scientific Affairs. Dental management of patients receiving oral bisphosphonate therapy: expert panel recommendations—report of the Council on Scientific Affairs. Available at: www.ada.org/prof/resources/topics/topics_osteonecrosis_bisphosphonate_report.pdf. Accessed November 13, 2009.
- Ruggiero SL, Dodson TB, Assael LA, et al. American Association of Oral and Maxillofacial Surgeons position paper on bisphosphonate-related osteonecrosis of the jaws—2009 update. *J Oral Maxillofac Surg.* 2009;67:2-12.
- McMahon RE, Bouquot JE, Glueck CJ, et al. Staging bisphosphonate-related osteonecrosis of the jaw should include early stages of disease. *J Oral Maxillofac Surg.* 2007;65:1899-1900.