

AperTO - Archivio Istituzionale Open Access dell'Università di Torino

Unusual case of uterine stump pyometra in a cat.

This is the author's manuscript

Original Citation:

Availability:

This version is available <http://hdl.handle.net/2318/85273> since

Published version:

DOI:10.1016/j.jfms.2010.11.013

Terms of use:

Open Access

Anyone can freely access the full text of works made available as "Open Access". Works made available under a Creative Commons license can be used according to the terms and conditions of said license. Use of all other works requires consent of the right holder (author or publisher) if not exempted from copyright protection by the applicable law.

(Article begins on next page)



UNIVERSITÀ DEGLI STUDI DI TORINO

1
2
3
4
5
6
7
8
9
10
11
12
13

This is an author version of the contribution published on:

Questa è la versione dell'autore dell'opera:

[Journal of Feline Medicine and Surgery, 13 (6), 2011, doi:
10.1016/j.jfms.2010.11.013.]

The definitive version is available at:

La versione definitiva è disponibile alla URL:
[<http://jfm.sagepub.com/content/13/6/448.long>]

14
15
16
17
18
19
20
21
22
23
24
25
26
27
28

Unusual case of uterine stump pyometra in a cat

Ada Rota DVM, PhD, Dipl ECAR, ^{1*}

Paola Pregel, MS, PhD, ¹

Francesca T Cannizzo, MS, PhD, ¹

Alessandra Sereno, ¹

Simonetta Appino DVM, PhD ²

¹ *Dipartimento di Patologia Animale, via Leonardo da Vinci, 44, 10090 Grugliasco, Torino, Italy*

² *Dipartimento di Patologia e Clinica Veterinaria, via Vienna 2, 07100 Sassari, Italy*

* Corresponding Author, email address: ada.rota@unito.it

29
30
31
32
33
34
35
36
37
38
39
40

Summary

This report describes an unusual case of uterine stump pyometra in a cat, in which the main symptom at presentation was abdominal straining. At the time of ovariohysterectomy, the surgeon reported that uterine body had a purulent content. About one month after surgery the cat showed abdominal straining. The enlarged uterine stump, filled with purulent fluid, had caused compression of the rectum and secondary intestinal sub-occlusion. Surgical revision consisted in draining the purulent content of the remnant of the uterine body and ablating as much of it as possible; checking of the ovarian pedicles revealed the presence of a small fragment of whitish tissue on the right side, which was shown to contain, by means of histological observation and immunohistochemical staining, ovarian tissue. Four months after surgical revision the cat did not show any pathological sign and he is healthy after one year.

41 At the end of July 2009 an 8-month-old spayed mixed breed queen, living indoors with free access
42 to the outdoors, was taken to the Veterinary Teaching Hospital of The Faculty of Veterinary
43 Medicine of Turin University because of worsening of abdominal straining, a condition that had
44 appeared about three weeks after ovariectomy. The cat had also shown reduced appetite and
45 activity. Ovariectomy had been performed about 6 weeks earlier and the practitioner had
46 reported that uterus had a purulent content. Two weeks after surgery the queen had shown enlarged
47 mammary glands and milk secretion, and cabergoline (5 µg/kg) had been administered for 5 days.
48 The cat appeared in quite good condition, alert and not dehydrated. Abdominal palpation was not
49 painful but revealed the presence of a highly distended colon with soft content. The hypothesis of
50 an intestinal sub-occlusion, which was the cause of the straining reported by the owner was
51 confirmed by a radiological exam (Fig. 1). Abdominal ultrasound revealed the presence of a fluid-
52 filled structure referable to a uterine stump, measuring 3.7x2.6 cm, compressing the rectum
53 dorsally. Cell blood count, biochemical parameters (aspartate aminotransferase, alanine
54 aminotransferase, creatine kinase, γ-glutamyltransferase, creatinine, urea, glucose, total bilirubin,
55 triglycerides, total cholesterol, alkaline phosphatase, amylase and lipase) and total serum protein
56 were within normal limits. Feline leukaemia virus and feline immunodeficiency virus tests were
57 negative. A surgical revision was suggested in order to eliminate the cause of the obstruction. After
58 sedation, anaesthesia was induced with propofol and maintained with isoflurane in oxygen.
59 A median ventral laparotomy revealed the presence of an enlarged uterine stump, with
60 granulomatous tissue and adhesions to the bladder. Grossly, the uterine wall appeared thinned and
61 the uterine lumen showed a conspicuous amount of purulent exudate, which was drained. A sample
62 was taken for culture and sensitivity testing. The remnant of uterine tissue was removed as
63 completely as possible. Bilateral exploration of the abdomen, from the caudal pole of each kidney
64 to the uterine stump was performed and an increased vascularisation of the right ovarian pedicle
65 was detected, together with the presence of a small fragment of whitish tissue which was removed
66 for histological examination. At the end of the surgical procedure an enema consisting of warm
67 water and mineral oil was administered. Two more enemas were administered during the following
68 days, and the intestinal functionality was re-established. The cat was treated with amoxicillin-
69 clavulanic acid (12.5 mg/kg BID), a therapy that was confirmed after culture results and
70 antimicrobials susceptibility tests (β-haemolytic *Streptococcus* sp.). Recovery was uneventful.
71 Histopathological examination of the fragment of tissue removed from the right ovarian pedicle
72 showed a mild inflammatory process with presence of haemorrhagic areas and scar tissue with
73 fibroblasts. Other areas were characterized by the presence of both small cells with uniform round
74 or oval hyperchromatic nuclei with finely granular chromatin, resembling granulosa cells, and
75 larger cells with *round* or oval nuclei and cytoplasmic vacuolization resembling luteal cells (Fig.
76 2a).
77 Histopathological examination of the uterine stump revealed a mild cystic endometrial hyperplasia ,
78 meanwhile a diffuse chronic inflammatory infiltrate was present in all layers of uterine wall.
79
80 In order to confirm the hypothesis of ovarian remnant, 4µ-thick sections from the tissue fragment
81 were subjected to immunohistochemistry with anti-progesterone receptor (PR) and anti-aromatase
82 antibodies. PR expression is selectively induced in granulosa cells of preovulatory follicles by LH¹⁻³
83 and persists in the corpus luteum of the ovary.^{4,5} Aromatase is a key enzyme in ovarian
84 steroidogenesis and plays an important role in sexual differentiation, oestrogen biosynthesis,
85 fertility and carcinogenesis. It is highly conserved amongst mammals and it is expressed in
86 granulosa cells and participates in conversion of androgens to oestrogens.⁶
87 The tissue fragment removed from the right ovarian pedicle showed a positive staining for both PR
88 and aromatase. In particular, nuclei of putative granulosa cells stained strongly positive for PR,
89 while putative luteal cells showed a mild cytoplasmic staining (Fig. 2b). Immunohistochemistry for
90 aromatase showed a diffuse cytoplasmic immunoreactivity in several areas where both granulosa
91 and luteal cells were detected (Fig. 2c).

92 The reported findings suggested the presence of ovarian tissue in the fragment.
93

94 Four months after surgical revision, the cat had gained weight and the owner reported that no
95 pathological signs had occurred since. At ultrasound the uterine stump was appreciable as a small
96 (1x0.5 cm) hyperechoic area dorsal to the bladder which was interpreted as fibrosis. To this day (i.e.
97 about one year later) the cat has been healthy.
98

99 In cats uterine stump pyometra is reported to occur in neutered queens either in case of ovarian
100 remnants or following administration of progestagens.^{7,8} Ovarian remnant syndrome is usually
101 diagnosed when a previously spayed queen shows recurrent behavioural signs of oestrous.^{9,10} In our
102 case, the cat had been in heat for the first time at about 6 months of age, but neither signs of oestrus
103 were present after ovariohysterectomy, nor she had ever received progestagens. The interval
104 between ovariohysterectomy and uterine stump pyometra diagnosis was around 40 days; our
105 hypothesis is that uterine stump pyometra was sustained by the presence of functional ovarian luteal
106 tissue. The duration of luteal function is about 40-50 days in the non pregnant queen,¹¹ and, in our
107 case, the luteal tissue localized in the examined fragment could represent the remnant of old corpora
108 lutea. We believe that ovarian luteal tissue maintained the conditions of endometrial hyperplasia
109 and increase of the secretory activity of the endometrial glands,^{7,12} which allowed the
110 persistence/recurrence of the uterine infection. We did not measure serum progesterone
111 concentration at the moment of surgical revision, but, according to our hypothesis, it could have
112 been low or around basal. From the history of the queen, we know that she had been treated with
113 cabergoline because of mammary secretion following ovariohysterectomy: the prolactin increase
114 causing milk secretion is likely to have been induced by a sharp decline in progesterone
115 concentration, and this means that the queen had ovulated and had corpora lutea on ovaries when
116 she had undergone ovariohysterectomy. In cats cabergoline has an antiprolactinic action and
117 induces abortion¹³ by means of a slow (3-4 days) reduction in plasma progesterone concentration¹⁴.
118 After the end of cabergoline effect, residual luteal tissue may have regained functionality. However,
119 we can not exclude that the observed condition might have developed also in the absence of
120 functional luteal tissue: in fact, although a correlation between pyometra and corpora lutea presence
121 has been observed in cats,⁸ cats with pyometra may also have low serum progesterone concentration
122 because the effects of progesterone on uterine mucosa and glands may persist beyond the end of the
123 luteal phase.⁷
124

125 **Acknowledgments**

126

127 The authors are grateful to the Centro di Referenza di Patologia Comparata 'Bruno Maria Zaini' for
128 the skilful assistance.
129

130 **References**

131

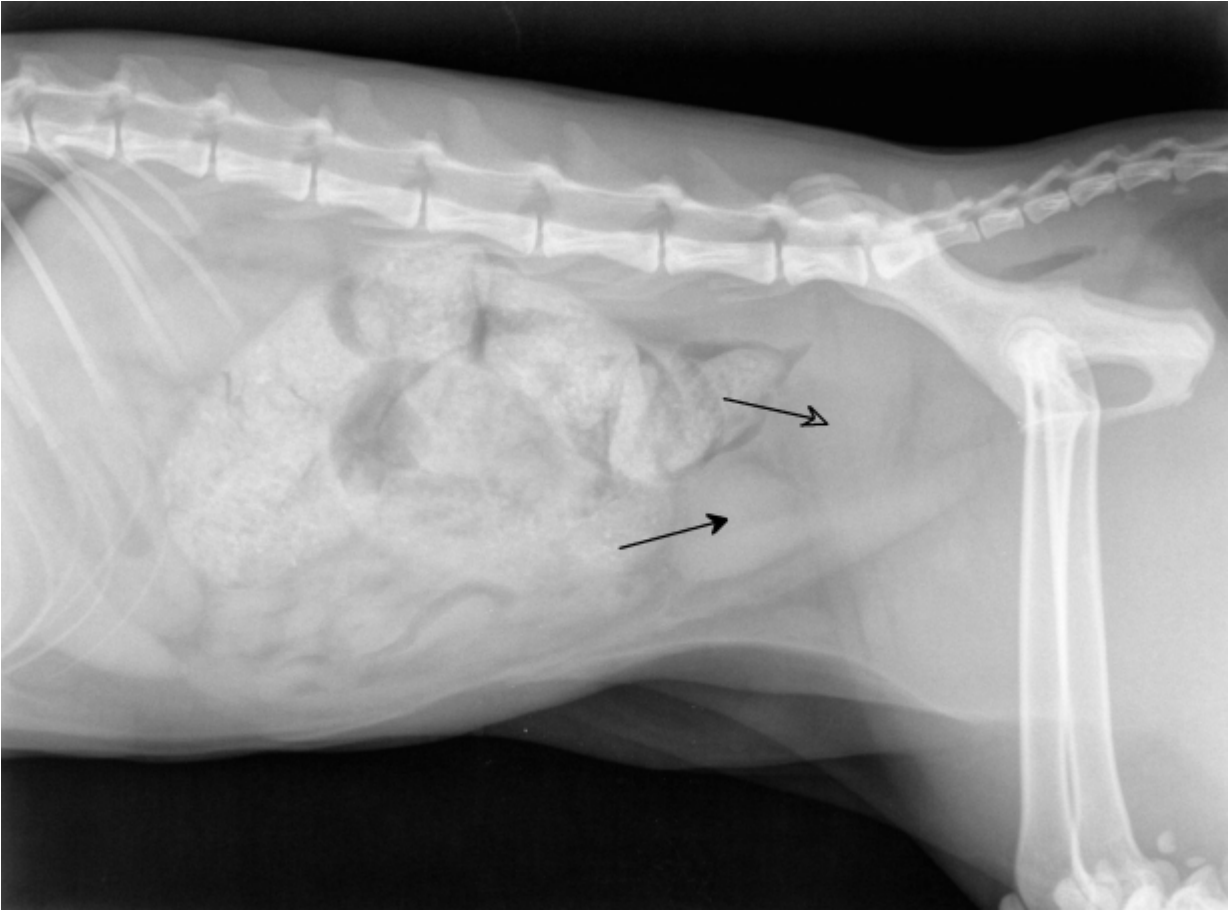
- 132 1. Park O-K, Mayo K. Transient expression of progesterone receptor messenger RNA in
133 ovarian granulosa cells after the preovulatory luteinizing hormone surge. *Mol Endocrinol*
134 1991; **5**: 967-78.
- 135 2. Natraj U, Richards JS. Hormonal regulation, localization and functional activity of the
136 progesterone receptor in granulosa cells of rat preovulatory follicles. *Endocrinology* 1993;
137 **133**: 761-9.
- 138 3. Park-Sarge O-K, Parmer TG, Gu Y, Gibori G. Does the rat corpus luteum express the
139 progesterone receptor gene? *Endocrinology* 1995; **136**: 1537-43.
- 140 4. Shao R, Markström E, Friberg P, Johansson M, Billig H. Expression of progesterone
141 receptor (PR) A and B isoforms in mouse granulosa cells: stage-dependent PR-mediated
142 regulation of apoptosis and cell proliferation. *Biol Reprod* 2003; **68**: 914 -21.

- 143 5. Press MF, Greene GL. Localization of progesterone receptor with monoclonal antibodies to
144 the human progestin receptor. *Endocrinology* 1988; **122**: 1165–75.
- 145 6. Tsonis CG, Carson RS, Findlay JK. Relationships between aromatase activity, follicular
146 fluid oestradiol 17_ beta and testosterone concentrations, and diameter and atresia of
147 individual ovine follicles. *J Reprod Fertil* 1984; **72**: 152– 63.
- 148 7. Johnston SD, Root Kustritz MV, Olson PNS. Disorders of the Feline Uterus and Uterine
149 Tubes. In: Johnston SD, Root Kustritz MV, Olson PNS. *Canine and Feline Theriogenology*.
150 1st edn. Philadelphia, Saunders, 2001: 463-71.
- 151 8. Agudelo CF. Cystic endometrial hyperplasia-pyometra complex in cats. *Vet Quart* 2005; **27**:
152 173-82.
- 153 9. Wallace MS, 1991. The ovarian remnant syndrome in the bitch and queen. *Vet Clin North*
154 *Am Small Anim Pract*; **21**, 501-7.
- 155 10. Miller DM. Ovarian remnant syndrome in dogs and cats: 46 cases (1988-1992). *J Vet Diagn*
156 *Invest* 1995; **7**: 572-4.
- 157 11. Paape SR, Shille VM, Seto H, Stabenfeldt GH. Luteal activity in the pseudopregnant cat.
158 *Biol Reprod* 1975; **13**: 470-4.
- 159 12. Lawler DF, Evans RH, Reimers TJ, Colby ED, Monti KL. Histopathologic features,
160 environmental factors, and serum estrogen, progesterone, and prolactin values associated
161 with ovarian phase and inflammatory uterine disease in cats. *Am J Vet Res* 1991;**52**:1747–
162 53.
- 163 13. JöchleW, Arbeiter K, Post K, Ballabio R, D’Ver AS. Effects on pseudopregnancy,
164 pregnancy and interoestrous intervals of pharmacological suppression of prolactin secretion
165 in female dogs and cats. *J Reprod Fertil Suppl* 1989;**39**:199–207
- 166 14. Verstegen JP, Onclin K, Silva LD, Donnay I. Abortion induction in the cat using
167 prostaglandin F2 alpha and a new anti-prolactinic agent, cabergoline. *J Reprod Fertil Suppl*.
168 1997;**51**:259-63.
- 169
170
171

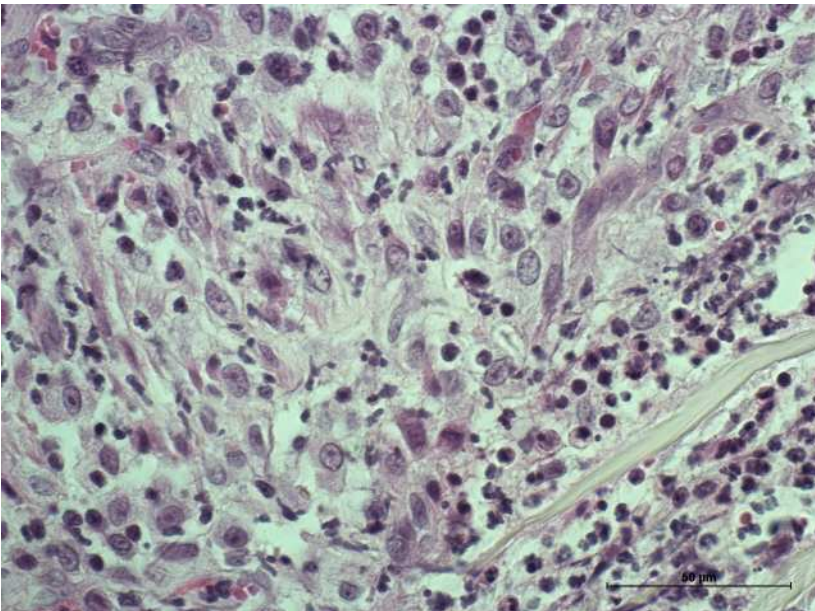
172 Fig 1. Right lateral radiographic projection showing distended colon and rectum and enlarged
173 uterine stump (open arrow) dorsal to the bladder (closed arrow).

174 Fig. 2 a: Microphotograph of the fragment of tissue removed from the right ovarian pedicle showing
175 the presence of both small cells with uniform round or oval hyperchromatic nuclei with finely
176 granular chromatin, resembling granulosa cells, and larger cells with round or oval nuclei and
177 cytoplasmic vacuolization resembling luteal cells (H.E. 60x); b: PR immunostaining in the tissue
178 fragment, showing strongly positive nuclei of putative granulosa cells (60x); c: Aromatase
179 immunostaining in the tissue fragment, showing a diffuse cytoplasmic immunoreactivity in both
180 granulosa and luteal putative cells (40x)

181

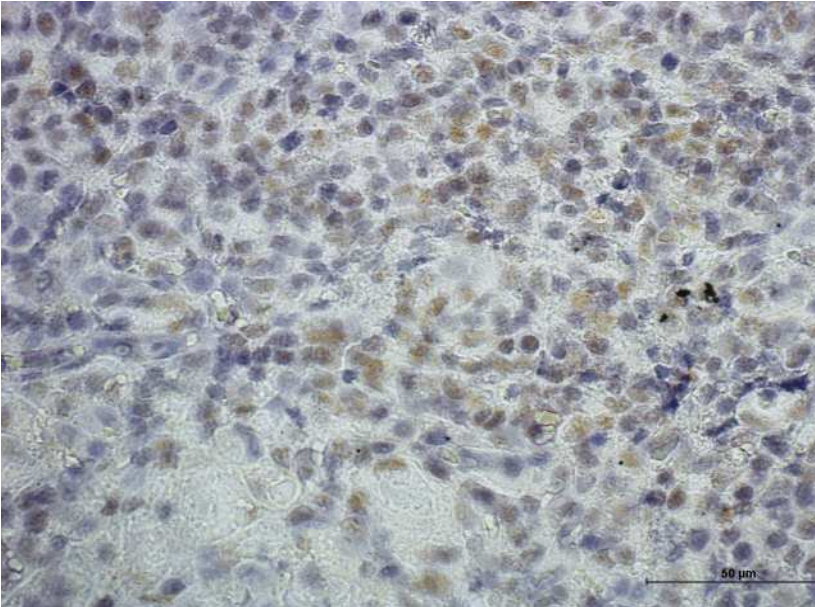


182
183
184
185



186

187



188

