

AperTO - Archivio Istituzionale Open Access dell'Università di Torino

The impact of plasma rich in growth factors on clinical and biological factors involved in healing processes after third molar extraction

This is the author's manuscript

Original Citation:

Availability:

This version is available <http://hdl.handle.net/2318/131533> since 2019-04-30T10:04:08Z

Terms of use:

Open Access

Anyone can freely access the full text of works made available as "Open Access". Works made available under a Creative Commons license can be used according to the terms and conditions of said license. Use of all other works requires consent of the right holder (author or publisher) if not exempted from copyright protection by the applicable law.

(Article begins on next page)

The impact of plasma rich in growth factors on clinical and biological factors involved in healing processes after third molar extraction

Marco Mozzati,¹ Germana Martinasso,² Renato Pol,¹ Carolina Polastri,¹ Antonio Cristiano,¹ Giuliana Muzio,² Rosa Canuto²

¹Oral Surgery Unit, Dentistry Section, Department of Biomedical Sciences and Human Oncology, University of Turin, Turin, Italy

²Department of Experimental Medicine and Oncology, University of Turin, Turin, Italy

Received 23 December 2009; accepted 10 May 2010

Published online 19 August 2010 in Wiley Online Library (wileyonlinelibrary.com). DOI: 10.1002/jbm.a.32882

Abstract: Extraction of an impacted mandibular third molar is a common surgical procedure, although it still leads to several postoperative symptoms and complications. The study assessed the efficacy of autologous plasma rich in growth factors (PRGF) in the healing process by checking the difference of tissue cytokines and other healing factors produced by the mucosa after extraction between sites treated with PRGF and control sites and, at the same time, by evaluating the clinical efficacy of PRGF in terms of reduced pain and facial swelling. This study was a split-mouth study, in which the patient becomes his/her own control, to eliminate any individual response differences toward PRGF treatment. The parameters regarding inflammation and

subsequent wound healing were all significantly higher at PRGF sites than at control sites. The increase at PRGF sites of the two proinflammatory cytokines evaluated, interleukin (IL)-1 β and IL-6, was accompanied by the increase of two anti-inflammatory cytokines, IL-10 and transforming growth factor- β . Furthermore, IL-1 β and IL-6 induce fibroblast and keratinocyte proliferation, important events in wound healing. Postoperative pain and the swelling, measured at all experimental times, were reduced in the presence of PRGF. © 2010 Wiley Periodicals, Inc. *J Biomed Mater Res Part A*: 95A: 741–746, 2010.

Key Words: PRGF, third molar, cytokines, BMP, collagen

INTRODUCTION

Extraction of an impacted mandibular third molar is a common procedure in oral and maxillofacial surgery. Despite the development of new techniques and materials, this kind of surgery still leads to several postoperative symptoms and complications, with temporary alterations in the patient's quality of life. In the first week after surgery, pain, swelling, and trismus are frequent symptoms, sometimes with marked functional alteration. Alveolitis, infection, and hemorrhage are other common postoperative complications.^{1–4}

To reduce the risk of complications, researchers and clinicians are advancing rapidly toward treatments that reduce morbidity while enhancing functional recovery. An important example is the development of platelet-rich therapies. The use of blood-derived products to seal wounds and stimulate healing was first described by Kingsley,⁵ who used an autologous platelet-derived preparation called platelet-rich plasma (PRP) to promote/accelerate wound cicatrization. The first application of an autologous fibrin glue in oral surgery was reported in 1994 by Tayapongsak et al.,⁶ who used autologous fibrin adhesive as a medium for compacting grafts. The emergence and application of these platelet-enriched preparations have revolutionized the field of regenerative medicine, thanks to the repair capacities of the growth factors and other proteins secreted by platelets.

In 1997, Whitman et al.⁷ used platelet gel in reconstructive maxillofacial surgery. Marx et al.⁸ was the first to standardize the technique for using PRP, a volume of autologous plasma with a platelet concentration above baseline, activated by bovine thrombin and calcium chloride. The monoclonal antibody technique has revealed the presence of transforming growth factor (TGF)- β 1, TGF- β 2, and platelet-derived growth factor (PDGF) in PRP.^{7,8} In the last few years, PRP has been widely used in oral surgery, alone or with various graft materials, to accelerate and facilitate tissue and bone regeneration.⁹ Anitua et al.^{10–13} introduced a new protocol for platelet gel preparation, producing the so-called plasma rich in growth factors (PRGF). PRGF is considered an optimized and safe product, which circumvents many of the limitations entailed in the use of other PRPs. For example, its preparation does not require large amount of blood as does that of PRP, and it does not use exogenous bovine thrombin as activator, obviating immunological reactions and risk of disease transmission. These platelet gels are highly concentrated forms of autogenous platelets, known for their role in hemostasis, where they prevent blood loss at sites of vascular injury. They do so by adhering, aggregating, and forming a procoagulant surface leading to thrombin generation and fibrin formation. Platelets also release substances that promote tissue repair and influence the reactivity of vascular and other blood cells in

Correspondence to: R. A. Canuto; e-mail: rosangela.canuto@unito.it
Contract grant sponsor: Regione Piemonte and University of Turin, Italy

angiogenesis and inflammation. The alpha granules of platelets contain storage pools of growth factors, including platelet-derived growth factor, vascular endothelial growth factor, transforming growth factor- β , epidermal growth factor, insulin-like growth factor, and fibroblast growth factor, as well as extracellular matrix components, such as fibronectin, thrombospondin, and vitronectin. Chemokines and newly-synthesized active metabolites are also released. The fact that platelets secrete growth factors and active metabolites means that their applied use can have a positive influence in clinical situations requiring rapid healing and tissue regeneration.

The effect of local application of a scaffold-like preparation rich in growth factors (PRGF) was investigated: PRGF has been shown to accelerate bone regeneration in artificial defects and to improve the osseointegration of titanium dental implants.¹⁴ Orthopedic surgery, muscle and/or tendon repair, treatment of joint diseases, reversal of skin ulcers, and hole repair in eye surgery and cosmetic surgery are other situations where autologous platelets accelerate healing.^{11-13,15}

The aim of this split-mouth study was to assess the efficacy of autologous PRGF in the healing process after third molar extraction. This was addressed by verifying the difference in tissue cytokines and other healing factors produced by the mucosa after extraction between sites treated with PRGF and control sites and, at the same time, by evaluating the clinical efficacy of PRGF treatment. No studies, in particular not of the split-mouth type, have yet examined the production of biological factors at sites treated with PRGF after impacted third molar extraction while evaluating clinical aspect, such as pain and facial swelling.

MATERIALS AND METHODS

Sixteen healthy patients, aged 18 to 35 years (mean 22.5 years), with impaction of both lower third molars and indications to their extraction, entered the study. Patient selection was based on the absence of any local or systemic disease that might contraindicate the treatment. Informed consent was obtained from all patients entering the study.

Preparation of PRGF

Blood was obtained several minutes before starting surgery, prior to administration of anesthesia. Ten to twenty milliliters of blood were drawn from each patient using 5-mL tubes, containing 3.8% trisodium citrate solution as anticoagulant. The tubes were centrifuged at 1800 rpm for 8 min (PRGF Sistem®, BTI Biotechnology Institute, Milan, Italy) at room temperature. The blood was, thus, separated into its three basic components: red blood cells, which appeared at the bottom of the tube, PRGF in the middle of the tube, and plasma poor in growth factors (PPGF) at the top of the tube. The fraction (0.5 mL) located immediately above the erythrocytes was collected from each tube and transferred to sterile tubes. Calcium chloride (50 μ L) at 10% was added per 1-mL fraction of PRGF. After 15 to 20 min, a PRGF gel was formed. The time delay between PRGF gel formation and filling the defect was standardized to 5 to 10 min.

Surgical protocol

Both the mandibular third molars were extracted in the same surgical session. After truncular and locoregional anesthesia (mepivacaine 2% with adrenaline 1:100,000), a full-thickness mucoperiosteal flap was raised. Osteotomy was first performed using a Lindeman burr in conjunction with constant irrigation, followed by odontotomy and, if necessary, tooth luxation and avulsion.

In each patient, one postextractive defect was filled with PRGF whereas the other was left empty as control site. Left and right sockets were assigned randomly. This provided the best possible control group, because both treatments were carried out in the same patient, with the same surgical procedure and identical microbiologic conditions, and by the same surgeon. In all cases, 3-0 silk sutures were used to stitch the flap; they were removed after 7 days. Patients were given antibiotic (amoxicillin every 12 h for 6 days) and oral anti-inflammatory treatment (nimesulide every 12 h for 3 days).

Samples of soft tissues were removed from around the tooth at the following times: before tooth extraction (T0) and after 7 days (T7). All specimens were placed in RNA-later solution (Qiagen, Milan, Italy), and maintained at -80°C until use.

Biological factor analysis

The samples were processed to determine cytokines and protein expression using real-time polymerase chain reaction (PCR). The inflammatory cytokines interleukin (IL)-1 β , IL-6, IL-10, TGF- β 2, bone morphogenetics protein (BMP)-4 and BMP-7, peroxisome proliferator-activated receptor (PPAR)- β , and collagen type I and type III were examined.

Total ribonucleic acid (RNA) was extracted from the specimens using the NucleoSpin RNA II Kit (Macherey-Nagel GmbH & Co., KG, Düren, Germany). Real-time PCR was performed with single-stranded complementary deoxyribonucleic acid (cDNA) prepared from total RNA (1 μ g) using a high-capacity cDNA archive kit (Applied Bio Systems, Foster City, CA).

The forward (FW) and reverse (RV) primers listed in Table I were designed using the Beacon Designer® program (Bio-Rad, Hercules, CA). Twenty-five microliters of a PCR mixture containing cDNA template equivalent to 40 ng of total RNA, 5 pmoles each of FW and RW primers, and $2 \times$ IQ SYBR Green SuperMix (Bio-Rad) were amplified using an iCycler PCR instrument (Bio-Rad) with an initial melt at 95°C for 10 min, followed by 35 to 40 cycles at 95°C for 40 s, annealing temperature for each primer set for 40 s, and 72°C for 40 s. A final extension of 7 min at 72°C was applied. Each sample was tested in duplicate, and threshold cycle (Ct) values were averaged from each reaction. The fold change, for both control and PRGF samples, was defined as the relative expression in the sample removed 7 days after the extraction of teeth (T7) compared with that in the sample removed before the extraction (T0), calculated as $2^{-\Delta\Delta\text{Ct}}$, where $\Delta\text{Ct} = \text{Ct}_{\text{sample}} - \text{Ct}_{\text{GAPDH}}$ and $\Delta\Delta\text{Ct} = \Delta\text{Ct}_{\text{T7sample}} - \Delta\text{Ct}_{\text{T0sample}}$.

TABLE I. Forward and Reverse Primers

| Gene, Accension Number | Sequence | Annealing Temperature (°C); No. Cycles | Product Length (bp) |
|------------------------------|---|--|---------------------|
| GAPDH, NM_002046 | FW 5'-GTC GGA GTC AAC GGA TTT GG-3' RV 5'-GGG TGG AAT CAT ATT GGA ACA TG-3' | 52; 35× | 142 |
| IL-1 β , AF043335 | FW 5'-GCA CCT TCT TTC CCT TCA TCT TT-3' RV 5'-GCG TGC AGT TCA GTG ATC GTA-3' | 52; 40× | 105 |
| IL-6, M14584 | FW 5'-CCA GTA CCC CCA GGA GAA GAT T-3' RV 5'-GTC AAT TCG TTC TGA AGA GGT GAG T-3' | 52; 40× | 78 |
| IL-10, AY029171 | FW 5'-CCG AGA TGC CTT CAG CAG AG-3' RV 5'-CAT CAC CTC CTC CAG GTA AAA CT-3' | 60; 30× | 154 |
| TGF- β 2, NM_003238 | FW 5'- GAG TAC TAC GCC AAG GAG GTT TAC A-3' RV 5'-CGA ACA ATT CTG AAG TAG GGT CTG T-3' | 52; 40× | 104 |
| BMP-4, D30751 | FW 5'-CTC GCT CTA TGT GGA CTT C-3' RV 5'-ATG GTT GGT TGA GTT GAG G-3' | 58; 40× | 130 |
| BMP-7, NM_001719 | FW 5'-GTG GAA CAT GAC AAG GAA T-3' RV 5'-GAA AGA TCA AAC CGG AAC-3' | 58; 40× | 65 |
| PPAR- β , XM_165760 | FW 5'-AAA GAA GGC CCG CAG CAT-3' RV 5'-CTG GAT GTC GTG GAT CAC AAA-3' | 56; 40× | 170 |
| Collagen type I, NM_000089 | FW 5'-GAG GAA ACT GTA AGA AAG G-3' RV 5'-GTT CCC ACC GAG ACC-3' | 58; 35× | 150 |
| Collagen type III, NM_000090 | FW 5'-ACT CGC CCT CCT AAT GG-3' RV 5'-GGC ATG ATT CAC AGA TTC C-3' | 59; 35× | 148 |

Clinical evaluation

For the clinical examination, the patient was asked to score his/her feeling of pain on a 10-cm visual analog scale (VAS), with 0 cm reflecting no pain and 10 cm reflecting worst pain possible. The pain was evaluated each day at the same hour from 2 h after extraction (T1) to day 7 (T7) in the postoperative period. At the same time, the patient was asked to measure facial swelling, with the exception of the first and seventh measures, which were done by a dentist. Facial swelling was evaluated using a horizontal and vertical guide with a flexible ruler and a vernier caliper, and the control points described by Neupert et al.¹⁶ The facial measures corresponded to mentalis angle (Go) and 4 facial points indicating the angle of the mandible: (1) ear tragus (Tr), (2) external canthal of the eye (Ca), (3) nose spine (Sp), and (4) buccal commissure (Po). The facial swelling score was obtained by dividing the measures made in the postoperative period (day 2–7) by the value for the preoperative period (T0).

Statistical analysis

Statistical analyses were performed using InStat3 software. All data are expressed as means \pm standard deviation (SD). The significance of differences between control and PRGF mean values was assessed by the nonparametric Wilcoxon test. Data were statistically significant when $p < 0.05$.

As regards facial swelling, the collected data were analyzed using the Wilcoxon signed rank test. The level of significance applied was 5.0%.

RESULTS

Sixteen healthy patients, aged between 18 and 35 years with both impacted lower third molars requiring extraction, comprised the study group. There was no significant differ-

ence between the two operations in each individual patient, as regards duration of surgery and amount of local anesthetic administered.

Biological factor analysis

Figures 1–4 report the data relating to various biological factors that are involved in the healing of wounds caused by tooth extraction, and show the differences between the PRGF site and control site. The data refer to T7 and were compared with those obtained at T0, taken as 1 (black line in the figures).

As shown in Figure 1, IL-1 β , IL-6, and IL-10 increased at the site treated with PRGF in comparison with the control site at 7 days after extraction, the increase for IL-1 β being about five times the control value, IL-6 about three times and IL-10 about twice. On the contrary, the increase of TGF-

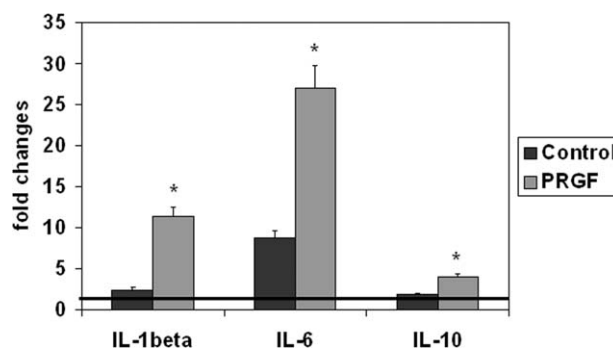


FIGURE 1. IL-1 β , IL-6, and IL-10 values in PRGF and control sites at T7. Control and PRGF values at T7 are compared with their respective T0 values (black line). The values are means \pm SD of 16 patients. The significance of differences between control and PRGF means was assessed by nonparametric Wilcoxon test (* $p < 0.05$ PRGF vs. control).

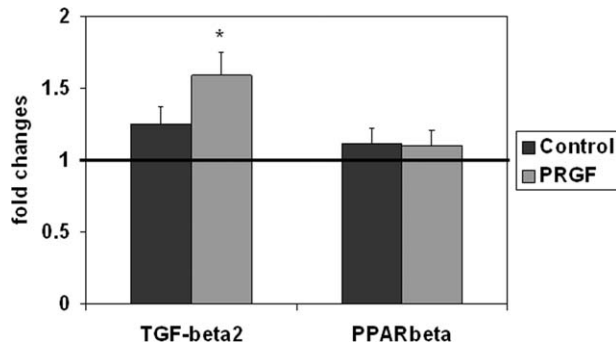


FIGURE 2. TGF-β2 and PPAR-β values in PRGF and control sites at T7. Control and PRGF values at T7 were compared with their respective T0 values (black line). The values are means ± SD of 16 patients. The significance of differences between control and PRGF means was assessed by nonparametric Wilcoxon test (* $p < 0.05$ PRGF vs. control).

β2 (Fig. 2), as also that of BMP-4 and BMP-7 (Fig. 3), at sites treated with PRGF in comparison with control sites, was lower than the increase in ILs, being about 1.30, 1.20, and 1.5 times for TGF-β2, BMP-4, and BMP-7, respectively. For PPAR-β, no increase was observed.

Collagen I and III (Fig. 4) increased at sites treated with PRGF in comparison with the control sites, as occurred in the case of cytokines, the increase for collagen I (~3.6 times the control value) being greater than that for collagen III (~3 times the control value). Comparing the changes in collagen I and III, the latter was changed more than the former: 12 versus 7.

Clinical evaluation

The VAS of pain was lower for PRGF sites than for control sites at all times examined, even if the difference was significant only at T7 (Fig. 5).

Figure 6 shows the difference in facial swelling between PRGF sites and control sites. At the PRGF sites, there was less swelling than at the control sites; the difference was significant for all the four measures, Go-Ca, Go-Tr, Go-Po,

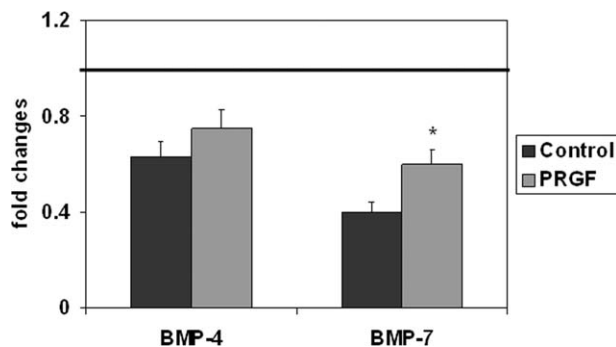


FIGURE 3. BMP-4 and BMP-7 values in PRGF and control sites at 7 days after surgery. Control and PRGF values at 7 days were compared with their respective T0 values (black line). The values are means ± SD of 16 patients. The significance of differences between control and PRGF means was assessed by nonparametric Wilcoxon test. (* $p < 0.05$ PRGF vs. control).

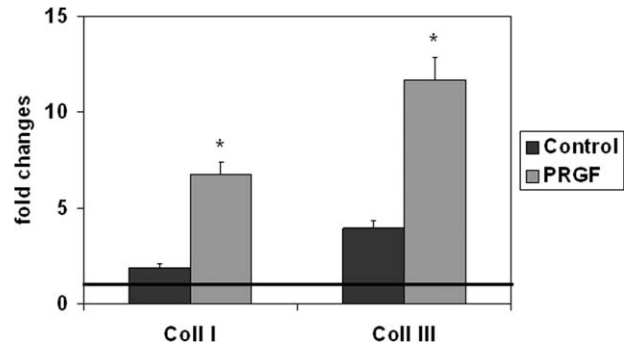


FIGURE 4. Collagen I and III values in PRGF and control sites at 7 days after surgery. Control and PRGF values at 7 days were compared with the respective T0 values (black line). The values are means ± SD of 16 patients. The significance of differences between control and PRGF means was assessed by nonparametric Wilcoxon test (* $p < 0.05$ PRGF vs. control).

and for Go-Sp, with the exception of time T7 for Go-Tr and Go-Po.

DISCUSSION

Surgery of impacted third molars is one of the most frequent procedures in oral and maxillofacial surgery¹⁻⁴ and can lead to immediate postoperative pain and discomfort.¹⁻⁴ Trismus is a direct sequel of postoperative swelling, which can compress nerve structures and generate mild to severe pain.^{17,18} Thus, it appeared that, in addition to the use of analgesics, PRGF might improve wound healing after third molar extraction and, at the same time, reduce pain and swelling. A significant problem with this experimental approach is designing appropriate control groups. To avoid this problem, this study employed a “split-mouth” method, whereby one side of each patient was included in the control group, and the other side (randomly selected) was in the PRGF group. In this model of split-mouth study, the patient becomes his/her own control, to eliminate any individual response differences toward PRGF treatment.

The parameters regarding the inflammation process and subsequent wound healing were all significantly higher at

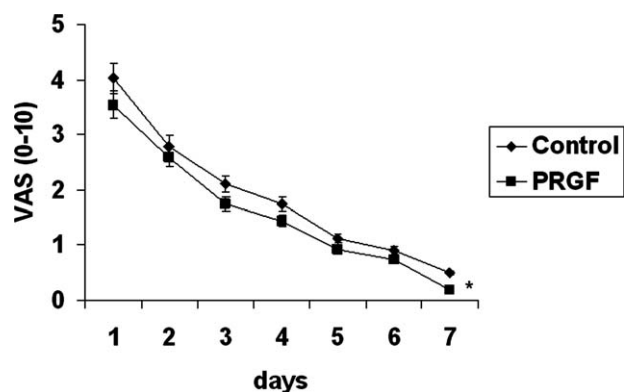


FIGURE 5. VAS for pain measurement in PRGF and control sites. Values are means ± SD of 16 patients. The significance of differences between control and PRGF means was assessed by nonparametric Wilcoxon test (* $p < 0.05$ PRGF vs. control).

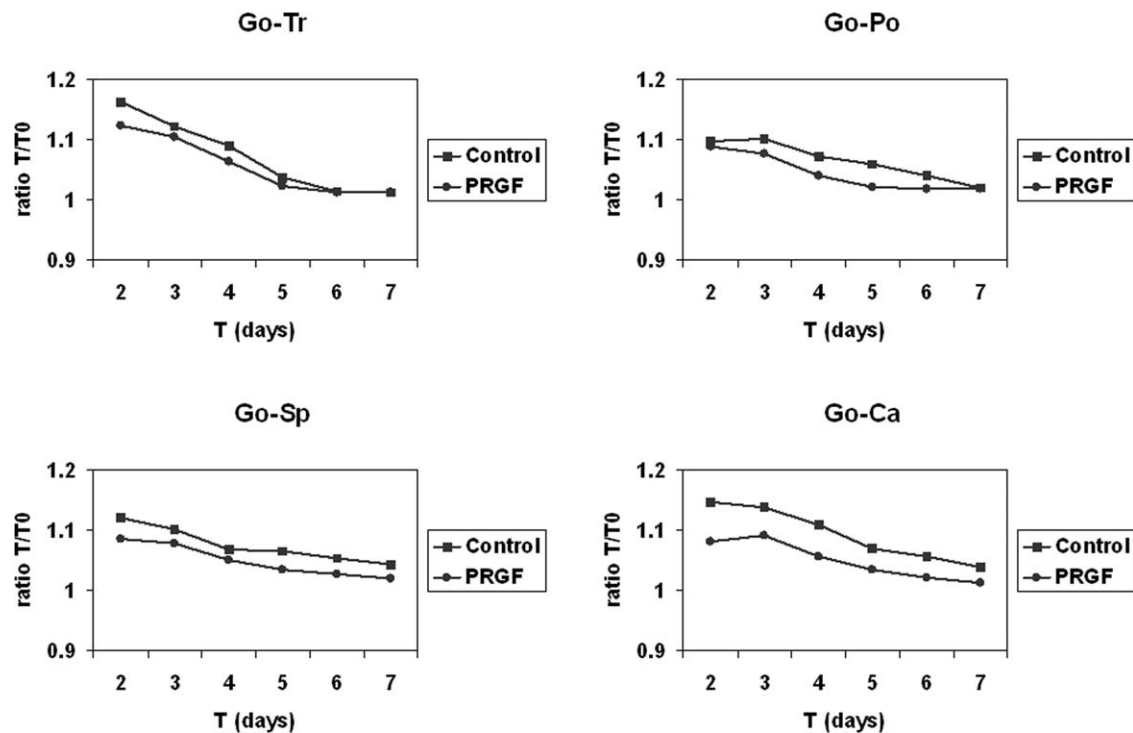


FIGURE 6. Measures of facial swelling for PRGF and control sites. Values are means \pm SD of 16 patients. The collected data were analyzed using the Wilcoxon of signed rank test. The level of significance was 5.0% for all four measures, Go-Ca, Go-Tr, Go-Po, and for Go-Sp, with exception of the T7 values for Go-Tr and Go-Po. Go-Tr, mentalis angle-ear tragus; Go-Po, mentalis angle-buccal commissure; Go-Sp, mentalis angle-nose spine; Go-Ca, mentalis angle-external canthal of the eye.

PRGF sites than at control sites. It might seem surprising that inflammation parameters, such as IL-1 β and IL-6, were found at higher levels at PRGF sites than at control sites. Two possible explanations can be done: 1. IL-1 β and IL-6 could facilitate wound healing, as demonstrated by the increase in collagen I and III. In fact, in addition to its principal pro-inflammatory activity, IL-1 β can also stimulate fibroblast proliferation, collagen synthesis and the production of collagenases, implicated in collagen remodeling during wound healing.¹⁹ IL-6 also shows slight anti-inflammatory activity,²⁰ inducing keratinocyte proliferation and inhibiting pro-inflammatory cytokines.²¹ Thus the involvement of IL-1 β and IL-6 on facilitating wound healing must be also considered as a possibility, based on their stimulation of fibroblast and keratinocyte proliferation. 2. At the PRGF sites, the increase of IL-1 β and IL-6 was also accompanied by the increase in IL-10 and TGF- β 2, two cytokines possessing anti-inflammatory activity and inducing fibroblast proliferation.¹⁹ Therefore, IL-10 and TGF- β 2 could prevent the pro-inflammatory properties of IL-1 β and IL-6, favoring the healing process.

In parallel to the inflammation and healing parameters, pain and swelling were measured at all experimental times. Pain was measured by VAS scale, a relatively simple method for pain measurement, because experimental subjects can easily reply to the question.²² Postoperative swelling was measured using the method of Neupert et al.¹⁶ Both measures showed that PRGF reduces postoperative pain and swelling. As regards the first parameter, severe pain was

experienced 2 h after surgery at which time the mean VAS pain score was 4.03 cm at control sites and 3.54 cm at PRGF sites. This represents a 12.16% reduction, which is less than that reported by other researchers as being a clinically significant reduction.²³ The difference between the two sites persisted until 7 days after surgery, when the mean VAS pain score was 0.49 cm at control sites and 0.19 cm at PRGF sites. This represents a 61.22% reduction and is highly significant.

Facial swelling, evaluated with different measures, was demonstrated to be reduced at PRGF sites compared with control sites. For Go-Tr and Go-Po, the difference disappeared at the end of the experimental time, whereas it remained for Go-Ca and Go-Sp.

In conclusion, this study employed a viable and simple method to evaluate the action of PRGF and its effect on inflammation process, wound healing, pain, and swelling scientifically, without enrolling a placebo control group. PRGF was found to be more effective on all parameters examined. Thus, it may be used on a routine basis after third molar surgery, without any associated side effects.

ACKNOWLEDGMENT

We thank Dr. Gorka Orive for revising the article.

REFERENCES

1. Bui CH, Seldin EB, Dodson TB. Types, frequencies, and risk factors for complications after third molar extraction. *J Oral Maxillofac Surg* 2003;61:1379-1389.

2. Laureano Filho JR, Maurette PE, Allais M, Cotinho M, Fernandes C. Clinical comparative study of the effectiveness of two dosages of dexamethasone to control postoperative swelling, trismus and pain after the surgical extraction of mandibular impacted third molars. *Med Oral Patol Oral Cir Bucal* 2008;13: E129–E132.
3. Beeman CS. Third molar management: A case for routine removal in adolescent and young adult orthodontic patients. *J Oral Maxillofac Surg* 1999;57:824–830.
4. Conrad SM, Blakey GH, Shugars DA, Marciani RD, Phillips C, White RP Jr. Patients' perception of recovery after third molar surgery. *J Oral Maxillofac Surg* 1999;57:1288–1294.
5. Kingsley CS. Blood coagulation; evidence of an antagonist to factor VI in platelet-rich human plasma. *Nature* 1954;173: 723–724.
6. Tayapongsak P, O'Brien DA, Monteiro CB, Arcero-Dias LL. Autologous fibrin adhesive in mandibular reconstruction with particulate cancellous bone and marrow. *J Oral Maxillofac Surg* 1994;52: 161–166.
7. Whitman DH, Berry RL, Green DM. Platelet gel: An autologous alternative to fibrin glue with applications in oral and maxillofacial surgery. *J Oral Maxillofac Surg* 1997;55:1294–1299.
8. Marx RE, Carlson ER, Eichstaedt RM, Schimmele SR, Strauss JE, Georgeff KR. Platelet-rich plasma: Growth factor enhancement for bone grafts. *Oral Surgery Oral Med Oral Pathol Oral Radiol Endod* 1998;85:638–646.
9. Sanchez AR, Eckert SE, Sheridan PJ, Weaver AL. Influence of platelet-rich plasma added to xenogeneic bone grafts on bone mineral density associated with dental implants. *Int J Oral Maxillofac Implants* 2005;20:526–532.
10. Anitua E. Plasma rich in growth factors: Preliminary results of use in the preparation of future sites for implants. *Int J Oral Maxillofac Implants* 1999;14:529–535.
11. Anitua E, Andia I, Ardanza B, Nurden P, Nurden AT. Autologous platelets as a source of proteins for healing and tissue regeneration. *Thromb Haemost* 2004;91:4–15.
12. Anitua E, Sanchez M, Nurden AT, Nurden P, Orive G, Andia I. New insights into and novel applications for platelet-rich fibrin therapies. *Trends Biotechnol* 2006;24:227–234.
13. Anitua E, Sanchez M, Orive G, Andia I. The potential impact of the preparation rich in growth factors (PRGF) in different medical fields. *Biomaterials* 2007;28:4551–4560.
14. Anitua E, Orive G, Pla R, Roman P, Serrano V, Andia I. The effects of PRGF on bone regeneration and on titanium implant osseointegration in goats: A histologic and histomorphometric study. *J Biomed Mater Res A* 2009;91:158–165.
15. Sánchez M, Anitua E, Azofra J, Aguirre JJ, Andia I. Intra-articular injection of an autologous preparation rich in growth factors for the treatment of knee OA: A retrospective cohort study. *Clin Exp Rheumatol* 2008;26:910–913.
16. Neupert EA III, Lee JW, Philput CB, Gordon JR. Evaluation of dexamethasone for reduction of postsurgical sequelae of third molar removal. *J Oral Maxillofac Surg* 1992;50:1177–1182.
17. Savin J, Ogden GR. Third molar surgery—A preliminary report on aspects affecting quality of life in the early postoperative period. *Br J Oral Maxillofac Surg* 1997;35:246–253.
18. Skjelbred P, Løkken P. Post-operative pain and inflammatory reaction reduced by injection of a corticosteroid. A controlled trial in bilateral oral surgery. *Eur J Clin Pharmacol* 1982;21:391–396.
19. Chang HC, Bistrain B. The role of cytokines in the catabolic consequences of infection and injury. *JPEN J Parenter Enteral Nutr* 1998;22:156–166.
20. Opal SM, DePalo VA. Anti-inflammatory cytokines. *Chest* 2000; 117:1162–1172.
21. Werner S, Grose R. Regulation of wound healing by growth factors and cytokines. *Physiol Rev* 2003;83:835–870.
22. Price DD, McGrath PA, Rafii A, Buckingham B. The validation of visual analogue scales as ratio scale measures for chronic and experimental pain. *Pain* 1983;17:45–46.
23. Tavares MG, Machado AP, Motta BG, Borsatto MC, Rosa AL, Xavier SP. Electro-acupuncture efficacy on pain control after mandibular third molar surgery. *Braz Dent J* 2007;18:158–162.