

AperTO - Archivio Istituzionale Open Access dell'Università di Torino

Melanoma of unknown primary site: a 33-year experience at the Turin Melanoma Centre.

This is the author's manuscript

Original Citation:

Availability:

This version is available <http://hdl.handle.net/2318/81631> since

Published version:

DOI:10.1097/CMR.0b013e328333bc04

Terms of use:

Open Access

Anyone can freely access the full text of works made available as "Open Access". Works made available under a Creative Commons license can be used according to the terms and conditions of said license. Use of all other works requires consent of the right holder (author or publisher) if not exempted from copyright protection by the applicable law.

(Article begins on next page)



UNIVERSITÀ DEGLI STUDI DI TORINO

*This is an author version of the contribution published on:
Questa è la versione dell'autore dell'opera:*

Melanoma Res. 2010 Jun;20(3):227-32.

Savoia P, Fava P, Osella-Abate S, Nardò T, Comessatti A, Quaglino P, Bernengo MG. Melanoma of unknown primary site: a 33-year experience at the Turin Melanoma Centre.

*The definitive version is available at:
La versione definitiva è disponibile alla URL:*

<http://journals.lww.com/melanomaresearch/pages/articleviewer.aspx?year=2010&issue=06000&article=00011&type=abstract>

Melanoma Research Issue: Volume 20(3), June 2010, pp 227-232

DOI: 10.1097/CMR.0b013e328333bc04

Melanoma of unknown primary site: a 33-year experience at the Turin Melanoma Centre

Savoia, Paola; Fava, Paolo; Osella-Abate, Simona; Nardò, Tiziana; Comessatti, Alessandra; Quaglino, Pietro; Bernengo, Maria Grazia

Department of Biomedical Sciences and Human Oncology, Section of Clinics and Oncological Dermatology, University of Turin, Italy

Correspondence to Paola Savoia, MD, Department of Biomedical Sciences and Human Oncology, Section of Clinics and Oncological Dermatology, v. Cherasco 23, 10126, Torino, Italy

Tel: +39 11 6335816; fax: +39 11 674034; e-mail: paola.savoia@unito.it

Keywords: melanoma, prognosis, survival, unknown primary

Abstract

Unknown melanoma occurs as metastasis to skin, nodes or viscera, without a detectable cutaneous primary tumour. We reviewed our database of 4881 melanoma patients, diagnosed and followed up prospectively for a 33-year period. We identified 93 cases of metastatic melanoma without evidence of primary; however, five of these patients had a history of a previous excision of a presumed benign lesion without histological examination and were excluded from analyses. At diagnosis, metastases were cutaneous in 35.3% of cases, nodal in 43.2% and visceral in 17% of cases; in 4.5% of patients, both skin and nodes were involved. In all cases, clinical inspection and staging procedures performed at diagnosis of metastatic disease failed to identify a primary melanoma. In 11 cases (11.8%), extensively regressed pigmented lesions (without evidence of melanoma cells at the histological examination) were documented; moreover, we identified in our series five patients with unknown primary affected by vitiligo. The 5-year and 10-year overall survival rates were 49.6 and 41.4%, respectively, with a median of 4.9 years. The 5-year and 10-year time to progression rates were 39.4 and 32.3%, respectively, with a median of 2.3 years. Survival was longer in females and showed significant differences among patients with skin, lymph node or visceral involvement at diagnosis. In melanoma patients, unknown primary represents a not so rare event, with an uncertain origin. We confirmed the relatively good prognosis of unknown primary melanoma patients, a fact that has to be taken into consideration for their management.

Introduction

Melanoma with unknown primary site (MUP), described for the first time in 1952 [1], is defined as histologically confirmed subcutaneous, lymph nodal or visceral metastatic melanoma with no evidence of

concomitant cutaneous, mucosal or ocular primary lesion or previous skin tumour excised without histological examination [2].

Several theories have been proposed to clarify the pathogenesis of unknown primary melanoma. Some authors suggested that ectopic melanocytes located in lymph nodes can undergo malignant transformation [3,4]. Others recognize, instead, a role of an undetected primary melanoma that may have undergone spontaneous regression mediated by endogenous immune response [3].

In the literature, the incidence of MUP is rather frequent, ranging from 2 to 8% of all melanoma cases [3–6]. However, the biological behaviour of the disease in these patients needs to be characterized. In several studies [7–9], prognosis seems not to be adversely affected by the lack of identification of primary melanoma; notably, unknown primary patients who presented with lymph nodal involvement show better prognosis than those with known primary melanoma [4,10,11].

In this study, we report our experience of 88 patients with diagnosis of MUP, with the aim to better clarify their clinical characteristics and outcome.

Materials and methods

Patient population and follow-up

The clinical records of 4881 melanoma patients who were diagnosed and prospectively followed up at our Institution during a 33-year period (from January 1975 to December 2008) have been reviewed. We identified 93 patients with diagnosis of metastatic melanoma to lymph node, soft tissues or internal organs, without evidence of a primary lesion.

Patient's age, sex, familiar or personal history of melanoma, history of vitiligo, spontaneous regression of nevi or previous excised skin lesions were recorded. Site of presentation, number of tumour-involved sites and clinical outcome were also evaluated. All the patients underwent clinical and radiological staging and follow-up procedures at our institution. At the time of diagnosis, patients underwent cutaneous, otorhinolaryngologist, ophthalmological and anogenital examination and brain and body imaging studies; after 1999, all patients underwent reverse transcription (RT)-PCR tyrosinase detection on peripheral blood. Afterwards, clinical and radiological follow-up was performed according to the guidelines in use [12,13].

Patients were staged on the basis of the AJCC classification [14]. MUP with a localized nodal or cutaneous–subcutaneous involvement were considered stage III, whereas patients with cutaneous–subcutaneous disseminated metastases involvement of two or more nodal stations or with visceral metastases were classified as stage IV.

The control group consisted of stage III and stage IV patients with a documented primary cutaneous melanoma, diagnosed and treated during the same time interval.

Tyrosinase detection

Fifteen millilitres of blood were collected in EDTA (K3) tubes. The first few millilitres of each blood sample were discarded to avoid any possible contamination by normal skin melanocytes. Blood samples were processed within 2 h of collection. The RNA extraction, yield and nested RT-PCR procedures have been described elsewhere and all standard steps were taken to prevent carry-over contamination. A negative

control (RNA from healthy donors blood) and a positive control (RNA from a melanoma cell line) were included with each batch of samples to verify a contamination-free environment and a faultless RT-PCR operating system. The integrity of the RNA for each sample was verified by RT-PCR with primers for human glyceraldehyde 3-phosphate dehydrogenase, as described elsewhere [15].

Statistical analysis

The main endpoints calculated were: (i) time to progression (TTP), which is defined as the time between the diagnosis and the development of a new metastatic involvement; (ii) overall survival (OS), calculated from the date of histological diagnosis of metastatic MUP until death due to any cause.

The Kaplan–Meier product-limit method was used to estimate curves for OS; the log-rank test was used to test differences between the survival curves.

Univariate/multivariate analysis using the Cox proportional hazard regression model was performed to evaluate the impact of the known risk factors on the development and the distribution pattern of cutaneous metastases. The parameters included in the univariate/multivariate analysis model were clinical (age, sex, site of involvement); moreover, type of treatment (surgery alone vs. others) and baseline tyrosinase expression were also evaluated. The age was a continuous variable, the others categorical.

Results

Clinical features

We identified 93 out of 4881 patients with histologically confirmed metastatic melanoma to lymph node, soft tissues and/or internal organs, without history of a primary melanoma excision.

In all patients, clinical inspection and staging procedures performed at the time of diagnosis of metastatic disease failed to show a primary melanoma. In 11 cases (11.8%), we identified at clinical examination an extensively regressed pigmented lesion; however, pathological analyses failed to detect histological evidences of melanoma cells. Interestingly, three other patients showed large areas of vitiligo, without suspicious pigmented lesions, whereas two developed vitiligo during the follow-up; the global percentage of patients affected by vitiligo in these series was 5.4%.

Five of the 93 patients were excluded from the study because they were referred to our department from other institutions with a history of a previous excision of a presumed benign lesion without histological examination. Two other patients experienced a removal of a body extremity (left foot amputation in one diabetic patient; traumatic excision of a finger due to an industrial accident in the other one); nevertheless, there was no history of suspected skin lesions in these body areas.

Eighty-eight patients (1.8% of the entire series) were included in the study (55 male and 33 female). The median age was 60 years (range 17–88); median age was lower in women (56 years, range 23–85) than in men (63 years, range 17–88) (Table 1).

The sites of involvement at diagnosis can be summarized as follows: 31 patients (35.3%) showed cutaneous or subcutaneous metastases, which were localized in 27 patients and disseminated in the remaining four. Thirty-eight patients (43.2%) had only lymph node involvement, whereas in another four (4.5%) we found both lymph node and skin localizations. In the remaining 15 patients (17%), melanoma

presented with visceral metastases, which were either disseminated (nine patients) or localized (brain, four cases; stomach, one case; lung, one case) (Table 1). According to the AJCC classification, one patient was stage IIIA, 53 were IIIB, 13 were IIIC and 21 were classified as stage IV (one with disseminated cutaneous metastases; three with disseminated subcutaneous localizations; two with two or more lymph nodal stations involved; 15 with visceral spreading).

Tyrosinase expression was evaluated at baseline condition in the 51 patients diagnosed from January 1999. Tyrosinase was positive in 12 patients, whereas the others showed negative results.

None of our patients had a positive family history of melanoma. Five patients developed a new primary melanoma during the follow-up. Four were in-situ melanomas, without signs of regression or vascular invasion, and developed after a median time of 0.6 years (range 0.2 months–3.1 years) from the diagnosis of unknown primary. The last one was a nodular melanoma that developed in nasal mucosa after 7.8 years from the first diagnosis. In six patients, we documented a personal history of other nonmelanoma tumours (two breast carcinoma, one uterus, one lung, one kidney, one prostate adenocarcinoma).

Treatment

Surgery was the treatment of choice for 31 patients with cutaneous or subcutaneous localization, 36 patients with lymph node involvement, three patients with both skin and lymph node metastases and six patients with visceral single metastases, who achieved a disease-free state; 36 of these patients received adjuvant immunotherapy (14) or chemoimmunotherapy (22). The remaining 12 metastatic patients were treated with chemotherapy or chemoimmunotherapy according to the current protocols of treatment.

Outcome

The overall 5-year and 10-year survival rates of MUP patients were 49.6 and 41.4%, respectively, with a median survival rate of 4.9 years (Fig. 1a). Female patients had a better survival rate (median 6.5 years; 5 years 52.4%; 10 years 48.1%) than male patients (median 3.2 years; 5 years 47.8%; 10 years 35.4%) (Fig. 1b); however, these differences were not statistically significant. Survival was significantly different among patients with skin (median 8.6 years), lymph node (median 17.4 years) or visceral (median 1.0 years) involvement at the time of diagnosis. MUP with visceral metastases at diagnosis showed an OS significantly lower than the other MUP patient groups ($P<0.001$) (Fig. 1c).

The 5-year and 10-year TTP rates were 39.4 and 32.3%, respectively, with a median TTP of 2.3 years (Fig. 1d). TTP was higher, although not statistically significant, in females (median 4.2 years; 5 years and 10 years 43.7%) than in males (median 2.2 years; 5 years 37.2%; 10 years 24.8%) (Fig. 1e). Site of involvement at the time of diagnosis did not affect the percentage of patients who developed new metastasis during follow-up; however, patients with early skin and/or lymph node involvement developed new recurrence later than those with visceral metastases (4.2 years, 2.3 years and 1.4 years, respectively) (Fig. 1f).

When stage III MUP patients were compared with control group, we observed a significantly higher OS (5-year survival 60.2 vs. 42.2%; 10-year survival 51.7 vs. 33.8%; $P=0.0171$) (Fig. 2a). OS was also increased in stage IV MUP patients (1-year survival 52.2 vs. 40.4%; 5-year survival 16.2 vs. 9.7%), even if these differences were not statistically significant (Fig. 2b).

The disease course was influenced by tyrosinase status at baseline; univariate analysis showed a TTP significantly lower ($P=0.016$) in patients with positive tyrosinase at diagnosis than in those with negative results.

Multivariate analysis

Multivariate analysis on entire cohort of patients showed a significant OS difference between patients with soft tissue and visceral metastases ($P=0.05$), whereas no differences were found in TTP (Table 2).

In 51 of 88 patients, baseline tyrosinase was included as a parameter in multivariate analysis. Despite the lower number of patients, analysis confirmed that the site of involvement at the time of diagnosis (soft tissues vs. visceral metastases) was the most powerful prognostic indicator associated with significant OS differences ($P=0.0021$) (Table 2). Similarly, as shown earlier on the entire cohort of patients, soft tissue versus visceral involvement did not affect TTP.

Multivariate analyses showed that baseline tyrosinase detection plays a significant prognostic role on TTP, with a risk ratio of 2.56 ($P=0.046$) (Table 2), whereas was not significant in terms of OS.

Discussion

The finding of patients with diagnosis of metastatic melanoma without evidence or previous history of suspicious pigmented skin lesions is a relatively frequent event, which assesses for 1.8% of all melanoma cases in our series. This percentage is in agreement with that reported by other studies [3–6], although the incidence of unknown primary is estimated to be approximately 8–9% by authors that take into account only patients with lymph node involvement [7,16]. In our experience, in agreement with the majority of published series [3,4,17,18], patients with unknown primary were predominantly middle-aged males. In almost half of the cases, the first site of presentation was a lymph nodal mass, but also cutaneous or subcutaneous localizations were frequent; on the contrary, visceral metastases were found at diagnosis in only 18% of patients.

We classified our MUP patients according to the rules of the AJCC classification, as recently reported [5,6,16]. However, the use of AJCC in the classification of MUP could be misleading. Actually, the current AJCC system classifies patients with locoregional skin metastases as stage IIIb and patients with distant skin localizations as stage IV [14]. The site of primary melanoma plays an important role in the definition of cutaneous or lymph nodal involvement as locoregional (stage III) or distant (stage IV) and, consequently, the absence of a known site of primary melanoma could lead to incorrect classification. We arbitrarily classified as stage III all MUP patients with a single lymph-nodal or soft-tissue metastasis; whereas, patients with involvement of two or more nodal stations, disseminated cutaneous or subcutaneous metastases or with visceral localizations were classified as stage IV. As we did not find any sign of primary melanoma in more than 77% of our patients, some stage IV patients could be erroneously assigned to stage III, with considerable implications in their treatment and follow-up. However, despite this likely incorrect classification, we confirmed the better prognosis of MUP patients, when compared with those with known primary site [4,6,9,16]. Our data show higher OS and TTP in patients with unknown primary, with a further survival advantage in females. We suppose that these differences could be more underestimated in the light of the above-mentioned classification mistakes.

Although our data are not statistically significant on account of the small number of patients, no differences in the percentage of patients with progressive disease were observed depending on the site of involvement at the time of diagnosis (skin, lymph node or viscera); however, the TTP to new metastatic sites was significantly higher in patients with skin involvement at diagnosis (4.2 years) than in those with lymph nodal or visceral metastases (2.3 and 1.4 years, respectively). This observation could have an impact on therapeutic strategies and can support, in our opinion, the role of local therapies in the management of MUP patients with disease restricted to the skin. In contrast, the predictive role of the first site of involvement (soft tissues vs. viscera) in OS was also confirmed in multivariate analysis. Moreover, we confirmed a positive predictive value for surgery, whereas no outcome differences were found between patients that underwent adjuvant therapy and those treated with surgery alone. The role of adjuvant therapy in MUP patients remain unclear; in fact, the small size of the majority of published series precluded a comparative analysis of survival between the different group of patients [4,5].

Recently, the value of serum S100 protein as sensitive and specific marker to detect melanoma metastases has been confirmed [19,20], and its inclusion in the baseline staging of MUP patients has been recommended [21]. Staging procedures in use at our department do not include S-100 determination, but, since 1999, tyrosinase detection is made on peripheral blood. At the time of diagnosis, positive results were found in 12 of 51 MUP patients. Univariate analysis confirmed that tyrosinase status at baseline influenced the disease outcome: patients with positive results at diagnosis showed a TTP significantly lower than patients with negative results ($P=0.016$). Multivariate analyses confirmed the prognostic role of baseline tyrosinase in TTP, with a risk ratio of 2.56 ($P=0.046$). These data are in agreement with our previous observations. The relationship between tyrosinase results and disease status has been shown by our group, as well as the predictive role of this marker and its usefulness in the monitoring of stage III patients [15,22]. Multivariate analyses including the tyrosinase variable was not performed on the totality of cases; however, this cohort seems to be representative of the entire MUP population included in this study. The remaining parameters analyzed did indeed show superimposable results.

To date, the aetiology of MUP remains unexplained; in literature, two main hypotheses have been proposed: (i) complete spontaneous regression of the primary melanoma [23] and (ii) primary origin from melanocytes in lymph nodes or viscera [24].

The first hypothesis is supported by the demonstration of partially regressed pigmented lesion in several MUP patients [4]. We found lesions suggestive for a melanoma with regression in 11 of our patients (11.8%). Moreover, others five patients (5.4%) showed large areas of vitiligo, even if we did not find any suspicious pigmented lesion; this percentage is higher in comparison with both the general population (0.5–1%) [25,26] and the patients affected by melanoma with known primary site (2.8% in patients followed up at our institution during the last 33-year period). Therefore, it is possible that areas of vitiligo could hide a primary melanoma in some patients. Noteworthy, in melanoma patients it has been shown that vitiligo has a positive prognostic role [26,27].

The hypothesis of MUP origin from melanocytes in lymph node or viscera [23] has to be confirmed. It could be supported by the fact that in the majority of patients with unknown primary, clinical and radiological examination performed to detect primary lesion resulted normal. In a large study published by Lenzi et al. [28], including patients affected by different metastatic solid tumours, the primary site was identified only in less than a quarter of investigated patients. Furthermore, in our experience, radiological procedures, otorhinolaryngologist, ophthalmological and anogenital, as well as cutaneous examinations failed in the

identification of suspect lesions in the vast majority of cases. Therefore, the real cost-effectiveness of these tests and their importance in the management of MUP patients is questionable.

Our experience confirms that unknown primary is not such a rare event; the aetiology remains uncertain and, probably, we have to take in account different mechanisms. Probably, immune system response plays a crucial role. However, we confirmed the relatively good prognosis of MUP, which has key implications both for counselling and management of these patients. Finally, in consideration of the large percentage of failure in the search of primary tumour, we advise a careful examination of skin and mucosae but discourage thorough expensive and time-consuming examinations other than those used in the current staging procedures of patients with melanoma of known primary site.

Acknowledgement

The authors have no significant interest with commercial supporters.

References

1. Pack GT, Gerber DM, Scharnagel IM. End results in the treatment of malignant melanoma; a report of 1190 cases. *Ann Surg* 1952; 136:905–911.
2. Das Gupta T, Bowden L, Berg JW. Malignant melanoma of unknown primary origin. *Surg Gynecol Obstet* 1963; 117:341–345.
3. Giuliano AE, Moseley HS, Morton DL. Clinical aspects of unknown primary melanoma. *Ann Surg* 1980; 191:98–104.
4. Anbari KK, Schuchter LM, Bucky LP, Mick R, Synnestvedt M, Guerry D 4th, et al. Melanoma of unknown primary site: presentation, treatment, and prognosis—a single institution study. University of Pennsylvania Pigmented Lesion Study Group. *Cancer* 1997; 79:1816–1821.
5. Katz KA, Jonasch E, Hodi FS, Soiffer R, Kwitkiwski K, Sober AJ, et al. Melanoma of unknown primary: experience at Massachusetts General Hospital and Dana-Farber Cancer Institute. *Melanoma Res* 2005; 15:77–82.
6. Cormier JN, Xing Y, Feng L, Huang X, Davidson L, Gershenwald JE, et al. Metastatic melanoma to lymph nodes in patients with unknown primary sites. *Cancer* 2006; 106:2012–2020.
7. Wong JH, Cagle LA, Morton DL. Surgical treatment of lymph nodes with metastatic melanoma from unknown primary site. *Arch Surg* 1987; 122:1380–1383.
8. Norman J, Cruse CW, Wells KE, Saba HI, Reintgen DS. Metastatic melanoma with an unknown primary. *Ann Plast Surg* 1992; 28:81–84.
9. Sclagenhauff B, Stroebel W, Ellwanger U, Meier F, Zimmermann C, Breuninger H, et al. Metastatic melanoma of unknown primary origin shows prognostic similarities to regional metastatic melanoma: recommendation for initial staging examinations. *Cancer* 1997; 80:60–65.
10. Chang P, Knapper WH. Metastatic melanoma of unknown primary. *Cancer* 1982; 49:1106–1111.

11. Panagopoulos E, Murray D. Metastatic malignant melanoma of unknown primary origin: a study of 30 cases. *J Surg Oncol* 1983; 23:8–10.
12. Bernengo MG, Doveil GC, Lisa F, Pippione M, Aloï FG, Stuardi C, et al. Melanoma cutaneo nel Centro Melanoma di Torino. *Giorn It Derm Vener* 1986; 121:311–326.
13. Bernengo MG, Quaglino P, Cappello N, Fierro MT, Doveil GC, Macripò G, et al. Time course and pattern of first relapse in stage I-II primary cutaneous melanoma: a multivariate analysis of disease-free survival in 3174 patients followed-up at the Turin Melanoma Centre from 1975 to 2004. *G Ital Dermatol Venereol* 2005; 140:191–200.
14. Balch CM, Soong SJ, Gershenwald JE, Thompson JF, Reintgen DS, Cascinelli N. Prognostic factors analysis of 17 600 melanoma patients: validation of the American Joint Committee On Cancer Melanoma Staging System. *J Clin Oncol* 2001; 19:3622–3634.
15. Osella Abate S, Savoia P, Cambieri I, Salomone B, Quaglino P, Bernengo MG. Role of RT-PCR tyrosinase detection in the monitoring of patients with advanced metastatic melanoma. *Melanoma Res* 2000; 10:545–555.
16. Lee CC, Faries MB, Wanek LA, Morton DL. Improved survival after lymphadenectomy for nodal metastasis from an unknown primary melanoma. *J Clin Oncol* 2008; 26:535–541.
17. Paul E, Mullhofer R. Metastasizing malignant melanoma from unknown primary tumour. *Hautartz* 1990; 41:432–437.
18. Velez A, Walsh D, Karakousis CP. Treatment of unknown primary melanoma. *Cancer* 1991; 68:2579–2581.
19. Mocellin S, Zavagno G, Nitti D. The prognostic value of serum S100B in patients with cutaneous melanoma: a meta-analysis. *Int J Cancer* 2008; 123:2370–2376.
20. Tarhini AA, Stuckert J, Lee S, Sander C, Kirkwood JM. Prognostic significance of serum S100B protein in high-risk surgically resected melanoma patients participating in Intergroup Trial ECOG 1694. *J Clin Oncol* 2009; 27:38–44.
21. Oberholzer PA, Urosevic M, Steinert HC, Dummer R. Baseline staging of melanoma with unknown primary site: the value of serum S100 protein and positron emission tomography. *Dermatology* 2008; 217:351–355.
22. Osella-Abate S, Savoia P, Quaglino P, Fierro MT, Leporati C, Ortoncelli M, et al. Tyrosinase expression in the peripheral blood of stage III melanoma patients is associated to a poor prognosis: a clinical follow-up study of 110 patients. *Br J Cancer* 2003; 89:1457–1462.
23. Bottger D, Dowden RV, Kay PP. Complete spontaneous regression of cutaneous primary malignant melanoma. *Plast Reconstr Surg* 1992; 89:548–553.
24. Shenoy BV, Fort L III, Benjamin SP. Malignant melanoma primary in lymph node: the case of missing link. *Am J Surg Pathol* 1987; 11:140–146.
25. Kovacs SO. Vitiligo. *J Am Acad Dermatol* 1998; 38:647–666.

26. Quaglino P, Marengo F, Osella-Abate S, Cappello N, Ortoncelli M, Salomone B, et al. Vitiligo is an independent favourable prognostic factor in stage III and IV metastatic melanoma patients: results from a single-institution hospital-based observational cohort study. *Ann Oncol* 2009;21
27. Boasberg PD, Hoon DS, Piro LD, Martin MA, Fujimoto A, Kristedja TS, et al. Enhanced survival associated with vitiligo expression during maintenance biotherapy for metastatic melanoma. *J Invest Dermatol* 2006; 126:2658–2663.
28. Lenzi R, Hess KR, Abbruzzese MC, Raber MN, Ordoñez NG, Abbruzzese JL. Poorly differentiated carcinoma and poorly differentiated adenocarcinoma of unknown origin: favorable subsets of patients with unknown primary carcinoma? *J Clin Oncol* 1997; 15:2056–2066.

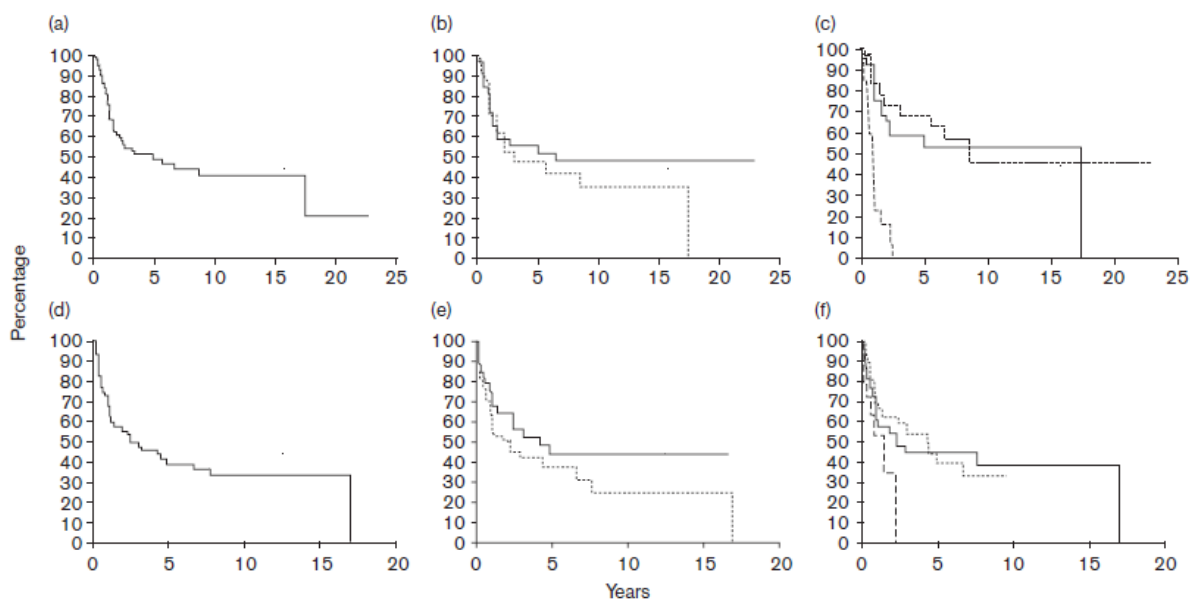
Keywords: melanoma; prognosis; survival; unknown primary

Table 1 Patient characteristics

Sex M/F		55/33
Median age (years)		60 (17–88)
M		63 (17–88)
F		56 (23–85)
First site of progression	No. of patients	Site
Cutaneous	10	
	4	Leg
	2	Abdomen
	2	Back
	1	Head
	1	Disseminated
Subcutaneous	21	
	6	Back
	4	Leg
	4	Abdomen
	3	Disseminated
	2	Arm
	1	Head
	1	Foot
Lymph nodes	38	
	20	Axilla
	10	Groin
	6	Neck
	2	Multiple
Lymph nodes, cutaneous and subcutaneous concomitant	4	
	3	Axilla + skin
	1	Neck + skin
Visceral	15	
	9	Multiple
	4	Brain
	1	Gastric
	1	Lung
Total	88	

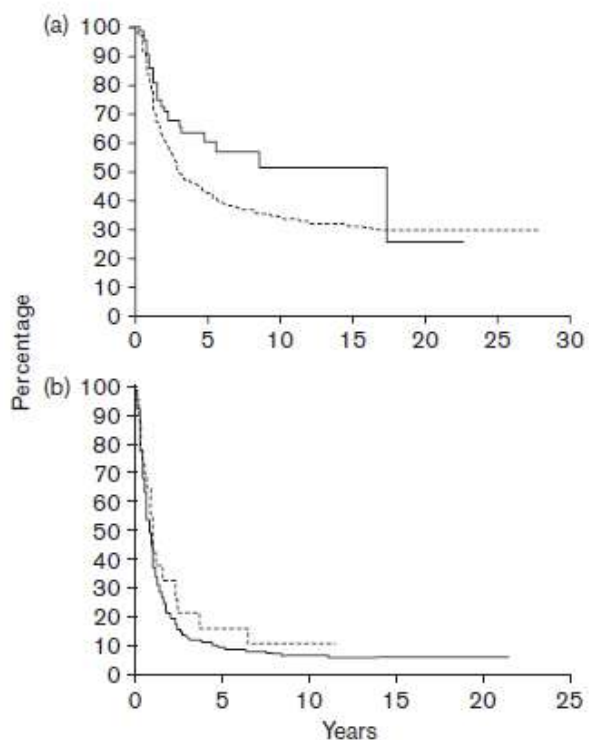
F, female; M, male.

Fig. 1



Overall survival (OS) and time to progression (TTP) in patients with unknown primary melanoma (MUP). (a) OS in all MUP patients. (b) OS according to sex (solid line, female; dotted line, male). (c) OS according to site of involvement (solid line, skin; dotted line, node; dashed line, visceral) ($P < 0.001$). (d) TTP in all MUP patients. (e) TTP according to sex (solid line, female; dotted line, male). (f) TTP according to site of involvement (solid line, skin; dotted line, node; dashed line, visceral).

Fig. 2



Overall survival according to American Joint Committee On Cancer classification; unknown primary melanoma (solid line) versus melanoma of known primary site (dotted line). (a) Stage III ($P = 0.0171$). (b) Stage IV.

Table 2 Multivariate analysis results, OS and TTP in 88 and 51 patients

Variables	OS				TTP			
	Coefficient	Standard error	Risk ratio	P value	Coefficient	Standard error	Risk ratio	P value
Age	-0.0059	0.0109	0.9941	0.5905	-0.0158	0.0097	0.9844	0.1026
Sex	0.2596	0.3211	1.2964	0.4189	0.4480	0.3142	1.5653	0.1538
Soft tissue/Viscera	1.2640	0.6565	3.5394	0.0498	0.2784	0.6396	1.3211	0.6633
Treatment	-0.1965	0.3799	0.8216	0.6051	-0.0914	0.3296	0.9126	0.7815
Baseline tyrosinase ^a	0.6709	0.4580	1.9559	0.1430	0.9401	0.4711	2.5603	0.0460
Age	-0.0173	0.0162	0.9828	0.2848	-0.0208	0.0165	0.9794	0.2084
Sex	0.1654	0.4315	1.1798	0.7015	0.2201	0.4697	1.2462	0.6394
Soft tissue/Viscera	2.1265	0.6900	8.3855	0.0021	0.8927	0.5930	2.4418	0.1322
Treatment	-0.4362	0.2987	0.6465	0.1441	-1.0166	0.5393	0.3618	0.0594

The numbers in bold are statistically significant.

OS, overall survival; TTP, time to progression.

^aTyrosinase negative = 0, Tyrosinase positive = 1.