

AperTO - Archivio Istituzionale Open Access dell'Università di Torino

Metallic staples line mimicking a retained surgical sponge

This is the author's manuscript

Original Citation:

Availability:

This version is available <http://hdl.handle.net/2318/74263> since

Terms of use:

Open Access

Anyone can freely access the full text of works made available as "Open Access". Works made available under a Creative Commons license can be used according to the terms and conditions of said license. Use of all other works requires consent of the right holder (author or publisher) if not exempted from copyright protection by the applicable law.

(Article begins on next page)

METALLIC STAPLES LINE MIMICKING A RETAINED SURGICAL SPONGE

L. Cardinale¹, C. Fava¹, N. Dervisci, D. Najada¹, P. Borasio², F. Ardisson²

The inadvertent loss of surgical sponges remains a dreadful hazard of surgery. We report the case of a patient with a medical history of myotonic dystrophy type 1 who had received a right upper lobectomy for the treatment of a stage IIA (pT1N1M0) well differentiated neuroendocrine carcinoma. In the early postoperative period, aspiration of gastric contents occurred and the patient underwent endotracheal intubation and mechanical ventilation. A follow-up multi-detector computed tomography (MDCT) scan of the chest showed a complex mass in interlobar position with an internal radiopaque serpiginous thread of metallic density which was assumed to represent a retained surgical sponge. Upon surgical exploration, no retained foreign body was found and a zone of recent hemorrhagic infarction, bordered by the line of the mechanical staples used to complete the minor fissure, was removed from the middle lobe. When evaluating patients suspected of having a retained surgical sponge, thoracic surgeons and radiologists should be aware of this potential source of confusion.

Key-word: Foreign bodies.

Retained surgical sponges (also called gossypibomas or textilomas) are a rare but well recognized and dreaded complication of surgery. Several authors have highlighted the inconsistency and variability of the radiologic appearances of intrathoracic gossypibomas (1, 2). In this report we describe a peculiar case where, paradoxically enough, modern imaging techniques introduced unanticipated confounding factors into this diagnostic problem.

Case report

A 57-year-old man with a medical history of myotonic dystrophy type 1 (Steinert disease) underwent right upper lobectomy and systematic lymphadenectomy for a 20-mm well differentiated neuroendocrine carcinoma with lobar and interlobar lymph nodes involvement, staged as a T1N1 tumor. Multiple firings (n = 4) of a gastrointestinal anastomosis stapler with a 55 mm 3.85 mm load of titanium staples were used to complete both minor and major fissures. The surgical procedure was straightforward: no safety-compromising events known to be associated with a risk of retention of a foreign body occurred (3, 4) and repeated counting procedures of instruments and surgical sponges were correct. On postoperative day 2, hemodynamic compromise and acute respiratory failure developed following aspiration of gastric contents. The patient underwent endotracheal intubation and mechanical ventilation. Anteroposterior portable chest radiographs demonstrated opacification

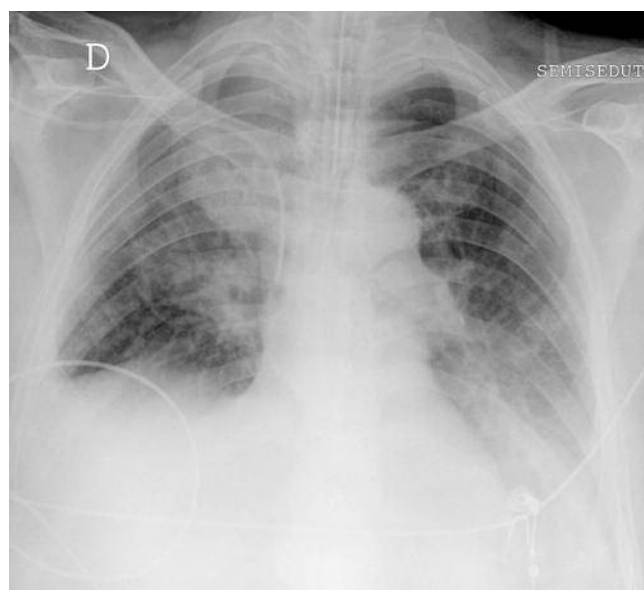


Fig. 1. — Anteroposterior portable chest radiograph obtained on postoperative day 8 shows opacification of the right paratracheal zone. Note also a pleural fluid collection in the left lower lung zone.

of the right paratracheal zone which was interpreted as postoperative pulmonary bleeding and inadequate ventilation of the middle lobe (Fig. 1). However, owing to a poor response to treatment, a multi-detector computed tomography (MDCT) scan was obtained on postoperative day 10, which showed a complex mass in the right upper hemithorax. A serpiginous linear opacity of metallic density was seen within the mass (Fig. 2). The findings were thought most likely to represent a retained surgical sponge and thoracotomy for removal was recommended. At operation, no

retained surgical sponge was found and a dark bluish zone of hepatisation in the middle lobe, bordered by the line of the staples used to complete the minor fissure, was removed. Pathologic evaluation showed recent hemorrhagic infarction. The postoperative course was complicated by persistent disorders of deglutition and impaired cough mechanism. The patient was discharged to a long-term care facility with tracheostomy and feeding jejunostomy on postoperative day 35.

Discussion

Despite numerous published reports, there is little consensus in the literature on the incidence of retained surgical sponges, with estimates ranging from 1 in 1,000 to 1 in over 18,000 procedures (3). Most

From: 1. Radiology Unit, 2. Thoracic Surgery Unit, University of Turin, Department of Clinical & Biological Sciences, Orbassano, Turin, Italy.

Address for correspondence: Dr L. Cardinale, University of Turin, Department of Clinical & Biological Sciences, Radiology Unit, San Luigi Hospital, I-10043 Orbassano (Torino), Italy. E-mail: luciano.cardinale@gmail.com

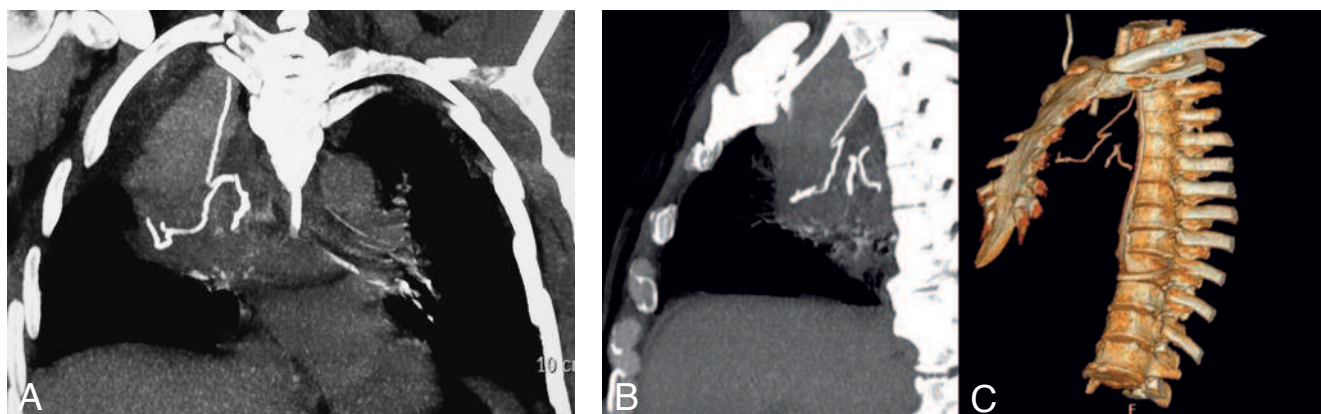


Fig. 2. — MDCT. Coronal MIP image (A) shows a heterogeneous mass in the right upper hemithorax with an internal radiopaque thread of metallic density which was assumed to be a retained surgical sponge. Additional sagittal oblique MIP (B) and volume-rendered (C) images show the interrupted serpiginous pattern of metallic density, compatible with the multiple firings of the staple device used to divide interlobar fissures.

likely, the difficulty in ascertaining the true incidence of retained surgical sponges results from the lack of established reporting systems for such adverse occurrences, the concern for potentially serious medicolegal implications, and the number of asymptomatic retained surgical sponges remaining undiscovered for years or decades (5). Indeed, the inadvertent loss of surgical sponges continues to be a dreadful hazard of surgery.

Surgical sponges are routinely supplied with radiopaque markers allowing them to be readily recognized on imaging studies. However, in the early postoperative period, proper identification of radiopaque sponge markers on plain radiographs is hampered by several factors including location and orientation of the foreign body, marker distortion by folding or twisting, and presence of metallic artifacts from surgically placed staple lines or clips (6-8). Besides, detection of radiopaque sponge markers may not be as easy as claimed owing to the less than ideal diagnostic quality of anteroposterior portable chest film obtained in the perioperative period.

In our case, also retrospectively, was the staple lines specific pattern not recognizable in bedside radiography.

Finally, the most CT characteristic signs for retained surgical sponges, namely a spongiform or whirl-like pattern with gas bubbles in a mass with a thin enhancing capsule, may be absent or may be confused with loculated infection and organized hematoma or seroma (9). All of these factors can lead to diagnostic dilemmas and misinterpretations.

Recent advances in MDCT technology have greatly improved the quality of three-dimensional (3D) renderings. However, combining our findings with those of two prior case reports (7, 8) suggests that the reconstruction of images by using maximum intensity projection (MIP) technique, besides lacking accurate 3D perspective, results in increased opacity of the line of the mechanical staples used to complete interlobar fissures, which simulates the radiopaque marker of a supposedly retained surgical sponge. In retrospect, closer examination of additional images generated with both MIP and volume rendering techniques (Fig. 2B,C) or the creation of cine loops from MIP images in multiple planes revealed the interrupted pattern of metallic density, consistent with the multiple firings of the gastrointestinal anastomosis stapler used to separate the lobes. On the other hand, disintegration of the radiopaque marker embedded in a retained surgical sponge was to be excluded in view of the short time that had elapsed since surgery.

We reiterate the opinion of others (6, 10) that optimal use of imaging techniques (native axial CT data and multiplanar reformation with MIP for the reconstruction of two-dimensional images, and volume rendering for the creation of 3D images) is required for achieving a confident understanding of equivocal imaging findings. Besides, referral to a photoradiographic atlas of surgical items that can be left, either intentionally or unintentionally, in surgical wounds would contribute to making a prompt diagnosis and facilitating appropriate treatment.

References

1. Suwatanapongched T., Boonkasem S., Sathianpitayakul E., Leelachaikul P.: Intrathoracic gossypiboma: radiographic and CT findings. *Brit J Radiol* 2005, 78: 851-853.
2. Madan R., Trotman-Dickenson B., Hunsaker A.R.: Intrathoracic gossypiboma. *AJR* 2007, 189: W90-W91.
3. Gawande A.A., Studdert D.M., Orav E.J., Brennan T.A., Zinner M.J.: Risk factors for retained instruments and sponges after surgery. *N Engl J Med* 2003, 348: 229-235.
4. Christian C.K., Gustafson M.L., Roth E.M., Sheridan T.B., Gandhi T.K., Dwyer K., et al.: A prospective study of patient safety in the operating room. *Surgery* 2006, 139: 159-173.
5. Kaiser C.W., Friedman S., Spurling K.P., Slowick T., Kaiser H.A.: The retained surgical sponge. *Ann Surg* 1996, 224: 79-84.
6. de Lacey G.: Retained surgical swabs: possible causes for errors in X-ray detection and an atlas to assist recognition. *Brit J Radiol* 1978, 51: 691-698.
7. Poncelet A.J., Watremez C., Tack D., Noirhomme P.: Paracardiac opacity following inferior- and middle-lobe resection for bronchogenic carcinoma. Unsuspected diagnosis. *Chest* 2005, 128: 439-441.
8. Granetzny A., Holtbecker N., Thomas H., Klein K., Boseila A.: Misinterpretation of a pulmonary GI anastomosis stapler line as a retained foreign body. *Chest* 2008, 133: 281-283.
9. Kopka L., Fischer U., Gross A.J., Funke M., Oestmann J.W., Grabbe E.: CT of retained surgical sponges (textilomas): pitfalls in detection and evaluation. *J Comput Assist Tomogr* 1996, 20: 919-923.
10. Wolfson K.A., Seeger L.L., Kadell B.M., Eckardt J.J.: Imaging of surgical paraphernalia: what belongs in the patient and what does not. *RadioGraphics* 2000, 20: 1665-1673.