

AperTO - Archivio Istituzionale Open Access dell'Università di Torino

**Effectiveness of extracorporeal photochemotherapy in the treatment of a case of refractory erosive lichen planus**

**This is the author's manuscript**

*Original Citation:*

*Availability:*

This version is available <http://hdl.handle.net/2318/74984> since

*Published version:*

DOI:10.1080/09546630902991468

*Terms of use:*

Open Access

Anyone can freely access the full text of works made available as "Open Access". Works made available under a Creative Commons license can be used according to the terms and conditions of said license. Use of all other works requires consent of the right holder (author or publisher) if not exempted from copyright protection by the applicable law.

(Article begins on next page)



UNIVERSITÀ DEGLI STUDI DI TORINO

This is an author version of the contribution published on:

Zingoni A, Deboli T, Savoia P, Bernengo MG.

Effectiveness of extracorporeal photochemotherapy in the treatment of a case  
of refractory erosive lichen planus

THE JOURNAL OF DERMATOLOGICAL TREATMENT (2010) 21

DOI: 10.1080/09546630902991468

The definitive version is available at:

<http://www.informaworld.com/openurl?genre=article&doi=10.1080/09546630902991468&magic=crossref||D404A21C5BB053405B1A640AFFD44AE3>

## CASE REPORT

### **Effectiveness of extracorporeal photochemotherapy in the treatment of a case of refractory erosive lichen planus**

ADELE ZINGONI, TOMMASO DEBOLI, PAOLA SAVOIA & MARIA GRAZIA BERNENGO

Department of Biomedical Sciences and Human Oncology, Section of Clinics and Oncological Dermatology, University of Turin, Turin, Italy

#### **Abstract**

Erosive lichen planus is characterized by painful, multi-focal erythematous-ulcerative areas affecting mucosal oral and genital areas. Topical therapies are usually ineffective, whereas systemic steroids and immunosuppressive agents are frequently associated with a wide spectrum of side effects. Herein, we presented our positive experience in the treatment of a case of multi-resistant erosive lichen planus with extracorporeal photochemotherapy.

**Key words:** Erosive lichen planus, extracorporeal photochemotherapy, treatment

#### **Introduction**

Erosive lichen planus (LP) is a severe, recurrent and recalcitrant disease that affects mucosal oral and genital areas (1–3). The cause is unknown, even if it is believed to result from an abnormal T-cell-mediated immune response in which basal epithelial cells are recognized as foreign because of changes in the antigenicity of their surface (4). This condition, characterized by painful, multi-focal erythematous-ulcerative areas that migrate over time, is often distressing for the patient, interfering with daily life. Topical therapies (high-potency corticosteroids, cyclosporin or tacrolimus) are usually ineffective (5–7), whereas long-term systemic steroids and immunosuppressive agents such as azathioprine or methotrexate are frequently associated with a wide spectrum of side effects (8–10).

Herein, we present our positive experience in the treatment of a case of multi-resistant erosive LP with extracorporeal photochemotherapy (ECP).

#### **Case report**

A 50-year-old woman was referred to our institution with painful, erythemato-ulcerative lesions involving both the oral and the genital mucosa; the patient also presented erythemato-cyanematous lesions on the trunk overlaid by vesicles and crusts (Figure 1A, C and E).

Histology confirmed the clinical diagnosis of OLP. All routine blood, immunological and radiological tests were within the normal range and markers for hepatitis B and C and for HIV were negative.

The patient underwent systemic therapy with high-dose prednisone without benefit. Cyclosporin A (CyA) treatment was started at a dose of 3 mg/kg per day, but was discontinued after 2 weeks due to serious side effects.

Because of the failure of these traditional therapies we started treatment with ECP, on the basis of the protocol used in our department for cutaneous T-cell lymphomas, inflammatory erythroderma and graft-

versus-host disease. ECP was performed on 2 consecutive days every 3 weeks. Therapy was well tolerated, without infectious complications or induced lymphopenia.

After a few weeks we observed an improvement of both cutaneous and mucosal lesions. After 16 courses (8 months), the patient achieved complete remission of skin lesions, with substantial re-epithelization of vulvar erosions as well as those located on the tongue, cheeks and lips (Figure 1B, D and F).

## Discussion

High-potency topical corticosteroids represent the first-line therapy in LP, whereas topical cyclosporin or tacrolimus have been proposed as second-line treatment for refractory patients. Long-term systemic steroids are usually effective, even if associated with a well-known spectrum of side effects and relapses following steroid withdrawal (11). Data about the efficacy of other therapeutic agents proposed in the treatment of LP, such as azathioprine or thalidomide, are limited and controversial (12,13). Recently, methotrexate has been proposed in the treatment of patients with erosive, treatment-refractory disease, with encouraging results (10).

Moreover, even non-pharmacologic agents such as psoralen-UVA have been tested in LP (14). In particular, the effectiveness of ECP in the treatment of erosive LP is reported, to date, in four studies, concerning 25 patients; in 14 of those, as well as in our case, the erosive lesions involved genital or anal mucosa (11,15,16). ECP treatment is based on the re-infusion of mononuclear cells, isolated by apheresis, after exposure to 8-methoxypsoralen and UVA. The mechanism underlying the efficacy of this treatment is not yet well characterized, but it has been hypothesized that ECP can induce a reduction in peripheral blood T-lymphocyte subsets. The use of ECP in the treatment of LP has been proposed on the basis of the clinical benefit raised by GvHD patients; LP shows, in fact, several clinical and physiopathological similarities with lichenoid GvHD.

ECP is a relatively safe treatment, and the risk of opportunistic infections in the treated patients is low. However, ECP is expensive and time-consuming, and its effect is only palliative; remission depended on a persistent treatment with spaced sessions. In the series reported by Guyot et al. (11), only one out of the eight patients with a complete response maintained a stable response for several years after ECP discontinuation; others relapsed in a median time of 8.3 months. Similarly, only one out of the four patients described by Kunte et al. (15) was in complete remission after 9 months. Our experience about the treatment of LP with ECP is positive, even if limited to a single case. Our patient, who suffered from a severe and multi-resistant disease, achieved a substantial response with limited side effects after a small number of ECP courses. ECP treatment permitted a reduction in corticosteroid dosage, such as in the majority of literature cases, even if only Bécherel et al. (17) reported a suspension of all other current treatments. So, in our opinion, ECP should be considered as a therapeutic option for the treatment of multi-resistant LP cases, even if further studies with a long-term follow-up are required in order to clarify the effective clinical and cost-benefit advantages.

*Declaration of interest:* The authors report no conflicts of interest. The authors alone are responsible for the content and writing of the paper.

## References

1. Pelisse M, Leibovitch M, Sedel D, Hevitt J. Un nouveau syndrome 1. vulvo-vagino-gingival: Lichen planus erosif plurimiqueux. *Ann Dermatol Venereol.* 1982;109:7979–98.
2. Edwards PC, Kelsch R. Oral lichen planus: Clinical presentation 2. and management. *J Can Dent Assoc.* 2002;8:494–9.
3. Eisen D, Carrozzo M, Bagan Sebastian JV, Thongprasom K. 3. Oral lichen planus: Clinical features and management. *Oral Dis.* 2005;11:338–49.
4. Surgeman PB, Savage NW, Walsh LJ, Zhao ZZ, Zhou XJ, Khan A, et al. The pathogenesis of oral lichen planus. *Crit Rev Oral Biol Med.* 2002;13:350–65.

5. Conrotto D, Carbone M, Carrozzo M, Arduino P, Broccoletti R, Pentenero M, et al. Ciclosporin vs. clobetasol in the topical management of atrophic and erosive oral lichen planus: A double-blind, randomized controlled trial. *Br J Dermatol*. 2006;154:139–45.
6. Byrd JA, Davis MD, Bruce AJ, Drage LA, Rogers RS 3rd. 6. Response of oral lichen planus to topical tacrolimus in 37 patients. *Arch Dermatol*. 2004;14:1508–12.
7. Byrd JA, Davis MD, Rogers RS. Recalcitrant symptomatic 7. vulvar lichen planus: Response to topical tacrolimus. *Arch Dermatol*. 2004;140:715–20.
8. Cribier B, Frances C, Chosidow O. Treatment of lichen 8. planus. An evidence-based medicine analysis of efficacy. *Arch Dermatol*. 1998;134:1521–30.
9. Hersle K, Mobacken H, Sloberg K, Thilander H. Severe oral 9. lichen planus: Treatment with an aromatic retinoid (etretinate). *Br J Dermatol*. 1982;10:77–80.
10. Torti DC, Jorizzo JL, McCarthy MA. Oral lichen planus: A case series with emphasis on therapy. *Arch Dermatol*. 2007;143:511–15.
11. Guyot AD, Farhi D, Ingen-Housz-Oro S, Bussel A, Parquet N, Rabian C, et al. Treatment of refractory erosive oral lichen planus with extracorporeal photochemotherapy: 12 cases. *Br J Dermatol*. 2007;156:553–6.
12. Camisa C, Popovsky JL. Effective treatment of oral erosive lichen planus with thalidomide. *Arch Dermatol*. 2000;136:1442–3.
13. Zakrzewska JM, Chan ES, Thornhill MH. A systematic review of placebo-controlled randomized clinical trials of treatments used in oral lichen planus. *Br J Dermatol*. 2005;153:336–41.
14. Lundquist G, Forsgren H, Gajecki M, Emtestam L. Photochemotherapy of oral lichen planus: A controlled study. *Oral Surg Oral Med Oral Pathol Oral Radiol Endod*. 1995;79:554–8.
15. Kunte C, Erlenkeuser-Uebelhoer I, Michelsen S, Scheerer-Dhungel K, Plewig G. Treatment of therapy-resistant erosive oral lichen planus with extracorporeal photopheresis (ECP). *J Dtsch Dermatol Ges*. 2005;3:889–94.
16. Marchesseau-Merlin AS, Perea R, Kanold J, Demeocq F, Souteyrand P, D’Incan M. Photopheresis: An alternative therapeutic approach in corticoreistant erosive oral lichen planus. *Ann Dermatol Venereol*. 2008;135:209–12.
17. Bécherel PA, Bussel A, Chosidow O, Rabian C, Piette JC, Francès C. Extracorporeal photochemotherapy for chronic erosive lichen planus. *Lancet*. 1998;14:805.

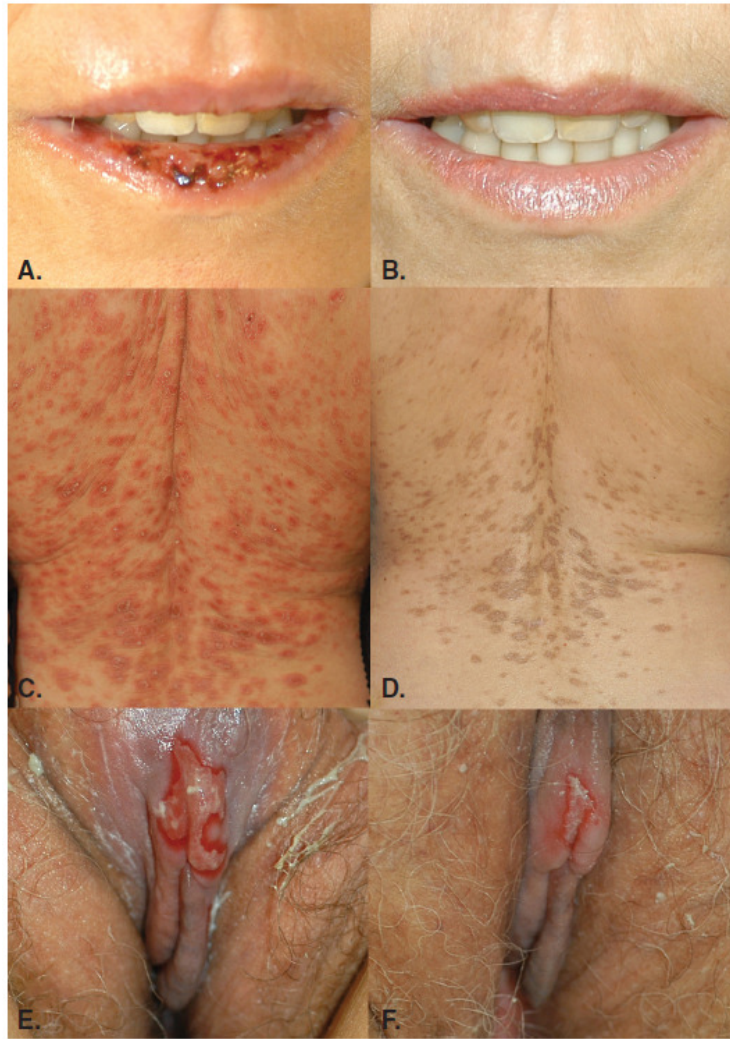


Figure 1. Mucosal and cutaneous lesions before (A, C, E) and after (B, D, F) eight sessions of extracorporeal photochemotherapy.