

AperTO - Archivio Istituzionale Open Access dell'Università di Torino

**Effectiveness of electrochemotherapy in treatment of a recurrent squamous cell carcinoma of the scalp.**

**This is the author's manuscript**

*Original Citation:*

*Availability:*

This version is available <http://hdl.handle.net/2318/94166> since

*Published version:*

DOI:10.1684/ejd.2011.1334

*Terms of use:*

Open Access

Anyone can freely access the full text of works made available as "Open Access". Works made available under a Creative Commons license can be used according to the terms and conditions of said license. Use of all other works requires consent of the right holder (author or publisher) if not exempted from copyright protection by the applicable law.

(Article begins on next page)



UNIVERSITÀ DEGLI STUDI DI TORINO

This is an author version of the contribution published on:

Marenco F, Nardo T, Savoia P, Bernengo MG  
Effectiveness of electrochemotherapy in treatment of a recurrent squamous  
cell carcinoma of the scalp.  
EUROPEAN JOURNAL OF DERMATOLOGY (2011) 21  
DOI: 10.1684/ejd.2011.1334

Correspondence

Eur J Dermatol. 2011 Jul-Aug;21(4):618-9.  
doi: 10.1684/ejd.2011.1334.

### **Effectiveness of electrochemotherapy in treatment of a recurrent squamous cell carcinoma of the scalp**

Federica MARENCO, Tiziana NARDO', Paola SAVOIA, Maria Grazia BERNENGO

Department of Biomedical Sciences and Human Oncology, v. Cherasco 23,10126 Torino, Italy  
Mail: paola.savoia@unito.it

Electrochemotherapy (ECT) has recently emerged as a treatment for cutaneous and subcutaneous lesions from different malignancies, including squamous cell carcinoma (SCC), with curative or palliative intent [1]. It combines the delivery of electric pulses into the lesions with the effect of anticancer drugs such as bleomycin and cisplatin; the increased cell membrane permeability following the electric pulse enhances drug uptake into tumoral cells and raises the cytotoxicity of these intravenously or intralesionally administered molecules. With respect to surgery, radiotherapy and other standard treatments [2], ECT acts rapidly on multiple lesions with limited side effects and no functional impairment; moreover, repeated sessions can be performed to achieve or maintain the clinical response.

We present an 80-year-old male admitted at our institution with multiple erythematous nodules, ranging from 0.5 to 1.5 cm in diameter, at the right fronto-parieto-occipital region (figure 1A). One month before he had undergone the excision of an infiltrating squamous cell carcinoma of the vertex; due to its large extension and infiltrating growth a cycle of radiotherapy immediately followed surgery but was interrupted for the appearance of multiple histologically confirmed secondary lesions surrounding the treated area. Due to the number and extension of nodules, standard approaches were excluded; we therefore performed ECT. Treatment was carried out under mild general anaesthesia, with 15 mg/m<sup>2</sup> intravenous bleomycin. Electrical pulses were generated and applied using the Cliniporator TM device (IGEA Ltd.) and type III hexagonal electrodes. A response was already observed at week 2 after treatment (figure 1B). At week 8, a relapse of 3 lesions was observed: the recurrences appeared as small necrotic ulcers with erythematous and infiltrated borders, the largest diameter measuring 3.5 cm. Thus, a second ECT was performed and a new complete regression was obtained; at week 4 the infiltration was no longer evident and only residual superficial ulcers covered by necrotic crusts were present. Unfortunately, two months after treatment the patient developed parotid gland and regional lymph node involvement and died 3 months later of a systemic progression.

Since the early 1990s, clinical and preclinical studies have been conducted on ECT, many including cutaneous and mucosal SCC [2, 3]; but only recently has ECT entered clinical practice and its use in SCC remains limited.

The most recent ECT prospective non-randomized trials [2, 4] included SCC patients: a good clinical activity was reported, with no significant differences in response rates according to nodule size, and without relevant side effects. A recent paper by Landstrom et al. [5] described the results obtained in 6 cases of head and neck skin cancer (HNSC), including 3 SCC: in 4/6 cases, tumour eradication with satisfactory cosmetic results was obtained after only one ECT session, suggesting the alternative role of ECT in complicated skin cancers. In another study including 9 SCC [6], an 80% CR rate was achieved. The remaining

3 patients achieved a PR, but the reduction in nodule size allowed for surgical excision, confirming the role of ECT also as a neoadjuvant treatment. In our patient, with the infeasibility of surgery and radiotherapy, ECT represented a valuable therapeutic option; in fact, with this relatively simple and well-tolerated procedure, a satisfactory and prompted response was obtained. Another relevant point was the possibility of successfully retreating relapsed lesions, maintaining a good local control of the disease. However, ECT remains a local treatment, which does not prevent disease progression. ECT can be considered as a radical treatment in cases with limited disease with a more indolent behaviour, where surgery would cause a cosmetic and functional impairment.

Disclosure.

Financial support: none.

Conflict of interest: none.

1. Marty M, Sersa G, Garbay JR, et al. Electrochemotherapy—Aneasy, highly effective and safe treatment of cutaneous and subcutaneous metastases: results of ESOPE (European Standard Operating Procedures of Electrochemotherapy) study. *Eur J Cancer* 2006; 4 (Suppl.): 3-13.
2. Arora A, Attwood J. Common skin cancers and their precursors. *Surg Clin North Am.* 2009; 89: 703-12.
3. Bloom DC, Goldfarb PM. The role of intratumour therapy with electroporation and bleomycin in the management of advanced squamous cell carcinoma of the head and neck. *Eur J Surg Onc* 2005; 31: 1029-35.
4. Campana LG, Mocellin S, Basso M, et al. Bleomycin-based electrochemotherapy: clinical outcome from a single institution's experience with 52 patients. *Ann Surg Onc* 2009; 16: 191-9.
5. Landström FJ, Nilsson CO, Crafoord S, Reizenstein JA, Adamsson GB, Löfgren LA. Electroporation therapy of skin cancer in the head and neck area. *Dermatol Surg* 2010; 36: 1245-50.
6. Gargiulo M, Moio M, Monda G, Parascandolo S, Cubicciotti G. Electrochemotherapy: actual considerations and clinical experience in head and neck cancers. *Ann Surg* 2010; 251: 773.

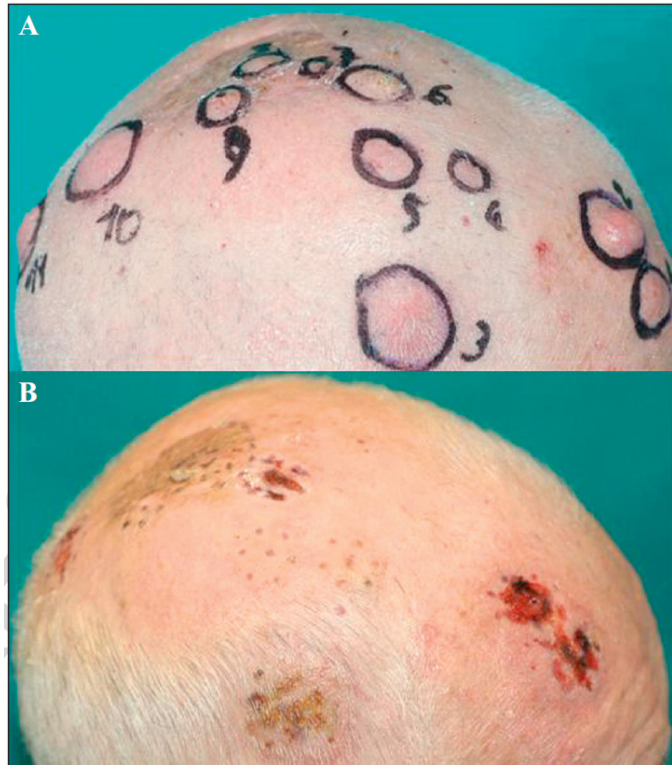


Figure 1. Recurrences of scalp squamous cell carcinoma at right fronto-parieto-occipital region before (A) and 2 weeks after (B) 1st ECT.