

AperTO - Archivio Istituzionale Open Access dell'Università di Torino

**Transvaginal Natural Orifice Transluminal Endoscopic Surgery-Assisted Minilaparoscopic Nephrectomy: A Step Towards Scarless Surgery**

**This is the author's manuscript**

*Original Citation:*

*Availability:*

This version is available <http://hdl.handle.net/2318/137356> since 2017-12-03T10:29:48Z

*Published version:*

DOI:10.1016/j.eururo.2010.09.038

*Terms of use:*

Open Access

Anyone can freely access the full text of works made available as "Open Access". Works made available under a Creative Commons license can be used according to the terms and conditions of said license. Use of all other works requires consent of the right holder (author or publisher) if not exempted from copyright protection by the applicable law.

(Article begins on next page)



## UNIVERSITÀ DEGLI STUDI DI TORINO

This Accepted Author Manuscript (AAM) is copyrighted and published by Elsevier. It is posted here by agreement between Elsevier and the University of Turin. Changes resulting from the publishing process - such as editing, corrections, structural formatting, and other quality control mechanisms - may not be reflected in this version of the text. The definitive version of the text was subsequently published in

### **Transvaginal Natural Orifice Transluminal Endoscopic Surgery-Assisted Minilaparoscopic Nephrectomy: A Step Towards Scarless Surgery**

**Volume:** 60

**Issue:** 4

**Pages:** 862-866

**DOI:** 10.1016/j.eururo.2010.09.038

**Published:** OCT 2011

You may download, copy and otherwise use the AAM for non-commercial purposes provided that your license is limited by the following restrictions:

- (1) You may use this AAM for non-commercial purposes only under the terms of the CC-BY-NC-ND license.
- (2) The integrity of the work and identification of the author, copyright owner, and publisher must be preserved in any copy.
- (3) You must attribute this AAM in the following format: Creative Commons BY-NC-ND license (<http://creativecommons.org/licenses/by-nc-nd/4.0/deed.en>)

**DOI:** 10.1016/j.eururo.2010.09.038

## Abstract

The feasibility of a transvaginal hybrid natural orifice transluminal endoscopic surgery (NOTES) nephrectomy has already been demonstrated using standard laparoscopic ports through the abdominal wall. We evaluated the feasibility of a transvaginal NOTES-assisted minilaparoscopic nephrectomy (mLN).

The patient is positioned in a semilumbotomy position with legs separated to allow for vaginal access. A 3.5-mm port is placed at the umbilicus for a 30° laparoscope; two 3.5-mm ports are placed in the flank in the same location as for a standard transperitoneal nephrectomy; and a 12-mm port is placed through the vagina, perforating the vaginal wall. Kidney dissection is performed following the steps of a traditional nephrectomy. The renal pedicle is dissected and secured with Hem-o-Lok clips through the vaginal access port. The specimen is then extracted through an extended incision in the posterior wall of the vagina.

We treated five patients. The average operative time was 120 min, blood loss was 160 ml, and no complications were recorded.

Our initial experience suggests that transvaginal NOTES-assisted mLN is feasible and appears to be safe. It is simpler than a pure NOTES procedure and ensures excellent cosmetic results.

## Keywords

- NOTES;
- Laparoscopy;
- Nephrectomy;
- Renal cancer;
- Minilaparoscopy

---

## 1. Case series

Natural orifice transluminal endoscopic surgery (NOTES) has been successfully performed experimentally via transgastric, transcolonic, and transvesical routes [1]. In the field of human urology, transvaginal access is the most utilised, and a nephrectomy is the intervention of choice [2] and [3].

Although feasible, a pure NOTES nephrectomy is technically demanding and time consuming [4], and thus a laparoscopic approach with 5- and 12-mm port placement through the abdominal wall has been combined with NOTES to develop a “hybrid” technique [3], [4] and [5]. Invasiveness of hybrid NOTES can be reduced further with the use of 3.5-mm ports instead of the 5- and 12-mm abdominal laparoscopic ports

when performing a transvaginal NOTES-assisted minilaparoscopic nephrectomy (mLN). We present our experience with transvaginal NOTES-assisted mLN to demonstrate the feasibility of the technique.

After ethics committee approval, five patients underwent a transvaginal NOTES-assisted mLN at our institution between November 2009 and May 2010.

### 1.1. Surgical technique

Under general anaesthesia, the patient is placed in a semilumbotomy position with legs separated to allow for vaginal access (Fig. 1).

A pneumoperitoneum is achieved using a Veress needle at the level of the umbilicus, then a 3.5-mm (or 5-mm) port (Storz Medical System, Tuttlingen, Germany) is placed at the umbilicus and a 3-mm 30° laparoscope is used (Storz Medical System, Tuttlingen, Germany). Under direct vision, two 3.5-mm (or 3.9-mm) ports are placed in the abdomen using the same technique as for a standard transperitoneal nephrectomy. Vaginal walls are retracted, and the cervix is anteriorly pulled to expose the posterior fornix. Finally, a 12-mm port designed for morbidly obese patients (Applied Medical Rancho Santa Margarita, CA, USA) is placed through the vagina into the abdominal cavity, perforating the vaginal wall in the posterior cul de sac (Fig. 2). At that time, a carbon dioxide (CO<sub>2</sub>) insufflation tube is connected to the 12-mm port.

The kidney dissection is performed by the first operator following the steps of a traditional transperitoneal nephrectomy using 3-mm instruments (Storz Medical System, Tuttlingen, Germany) through the abdominal wall, and a 35- or 45-cm suction/irrigation device (Elefant, Coloplast GmbH, Hamburg Germany) is transvaginally used by the assistant (Fig. 3). The renal pedicle is identified and progressively dissected, then the artery and vein are freed by the first operator. Renal artery, vein (Fig. 4), and ureter are secured after positioning Hem-o-Lok clips (Weck Closure Systems, Research Triangle Park, NC, USA) and then divided. A 35- or 45-cm (if available) Hem-o-Lok applier (Weck Closure Systems, Research Triangle Park, NC, USA) is used through the vaginal wall port. When the Hem-o-Lok positioning is not possible through the 12-mm port, the pedicle can be managed with a suture secured with intracorporeal knots through the abdominal ports. The surgical specimen is extracted in a sterile retrieval bag under direct visualisation through an extended transvaginal incision in the posterior wall of the vagina. Finally, the culpotomy is transvaginally closed with running 2-0 absorbable sutures.

No skin sutures are required; small pieces of adhesive strips are applied to approximate the skin edges of the minilaparoscopic incisions.

## 1.2. Postoperative follow-up

Patients were visited at 7, 15, and 30 d after surgery. After 30 d, overall patient satisfaction was investigated with the following question: "Overall, how satisfied are you with the intervention? (1: extremely dissatisfied; 2: dissatisfied; 3: uncertain; 4: satisfied; or 5: extremely satisfied)." After 3 mo, the Patient Scar Assessment Questionnaire and Scoring System (PSAQ) was administered [6].

Baseline characteristics of five patients are summarised in Table 1. All interventions were completed using transvaginal NOTES-assisted mLN with no conversions to standard laparoscopy. Perioperative data are summarised in Table 2.

In both cases of suspected kidney cancer (Fig. 5), pathology revealed a pT1b renal cell carcinoma (RCC) with complete intraparenchymal growth.

No complications were recorded during the postoperative stay and the follow-up visits, and no patients reported pelvic pain or dyspareunia.

At day 30, patients were either totally satisfied ( $n = 4$ , 80%) or satisfied ( $n = 1$ , 20%) with the intervention. After 3 mo, PSAQ score was 34 (minimum score [best results]: 28; maximum score [worst results]: 112).

## 2. Discussion

The technical feasibility of a pure NOTES nephrectomy has already been reported by Kaouk et al. [4]. The authors concluded that the procedure was tedious, time consuming, and technically demanding. For these reasons, hybrid NOTES is often performed instead of a pure NOTES procedure using adjunctive transabdominal laparoscopic ports (5, 10, and 12 mm) or using a single umbilical port [3], [5] and [7].

Castillo et al reported a NOTES nephrectomy using one transvaginal port, one 12-mm umbilical port, and one 3.5-mm abdominal port, demonstrating the feasibility of the technique [8].

One of the most important advantages of using mini (3.5- or 3.9-mm) ports is that mini-incisions do not necessitate suturing, thus allowing for nearly invisible scars. Moreover, some authors have demonstrated that minilaparoscopy significantly reduces pain, hospital stays, and recovery time when compared to standard laparoscopy [9].

To our knowledge, no case of a hybrid NOTES-assisted nephrectomy has been reported using only mini adjunctive ports. We used three ports placed as for a standard nephrectomy. The 12-mm port is placed

under direct visualisation by the assistant, while the first surgeon displaces the bowel and retracts the vaginal walls and cervix to expose the posterior fornix. By using this technique we did not have bladder or rectum injuries during port placement.

Kidney and pedicle dissection was performed as usual and followed a standard laparoscopic nephrectomy. The transvaginal port is essential during these steps and overcame the technical limitations of minilaparoscopy: CO<sub>2</sub> insufflation was connected to this port, maintaining an adequate abdominal pressure, and the assistant helped the first surgeon with the suction device during the dissection phase. Once the renal pedicle was dissected, the artery and vein were managed with Hem-o-Lok clips placed transvaginally. Again, the 12-mm port overcame the limitations of the 3.5-mm ports, which do not permit the use of Hem-o-Lok or clip applicators, and allowed for secure ligation of vessels. We used this device in all cases, but when the angle of the device is such that the pedicle cannot be accessed, vessels can be managed with a suture secured with intracorporeal knots.

Of interest, operative times (120 min) were comparable to a standard laparoscopic nephrectomy—an additional advantage compared to a “pure” procedure.

We did not record any intraoperative complications, postoperative stays were uneventful, and no complications were recorded during follow-up, suggesting the safety of this procedure.

Even if sexual dysfunction may complicate a vaginal incision, literature reporting on vaginal surgery suggests that sexual dysfunction is a rare event after vaginal surgery [10]. Our experience confirmed this because no patient reported pelvic pain or dyspareunia.

As far as cosmetic results are concerned, a hybrid procedure can impair the cosmesis with respect to pure NOTES due to the need for skin incisions. Nevertheless, the mini-incision required no suturing, and the ensuing scars were nearly invisible 3 mo after surgery (Fig. 6). The excellent cosmetic results were confirmed by the PSAQ score.

This study has the limitations of small sample size and selection bias because we chose the patients to treat with this procedure (nonmorbidly obese patients, no previous major abdominal surgery, and renal masses not suitable for partial nephrectomy). Finally, the technique required three abdominal ports in lieu of the two ports used by other authors, although it should be noted that the adjunctive mini-incisions had a negligible impact on cosmetic results.

Despite these limitations, the results of our study confirm that transvaginal NOTES-assisted mLN is feasible and appears to be safe in this small series of five patients.

The minilaparoscopic and NOTES approaches are complementary and allowed us to perform a procedure that is technically similar to a standard procedure and simpler than pure NOTES, while having excellent cosmetic results, as proven by objective data.

Further studies are required to understand the future roles for transvaginal NOTES (both pure and hybrid) in the management of urologic diseases.

**Author contributions:** Francesco Porpiglia had full access to all the data in the study and takes responsibility for the integrity of the data and the accuracy of the data analysis.

*Study concept and design:* Porpiglia, Fiori.

*Acquisition of data:* Morra.

*Analysis and interpretation of data:* Morra, Fiori.

*Drafting of the manuscript:* Fiori.

*Critical revision of the manuscript for important intellectual content:* Scarpa.

*Statistical analysis:* None.

*Obtaining funding:* None.

*Administrative, technical, or material support:* None.

*Supervision:* Scarpa.

*Other (specify):* None.

**Financial disclosures:** I certify that all conflicts of interest, including specific financial interests and relationships and affiliations relevant to the subject matter or materials discussed in the manuscript (eg, employment/affiliation, grants or funding, consultancies, honoraria, stock ownership or options, expert testimony, royalties, or patents filed, received, or pending), are the following: None.

**Funding/Support and role of the sponsor:** None.

EU-ACME question

Please visit [www.ed-acme.org/europeanurology](http://www.ed-acme.org/europeanurology) to answer the following EU-ACME question online (the EU-ACME credits will be attributed automatically).

Question

NOTES-assisted minilaparoscopic nephrectomy:

A.

Could become the gold standard for “simple” nephrectomy

B.

Could become the gold standard for radical nephrectomy

C.

Allows performance of a procedure that is technically similar to a standard procedure and simpler than pure NOTES

D.

Can be proposed to all patients with small renal cell carcinoma

References

- W.M. White, G.P. Haber, M.J. Doerr, M. Gettman
- **Natural orifice transluminal endoscopic surgery**
- Urol Clin North Am, 36 (2009), pp. 147–155
- 
- G.N. Box, M. Bessler, R.V. Clayman
- **Trans-vaginal access: current experience and potential implications for urologic applications**
- J Endourol, 23 (2009), pp. 753–757
- 
- A.W. Branco, A.J. Branco Filho, W. Kondo *et al.*
- **Hybrid transvaginal nephrectomy**
- Eur Urol, 53 (2008), pp. 1290–1294
- 
- J.H. Kaouk, G.-P. Haber, R.K. Goel *et al.*
- **Pure natural orifice transluminal endoscopic surgery (NOTES) transvaginal nephrectomy**



- Eur Urol, 57 (2010), pp. 723–726
- 
- A. Alcaraz, L. Peri, A. Molina *et al.*
- **Feasibility of transvaginal NOTES-assisted laparoscopic nephrectomy**
- Eur Urol, 57 (2010), pp. 233–237
- 
- P. Durani, D.A. McGrouther, M.W. Ferguson
- **The Patient Scar Assessment Questionnaire: a reliable and valid patient-reported outcomes measure for linear scars**
- Plast Reconstr Surg, 123 (2009), pp. 1481–1489
- 
- R. Sotelo, R. de Andrade, G. Fernández *et al.*
- **NOTES hybrid transvaginal radical nephrectomy for tumor: stepwise progression toward a first successful clinical case**
- Eur Urol, 57 (2010), pp. 138–144
- 
- O.A. Castillo, I. Vidal-Mora, R. Camposa *et al.*
- **Nefrectomía laparoscópica simple con asistencia de notes trans-vaginal y uso de instrumentos laparoscópicos estándar**
- Actas Urol Esp, 33 (2009), pp. 767–770
- 
- Y.W. Novitsky, K.W. Kercher, D. Czerniach *et al.*
- **Advantages of mini-laparoscopic vs conventional laparoscopic cholecystectomy. Results of a prospective randomized trial**
- Arch Surg, 140 (2005), pp. 1178–1183
- 
- H.S. Tunuguntla, A.E. Gousse
- **Female sexual dysfunction following vaginal surgery: a review**
- J Urol, 175 (2006), pp. 439–446

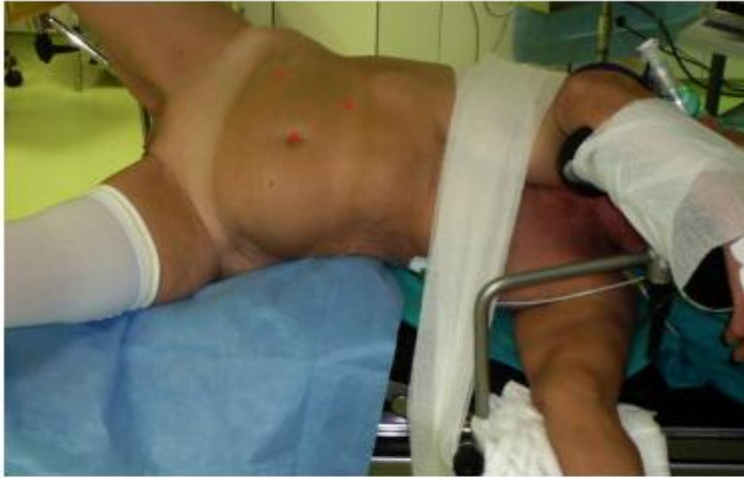

Fig. 1.

Position of the patient during right transvaginal natural orifice transluminal endoscopic surgery–assisted minilaparoscopic nephrectomy. The patient is placed in a semilumbotomy position with separated legs to allow vaginal access. Red points indicate the sites of port placement.

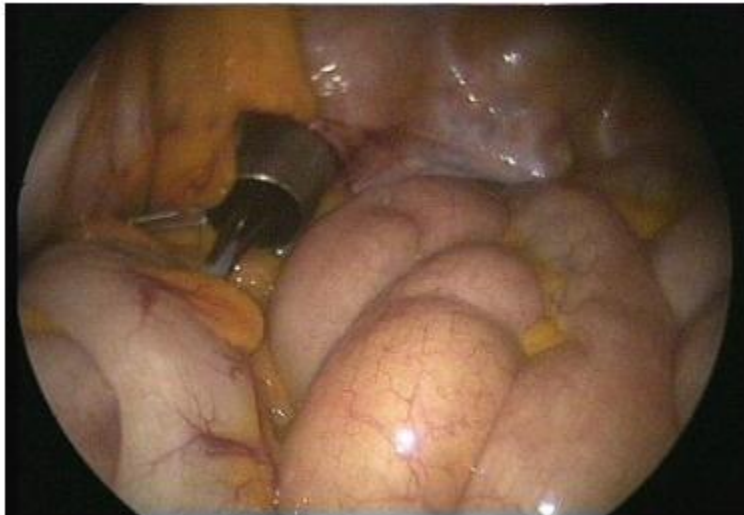

Fig. 2.

A 12-mm port is placed through the vagina into the abdominal cavity, perforating the vaginal wall in the posterior cul de sac under direct vision.

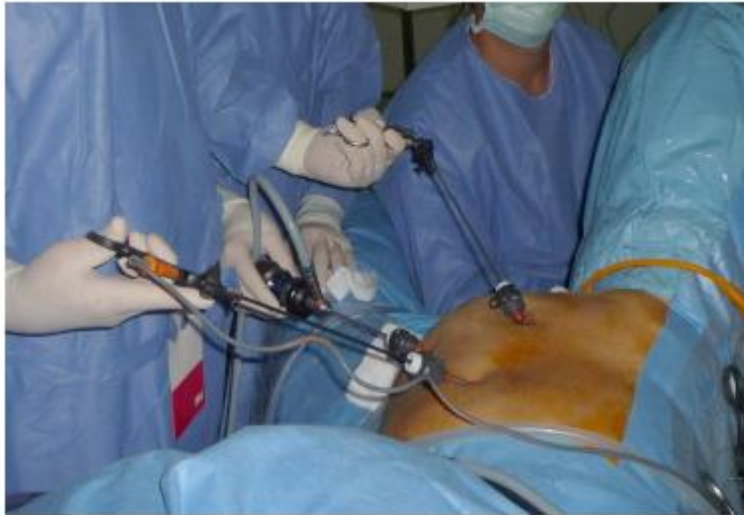

Fig. 3.

Disposition of ports and surgeons during the procedure. The first surgeon uses 3-mm instruments placed through the abdominal wall, and the assistant works with instruments inserted through the 12-mm port placed in the vagina.

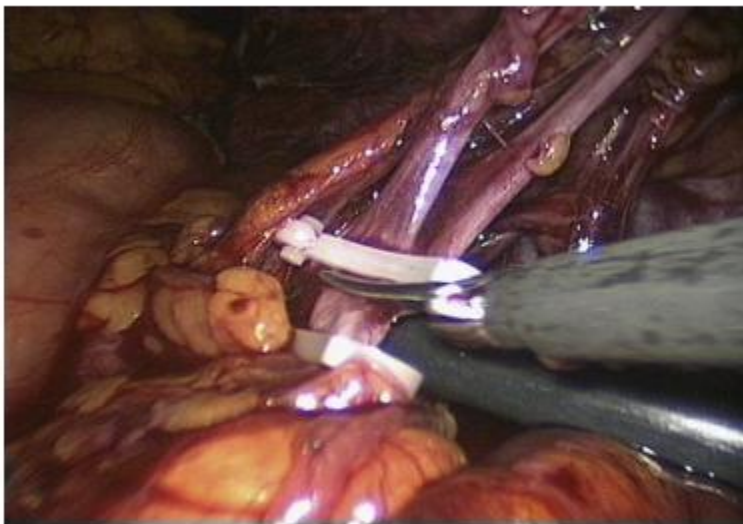


Fig. 4.

Left renal vein is secured with Hem-o-Lok clips and sectioned. The Hem-o-Lok applier is inserted through the vaginal port and utilised by the assistant.

Table 1.

Baseline characteristics of all five patients\*

Characteristic	
Age, yr	58 (11.9)
Body mass index	24.8 (1.6)
American Society of Anaesthesiologists score	2.4 (0.5)
Affected kidney	
left	3
right	2
Patients with tumours, No. (%)	
Tumour size, cm	5.2 (3.5)
Patients with renal atrophy, No. (%)	
Due to ureteral stone, No. (%)	1 (33)
Due to ureteropyelic obstruction, No. (%)	2 (67)
Significant comorbidities, No. (%)	
Hypertension	3 (60)
Diabetes	1 (20)
Hypercholesterolaemia	1 (20)
Previous gynaecological surgery	1 (20)
Previous surgery for cancer	1 (20)

\* Data are presented as mean plus standard deviation.

Table 2.

Perioperative data from all five patients<sup>\*</sup>

Perioperative variables	
Time for patient positioning, min	12.8 (2.1)
Use of 5-mm telescope, %	2 (40)
Control of the renal pedicle with suture (intracorporeal knots)	0
Operative time, min	120 (15.8)
Operative time, min, range	100–140
Intraoperative complications, %	0
Estimated blood losses, ml	160 (54)
Range of estimated blood loss, ml	100–200
Patients receiving transfusion, %	0
Use of analgaesic (buprenorphine cloridate, 0.3 mg, IV), d	1
Surgical drain removal, d	1.6 (0.5)
Mobilisation, d	1.6 (0.5)
Oral feeding, d	1.4 (0.5)
Postoperative complications, %	0
Postoperative hospital stay, d	2.6 (0.5)
Range of postoperative hospital stay, d	2–3

IV = intravenous.

\* Data are presented as mean plus standard deviation.

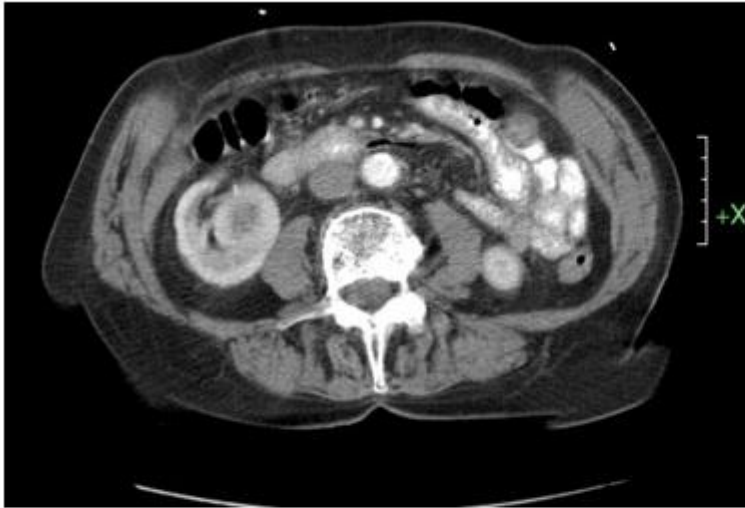

Fig. 5.  
Computed tomography scan shows right renal tumour with totally intraparenchymal growth. Pathology revealed a pT1b renal cell carcinoma.

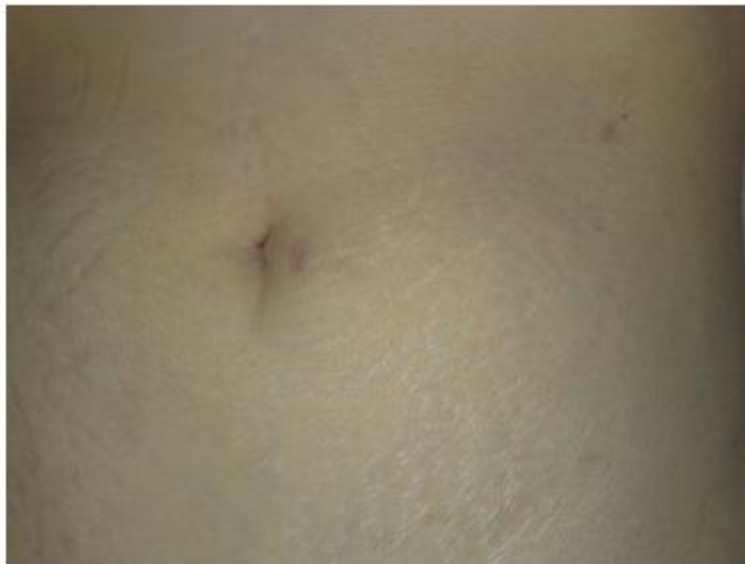

Fig. 6.  
Cosmetic results at 3 mo after a left natural orifice transluminal endoscopic surgery–assisted minilaparoscopic nephrectomy. Note the small scars at the level of the abdominal wall.