

AperTO - Archivio Istituzionale Open Access dell'Università di Torino

## New approaches to the treatment of diabetic retinopathy.

### **This is the author's manuscript**

*Original Citation:*

*Availability:*

This version is available <http://hdl.handle.net/2318/130930> since

*Published version:*

DOI:10.1111/j.1463-1326.2011.01415.x

*Terms of use:*

Open Access

Anyone can freely access the full text of works made available as "Open Access". Works made available under a Creative Commons license can be used according to the terms and conditions of said license. Use of all other works requires consent of the right holder (author or publisher) if not exempted from copyright protection by the applicable law.

(Article begins on next page)



# UNIVERSITÀ DEGLI STUDI DI TORINO

***This is an author version of the contribution published on:***

*Questa è la versione dell'autore dell'opera:*

*[Diabetes Obes Metab. 2011 Sep;13(9):784-90. doi: 10.1111/j.1463-1326.2011.01415.x]*

***The definitive version is available at:***

*La versione definitiva è disponibile alla URL:*

*[<http://onlinelibrary.wiley.com/doi/10.1111/j.1463-1326.2011.01415.x/full>]*

# New approaches to the treatment of diabetic retinopathy

M. Porta\*,

P. Maldari and

F. Mazzaglia

## Abstract

Diabetic retinopathy (DR) is a leading cause of visual impairment in working age in industrialized countries. It is classified as non-proliferative (mild, moderate or severe) and proliferative, with diabetic macular oedema potentially developing at any of these stages. The prevalence and incidence of DR increase with diabetes duration and worsening of metabolic and blood pressure control. Current approaches to prevent and/or treat DR include optimized control of blood glucose and blood pressure and screening for early identification of high-risk, although still asymptomatic, retinal lesions. Results from recent clinical trials suggest a role for blockers of the renin-angiotensin system (angiotensin-converting enzyme inhibitors and angiotensin II receptor blockers) and for fenofibrate in reducing progression and/or inducing regression of mild-to-moderate non-proliferative DR. Intravitreal administration of anti-vascular endothelial growth factor (VEGF) agents was shown to reduce visual loss in more advanced stages of DR, especially in macular oedema.

## Epidemiology and Classification

Diabetic retinopathy (DR) remains a leading cause of visual impairment in working age in industrialized countries and can reach its more advanced stages in the almost total absence of symptoms. The prevalence of DR is about 70% in patients with type 1 diabetes and 40% among those with type 2, with no differences by gender [1]. The prevalence increases with disease duration and practically all patients with type 1 diabetes develop retinopathy, proliferative in half the cases, within 20 years of the diagnosis. The most serious forms of retinopathy, proliferative and macular oedema, occur in 23 and 14% of patients with type 1 and type 2 diabetes, respectively. At our screening centre in Turin, out of 6857 consecutive patients screened in 1992–2003, the prevalence of retinopathy was 39%, of which 19% mild, 11% moderate and more severe in the remaining cases.

Alterations of retinal capillaries are at the basis of DR and include multiple occlusions, increased permeability of the vessel wall and, in the proliferative form, growth of newly formed vessels. Occlusions cause areas of ischaemia and focal (microaneurysms) or generalized dilatation of the capillaries. Dilated, fragile and hyperpermeable vessels result in microhaemorrhages and leakage of serum and lipoproteins in the neuroretina, with the formation of oedema and the so-called hard exudates. Occlusion of vessels may result in focal retinal ischaemia, which may be manifested as white-grayish areas with blurred margins, or cotton wool spots. The presence of these lesions defines non-proliferative retinopathy, which can be mild, moderate or severe, and can develop into two forms at high risk of visual loss: diabetic macular oedema (DME) and proliferative diabetic retinopathy (PDR) (figures 1, 2) [2].

Figure 1. Proliferative retinopathy with tufts of new vessels accompanied by fibroglial tissue departing from the optic disc. There are signs of retinal tear and intravitreal bleeding. Some hard exudates in the macular region indicate the presence of macular oedema.

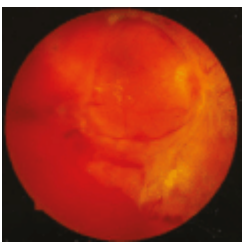
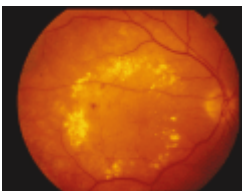


Figure 2. Diabetic macular edema with thickening of the retina in the macular region and deposition of hard exudates.



When the lesions of DR involve the macula lutea, the part of the retina responsible for vision of colours and details, severe functional impairment may result. DME affects primarily patients with type 2 diabetes and, as these represent more than 90% of the diabetic population, it is now the main cause of visual impairment in diabetes. Progressive ischaemia of the peripheral retina can cause PDR, with growth of new vessels which may invade the vitreous and give rise to vitreous haemorrhages and development of fibroglial tissue. The latter, by contracting, may cause retinal detachment. Severe ischaemia may proceed to the anterior chamber with development of iris neovascularization (rubeosis iridis), causing the terminal condition of neovascular glaucoma.

Although DR is considered predominantly a pathology of microvessels, increasing evidence points at degeneration of the neuroretina (mainly apoptosis of ganglion cells and glial activation) as an early event which may predate and perhaps contribute to microcirculatory abnormalities [3–7]. Damage of the neuroretina may result in loss of colour discrimination and contrast sensitivity, as detectable by electrophysiological studies in patients with short diabetes duration [8–10], and delayed multifocal electroretinographic implicit time may predict the development of early microangiopathy [11–13]. Metabolic and signalling pathways involved in retinal neurodegeneration may be shared with, and/or activate mechanisms involved in, the pathogenesis of microangiopathy [14].

## **Pathophysiology**

Among the possible mechanisms of glucose-induced vascular damage, potential targets for therapy, four hypotheses have been widely entertained: (i) increased flux through the polyol pathway, (ii) increased formation of advanced glycation end-products (AGEs), (iii) protein kinase C (PKC) activation, (iv) increased flux through the hexosamine pathway.

Aldose reductase (AR) is the key enzyme of the polyol pathway. It normally reduces toxic aldehydes to inactive alcohols and excess intracellular glucose to sorbitol while consuming NADPH with consequent hyperglycaemic pseudohypoxia [15] and increased susceptibility to intracellular oxidative stress [16]. However, sorbinil, an AR inhibitor did not modify the course of DR in a clinical trial [17].

Intracellular high glucose reacts with proteins, amino acids and nucleic acids via Schiff base condensation with amino groups, followed by irreversible rearrangement into Amadori products. Further Maillard reactions slowly produce AGE, which can also derive from earlier glycation products through glycooxidation or reactive dicarbonyl fragments generated from free glucose. AGE, in turn, can modify intracellular proteins [18], extracellular matrix [19] and circulating proteins, leading to activation of AGE receptors and production of inflammatory cytokines and growth factors. Inhibition of AGE by aminoguanidine prevents structural changes in experimental DR [20], but has not been tested in humans because of toxicity.

Intracellular high glucose increases the de novo synthesis of the lipid second messenger diacylglycerol, which in turn activates PKC synthesis [21], causing a number of effects, such as decreased synthesis of endothelial nitric oxide synthase and increased synthesis of endothelin-1, transforming growth factor  $\beta$ , plasminogen activator inhibitor-1 [22] and nuclear factor- $\kappa$ B (NF- $\kappa$ B) [23]. Ruboxistaurin, a specific inhibitor for the  $\beta$ -1 and -2 isoforms of PKC that are mostly activated in the diabetic retina, was developed and

subjected to clinical trials. Although its use was associated with better visual acuity than placebo in patients with DME, and although there were remarkably few side effects, this interesting agent was not registered with an indication for treatment of DR [24].

Excess fructose-6-phosphate derived from high availability of intracellular glucose can be transformed to glucosamine-6-phosphate and then to uridine diphosphate N-acetylglucosamine, which acts on serine and threonine residues of transcription factors, resulting in pathological changes in gene expression [25].

Brownlee and co-workers have hypothesized that the possible common denominator ('unifying mechanism') of these apparently independent biochemical pathways is high-glucose-induced excess production of reactive oxygen species (ROS) by the mitochondrial electron transport chain inside the endothelium, as a result of increased flux through the Krebs cycle [16,23]. ROS, by causing strand breaks in nuclear DNA, activate poly-(ADP-ribose) polymerase (PARP), which in turn inhibit GAPDH activity [26], therefore pushing metabolites from glycolysis in the upstream pathways mentioned above.

Benfotiamine, a thiamine derivative which can be administered orally, blocks all the above major pathways implicated in the pathogenesis of DR, and has been shown effective in preventing experimental DR [27]. However, clinical trials showing its effectiveness are still lacking.

### **Current Treatment Options**

Current possibilities to prevent and/or treat retinopathy include optimized control of blood glucose and blood pressure and screening for early identification of high-risk, although still asymptomatic, retinopathy.

The Diabetes Control and Complications Trial (DCCT) showed in patients with type 1 diabetes that optimized insulin treatment reduces the incidence of retinopathy by 76%, progression of mild-to-moderate non-PDR by 54% and the need for photocoagulation by 56% [28]. In patients with type 2 diabetes, the UK Prospective Diabetes Study (UKPDS) showed that, over 12 years, optimized metabolic control reduces progression of DR by 21% and the need for cataract surgery in 24% of the cases [29]. Follow-up of the patients involved in these studies showed that the beneficial effects of glycaemic control carry over in time in a sort of metabolic 'memory'[30] or 'legacy'[31], so that any period of life spent in good glycaemic control is 'accounted for' in the later prevention of retinopathy and other complications.

The UKPDS [32] also showed that reducing blood pressure (from 154/87 to 144/82 mmHg throughout 8 years) reduces the progression of DR by 34% and the overall risk of worsening of visual acuity by 47%, possibly by reducing DME. Until recently, the only intervention study to support a role for intensive hypertension control in the prevention of DR was the UKPDS. However, the Action in Diabetes and Vascular disease preterax and diamicron MR Controlled Evaluation (ADVANCE) [33] and Action to Control Cardiovascular Risk in Diabetes (ACCORD) [34] trials could not confirm an influence of blood pressure lowering on progression of DR. However, the patients in the UKPDS had larger reductions from higher blood pressure values than those in ADVANCE (−5.6 mmHg systolic pressure and −2.2 diastolic blood pressure from 145/81 mmHg, follow-up 4.3 years) [33] or in ACCORD, starting from 135/75 down to 128/68 with a median follow-up of 3.7 years [34], suggesting either that blood pressure lowering is more effective in poorly controlled hypertension or that longer follow-up is necessary to observe an effect on DR progression. No legacy effect was observed for blood pressure control in the UKPDS patients [31].

Current guidelines recommend to maintain glycated haemoglobin (HbA1c) below 7.0% and blood pressure below 130/80. However, achieving these targets is far from easy outside of clinical trials in the general diabetic population and data collected in the USA [35], France [36], UK [37], Italy [38] and other countries show that less than half, often less than one third, of patients do stay within those targets. Patients on insulin therapy have worse control than those treated with oral hypoglycaemic agents and, in turn, the latter fare worse than those on diet alone [37], presumably reflecting the levels of residual endogenous insulin secretion. Possible reasons for this high level of therapeutic failure include medical inertia, reduced patient adherence to prescriptions and the inadequacy of current pharmacological options and lifestyle measures.

Doctors often are poorly proactive in correcting high levels of HbA1c and blood pressure, as shown by a survey of practice in 30 American academic clinics [35]. That however may not be the only reason. In a 2-year clinical intervention study conducted in Liverpool on 200 patients with inadequate metabolic control, the best efforts of doctors went unrewarded and the only patients who obtained a drop in HbA1c were those treated with diet only [37]. The situation is particularly worrying in children and adolescents among whom, according to a recent report, less than 5% have an HbA1c lower than 7.0% and more than 80% are above 8.0% [39]. It may be that therapeutic goals are too ambitious, at least for younger and older age groups, as suggested for the latter by an increase in mortality observed when trying to push the HbA1c target below 6.5% [40]. It is also possible that individual patients are somehow set on different levels of diabetes severity, manifested by their values of HbA1c, in different stages of their life. Of course, this is a point of view that can be perceived as pragmatic or utilitarian, perhaps politically incorrect and certainly not supported by scientific evidence. However, if one considers goal focusing and personal motivation as contributors to improve metabolic control, then it stands out that only in exceptional circumstances of

limited duration, such as pregnancy, are levels of HbA1c below 6.5% reached in more than 80% of patients [41], often to drift back upwards after delivery.

In any case, the overall outcomes of diabetes care seem to be improving gradually worldwide, thanks to increasing awareness and availability of materials for self-monitoring and therapy. Data from the National Health and Nutrition Examining Survey (NHANES) 1999–2004 show a slow but steady increase in the percentage of US patients with HbA1c < 7.0% [42]. Probably in connection with this positive trend, the epidemiological data collected in Scandinavia and Wisconsin show a lower cumulative incidence of proliferative retinopathy in patients who contracted type 1 diabetes in more recent years [43,44]. In the DCCT/Epidemiology of Diabetes Interventions and Complications (EDIC) cohort, in 30 years of follow-up, the cumulative incidence of PDR was 21% in the patients originally randomized to optimized therapy during the DCCT, compared to 50% in those who remained all their life on conventional treatment [30].

There are, however, different approaches to interpreting these data. Progression of DR might be delayed rather than reduced in absolute terms, and the prolongation of life expectancy in patients may result in PDR appearing later rather than never at all. Data extrapolated from the DCCT dataset suggest that optimized insulin treatment would prolong life free of PDR by 14.7 years, of macular oedema by 8.2 years and life free of blindness by 7.7 years [45], all weighted against a two to three times higher risk of severe hypoglycaemia and increase in body weight. In addition, other predisposing factors not yet identified may play a role, as suggested by daily clinical experience and also quantified in the DCCT series. In fact, a post hoc analysis of all patients who participated in the trial showed that 10% of those who remained in the lowest HbA1c quintile (<6.87%) still developed DR, and 43% of those who remained in the worst quintile (HbA1c > 9.49%) did not develop retinal lesions during the study [46]. The search for genetic markers that make patients susceptible to, or protected by, microangiopathy remains an open field that has so far produced few generalizable results.

Currently, the main therapeutic tool at our disposal to prevent visual impairment consequent to DR is laser photocoagulation, which reduces the incidence of blindness from PDR by 95% and loss of visual acuity due to DME by 50% [47]. When laser is not sufficient, because retinopathy is too advanced and/or aggressive, vitreoretinal surgery (vitrectomy) becomes an option [48].

As blood glucose and blood pressure levels recommended by the guidelines cannot be reached in all patients, and as retinopathy may still develop in patients who are well controlled, it is paramount to organize systematic population screening programmes. Screening is a simple diagnostic procedure applied



to an entire population at risk aimed at identifying severe lesions that can be subjected to appropriate treatment before they have caused symptoms and functional damage. Screening does not represent a complete diagnostic workup but a method to identify patients who require further investigation. The efficacy of screening for high-risk DR has been shown in places such as Iceland or Sweden, where it has led to the reduction of diabetes-related blindness [49]. A countrywide screening programme has been established in the UK [50], and the results will become available in the coming years.

## **New Therapeutic Perspectives**

Lack of therapies targeting specific pathogenetic mechanisms remains a serious limitation to the prevention of diabetes-related blindness. Experimental evidence suggests involvement of the renin-angiotensin system (RAS) in that a physiologically active RAS is present in the eye, where angiotensin-2 appears to promote retinal expression of vascular endothelial growth factor (VEGF), through AT-1 receptors, and endothelial cell proliferation.

The EUrodiab Controlled trial of Lisinopril in Insulin-dependent Diabetes mellitus (EUCLID) study [51] reported that lisinopril, an angiotensin-converting enzyme inhibitor (ACEi), may reduce the progression of DR and the incidence of PDR in patients with type 1 diabetes. However, retinopathy was not a primary outcome of the study, which was also undersized from the statistical power point of view. The more recent ADVANCE/ADvance REtinal Measurements (ADREM) [52] appeared to show some protective effect, although not statistically significant, on progression of retinopathy of another ACEi, perindopril, associated with indapamide, a diuretic, in 1241 patients with type 2 diabetes. DIRECT (Diabetic Retinopathy Candesartan Trials) was a group of three multicentre, randomized, placebo-controlled studies designed to determine if the pharmacological blockade of the RAS by 32 mg of candesartan is able to prevent the onset of DR in patients with type 1 diabetes (DIRECT-Prevent 1) and to prevent progression or promote regression of DR in patients with type 1 (DIRECT-Protect 1) and 2 (DIRECT-Protect 2) diabetes [53,54]. A total of 5231 patients with normoalbuminuria were randomized. All patients with type 1 diabetes and 27% of those with type 2 diabetes were normotensive, while the remainder were taking non-RAS blockers for hypertension. The average follow-up was 4.7 years. Prevent-1 showed that candesartan reduces the risk of onset of retinopathy in type 1 diabetes by 35%, with an NNT of 18 patients treated to prevent one event. The severity of retinopathy at the end of the study was significantly more favourable in patients treated with candesartan in Prevent-1, Protect-1 [53] and Protect-2 [54]. The latter study showed a 13% reduction, not statistically significant, in the risk of progression of DR and a highly significant 34% increase in the probability of DR regression in type 2 diabetes, with Numbers Needed to Treat (NNT) of 21 patients treated to achieve an event. The results of DIRECT-Protect 2 represent the first description in the literature of regression of DR induced by a drug. The favourable effect of RAS blockade was confirmed by the Renin Angiotensin System Study (RASS) [55], conducted on 285 normotensive patients treated with 20 mg/day enalapril, 100 mg/day losartan or placebo. Enalapril and losartan reduced the likelihood of DR progression by 65 and 70%, respectively, in patients with type 1 diabetes. Although the results of the previous studies

are strongly indicative of a beneficial effect of RAS blockade in the early stages of DR, none of them was sufficient to grant registration for this specific indication. Hence, their use cannot be formally recommended in patients with DR who do not also have hypertension and/or microalbuminuria.

With reference to other possible mechanisms, the FIELD study showed a reduction by approximately 30% in the need for laser treatment for DME and PDR in patients treated with 200 mg/day fenofibrate. The drug prevented progression of existing retinopathy, regardless of its metabolic effects, but was not effective in terms of primary prevention [56]. Moreover, the retinopathy endpoint was a tertiary objective, measured in 1012 of 9795 patients enrolled in the study. Another clinical trial, ACCORD [34], confirmed reduced progression of DR in patients with type 2 diabetes treated with fenofibrate and statins, compared to patients treated with statins alone. The possible mechanisms for this unexpected action of fenofibrate remain to be elucidated.

Increased tendency to platelet aggregation in diabetes has long been suspected to play a role in determining capillary occlusions, which characterize the intermediate stages of non-P DR. Antiplatelet drugs such as aspirin, dipyridamole and ticlopidine underwent clinical trials in the 1970s and 1980s, showing modest efficacy in slowing the formation of new microaneurysms in early non-PDR [57,58] and no effects on evolution once DR reaches the preproliferative and proliferative stages [59]. Aspirin, however, does not increase the risk of bleeding from new vessels, so that proliferative retinopathy is not a contraindication to its use for other indications [59].

The only example of an effective mechanism-targeting treatment in DR is the use of anti-VEGF agents in DME. VEGF is upregulated in eyes with DME [60] and may be a major mediator of increased retinal permeability [61]. Anti-VEGF agents have to be injected directly into the vitreous body at regular intervals. Those under more advanced investigation include bevacizumab, ranibizumab and pegaptanib. While laser treatment permits at best to preserve visual acuity, clinical trials indicate that vision can improve with repeated injections of 1.25 mg bevacizumab [62], 0.5 mg ranibizumab [63] and 0.3 mg pegaptanib [64]. Mean best-corrected visual acuity improvements of 4.7 letters are obtained with a mean of five injections over 36 weeks with 0.3 mg pegaptanib and 5.6 letters with a median of nine injections over 1 year with 1.25 mg bevacizumab. VEGF Trap-Eye has also shown promising short-term results in a phase II study [65].

In addition, intravitreal triamcinolone has been widely used to treat DME and PDR in view of the inflammatory components in the pathogenesis of these sight-threatening stages of DR [66]. However, its benefits are short-lived, accompanied by high rates of cataract, glaucoma and infections, and the 3-year visual acuity is worse than obtained with grid laser treatment alone [67]. Visual acuity benefits of steroids are comparable to those of anti-VEGF in aphakic patients only [68].

## Conclusions

Overall, the results of the trials reported earlier suggest that interventions targeted at potential pathogenic mechanisms may be effective in early or mild, rather than moderate or more advanced stages of retinopathy in which damage to the capillary wall and the neuroretina may already be too advanced. Here, the question arises of whether a 'point of no return' exists in the natural history of DR. Antiplatelet agents appeared to slow down retinopathy at a very early stage characterized by the presence of microaneurysms alone [57,58], but not later when capillary occlusion becomes the prevailing feature [59]. Similarly, in DIRECT-Protect 2 [54], the administration of candesartan was associated with regression of minimal to mild retinopathy (occasional microaneurysms, microhaemorrhages, hard exudates and/or cotton wool spots), whereas non-proliferative stages, although classified as moderate, proved non-responsive, suggesting that also blockade of the RAS could be effective earlier than originally envisaged, again when damage of the capillary wall is minimal. This suggests that overactivation of the intraocular RAS may exert its pathogenic effects through mechanisms different from VEGF activation or that VEGF might have pathogenic effects independent of its ability to increase vessel wall permeability and angiogenesis, possibly involving its neuroprotective characteristics. However, data from FIELD [56] and ACCORD [34] appear to show that the progression of retinopathy can be stopped by fenofibrate at more advanced stages, moderate and severe non-proliferative, suggesting that different pathogenic mechanisms, responsive to different pharmacological agents, may intervene in various stages of this complication.

Progress in medical treatment of DR remains incomplete, just like our understanding of the mechanisms underlying this complication. More is achieved in the advanced stages, using VEGF inhibitors, than early in the evolution of DR but we are still far from the day when retinopathy will be treated aiming directly at a cause (as we do, for example, with iron for iron-deficient anaemia) or a mechanism (as with proton pump inhibitors for peptic ulcers). Causes for failure so far to identify a *primum movens* for retinopathy and, more generally, diabetic microangiopathy involve a series of good reasons: lack of funding and researchers dedicated to the specific problem, a presumably multifactorial pathogenesis, and the undoubted complexity of the phenomena involved. It is hoped that, as diabetes and its complications rise worldwide, the mere health and economic size of its consequences will stimulate further research into this field of human disease.

## Conflict of Interest

M. P. received payments for participating in clinical trials, advisory boards and/or lecturing by AstraZeneca, Fournier, Novartis, Pfizer and Takeda.

M. P. designed and wrote the manuscript. P. M. and F. M. contributed to writing and editing the manuscript.

## References

1

Klein R, Klein BEK, Moss SE. Prevalence of diabetes mellitus in southern Wisconsin. *Am J Epidemiol* 1984; 119: 54–61.

PubMed,

CAS,

2

Porta M, Bandello F. Diabetic retinopathy. A clinical update. *Diabetologia* 2002; 45: 1617–1634.

CrossRef,

PubMed,

CAS,

3

Antonetti DA, Barber AJ, Bronson SK et al. JDRF Diabetic Retinopathy Center Group (2006) Diabetic retinopathy: seeing beyond glucose-induced microvascular disease. *Diabetes* 2006; 55: 2401–2411.

CrossRef,

PubMed,

CAS,

4

Lieth E, Gardner TW, Barber AJ, Antonetti DA; Penn State Retina Research Group. Retinal neurodegeneration: early pathology in diabetes. *Clin Exp Ophthalmol* 2000; 28: 3–8.

5

Rungger-Brändle E, Dosso AA, Leuenberger PM. Glial reactivity, an early feature of diabetic retinopathy. *Invest Ophthalmol Vis Sci* 2000; 4: 1971–1980.

6

Lorenzi M, Gerhardinger C. Early cellular and molecular changes induced by diabetes in the retina. *Diabetologia* 2002; 44: 791–804.

7

Garcia-Ramírez M, Hernández C, Villarroel M et al. Interphotoreceptor retinoid-binding protein (IRBP) is downregulated at early stages of diabetic retinopathy. *Diabetologia* 2009; 52: 2633–2641.

8

Roy MS, Gunkel RD, Podgor MJ. Color vision defects in early diabetic retinopathy. *Arch Ophthalmol* 1986; 104: 225–228.

9

Shirao Y, Kawasaki K. Electrical responses from diabetic retina. *Prog Retin Eye Res* 2008; 17: 59–76.

CrossRef,

10

Barber AJ. A new view of diabetic retinopathy: a neurodegenerative disease of the eye. *Prog Neuropsychopharmacol Biol Psychiatry* 2003; 27: 283–290.

11

Bearse MA Jr, Adams AJ, Han Y et al. A multifocal electroretinogram model predicting the development of diabetic retinopathy. *Prog Retin Eye Res* 2006; 25: 425–448.

12

Bronson-Castain KW, Bearse MA Jr, Neuville J et al. Adolescents with type 2 diabetes: early indications of focal retinal neuropathy, retinal thinning, and venular dilation. *Retina* 2009; 29: 618–626.

13

Fletcher EL, Phipps JA, Ward MM, Puthussery T, Wilkinson-Berka JL. Neuronal and glial cell abnormality as predictors of progression of diabetic retinopathy. *Curr Pharm Des* 2009; 13: 2699–2712.

14

Asnaghi V, Gerhardinger C, Hoehn T, Adeboje A, Lorenzi M. A role for the polyol pathway in the early neuroretinal apoptosis and glial changes induced by diabetes in the rat. *Diabetes* 2003; 52: 506–511.

15

Williamson JR, Chang K, Frangos M et al. Hyperglycemic pseudohypoxia and diabetic complications. *Diabetes* 1993; 42: 801–813.

16

Brownlee M. Biochemistry and molecular cell biology of diabetic complications. *Nature* 2001; 414: 813–820.

17

Sorbinil Retinopathy Trial Research Group. A randomized trial of sorbinil, an aldose reductase inhibitor, in diabetic retinopathy. *Arch Ophthalmol* 1990; 108: 1234–1244.

18

Giardino I, Edelstein D, Brownlee M. Nonenzymatic glycosylation in vitro and in bovine endothelial cells alters basic fibroblast growth factor activity. A model for intracellular glycosylation in diabetes. *J Clin Invest* 1994; 94: 110–117.

19

Charonis AS, Reger LA, Dege JE et al. Laminin alterations after in vitro nonenzymatic glycosylation. *Diabetes* 1990; 39: 807–814.

20

Hammes HP, Martin S, Federlin K, Geisen K, Brownlee M. Aminoguanidine treatment inhibits the development of experimental diabetic retinopathy. *Proc Natl Acad Sci U S A* 1991; 88: 11555–11558.

21

Koya D, King GL. Protein kinase C activation and the development of diabetic complications. *Diabetes* 1998; 47: 859–866.

22

Koya D, Jirousek MR, Lin YW, Ishii H, Kuboki K, King GL. Characterization of protein kinase C beta isoform activation on the gene expression of transforming growth factor-beta, extracellular matrix components, and prostanoids in the glomeruli of diabetic rats. *J Clin Invest* 1997; 100: 115–126.

23

Nishikawa T, Edelstein D, Du XL et al. Normalizing mitochondrial superoxide production blocks three pathways of hyperglycaemic damage. *Nature* 2000; 404: 787–790.

24

Sheetz MJ, Aiello LP, Shahri N, Davis MD, Kles KA, Danis RP; for the MBDV Study Group. Effect of ruboxistaurin (RBX) on visual acuity decline over a 6-year period with cessation and reinstatement of therapy. Results of an open-label extension of the Protein Kinase C Diabetic Retinopathy Study 2 (PKC-DRS2). *Retina* 2011 [Epub ahead of print].

25

Du XL, Edelstein D, Rossetti L et al. Hyperglycemia-induced mitochondrial superoxide overproduction activates the hexosamine pathway and induces plasminogen activator inhibitor-1 expression by increasing Sp1 glycosylation. *Proc Natl Acad Sci U S A* 2000; 97: 12222–12226.

26

Du X, Matsumura T, Edelstein D et al. Inhibition of GAPDH activity by poly(ADP-ribose)polymerase activates three major pathways of hyperglycemic damage in endothelial cells. *J Clin Invest* 2003; 108: 1049–1057.

27

Beltramo E, Berrone E, Tarallo S, Porta M. Effects of thiamine and benfotiamine on intracellular glucose metabolism and relevance in the prevention of diabetic complications. *Acta Diabetologica* 2008; 45: 131–141.



28

The Diabetes Control and Complications Trial (DCCT) Research Group. The effect of intensive treatment of diabetes on the development and progression of long-term complications in insulin-dependent diabetes mellitus. *New Engl J Med* 1993; 329: 977–986.

29

UKPDS Group. Intensive blood-glucose control with sulphonylureas or insulin compared with conventional treatment and risk of complications in patients with type 2 diabetes (UKPDS 33). *Lancet* 1998; 352: 837–853.

30

The Diabetes Control and Complications Trial/Epidemiology of Diabetes Interventions and Complications (DCCT/EDIC) Research Group. Modern-day clinical course of type 1. Diabetes mellitus after 30 years' duration. The Diabetes Control and Complications Trial/Epidemiology of Diabetes Interventions and Complications and Pittsburgh Epidemiology of Diabetes Complications Experience (1983-2005). *Arch Intern Med* 2009; 169: 1307–1316.

31

Holman RR, Paul SK, Bethel MA, Matthews DR, Neil HAW. 10-Year follow-up of intensive glucose control in type 2 diabetes. *N Engl J Med* 2008; 359: 1577–1589.

32

UKPDS Group. Tight blood pressure control and risk of macrovascular and microvascular complications in type 2 diabetes: UKPDS 38. *BMJ* 1998; 317: 703–713.

33

ADVANCE Collaborative Group. Effects of a fixed combination of perindopril and indapamide on macrovascular and microvascular outcomes in patients with type 2 diabetes mellitus (the ADVANCE trial): a randomised controlled trial. *Lancet* 2007; 370: 829–840.

34

The ACCORD Study Group and ACCORD Eye Study Group. Effects of medical therapies on retinopathy progression in type 2 diabetes. *N Engl J Med* 2010; 363: 233–244.

35

Grant RW, Buse JB, Meigs JB, for the University Health System Consortium (UHC) Diabetes Benchmarking Project Team. Quality of diabetes care in U.S. Academic Medical Centers low rates of medical regimen change. *Diabetes Care* 2005; 28: 337–442.

36

Prévost G, Phan TM, Mounier-Venier C, Fontaine P. Control of cardiovascular risk factors in patients with type 2 diabetes and hypertension in a French national study (Phenomen). *Diabetes Metabol* 2005; 31: 479–485.

37

Gill GV, Woodward S, Pradhan S et al. Intensified treatment of type 2 diabetes. Positive effects on blood pressure but not glycaemic control. *Q J Med* 2003; 96: 833–836.

38

De Berardis G, Pellegrini F, Franciosi M et al. Quality of care and outcomes in type 2 diabetic patients. A comparison between general practice and diabetes clinics. *Diabetes Care* 2005; 28: 2637–2643.

39

Saunders SA, Wallymahmed M, Macfarlane IA. Glycaemic control in a type 1 diabetes clinic for younger adults. *Q J Med* 2004; 97: 575–580.

40

The Action to Control Cardiovascular Risk in Diabetes Study Group. Effects of intensive glucose lowering in type 2 diabetes. *N Engl J Med* 2008; 358: 2545–2559.

41

Mathiesen ER, Kinsley B, Amiel SA et al. On behalf of the Insulin Aspart Pregnancy Study Group. Maternal glycemic control and hypoglycemia in type 1 diabetic pregnancy. A randomized trial of insulin aspart versus human insulin in 322 pregnant women. *Diabetes Care* 2007; 30: 771–776.

42

Ford ES, Little RR, Li C, Mokdad AH. Trends in A1c concentrations among U.S. adults with diagnosed diabetes from 1999 to 2004. *Diabetes Care* 2008; 31: 102–104.

43

Hovind P, Tarnow L, Rossing K et al. Decreasing incidence of severe diabetic microangiopathy in type 1 diabetes. *Diabetes Care* 2003; 26: 1258–1264.

44

Klein R, Knudtson MD, Lee KE, Gangnon R, Klein BEK. The Wisconsin Epidemiologic Study of Diabetic Retinopathy XXII. The twenty-five-year progression of retinopathy in persons with type 1 diabetes. *Ophthalmology* 2008; 115: 1859–1868.

45

The Diabetes Control and Complications Trial Research Group. Lifetime benefits and costs of intensive therapy as practiced in the Diabetes Control and Complications Trial. *JAMA* 1996; 276: 1409–1415.

46

Zhang LY, Krzentowski G, Albert A, Lefevbre PJ. Risk of developing retinopathy in Diabetes Control and Complications Trial type 1 diabetic patients with good or poor metabolic control. *Diabetes Care* 2001; 24: 1275–1279.

47

Early Treatment of Diabetic Retinopathy Study Research Group. Early photocoagulation for diabetic retinopathy. ETDRS Report No. 9. *Ophthalmology* 1991; 98: 766–785.

48

Diabetic Retinopathy Vitrectomy Study Research Group. Early vitrectomy for severe vitreous haemorrhage in diabetic retinopathy. Two-year results of a randomized trial. DRVS Report No 2. *Arch Ophthalmol* 1985; 103: 1644–1652.

49

Stefansson E, Bek T, Porta M, Larsen N, Kristinsson JK, Agardh E. Screening and prevention of diabetic blindness. *Acta OphthalmolScand* 2000; 78: 374–385.

50

Scanlon PH. The English national screening programme for sight-threatening diabetic retinopathy. *J Med Screen* 2008; 15: 1–4.

51

Chaturvedi N, Sjolie AK, Stephenson JM et al. Effect of lisinopril on progression of retinopathy in normotensive people with type 1 diabetes. The EUCLID Study Group. EURODIAB Controlled Trial of Lisinopril in Insulin-Dependent Diabetes Mellitus. *Lancet* 1998; 35: 28–31.

52

Beulens JW, Patel A, Vingerling JR et al.; on behalf of the AdRem\* project team and ADVANCE management committee. Effects of blood pressure lowering and intensive glucose control on the incidence and progression of retinopathy in patients with type 2 diabetes mellitus: a randomised controlled trial. *Diabetologia* 2009; 52: 2027–2036.

53

Chaturvedi N, Porta M, Klein R et al.; DIRECT Programme Study Group. Effect of candesartan on prevention (DIRECT-Prevent 1) and progression (DIRECT-Protect 1) of retinopathy in type 1 diabetes: randomised, placebo-controlled trials. *Lancet* 2008; 372: 1394–1402.

54

Sjøløie AK, Klein R, Porta M et al.; DIRECT Programme Study Group. Effect of candesartan on progression and regression of retinopathy in type 2 diabetes (DIRECT-Protect 2): a randomised placebo-controlled trial. *Lancet* 2008; 372: 1385–1393.

55

Mauer M, Zinman B, Gardiner R et al. Renal and retinal effects of enalapril and losartan in type 1 diabetes. *N Engl J Med* 2009; 361: 40–51.

56

Keech AC, Mitchell P, Summanen PA et al. Effect of fenofibrate on the need for laser treatment for diabetic retinopathy (FIELD study): a randomised controlled trial. *Lancet* 2007; 370: 1687–1697.

57

The DAMAD Study Group. Effect of aspirin alone and aspirin plus dipyridamole in early diabetic retinopathy. A multicentre randomized controlled clinical trial. *Diabetes* 1989; 38: 491–498.

58

The TIMAD Study Group. Ticlopidine treatment reduces the progression of non-proliferative diabetic retinopathy. *Arch Ophthalmol* 1990; 108: 1577–1583.

59

Early Treatment of Diabetic Retinopathy Study Group. Effects of aspirin treatment of diabetic retinopathy. ETDRS Report No. 8. *Ophthalmology* 1991; 98: 757–765.

60

Funatsu H, Yamashita H, Ikeda T, Mimura T, Eguchi S, Hori S. Vitreous levels of interleukin-6 and vascular endothelial growth factor are related to diabetic macular edema. *Ophthalmology* 2003; 110: 1690–1696.

61

Bhagat N, Grigorian RA, Tutela A, Zarbin MA. Diabetic macular edema: pathogenesis and treatment. *Surv Ophthalmol* 2009; 54: 1–32.

62

Michaelides M, Kaines A, Hamilton RD et al. A prospective randomized trial of intravitreal bevacizumab or laser therapy in the management of diabetic macular edema (BOLT study) 12-month data: report 2. *Ophthalmology* 2010; 117: 1078–1086

63

Massin P, Bandello F, Garweg JG et al. Safety and efficacy of ranibizumab in diabetic macular edema (RESOLVE Study): a 12-month, randomized, controlled, double-masked, multicenter phase II study. *Diabetes Care* 2010; 33: 2399–2405.

64

Cunningham ET Jr, Adamis AP, Altaweel M et al. A phase II randomized double-masked trial of pegaptanib, an anti-vascular endothelial growth factor aptamer, for diabetic macular edema. *Ophthalmology* 2005; 112: 1747–1757.

65

Major JC Jr, Brown DM, DA VINCI Study Group. DA VINCI: DME and VEGF Trap-Eye: investigation of clinical impact: phase 2 study in patients with diabetic macular edema (DME). *Invest Ophthalmol Vis Sci* 2010; 52(Suppl.): 6426.

66

Ahmadieh H, Ramezani A, Shoeibi N et al. Intravitreal bevacizumab with or without triamcinolone for refractory diabetic macular edema; a placebo-controlled, randomized clinical trial. *Graefes Arch Clin Exp Ophthalmol* 2008; 246: 483–489.

67

Diabetic Retinopathy Clinical Research Network (DRCR.net). Three-year follow-up of a randomized trial comparing focal/grid photocoagulation and intravitreal triamcinolone for diabetic macular edema. *Arch Ophthalmol* 2009; 127: 245–251.

68

Diabetic Retinopathy Clinical Research Network (DRCR.net). Expanded 2-year follow-up of ranibizumab plus prompt or deferred laser or triamcinolone plus prompt laser for diabetic macular edema. *Ophthalmology* 2011; 118: 609–614