

AperTO - Archivio Istituzionale Open Access dell'Università di Torino

Diagnostic and prognostic role of steroidogenic factor 1 in adrenocortical carcinoma: a validation study focusing on clinical and pathologic correlates

This is the author's manuscript

Original Citation:

Availability:

This version is available <http://hdl.handle.net/2318/127212> since

Published version:

DOI:10.1016/j.humpath.2012.07.025

Terms of use:

Open Access

Anyone can freely access the full text of works made available as "Open Access". Works made available under a Creative Commons license can be used according to the terms and conditions of said license. Use of all other works requires consent of the right holder (author or publisher) if not exempted from copyright protection by the applicable law.

(Article begins on next page)



UNIVERSITÀ DEGLI STUDI DI TORINO

This is an author version of the contribution published on:

Questa è la versione dell'autore dell'opera:

[Human Pathology, 44 (5), 2013, 10.1016/j.humpath.2012.07.025]

*ovvero [Duregon E, Volante M, Giorcelli J, Terzolo M, Lalli E, Papotti M., 44,
Elsevier, 2013, pagg.822-828]*

The definitive version is available at:

La versione definitiva è disponibile alla URL:

[<http://www.sciencedirect.com/science/article/pii/S0046817712002882>]

**DIAGNOSTIC AND PROGNOSTIC ROLE OF STEROIDOGENIC FACTOR 1 IN ADRENOCORTICAL
CARCINOMA: a validation study focusing on clinical and pathological correlates.**

**Eleonora Duregon, Marco Volante, Jessica Giorcelli, Massimo Terzolo*, Enzo Lalli§,
Mauro Papotti**

Divisions of Pathology and *Internal Medicine 1 of the Department of Clinical and
Biological Sciences, University of Turin at San Luigi Hospital, Orbassano, Torino, Italy.

§Institut de Pharmacologie Moléculaire et Cellulaire CNRS and Université de Nice-
Sophia Antipolis, Valbonne, France.

Running title: SF-1 in adrenocortical carcinoma

Address for correspondence: Marco Volante, MD

Department of Clinical & Biological Sciences, University of Turin at San Luigi Hospital,
Regione Gonzole 10, 10043 Orbassano, Torino, Italy

Phone: +390116705464; Fax: +390116705432; email: marco.volante@unito.it

Source of support: Work supported by grants from the Italian Association for Cancer
Research (AIRC, Milan, grant no. IG/10795/2010 to MP); Institut National du Cancer,
FP7 ENS@T-Cancer under grant agreement 259735 and Association pour la Recherche
sur le Cancer (Projets ARC SFI20111203563) to EL.

Conflict of interest statement: All Authors declare the absence of any potential conflict
of interest.

ABSTRACT

The pathological characterization of adrenocortical cancer (ACC) is still problematic for several reasons, including the identification of novel markers of diagnostic or prognostic relevance. Among them, steroidogenic factor 1 (SF-1) deserves major interest because of its potential usefulness as a marker of adrenocortical derivation and of biological aggressiveness. Our aim was to validate its prognostic relevance in a large series of ACC, comparing the performance of two different commercial antibodies and investigating its expression in ACC variants and in comparison to clinical and pathological features. Seventy-five (including 53 classical, 10 myxoid and 12 oncocytic) ACC cases were included in TMAs and analyzed for the immunohistochemical expression of SF-1 using two commercial antibodies, one polyclonal and one monoclonal (N1665). Nuclear SF-1 staining was assessed using a semi-quantitative score and correlated with ACC type and clinical pathological characteristics. A weak but significant correlation was found comparing the two antibodies with a positive rate of 88% and 58% using the monoclonal and polyclonal antibodies, respectively. High SF-1 expression with the N1665 antibody was positively correlated with high mitotic count, high Ki-67 index and high ENSAT stage, and negatively associated with loss of functionality and presence of oncocytic features. Moreover, high SF-1 expression with this same antibody was significantly associated at univariate analysis with a decreased survival, together with high Ki-67 and mitotic indexes, with a trend to significance confirmed by multivariate analysis, thus supporting the detection of SF-1 using the N1665 antibody as a novel prognostic marker in ACC.

Keywords. adrenal cancer, SF-1, monoclonal antibody, prognosis.

INTRODUCTION

The pathological characterization of adrenocortical carcinoma (ACC) still remains challenging for the pathologist for several reasons. First of all, it is a rare neoplasm (about 1 case per million) for which clear-cut morphological parameters to define malignancy are lacking [1]. Many diagnostic methods have been proposed, either based on scoring systems including the most frequently used Weiss system [2,3] or using alternative algorithmic approaches [4,5]. In addition, rare morphological variants exist, such as myxoid [6] and oncocytic [7,8] ACC, for which the Weiss system is not adequate due to the risk of under or overestimating malignancy, respectively. Moreover, even when malignancy is easily assessable, differential diagnosis of ACC might be uncertain from other primary adrenal (pheochromocytoma, PECOma) or extra-adrenal (renal cell carcinoma, melanoma, poorly differentiated metastatic carcinomas, retroperitoneal sarcomas) neoplasms, and immunophenotyping is not always conclusive. Finally, ACC is a highly aggressive malignancy and a more precise prognostic estimate is required. As a consequence, many complementary tools to the classical morphological diagnosis were proposed, generally based on specific marker immunodetection, and gene, miRNA or gene methylation profiling [9-14]. Among the most promising novel tools, Steroidogenic Factor-1 (SF-1) has been recently proposed as an adrenocortical-specific marker, as well as a relevant prognostic indicator in ACC [15]. In fact, SF-1 - which is expressed by adrenocortical cells during foetal and adult life, mostly in the zona glomerulosa and fasciculata - appeared as a highly sensitive (98.6%) and specific (100%) diagnostic marker of adrenocortical derivation and its high protein expression levels were also correlated with a poor prognosis. The diagnostic role of SF-1 was later confirmed by Sangoi and coworkers [16] on a series of 63 adrenocortical lesions, while the prognostic role

still needs to be validated. Aim of the present study was therefore: a) to compare the performance of two different SF-1 commercial antibodies in a large series of ACC; b) to investigate if ACC variants differ in SF-1 expression in comparison to the classical ACC; c) to compare SF-1 expression with several clinical and pathological features and validate its prognostic role in ACC patients.

MATERIAL AND METHODS

Tissue collection - 197 consecutive adrenocortical tumors having a Weiss score ≥ 3 [2, 3] were collected between 1990 and 2011 from the pathology files of the University of Turin, including 138 consultation cases. Among them, 75 cases had paraffin embedded tissue suitable for tissue microarray (TMA) construction and formed the basis of the current study (**Table 1**). The majority of these patients were treated at our Institution, which serves as a referral center for ACC in Italy. The histo-pathological features of 22 classical, 10 myxoid and 12 oncocytic ACCs of this data set have already been reported [5-7]. For all cases, the clinical, pathological and follow up data were collected. The study received ethical approval from the local Review Board of our Institution.

Tissue MicroArray (TMA) construction - Haematoxylin and eosin (H&E)-stained slides of the 75 ACC were reviewed by one of us (ED) to identify three representative areas of well-preserved morphology and no significant necrotic tissue. The corresponding areas on the paraffin block were marked for tissue punching. TMAs were assembled using a commercially available manual tissue puncher/arrayer (Quick-RAYTM tissue arrayer; Bio-Optica, Milan, Italy) according to the manufacturer's instructions. To minimize the number of inadequate

cases and to increase concordance rates among different cores, three cores with a diameter of 2 mm were punched from each tissue block and arrayed into the recipient paraffin block. TMAs also included two cores of different control tissues (adrenal cortex, adrenal medulla, kidney).

Immunohistochemistry – Serial five μm -thick paraffin sections from the constructed TMA blocks were processed for immunohistochemistry. Two commercially available antibodies against SF-1 were employed, the first polyclonal (diluted 1/500; Upstate, Millipore, Billerica, MA, USA) and the second monoclonal (clone N1665, diluted 1/100; Perseus Proteomics, Tokyo, Japan). The proliferative index was evaluated in parallel with MIB-1 antibody to Ki-67 (diluted 1/150; Dako Cytomation, Glostrup, Denmark). Sections were deparaffinized and rehydrated in ethanol. For antigen retrieval, a pressure cooker treatment for 5 minutes at 125°C, followed by a quick 10-second step at 90°C was performed in ethylenediamine tetraacetic acid (EDTA) buffer (pH 8.0) for all antibodies. Samples were allowed to cool to room temperature before incubation with 3% hydrogen peroxide in Tris-buffered saline (TBS) for 10 min to quench endogenous peroxidase activity. Subsequently, sections were incubated for one hour at 37°C with SF-1 antibodies, or for one hour at room temperature for Ki-67. A biotin-free, dextran chain-based detection system (EnVysion, Dako) was used according to a standard protocol and using diaminobenzidine as the chromogen. Finally, slides were counterstained with hematoxylin, dehydrated, and mounted. TMA cores of normal tissue including adrenal cortex, adrenal medulla and kidney served as appropriate internal positive (the former) and negative (the others) controls.

Staining interpretation and scoring system - All slides were analyzed independently by two

of us (ED, MV), who included in the analysis only samples with two or three evaluable cores after the immunostaining. Staining was assessed for each core using a semiquantitative scoring system based on the evaluation of nuclear staining, as follows: score 0= no staining; score 1= focal (<50% of the core) staining; score 2= diffuse (\geq 50% of the core) staining. An overall score for each case was calculated as the mean of the assessed cores. In case of discrepancies, slides were reviewed at a multihead microscope and a consensus was reached. For descriptive purposes, all cases with an overall score different from 0 were considered positive. Moreover, for subsequent statistical analysis, cases were then categorized as “negative/low” or “high” expression according to the mean score value of the overall population (corresponding to 1.11).

Statistical analysis - Correlation between the two SF-1 antibodies was made using a two-tailed Spearman’s test. Clinical and pathological characteristics were compared to staining patterns of the two SF-1 antibodies by Fisher’s exact or Chi-square and Student’s t tests, for categorical and continuous variables, respectively. To analyze the prognostic impact of all clinical and pathological variables considered, univariate overall survival analysis was based on the Kaplan–Meier product limit estimate of survival distribution. Clinical pathological parameters considered in overall survival analysis included: sex, age, hormonal secretion, weight, size, Weiss score, Ki67 index, mitotic index, ENSAT stage and the reactivity to SF-1 antibodies. Unadjusted differences between survival curves were tested using the log rank test. All parameters with a significant impact on survival at univariate analysis were considered for multivariate analysis using the Cox proportional hazard model. Statistical significance was set at $p < 0.05$. All tests were performed using GraphPad Prism version 5.0 and STATISTICA version 7.0 softwares.

RESULTS

Clinical and pathological data and SF-1 protein expression – Clinical and pathological data of the ACC series analyzed are summarized in **Table 1**. All tumors had a Weiss score ≥ 3 and were defined as malignant also using the “reticulin algorithm” [5]. All tumors had reticulin framework disruption in the presence of at least one of either high mitotic count or necrosis or vascular invasion.

SF-1 protein expression (including all cases with a mean case score different from 0) was detected in 64 of 73 evaluable ACC cases (88%) by the monoclonal antibody and in 42 of 72 (58%) by the polyclonal antibody. Both antibodies tested positive at the nuclear level in normal adrenocortical tissue (**Figure 1**) and negative in control tissues from adrenal medulla and kidney. A general more intense immunoreactivity, both in normal and neoplastic adrenocortical tissues, was observed using the SF-1 monoclonal antibody. An additional weak and occasional cytoplasmic immunoreactivity was observed when the SF-1 polyclonal antibody was used, only. A significant, although weak, positive correlation was found comparing the scoring results obtained with the two antibodies (Spearman r : 0.4786, 95% confidence interval: 0.2696 -0.6446; p -value < 0.0001).

Correlation of SF-1 expression with clinical and pathological variables (Table 2) – High SF-1 nuclear expression, as detected by using the polyclonal antibody, was associated to female sex and high mitotic rate. By contrast, high SF-1 nuclear expression, as detected by using the monoclonal antibody, was positively correlated with high mitotic count, high Ki-67 index and

advanced ENSAT stage. Interestingly, SF-1 protein using the monoclonal antibody was also differentially expressed in ACC variants, being negative or low in the majority of cases of the oncocytic type, and a higher rate of reactivity was observed in functioning tumors, too, although not significantly associated with the type of hormone secreted.

Correlation of SF-1 expression with disease outcome (Table 3) - Univariate analysis showed that high Ki-67 proliferation and high mitotic indexes were associated to shorter overall survival. Moreover, high SF-1 expression, as detected by means of the monoclonal antibody was associated with an increased risk of disease-related death (HR: 3.924, $p=0.0036$) and decreased survival (median survival of 27 vs 82 months in cases with high and negative/low expression, respectively) (**Figure 2**). A trend to significance was maintained at multivariate analysis ($p=0.117$) that showed mitotic index as the most powerful prognostic indicator in our series ($p=0.028$). By contrast, SF-1 expression as detected by the polyclonal antibody did not show any prognostic relevance in the current ACC series.

DISCUSSION

In the present report, we investigated the expression of SF-1 in a large series of ACC. The aim of our study was to validate the utility of SF-1 as a prognostic marker, testing the immunohistochemical performance of two different commercially available antibodies and comparing its expression with several clinical and pathological parameters. The first antibody we employed is a monoclonal reagent which has been previously demonstrated to be highly specific and sensitive for the recognition of adrenocortical tissues as well as

prognostic in ACC patients [15,16]. The second antibody is a polyclonal antibody never tested in ACC samples, so far, to the best of our knowledge.

Among several immunohistochemical and molecular markers recently proposed in ACC, SF-1 deserves a major interest for the dual potential implications in the diagnostic and prognostic characterization of ACC. In fact, as already mentioned above, SF-1 expression is a strong tool to determine the adrenocortical derivation of a given tumoral lesion, irrespective of its benign or malignant nature, being expressed by few other steroidogenic tissues only (such as ovarian stroma or steroid hormone producing testicular cells). Although we did not design this study to validate this specific diagnostic utility, we could confirm that SF-1 is expressed in a relevant percentage of ACC, thus being a highly sensitive tool to take ACC apart from other mimickers in the adrenal gland. However, the expression rates were different when considering the two different antibodies; in fact, it raised from 58% positive cases only with the polyclonal serum to 88% with the monoclonal antibody. This latter figure is slightly lower than that originally reported by Sbiera (98%) [15], but comparable to what reported recently on TMA material (86%) [16], using the same monoclonal antibody herein employed.

Indeed, we mainly focused our analysis of SF-1 expression in a cohort of ACC with the specific aim to validate its prognostic value and investigate different SF-1 expression profiles as compared to clinical and pathological features. In the original paper by Sbiera and coworkers [15] the sub-analysis of SF-1 distribution was limited to sex, age, tumor stage and hormone secretion, apparently with no specific correlation. In our series, the two different antibodies gave heterogeneous results as a possible consequence of their poor reciprocal correlation. In fact, while the polyclonal SF-1 antibody was associated to sex and mitotic index only, the monoclonal antibody showed a wider association with “high grade” clinical and pathological parameters that is to say characteristics predictive of worse prognosis. High

SF-1 expression, as detected with the monoclonal antibody, was positively correlated with advanced ENSAT stage, high proliferation and mitotic index, and high Weiss score values. These data are consistent with previous studies showing that SF-1 over-expression triggers proliferation of ACC cells and induces adrenocortical tumor formation in mice [17] and with *in vitro* observations that specific SF-1 antagonists are capable to decrease proliferation in ACC cell models [18]. Moreover, we originally found that SF-1 was differentially expressed in ACC histological types, since it was slightly more expressed in myxoid ACC (6/10 cases) compared to the conventional ones (14/51 cases), and it was very infrequently reactive in the oncocytic variant of ACC (1/12 cases). This observation might possibly reflect the generally lower growth potential in this latter group as compared to classical ACC [7], but alternative mechanisms linked to the specific metabolic/functional properties of oncocytic cell and tumors might be also active. Interestingly, we also observed a striking difference in the prevalence of SF-1 over-expression according to the functional status of the tumors analyzed: SF-1 was detected at a high expression level in nearly 40% of functioning but in 9% only of non-functioning tumors. Although this is apparently in contrast with the previous observation by Sbiera [15], it is quite reasonable to assume that the expression levels of SF-1, whose properties are related to steroidogenesis [19], might be proportional to hormonal production and secretion by tumor cells. It is worth to notice that the prevalence of functional tumors in the oncocytic and myxoid cases was opposite, since 3/7 and 5/6 were hormone secreting in the oncocytic and myxoid group of tumors, respectively. Therefore, it should be considered that this finding might be, at least partially, responsible of the correlation between SF-1 expression and histologic variant. In practical terms, the present data show that SF-1 expression may be a useful diagnostic tool, proven that the results are

integrated in an appropriate morphological and clinical context, since its sensitivity might be lower in specific ACC variants and in non-functioning tumors.

Finally, we validated the impact of SF-1 expression levels on prognosis of the current ACC series. At univariate analysis, high expression levels of SF-1, as detected by the N1665 monoclonal antibody, were closely correlated with survival, together with mitotic and proliferation indexes. At multivariate analysis, mitotic count was the only significant independent parameter in our series, but a trend to significance was maintained for SF-1, too. Although methodological differences (SF-1 scoring system and cut off value selection, size of the case series, patients' characteristics) are possibly responsible for the slightly lower statistical power of SF-1 as compared to that reported by Sbiera [15], our data are supportive of the potential role of SF-1 as a prognostic marker in ACC. For this reason, its inclusion in a minimal set of markers for the characterization of ACC samples is advisable.

In conclusion, SF-1 is detectable in a high percentage of ACC and its high expression levels correlate with high-grade features, histological type, functional status and adverse outcome. The N1665 monoclonal antibody proved superior to commercial polyclonal antisera and its use is therefore currently advisable in the clinical practice for both diagnostic and prognostic purposes.

REFERENCES

- 1) Papotti M, Libè R, Duregon E, Volante M, Bertherat J, Tissier F. The Weiss score and beyond--histopathology for adrenocortical carcinoma. *Horm Cancer* 2011; 2:333-40
- 2) Weiss LM. Comparative histologic study of 43 metastasizing and nonmetastasizing adrenocortical tumors. *Am J Surg Pathol* 1984; 8:163-9
- 3) Weiss LM, Medeiros LJ, Vickery AL Jr. Pathologic features of prognostic significance in adrenocortical carcinoma. *Am J Surg Pathol* 1989; 13:202-6
- 4) Blanes A, Diaz-Cano SJ. Histologic criteria for adrenocortical proliferative lesions: value of mitotic figure variability. *Am J Clin Pathol* 2007; 127:398-408
- 5) Volante M, Bollito E, Sperone P, et al. Clinicopathological study of a series of 92 adrenocortical carcinomas: from a proposal of simplified diagnostic algorithm to prognostic stratification. *Histopathology* 2009; 55:535-43
- 6) Papotti M, Volante M, Duregon E, et al. Adrenocortical tumors with myxoid features: a distinct morphologic and phenotypical variant exhibiting malignant behavior. *Am J Surg Pathol* 2010; 34:973-83
- 7) Duregon E, Volante M, Cappia S, et al. Oncocytic adrenocortical tumors: diagnostic algorithm and mitochondrial DNA profile in 27 cases. *Am J Surg Pathol* 2011; 35:1882-93
- 8) Wong DD, Spagnolo DV, Bisceglia M, Havlat M, McCallum D, Platten MA. Oncocytic adrenocortical neoplasms--a clinicopathologic study of 13 new cases emphasizing the importance of their recognition. *Hum Pathol* 2011; 42:489-99
- 9) de Reyniès A, Assié G, Rickman DS, et al. Gene expression profiling reveals a new classification of adrenocortical tumors and identifies molecular predictors of malignancy and survival. *J Clin Oncol* 2009; 27:1108-15

- 10) Ragazzon B, Libé R, Gaujoux S, et al. Transcriptome analysis reveals that p53 and {beta}-catenin alterations occur in a group of aggressive adrenocortical cancers. *Cancer Res* 2010; 70:8276-81
- 11) Ragazzon B, Assié G, Bertherat J. Transcriptome analysis of adrenocortical cancers: from molecular classification to the identification of new treatments. *Endocr Relat Cancer* 2011; 18:R15-27
- 12) Patterson EE, Holloway AK, Weng J, Fojo T, Kebebew E. MicroRNA profiling of adrenocortical tumors reveals miR-483 as a marker of malignancy. *Cancer* 2011; 117:1630-9
- 13) Özata DM, Caramuta S, Velázquez-Fernández D, et al. The role of microRNA deregulation in the pathogenesis of adrenocortical carcinoma. *Endocr Relat Cancer* 2011; 18:643-55
- 14) Rechache NS, Wang Y, Stevenson HS, et al. DNA Methylation Profiling Identifies Global Methylation Differences and Markers of Adrenocortical Tumors. *J Clin Endocrinol Metab* 2012 Apr 3. [Epub ahead of print]
- 15) Sbiera S, Schull S, Assie G, et al. High diagnostic and prognostic value of steroidogenic factor-1 expression in adrenal tumors. *J Clin Endocrinol Metab* 2010; 95:E161-71
- 16) Sangoi AR, Fujiwara M, West RB, et al. Immunohistochemical distinction of primary adrenal cortical lesions from metastatic clear cell renal cell carcinoma: a study of 248 cases. *Am J Surg Pathol* 2011; 35:678-86
- 17) Doghman M, Karpova T, Rodrigues GA, et al. Increased Steroidogenic Factor-1 dosage triggers adrenocortical cell proliferation and cancer. *Mol Endocrinol* 2007; 21:2968-87
- 18) Doghman M, Cazareth J, Douguet D, Madoux F, Hodder P, Lalli E. Inhibition of adrenocortical carcinoma cell proliferation by steroidogenic factor-1 inverse agonists. *J Clin Endocrinol Metab* 2009; 94:2178-83

19) Lalli E. Adrenocortical development and cancer: focus on SF-1. *J Mol Endocrinol* 2010;
44:301-7

Table 1. Clinical and pathological features of 75 ACC cases included in the Tissue MicroArrays.

Parameter	
M/F ratio	32/43
Age, mean (years)	46 [20-79]
Functional status (<i>Not known: 15</i>)	Not functioning: 23 Functioning: 37*
Size, mean (cm)	11.5 [2-30]
Weight, mean (grams)	481 [8-3200]
Histologic type	Conventional: 53 Myxoid: 10 Oncocytic: 12
Weiss score distribution	3-4: 15 5-6: 24 7-8-9: 36
ENSAT stage (<i>Not known: 20</i>)	1-2: 20 3-4: 35
Follow up (<i>lost to FU: 6</i>)	NED/DOC: 21 AWD: 15 DOD: 33
Median overall survival (months)	53

Abbreviations: ACC, adrenocortical carcinoma; M, male; F, female; *: functionality included the presence of predominant cortisol (28 cases, including 1 oncocytic and 5 mixoid tumors), aldosterone (6 cases, including 1 oncocytic tumor) and androgens (3 cases, including 1

oncocytic tumor) secretion; FU, follow up; NED, no evidence of disease; DOC, died of other cause; AWD, alive with disease; DOD, died of disease.

Table 2. SF-1 immunohistochemistry: clinical and pathological correlates in ACC

Parameter		SF1 polyclonal [^]			SF1 monoclonal [^]		
		negative/low	high	p	negative/low	high	p
Sex	M	24	8	0.016	25	6	0.19
	F	18	22		27	15	
Age	≤45	21	17	0.64	29	10	0.61
	>45	21	13		23	11	
Histologic type	conventional	31	19	0.44	37	14	0.026
	myxoid	4	6		4	6	
	oncocytic	7	5		11	1	
Functional status	functioning	21	14	0.40	22	14	0.015
	not functioning	16	6		21	2	
Type of hormone	cortisol	16	10	1.00	16	11	1.00
	aldosteron/androgens	5	4		6	3	
Size*	<11	15	11	0.77	21	9	0.59
	≥11	15	8		17	10	
Weight*	≤260	19	11	0.59	16	10	0.38
	>260	24	11		17	6	
Mitotic index	<11	29	11	0.017	33	7	0.036
	≥11	14	18		19	14	
x50HPF*							
Ki-67 index*	<20	18	10	0.43	26	2	0.0002
	≥20	16	15		15	17	
Weiss score	3-4	8	6	0.99	14	0	0.024

	5-6	14	10		16	7	
	7-8-9	20	14		22	14	
ENSAT stage	1-2	12	7	0.77	18	2	0.029
	3-4	18	14		20	14	
Disease status	NED/DOC	15	6	0.24	17	3	0.21
	AWD	6	8		10	5	
	DOD	19	12		20	12	

Abbreviations: SF-1 polyclonal: Upstate, Millipore; SF-1 monoclonal: clone N1665, Perseus;

M, male; F, female; NED, not evidence of disease; HPF, high power field; DOC, died of other

cause; AWD, alive with disease; DOD, died of disease. *: median value. ^: SF-1 polyclonal: 72

cases evaluable; SF-1 monoclonal: 73 cases evaluable

Table 3. Univariate overall survival analysis.

Parameter	HR	95% CI	p
Female sex	1.064	0.5317-2.129	0.8608
Age \leq 45	0.9039	0.4529-1.804	0.7744
Presence of hormonal activity	1.406	0.6741-2.933	0.3635
Weight >260	0.8803	0.3990-1.942	0.7992
Size >11 cm	1.257	0.5852-2.699	0.5577
Weiss score \geq 7	1.333	0.6639-2.676	0.4189
Ki-67 \geq 20%*	2.366	1.095-5.112	0.0285
Mitotic index x 50HPF \geq 11*	3.482	1.608-7.538	0.0015
ENSAT Stage 3-4	1.611	0.7724-3.360	0.2036
High SF-1 levels (polyclonal)	1.162	0.5522-2.443	0.6931
High SF-1 levels (monoclonal)*	3.924	1.561-9.860	0.0036

Abbreviations: SF-1 polyclonal: Upstate, Millipore; SF-1 monoclonal: clone N1665, Perseus;

*: parameters included in **multivariate analysis**: mitotic index: p=0.028; Ki-67: p=0.342; SF-1 monoclonal: p=0.117

FIGURES

Figure 1. SF-1 expression in normal adrenal cortex and ACC samples using a polyclonal and a monoclonal antibody (immunoperoxidase; original magnification 200x for all images)

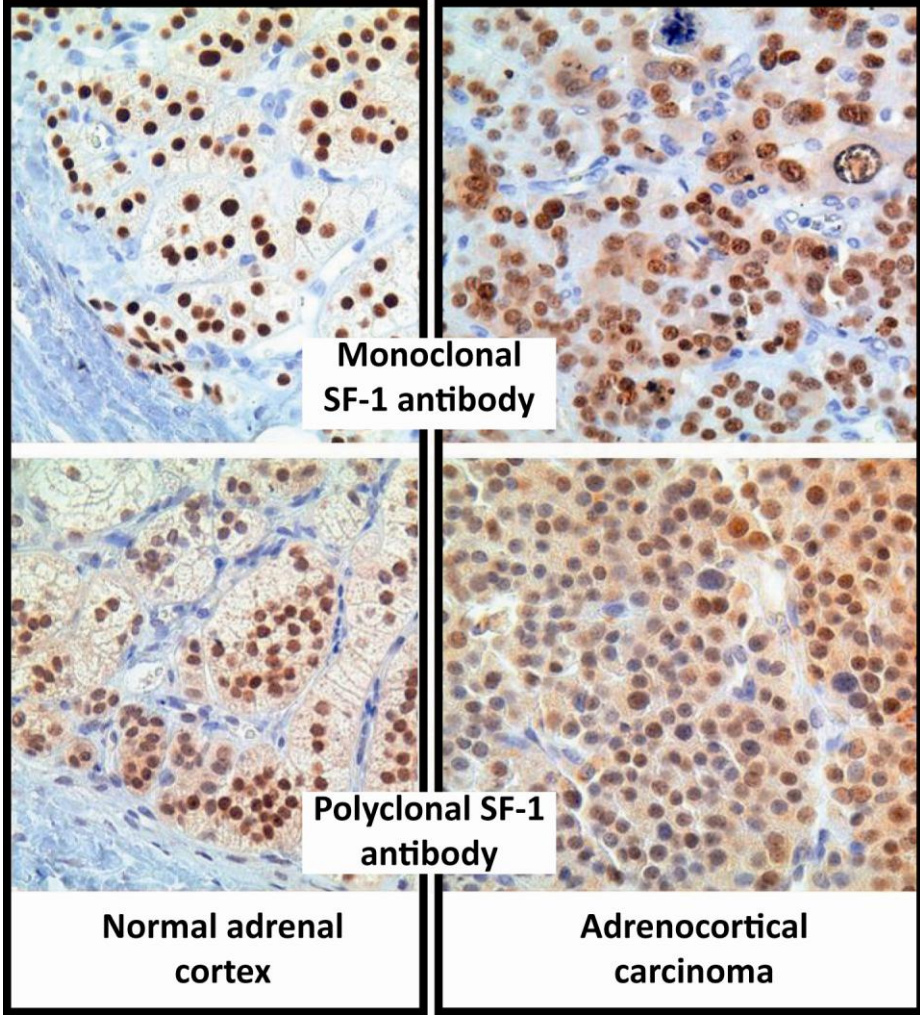


Figure 2. Kaplan Meier curves representing overall survival distribution in ACC patients with negative/low vs high SF-1 protein expression levels.

