

AperTO - Archivio Istituzionale Open Access dell'Università di Torino

Primary repair of crush nerve injuries by means of biological tubulization with muscle-vein-combined grafts.

This is the author's manuscript

Original Citation:

Availability:

This version is available <http://hdl.handle.net/2318/117764> since

Published version:

DOI:10.1002/micr.21957

Terms of use:

Open Access

Anyone can freely access the full text of works made available as "Open Access". Works made available under a Creative Commons license can be used according to the terms and conditions of said license. Use of all other works requires consent of the right holder (author or publisher) if not exempted from copyright protection by the applicable law.

(Article begins on next page)



UNIVERSITÀ DEGLI STUDI DI TORINO

This is the accepted version of the following article: "Primary repair of crush nerve injuries by means of biological tubulization with muscle-vein-combined grafts."

Tos P, Battiston B, Ciclamini D, Geuna S, Artiaco S. *Microsurgery*. 2012 Jul;32(5):358-63. doi: 10.1002/micr.21957. Epub 2012 Mar 16.

which has been published in final form at

<http://onlinelibrary.wiley.com/doi/10.1002/micr.21957/abstract;jsessionid=FFE8584242589948B6CFC9489D440DC9.f02t04>

PRIMARY REPAIR OF CRUSH NERVE INJURIES BY MEANS OF BIOLOGICAL TUBULIZATION WITH MUSCLE-VEIN-COMBINED GRAFTS

PIERLUIGI TOS, M.D.,¹ BRUNO BATTISTON, M.D.,¹ DAVIDE CICLAMINI, M.D.,¹

STEFANO GEUNA, M.D.,^{2*} and STEFANO ARTIACO, M.D.¹

¹ UOD Reconstructive Microsurgery, Department of Orthopaedics and Traumatology, CTO-M. Adelaide Hospital, Turin, TO, Italy

² Department of Clinical and Biological Sciences and Neuroscience Institute of the Cavalieri Ottolenghi Foundation, University of Turin, Turin, TO, Italy

Despite extensive research and surgical innovation, the treatment of peripheral nerve injuries remains a complex issue, particularly in nonsharp lesions. The aim of this study was to assess the clinical outcome in a group of 16 patients who underwent, in emergency, a primary repair for crush injury of sensory and mixed nerves of the upper limb with biological tubulization, namely, the muscle-vein-combined graft. The segments involved were sensory digital nerves in eight cases and mixed nerves in another eight cases (four median nerves and four ulnar nerves). The length of nerve defect ranged from 0.5 to 4 cm (mean 1.9 cm). Fifteen of 16 patients showed some degree of functional recovery. Six patients showed diminished light touch (3.61), six had protective sensation (4.31), and three showed loss of protective sensation (4.56) using Semmes-Weinstein monofilament test. All the patients who underwent digital nerve repair had favorable results graded as S4 in one case, S3p in six cases, and S3 in one case. With respect to mixed nerve repair, we observed two S4, two S3p, two S3, one S2, and one S0 sensory recovery. Less favorable results were observed for motor function with three M4, one M3, two M2, and two M0 recoveries. Altogether, the results of this retrospective study demonstrates that tubulization nerve repair in emergency, in case of short nerve gaps, may restore the continuity of the nerve avoiding secondary nerve grafting. This technique preserves donor nerve and, in case of failure, does not preclude a delayed repair with a nerve graft.

Despite continuous researches and surgical innovations, the treatment of peripheral nerve injuries remains a complex problem.^{1,2} Direct nerve repair is often impossible in case of loss of substance, thus requiring a different solution to manage the gap. Nowadays, nerve autograft is still considered the "gold standard" for such lesions because it restores the continuity of nerve trunk without tension and offers an ideal support to regenerating axons.²⁻⁷ A nerve autograft is rich of Schwann cells which have a major role in nerve repair due to basal membrane proteins (fibronectin and laminin) that promote and address axonal regeneration.⁸⁻¹¹ However, clinical outcome is often unsatisfactory and thus alternative types of nerve guides are sought.^{1,5,12}

The timing of intervention and the type of injury are major issues in nerve repair. As general rule, an open nerve injury should be early treated and repaired directly when optimal conditions, such as a) a clean uncontaminated wound and b) a sharp cut injury, are present.¹² Primary nerve repair with nerve graft in crush injuries could be a risk because the extent of resection might be difficult to judge in case of nerve laceration and contusion; in addition, sometimes it is better to avoid primary repair because of the conditions of the surrounding tissues.¹³ In these circumstances, it may be advisable to identify and suture the nerve ends to avoid retraction, and then looking forward to a secondary reconstruction when definitive graft repair can be performed.

Starting from 19th century, alternatives to autograft nerve repair with biological or artificial conduits has been addressed by a number of studies.^{4,14} Blood vessels were used as biological conduits for nerve repair starting from the first decade of the 20th century by Foramitti¹⁵ and Wrede¹⁶ who described the use of blood vessels as vehicles for nerve regeneration and reported successful clinical results in the reconstruction of nerve injuries with loss of substance. In 1993, Brunelli et al.¹⁷ described a new biological conduit based on the usage of a vein segment filled with fresh skeletal muscle (muscle-vein-combined graft). This technique was then successfully translated to the clinics to treat selected cases of peripheral nerve defect.^{4,18,19}

However, in previously published case series, most of the patients were treated several months after injury. The aim of this study was to assess the results of nerve reconstruction in a group of patients who underwent, in emergency, a primary repair for crush injuries of sensory and mixed nerves of the upper limb with the muscle-vein-combined graft.

PATIENTS AND METHODS

From 1995 to 2008, 16 patients with crush nerve injuries located at the upper limb underwent in emergency a repair with biological conduits. Nerve defects were treated by means of muscle-vein-combined grafts using

subcutaneous veins and muscle fibers harvested from muscles of the forearm of the limb involved by nerve lesion.

Surgical Technique

The injured nerve was explored and the length of the defect was evaluated. The nerve ends were cut next to the gap or to the damaged segment where the nerve had a normal morphological appearance under magnification. A vein of adequate diameter (similar to that of the damaged nerve) was selected and harvested. The vein was turned upside-down but not inside-out reversed before grafting. However, the vein wall and valves (if present) were dilated and weakened by means of a vessel dilator. When the width of the vein was not sufficient, a longer segment was harvested and progressively widened with nontraumatic Kelly forceps. A strip of muscle was harvested nearby the site of nerve lesion respecting the longitudinal course of fibers and washed in saline solution to avoid the persistence of blood. Through a forceps, the muscle fibers were driven inside the vein. The muscle-vein-combined graft was then sutured to the nerve ends with epineural stitches leaving 2–3 mm of each stump inside the conduit (Fig. 1). All the operations were performed with magnification devices (microscope or loupes) within 24 hours from the time of trauma.

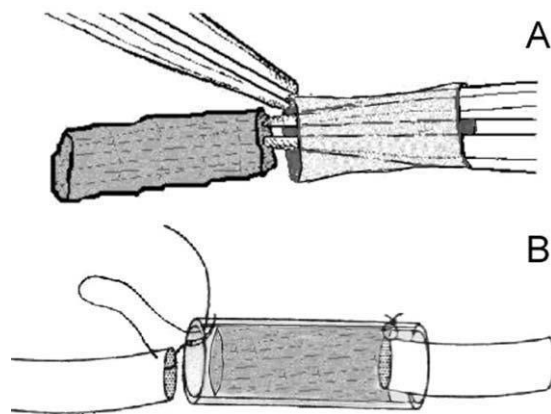


Figure 1. Muscle-vein-combined graft preparation. (A) Positioning of muscle fibers; (B) nerve suturing.

Case Series and Postoperative Follow-Up

All the patients were previously advised that second-ary nerve reconstruction with an autograft could have been required in case of unsuccessful functional recovery. The patients underwent monthly controls to verify the evolution of nerve recovery. The appearance and the pro-gression of Tinel's sign along the course of the injured nerve were examined to detect and follow up axonal regeneration to take into secondary reconstruction in case progression of Tinel's sign did stop.

The clinical series included 12 men and four women with a mean age of 37 years (range 17–60). The segments involved were sensory digital nerves in eight cases and mixed nerves in eight cases (four median nerves and four ulnar nerves). The nerve defect ranged from 0.5 to 4 cm (mean sensory nerve defect: 1.2 cm and mean mixed nerve defect: 2.5 cm). The overall mean value was 1.9 cm. The details about patients and nerve lesions are reported in Table 1.

The cause of trauma was a motor vehicle accident in six cases and domestic or industrial accident in 10 cases. All the patients were treated in emergency (Figs. 2A– 2D). Fourteen patients had isolated nerve injuries and two presented with associated vascular lesions. Sensory functional outcome was assessed by Semmes-Weinstein monofilament test and by static two-point discrimination test according to the criteria of the British Medical Research Council modified by Mackinnon–Dellon.²⁰ The criteria of the British Medical Research Council were also used to assess motor function recovery for mixed nerves. The degree of sensory and motor recovery was finally scored according to Sakellarides.²¹

Statistical analysis was carried out by Mann–Whitney U test using the software “Statistica per discipline biomediche” (McGraw-Hill, Milano, Italia) and comparing motor and functional outcome (scored according to criteria of the British Medical Research Council) in digital, median, and ulnar nerves, respectively. Statistical significance was established as $P < 0.05$.

RESULTS

All the patients were available for the follow-up. The follow-up ranged from 24 to 60 months and mean follow-up was 53 months (Table 1). The minimum period of follow-up considered for inclusion in this case series was 24 months. Assessment of the progression of Tinel's sign along the course of the injured nerve showed that axonal regeneration occurred in 15 of 16 patients. According to the Semmes-Weinstein monofilament test, six patients showed diminished light touch (3.61), six had protective sensation (4.31), and three showed loss of protective sensation (4.56). All the patients who underwent digital nerve repair had favorable results graded as S4 in one case, S3p in six cases, and S3 in one case, according to the classification of Mackinnon–Dellon. The mean value of the static two-point discrimination test was 11 mm (range 6–14 mm).

Regarding sensory recovery for mixed nerve injuries, six of eight patients had good or very good results (two S4, two S3p, and two S3) while two patients had poor/ no results (one S2 and one S0). Regarding motor recovery, all four patients had good or very good results (three M4 and one M3) after median nerve reconstruction (Figs. 3A–3D). On the contrary, two fair results and two failures (two M2 and two M0) were observed after ulnar nerve repair. Two patients who recovered protective sensation with absent or fair motor recovery received a secondary operative procedure with palliative tendon transfers to treat ulnar palsy. The two remaining patients with fair or poor motor recovery refused further operative treatment.

Table 1. Case Series

Case	Age	Nerve	Levels	Gap (cm)	Follow-up (months)	Sensory	S.W. Test	Motor	Results
1	45	Digital	P1	0.5	60	S4	3.61		VG
2	33	Digital	P1	1.0	60	S3p	3.61		VG
3	27	Digital	P1	0.8	60	S3p	4.31		VG
4	17	Digital	P1	1.5	24	S3p	4.31		VG
5	20	Digital	MF	2.0	48	S3p	4.31		VG
6	35	Digital	P1-P2	1.5	60	S3	4.31		G
7	20	Digital	P1	1.0	60	S3p	3.61		VG
8	41	Digital	P2	1.5	36	S3p	3.61		VG
9	28	Median	Wrist	2.5	60	S4	3.61	M4	VG
10	30	Median	Wrist	2.5	48	S4	3.61	M4	VG
11	32	Median	Wrist	4.0	60	S3p	4.31	M3	G
12	67	Median	Distal forearm	3.0	60	S3p	4.31	M4	VG
13	40	Ulnar	Distal forearm	2.0	48	S3	4.56	M2	F
14	50	Ulnar	Proximal forearm	2.0	60	S3	4.56	M2	F
15	53	Ulnar	Middle forearm	3.5	36	S0	–	M0	P
16	47	Ulnar	Middle forearm	1.5	60	S2	4.56	M0	P

Characteristics of nerve lesions and clinical results: VG, very good; G, good; F, fair; P, poor; S.W. Semmes-Weinstein monofilament test.

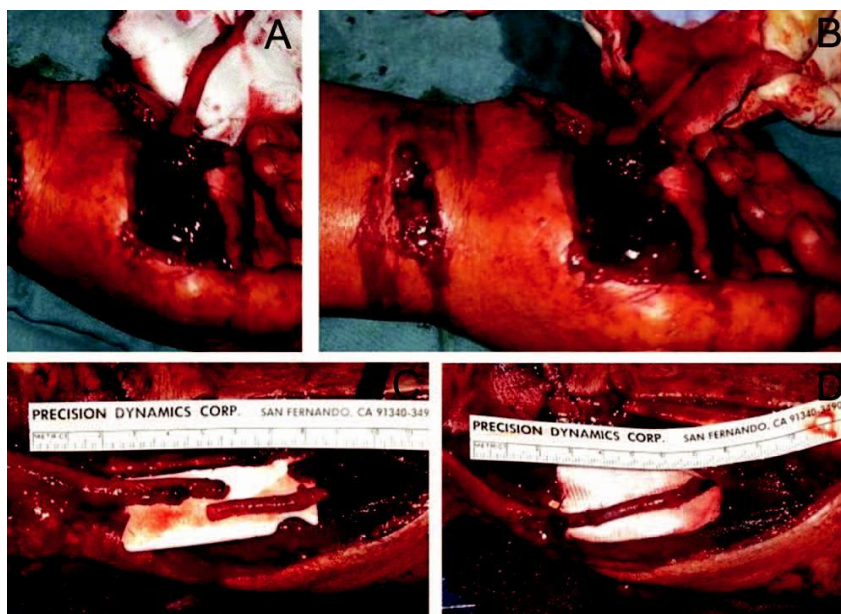


Figure 2. A and B: Crush injury of the right hand. Clinical aspect with median nerve tear. C and D: Primary nerve repair with muscle-vein-combined graft (nerve gap: 3 cm).

Statistical analysis comparing the degree of sensory outcome after digital, median, and ulnar nerve repair, respectively, revealed a significantly lower functional recovery after ulnar nerve reconstruction in comparison to the other two groups ($P < 0.05$) which, by contrast did not differ significantly between them ($P > 0.05$). Also regarding motor outcome, functional recovery after ulnar nerve repair was significantly lower than after median nerve repair ($P < 0.05$).

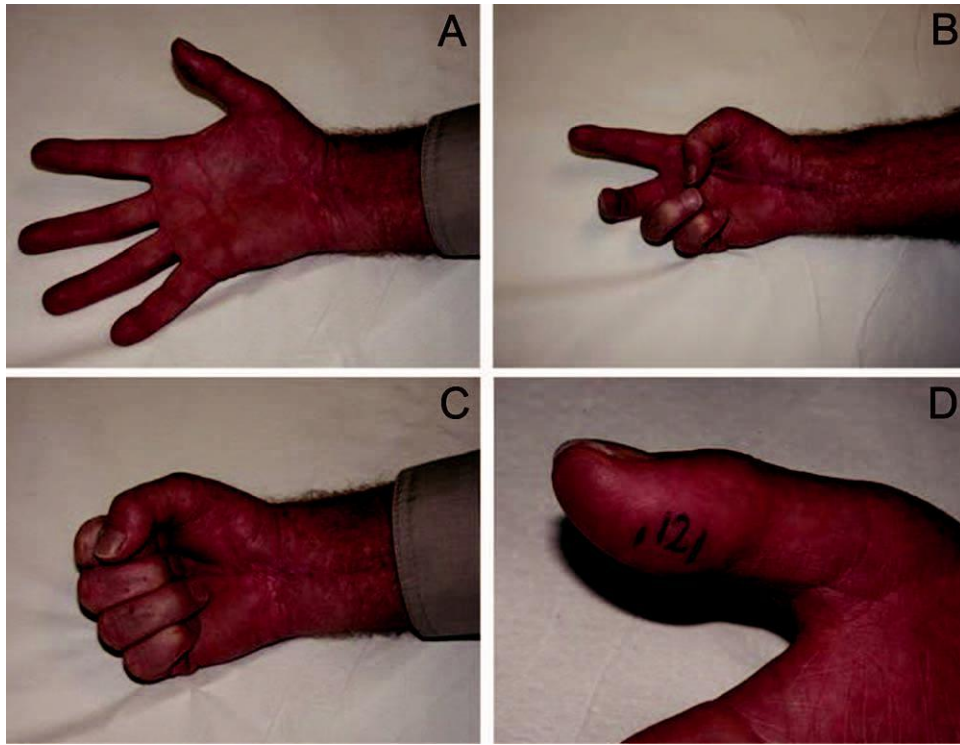


Figure 3. A–D: Clinical result in the same patients of Figure 2. Motor recovery M4 of undamaged thenar muscles. Sensory recovery S3p.

DISCUSSION

During the last decade, biological and synthetic tubulization have been widely examined and used to repair nerve injuries in case of loss of substance.^{1,4} Experimental research on rat demonstrated that filling the veins with fresh muscle fibers allow to obtain nerve regeneration that similar to that observed with nerve autografting.^{22,23}

Muscle fibers avoid conduit's collapse and promote axonal regeneration and Schwann cell migration by means of basal lamina scaffolds.^{24,25} However, a further element that may explain the positive effects of grafted skeletal muscle fibers on the regenerating nerve fibers arises from the recent demonstration that muscle fibers and Schwann cells share a common autotrophic loop based on the neu-regulin/ErbB receptor signaling pathway.^{26,27}

Previous clinical experiences showed that successful results could be obtained in short-gap nerve repair with muscle-vein-combined conduits.^{4,18} These results were recently confirmed by Marcoccio and Vigasio,¹⁹ who demonstrated the effectiveness of this technique in secondary digital nerve reconstruction, highlighting the possibility of using the wound and surrounding tissues as donor sites for nerve repair in emergency surgery.

The novelty of this article is that while in all previously published case series, most of the patients were treated after an interval of several months from injury, the present results are based on a homogeneous case series (with respect to timing of the surgery) of patients treated in emergency only. Therefore, it provides information about the outcome of primary nerve repair muscle-vein-combined conduits that was not obtainable in the previous articles. Our case series showed that that primary nerve repair by biological tubulization with veins filled with fresh muscle allowed to recover sensory and motor function in most patients with crush nerve injuries. Both sensory and motor function recovery was significantly lower for ulnar nerve repair in comparison to digital and median nerve repair, an occurrence which is typical also of other nerve reconstruction techniques²⁸ and that, in this case series, could also be influenced by the higher level of ulnar nerve lesions in comparison to median nerve lesions (Table 1).

The sought for alternatives to traditional nerve auto-grafts, which still remains the gold standard for bridging nerve gaps, is justified by the still unsatisfactory outcome which often follows autologous nerve grafting.^{1,5,13} Among the various biological and synthetic surgical techniques for nerve reconstruction, muscle-vein-combined conduits offer some important advantages: i) surgery was almost always performed in regional anesthesia allowing to harvest muscle tissue and veins, necessary for conduit preparation, from the same surgical field of nerve repair or just nearby to it; ii) however, donor sensory nerves, otherwise required to harvest a autograft for nerve repair, were preserved avoiding donor site morbidity²⁹; iii) the conduits were prepared according to reconstructive needs related to nerve size and defect length; iv) the costs for buying an artificial conduit were avoided. The latter point, however, deserves particular mention as, whereas autologous biological tissues clearly are apparently cost-free in comparison to artificial conduits on the market, their preparation requires additional operational room time. It has been recently estimated that the average cost of material and surgery in biological and synthetic tubulization for nerve repair does not differ significantly.³⁰

Over the last years, evidence is accumulating that tubulization nerve repair can be a good alternative to traditional autografts in selected cases.^{28,31,32} The clinical results presented in this article are in line with this growing evidence.

The main limitations of our study are the absence of a control group and the small number of patients involved in the research. In addition, the technique was applied both in sensory and mixed nerve repair, and the case series is heterogeneous regarding zone of injury and amount of crush, presence of associated vascular injuries, length of the gap, age of the patients, and follow-up interval. However, heterogeneity is common to nerve reconstruction case series, and in comparison to previous reports using the same technique,^{4,18} this study has at least eliminated heterogeneity due to variable interval between injury and repair focusing on primary reconstruction only.

In our experience, no patient underwent secondary nerve reconstruction, and therefore, the procedure proved to be definitive in all the cases. Anyway, in theory, the possibility for secondary nerve reconstruction was not precluded, and in case of failure, secondary nerve graft repair is expected to be easier to be carried out as the anatomical continuity was restored. Therefore, an indication for muscle-vein-combined nerve reconstruction is represented by clinical situation when doubts exist about primary autograft reconstruction due to various reasons, such as bad conditions of nerve stumps and surrounding tissues, lack of informed consent for harvesting a healthy nerve, and local plexus anesthesia.

CONCLUSIONS

Our retrospective study demonstrated that functional recovery can be achieved in primary repair of crush injured nerves with a muscle-vein-combined graft when a short gap is present. This technique, in case of failure, does not preclude a delayed repair with a nerve autograft.

Thus, it can be considered a reasonable surgical option in emergency treatment of crush nerve injuries.

REFERENCES

1. Siemionow M, Bozkurt M, Zor F. Regeneration and repair of peripheral nerves with different biomaterials: Review. *Microsurgery* 2010;30:574–588.
2. Yegiyants S, Dayicioglu D, Kardashian G, Panthaki ZJ. Traumatic peripheral nerve injury: A wartime review. *J Craniofac Surg* 2010; 21:998–1001.
3. Millesi H. Interfascicular nerve grafting. *Orthop Clin North Am* 1970;2:419–435.
4. Battiston B, Geuna S, Ferrero M, Tos P. Nerve repair by means of tubulization: Literature review and personal clinical experience comparing biological and synthetic conduits for sensory nerve repair. *Microsurgery* 2005;25:258–267.
5. Lundborg G. *Nerve Injury and Repair*. Edinburgh: Churchill Living-stone; 2005.
6. Weber RV, Mackinnon SE. Bridging the neural gap. *Clin Plast Surg* 2005;32:605–616.
7. Battiston B, Raimondo S, Tos P, Gaidano V, Audisio C, Scevola A, Perroteau I, Geuna S. Tissue engineering of peripheral nerves. *Int Rev Neurobiol* 2009;87:227–249.
8. Dubovy P, Svizenska I. Denervated skeletal muscle stimulates migration of Schwann cells from the distal stump of transected nerve: An in vivo study. *Glia* 1994;12:99–107.
9. Stoll G, Jander S, Myers RR. Degeneration and regeneration of the peripheral nervous system: From Augustus Waller's observations to neuroinflammation. *J Peripher Nerv Syst* 2002;7:13–27.
10. Geuna S, Raimondo S, Ronchi G, Di Scipio F, Tos P, Czaja K, Fornaro M. Histology of the peripheral nerve and changes occurring during nerve regeneration. *Int Rev Neurobiol* 2009;87:27–46.
11. Raimondo S, Fornaro M, Tos P, Battiston B, Giacobini-Robecchi MG, Geuna S. Perspectives in regeneration and tissue engineering of peripheral nerves. *Ann Anat* 2011;193:334–340.
12. Dvali L, Mackinnon S. Nerve repair, grafting and nerve transfers. *Clin Plast Surg* 2003;30:203–221.
13. Dahlin LB. Techniques of peripheral nerve repair. *Scand J Surg* 2008;97:310–316.
14. Ijpma FFA, Van De Graaf RC, Meek MF. The early history of tabulation in nerve repair. *J Hand Surg* 2008;5:581–586.
15. Foramitti C. Zur technik der nervennaht. *Arch Klin Chir* 1904;73: 643–648.
16. Wrede L. Überbrückung eines nervendefektes mittels seidennaht und leben venenstueckes. *Deutsches Medizin Wochenschrift* 1909;35: 1125–1160.
17. Brunelli G, Battiston B, Vigasio A, Brunelli G, Marocolo D. Bridging nerve defects with combined skeletal muscle and vein conduits. *Microsurgery* 1993;14:247–251.
18. Battiston B, Tos P, Cushway T, Geuna S. Nerve repair by means of vein filled with muscle grafts. I. Clinical results. *Microsurgery* 2000;20:32–36.
19. Marcoccio I, Vigasio A. Muscle-in-vein nerve guide for secondary reconstruction in digital nerve lesions. *J Hand Surg* 2010;35:1418–1426.

20. Mackinnon S, Dellon AL. Nerve repair and nerve grafting. In: Surgery of the Peripheral Nerve, Mackinnon S, Dellon AL (Editors). New York: Thieme Medical Publishers; 1988;89–129.
21. Sakellariades H. A follow-up study of 173 peripheral nerve injuries of the upper extremity of civilians. *J Bone Joint Surg Am* 1962;44: 140–148.
22. Battiston B, Tos P, Geuna S, Giacobini-Robecchi MG, Guglielmone R. Nerve repair by means of vein filled with muscle grafts. II. Morphological analysis of regeneration. *Microsurgery* 2000;20:37–41.
23. Geuna S, Tos P, Battiston B, Giacobini-Robecchi MG. Bridging peripheral nerve defects with muscle-vein combined guides. *Neurol Res* 2004;26:139–144.
24. Raimondo S, Nicolino S, Tos P, Battiston B, Giacobini-Robecchi MG, Perroteau I. Schwann cell behavior after nerve repair by means of tissue engineered muscle-vein combined guides. *J Comp Neurol* 2005;489:249–259.
25. Tos P, Battiston B, Nicolino S, Raimondo S, Fornaro M, Lee JM, Chirila L, Geuna S, Perroteau I. Comparison of fresh and predegenerated muscle-vein-combined guides for the repair of rat median nerve. *Microsurgery* 2007;27:48–55.
26. Geuna S, Raimondo S, Nicolino S, Boux E, Fornaro M, Battiston B, Perroteau I. Schwann-cell proliferation in muscle-vein combined conduits for bridging rat sciatic nerve defects. *J Reconstr Microsurg* 2003;19:119–123.
27. Geuna S, Nicolino S, Raimondo S, Gambarotta G, Battiston B, Tos P, Perroteau I. Nerve regeneration along bioengineered scaffolds. *Microsurgery* 2007;27:429–438.
28. Yang M, Rawson JL, Zhang EW, Arnold PB, Lineaweaver W, Zhang F. Comparisons of outcomes from repair of median nerve and ulnar nerve defect with nerve graft and tubulization: A meta-analysis. *J Reconstr Microsurg* 2011;27:451–460.
29. Ijpma FF, Nicolai JP, Meek MF. Sural nerve donor-site morbidity: Thirty-four years of follow-up. *Ann Plast Surg* 2006;57:391–395.
30. Rinker B, Liao JY. A prospective randomized study comparing woven polyglycolic acid and autogenous vein conduits for reconstruction of digital nerve gaps. *J Hand Surg Am* 2011;36:775–781.
31. Kehoe S, Zhang XF, Boyd D. FDA approved guidance conduits and wraps for peripheral nerve injury: A review of materials and efficacy. *Injury* (in press).
32. Jeon WJ, Kang JW, Park JH, Suh DH, Bae JH, Hong JY, Park JW. Clinical application of inside-out vein grafts for the treatment of sensory nerve segmental defect. *Microsurgery* 2011;31: 268–273.