

AperTO - Archivio Istituzionale Open Access dell'Università di Torino

International multicenter experience with an over-the-scope clipping device for endoscopic management of GI defects (with video)

This is the author's manuscript

Original Citation:

Availability:

This version is available <http://hdl.handle.net/2318/145418> since

Published version:

DOI:10.1016/j.gie.2014.03.049

Terms of use:

Open Access

Anyone can freely access the full text of works made available as "Open Access". Works made available under a Creative Commons license can be used according to the terms and conditions of said license. Use of all other works requires consent of the right holder (author or publisher) if not exempted from copyright protection by the applicable law.

(Article begins on next page)



UNIVERSITÀ DEGLI STUDI DI TORINO

This is an author version of the contribution published on:

Questa è la versione dell'autore dell'opera:

[[Gastrointestinal Endoscopy](#), 80(4), 2014, DOI: [10.1016/j.gie.2014.03.049](#)]

The definitive version is available at:

La versione definitiva è disponibile alla URL:

<http://www.sciencedirect.com/science/article/pii/S0016510714013340>

International multicenter experience with an over-the-scope clipping device for endoscopic management of GI defects (with video)

- Yamile Haito-Chavez, MD¹, Joanna K. Law, MD¹, Thomas Kratt, MD², Alberto Arezzo, MD³, Mauro Verra, MD³, Mario Morino, MD³, Reem Z. Sharaiha, MD⁴, Jan-Werner Poley, MD⁵, Michel Kahaleh, MD⁴, Christopher C. Thompson, MD⁶, Michele B. Ryan, MS⁶, Neel Choksi, MD⁷, B. Joseph Elmunzer, MD⁷, Sonia Gosain, MD⁸, Eric M. Goldberg, MD⁸, Rani J. Modayil, MD⁹, Stavros N. Stavropoulos, MD⁹, Drew B. Schembre, MD¹⁰, Christopher J. DiMaio, MD¹¹, Vinay Chandrasekhara, MD¹², Muhammad K. Hasan, MD¹³, Shyam Varadarajulu, MD¹³, Robert Hawes, MD¹³, Victoria Gomez, MD¹⁴, Timothy A. Woodward, MD¹⁴, Sergio Rubel-Cohen, MD¹⁵, Fernando Fluxa, MD¹⁵, Frank P. Vleggaar, MD¹⁶, Venkata S. Akshintala, MD¹, Gottumukkala S. Raju, MD¹⁷, Mouen A. Khashab, MD¹

- ¹ Division of Gastroenterology, Johns Hopkins Hospital, Baltimore, Maryland, USA
- ² Department of General, Visceral and Transplant Surgery, University Hospital of Tübingen, Tübingen, Germany
- ³ Department of Surgical Sciences, University of Torino, Torino, Italy
- ⁴ Department of Internal Medicine, Division of Gastroenterology and Hepatology, Weill Cornell Medical College, New York, New York, USA
- ⁵ Department of Gastroenterology and Hepatology, Erasmus MC, University Medical Center, Rotterdam, The Netherlands
- ⁶ Division of Gastroenterology, Brigham and Women's Hospital, Boston, Massachusetts, USA
- ⁷ Division of Gastroenterology, University of Michigan Medical Center, Ann Arbor, Michigan, USA
- ⁸ Division of Gastroenterology and Hepatology, University of Maryland School of Medicine, Baltimore, MD, USA
- ⁹ Division of Gastroenterology, Hepatology and Nutrition, Winthrop University Hospital, Mineola, New York, USA
- ¹⁰ Swedish Gastroenterology, Swedish Medical Center, Seattle, Washington, USA
- ¹¹ Division of Gastroenterology, The Mount Sinai Medical Center, New York, New York, USA
- ¹² Gastroenterology Division, Department of Internal Medicine, University of Pennsylvania Health System, Philadelphia, PA, USA
- ¹³ Center for Interventional Endoscopy, Florida Hospital, Orlando, Florida, USA
- ¹⁴ Division of Gastroenterology and Hepatology, Department of Medicine, Mayo Clinic, Jacksonville, Florida, USA
- ¹⁵ Department of Gastroenterology, Clinica Las Condes, Universidad de Chile, Santiago, Chile
- ¹⁶ Department of Gastroenterology and Hepatology, University Medical Center Utrecht, Utrecht, The Netherlands
- ¹⁷ Department of Gastroenterology, Hepatology, and Nutrition, University of Texas MD Anderson Cancer Center, Houston, Texas, USA

Background

The over-the-scope clip (OTSC) provides more durable and full-thickness closure as compared with standard clips. Only case reports and small case series have reported on outcomes of OTSC closure of GI defects.

Objective

To describe a large, multicenter experience with OTSCs for the management of GI defects. Secondary goals were to determine success rate by type of defect and type of therapy and to determine predictors of treatment outcomes.

Design

Multicenter, retrospective study.

Setting

Multiple, international, academic centers.

Patients

Consecutive patients who underwent attempted OTSC placement for GI defects, either as a primary or as a rescue therapy.

Interventions

OTSC placement to attempt closure of GI defects.

Main Outcome Measurements

Long-term success of the procedure.

Results

A total of 188 patients (108 fistulae, 48 perforations, 32 leaks) were included. Long-term success was achieved in 60.2% of patients during a median follow-up of 146 days. Rate of successful closure of perforations (90%) and leaks (73.3%) was significantly higher than that of fistulae (42.9%) ($P < .05$). Long-term success was significantly higher when OTSCs were applied as primary therapy (primary 69.1% vs rescue 46.9%; $P = .004$). On multivariate analysis, patients who had OTSC placement for perforations and leaks had significantly higher long-term success compared with those who had fistulae (OR 51.4 and 8.36, respectively).

Limitations

Retrospective design and multiple operators with variable expertise with the OTSC device.

Conclusion

OTSC is safe and effective therapy for closure of GI defects. Clinical success is best achieved in patients undergoing closure of perforations or leaks when OTSC is used for primary or rescue therapy. Type of defect is the best predictor of successful long-term closure.

Abbreviations

- APC, argon plasma coagulation;
- OTSC, over-the-scope clip;
- SEMS, self-expandable metal stent.

GI defects, whether caused by postoperative adverse events (eg, leaks and fistulae), endoscopic perforations, or underlying disease processes, are commonly encountered during endoscopic practice and are associated with significant morbidity and mortality.¹ Anastomotic and staple line leaks occur in 0.4% to 5.2% of patients having Roux-en-y gastric bypass,^{2 and 3} 1.6% to 13.6% of patients having gastric resection for malignant indications,^{4, 5 and 6} and 3% to 33% of patients having a colon resection for colorectal cancer.^{7, 8 and 9} The overall reported morbidity is between 5% and 50%^{2, 3, 8 and 9} and mortality between 0.5% and 1.2%.^{10, 11 and 12} Perforation is the most feared adverse event of GI endoscopy, and its incidence varies depending on multiple patient-related and procedure-related factors.^{13, 14 and 15} The incidence of colon perforations during diagnostic and therapeutic colonoscopy ranges between 0.07% and 0.1%.^{13 and 15} The risk increases to 0.2% after EMR and is as high as 5% after endoscopic submucosal dissection.¹⁶ If a perforation is immediately recognized and endoscopic closure is achieved, surgery can be avoided, provided there is absence of sepsis and generalized peritonitis.^{17 and 18}

Take-home Message

- Over-the-scope clip (OTSC) placement for closure of perforations and leaks was successful in more than 73% of patients, with few requiring subsequent interventions.
- OTSC should be considered in the immediate management of perforations. For closure of GI defects, OTSC placement can be used as primary or rescue therapy in the correct clinical context.

Conventional treatment of GI defects is with surgical management, which is associated with significant morbidity and mortality.^{19 and 20} Technological advances in endoscopic devices have allowed for endoscopic closure of GI defects, including perforations, fistulae, and leaks. Endoscopic therapies include placement of self-expandable metal stents (SEMSs) and application of clips and sealants, and they have proven utility in different clinical scenarios with varying degrees of success.^{21, 22, 23, 24 and 25} The most common endoscopic approach for treatment of GI defects before the over-the-scope clip (OTSC) was the use of temporary SEMSs. A large case series reported a success rate as high as 75% with SEMSs; however, this practice was associated with a high rate of adverse events (46%).²¹

The OTSC (Ovesco Endoscopy AG, Tübingen, Germany) provides more durable closure than standard clips because of its wider mouth and ability to grasp larger amounts of tissue.²⁶ In addition, full-thickness closure is achievable because of greater compressive force.²⁷ Multiple case reports and small case series have reported on the use of OTSCs for closure of GI defects.^{28, 29, 30, 31, 32, 33, 34, 35, 36, 37, 38, 39, 40, 41, 42 and 43} The primary goal of this study was to describe a large, international, multicenter experience with OTSCs for the management of GI perforations, fistulae, and

anastomotic leaks and to determine the overall success of GI defect closure. Secondary goals were to determine success rate by type of defect and type of therapy (primary vs rescue) and to determine predictors of OTSC success.

Methods

This study was approved by the institutional review board for human research at each institution. The study complied with Health Insurance Portability and Accountability Act regulations (Office for Civil Rights. Standards for privacy of individually identifiable health information; final rule. August 14, 2002. 45 CFR parts 160 and 164.) at the 8 U.S. centers.

A retrospective review of consecutive patients who underwent attempted OTSC placement for the indication of GI leak, fistula, or perforation at 16 academic centers in the United States, The Netherlands, Germany, Italy, and Chile was conducted between May 2006 and November 2012. Patients were identified by using endoscopic databases at each institution. All data were extracted and compiled into a central database. Data collection was separated into 3 categories: pre-procedural, procedural, and post-procedural data. Pre-procedural data of interest included patient demographics, indication for OTSC application, underlying etiology of GI defect, time elapsed between the diagnosis and OTSC placement, and any previous endoscopic and/or surgical attempts at repair. Relevant procedure-related data included size, location and appearance of the defect, type and size of OTSC, use and type of traction device, use of adjunct therapy, and immediate technical success. Adverse events were grouped as general or OTSC-related. Post-procedural data included duration of follow-up, need for further endoscopic and/or surgical intervention, radiologic and clinical follow-up, and final status of GI defect at last follow-up. Patients with a follow-up period of <2 weeks were excluded.

Definitions

GI defects included anastomotic leaks, fistulae, and perforations. *Anastomotic leak* was defined as disruption at a surgical anastomosis resulting in a fluid collection with or without evidence of extravasation of contrast medium on radiologic evaluation.⁴⁴ *Fistula* was defined as abnormal communication between 2 epithelialized surfaces.⁴⁵ *Perforation* was defined as an unintentional, acute iatrogenic, full-thickness defect in the GI tract. *Concomitant therapy* was defined as any kind of therapy applied during the same session of OTSC placement. *Primary therapy* referred to placement of an OTSC during the initial attempt at closure of a GI defect, whereas *rescue therapy* referred to placement of an OTSC after a prior failed closure attempt. Technical success was defined as successful deployment of an OTSC at the intended site as determined endoscopically and/or radiographically. *Immediate clinical success* was immediate technical success in addition to the absence of contrast medium extravasation through the defect and/or immediate cessation of drain output.⁴⁶ *Overall long-term clinical success* was defined as the resolution of the GI defect attributed to OTSC at the time of follow-up as evidenced by clinical, endoscopic, and/or abdominal imaging, with a minimum of 2 weeks of follow-up whether closure was performed as primary or rescue therapy.

For secondary analysis looking for predictors of OTSC success, variables were grouped as upper GI tract defects for lesions in the esophagus, stomach, duodenum, and proximal jejunum. *Lower GI defects* were defined as lesions located in the terminal ileum, colon, and rectum. The defects also were grouped into acute and chronic, based on the time elapsed between the diagnosis of the defect and the session of OTSC placement, with a cut-off of 30 days.

Statistical analysis

Descriptive statistics were calculated for all demographic, imaging, and clinical variables and were reported as median with interquartile ranges (IQR), mean \pm standard deviation (SD), or as a proportion. Univariate analysis was performed by using the chi-square test and the Fisher exact test for categorical variables and the *t* test for continuous variables as required. Multivariate analysis was performed by using logistic regression to evaluate the factors influencing the success of OTSC placement. The variables for inclusion in the logistic regression model were chosen based on existing clinical data and a cut-off *P* value of .50. All statistical analysis was conducted by using SPSS version 19 (IBM, SPSS Statistics, Armonk, NY). A *P* value of $< .05$ was considered significant.

Results

During the study period, 188 patients (101 female, mean [\pm SD] age 58.7 ± 14.9 years) underwent OTSC placement for closure of GI defects. The most common indication for OTSC placement was closure of fistulae (108 patients [57.5%]), followed by perforations (48 patients [25.5%]), followed by leaks (32 patients [17.0%]). OTSCs were most commonly placed in the upper GI tract (esophagus and stomach, $n = 118$, 62.8%) followed by colon and rectum ($n = 50$, 26.6%) and the small bowel ($n = 20$, 10.6%) ([Table 1](#)).

Table 1.

Demographics and characteristics of patients, defects, and OTSCs used

	Total n = 188	Fistulae n = 108	Perforations n = 48	Leaks n = 32
Age, mean (\pm SD) y	58.7 (14.9)	56.8 (14.9)	64.0 (14.2)	57.3 (14.3)
Defect diameter, median (IQR) mm	7 (4-10)	5 (4-10)	7 (4-11.5)	8 (5-10)
Sex, no. (%)				
Female	101 (53.7)	66 (61.1)	22 (45.8)	13 (40.6)
Time elapsed from clinical diagnosis of defect to OTSC placement, no. (%) d				
Immediate	48 (25.5)	0 (0)	43 (89.6)	5 (15.6)
<7	14 (7.4)	3 (2.8)	4 (8.3)	7 (21.9)
7-30	30 (15.9)	17 (15.7)	1 (2.1)	12 (37.5)
>30	96 (51.2)	88 (81.5)	0 (0)	8 (25)
Location of GI defect, no. (%)				
Esophagus	31 (16.5)	16 (14.8)	10 (20.8)	5 (15.6)
Stomach	87 (46.3)	63 (58.3)	13 (27.1)	11 (34.4)
Duodenum	11 (5.8)	1 (0.9)	9 (18.8)	1 (3.1)
Jejunum-ileum	9 (4.8)	5 (4.6)	4 (8.3)	0 (0)

	Total n = 188	Fistulae n = 108	Perforations n = 48	Leaks n = 32
Colon	19 (10.1)	8 (7.5)	8 (16.7)	3 (9.4)
Rectum	31 (16.5)	15 (13.9)	4 (8.3)	12 (37.5)
OTSC type, no. (%)				
11/6-A	11 (5.3)	4 (3.3)	7 (12.7)	0 (0)
11/6-T	5 (2.4)	3 (2.5)	1 (1.8)	1 (2.7)
12/6-A	5 (2.4)	1 (0.8)	4 (7.3)	0 (0)
12/6-T	113 (54.1)	55 (46.6)	32 (58.2)	26 (72.3)
12/6-GC	42 (20.1)	35 (29.7)	4 (7.3)	3 (8.4)
14/6-A	3 (1.4)	2 (1.7)	0 (0)	1 (2.7)
14/6-T	24 (11.5)	12 (10.2)	7 (12.7)	5 (13.9)
Unknown	6 (2.8)	6 (5.2)	0 (0)	0 (0)

OTSC, Over-the-scope clip; *SD*, standard deviation; *IQR*, interquartile range.

A total of 27 patients were lost to follow-up and excluded from analysis. Technical success was achieved in 151 patients (93.8%), with 1 OTSC placed in 142 patients (94 %). Type of OTSC used per defect is shown in [Table 1](#). Among 151 patients who underwent successful OTSC placement, 140 (92.7%) achieved immediate clinical success, and 11 (7.3%) were clinical failures. Overall long-term clinical success was achieved in 97 patients (60.2%) during a median follow-up of 146 days (IQR 60-337 days) ([Fig. 1](#)). Long-term clinical success was significantly higher when OTSCs were applied as primary therapy as compared with rescue therapy (69.1% vs 46.9%, respectively; $P = .004$).

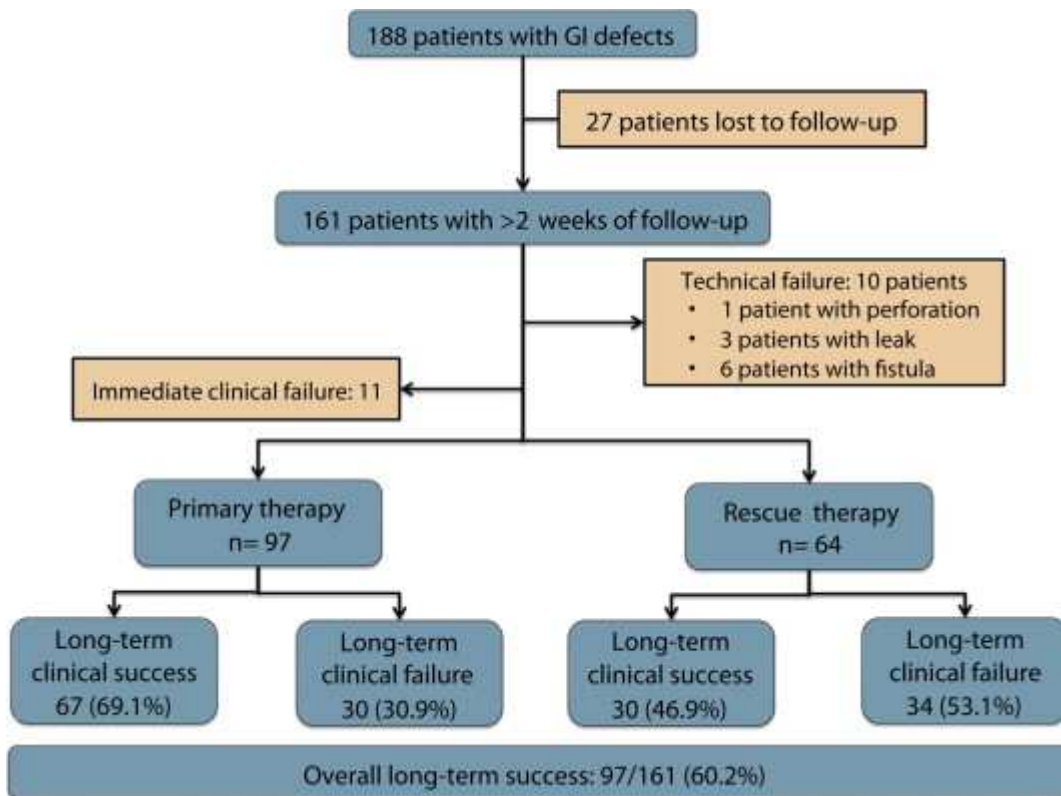


Figure 1.

Flow chart of 188 patients with GI defects who underwent over-the-scope clip placement.

There were no adverse events directly related to OTSC placement, although 1 patient died after failed closure of a colon perforation despite subsequent surgical intervention.

Patients with fistulae

Among the patients ($n = 108$) who underwent OTSC placement for fistulae closure, the most common location of the fistula was in the stomach ($n = 63$, 58.3%), followed by esophagus ($n = 16$, 14.8%) and rectum ($n = 15$, 13.9%). Persistent fistulae after removal of PEG or jejunostomy tubes were the most common etiology for fistula formation and occurred in 38 patients, followed by the patient having had bariatric surgery in 22 patients (Table 2). Fistulae were diagnosed <7 days before OTSC placement in 3 patients (2.8%), 7 to 30 days in 17 patients (15.7%), and >30 days in 88 patients (81.5%) (Table 1). A total of 51 patients (47.2%) had undergone unsuccessful previous attempts at fistulae closure before OTSC placement, with the most common being pure endoscopic therapy in 29 patients, followed by surgery in 11, combined therapy in 7, and percutaneous drainage in 4 (Table 2). The median defect size was 5 mm (IQR 4-10 mm). Concomitant endoscopic therapy at time of OTSC placement was performed in 47 patients (43.5%), with argon plasma coagulation (APC) being the most commonly used modality ($n = 35$, 32.4%).

Table 2.

Etiology and previous therapy in patients undergoing OTSC placement for fistulae closure

Patients with fistulae, $n = 108$

Etiology of fistula, no. (%)

Patients with fistulae, n = 108

PEG/PEJ tube-related	38 (35.2)
Result of bariatric surgery	22 (20.4)
Malignancy-related	20 (18.5)
Other*	28 (25.9)
Type of therapy prior to OTSC, no. (%)	51 (47.2)
Surgical	11 (10.2)
Percutaneous drainage	4 (3.7)
Endoscopic	29 (26.9)
Surgical and endoscopic	7 (6.4)

OTSC, Over-the-scope clip; PEJ, percutaneous endoscopic jejunostomy.

*Other included trauma, inflammatory bowel disease, and diverticulitis.

A total of 17 patients were lost to follow-up and excluded from the analysis. Technical success was achieved in 85 of the 91 patients with fistulae (93.4%). All 6 (6.6%) technical failures occurred in patients with upper GI fistulae caused by fibrotic or retracted edges impeding an adequate opposition of defect borders. In 5 of the 6 cases, a traction device (either an anchor or a twin grasper) was used (Table 3). Among patients who underwent successful OTSC placement, immediate clinical success was achieved in 77 patients (90.6%).

Table 3.

Characteristics of patients with technical failure

Type of lesion	Location	Prior therapy	Traction device used	Nature of borders	Cause of technical failure
Perforation	Duodenum	None	Twin grasper	Necrotic	Location and size of 15 mm
Leak	Esophagogastric	SEMS	Anchor grasper	Fibrotic	
Leak	Colorectal	Endoscopic vacuum	Foreign body grasper	Retracted	
Leak	Colorectal	None	Foreign body grasper	Retracted	
Fistula	Esophagocutaneous	SEMS	Twin grasper		Technical; OTSC fell off when the captured grasper was removed
Fistula	Esophagopleural	SEMS	Anchor grasper	Retracted	
Fistula	Tracheoesophageal	SEMS	Anchor	Retracted	

Type of lesion	Location	Prior therapy	Traction device used	Nature of borders	Cause of technical failure
Fistula	Gastrocutaneous	Surgery and SEMS	grasper Direct suction	Retracted	
Fistula	Gastrogastic	None	Twin grasper	Fibrotic	
Fistula	Gastrogastic	Endoscopic suturing	Twin grasper	Retracted	

SEMS, Self-expandable metal stent. OTSC, over-the-scope clip.

During a median follow-up period of 121 days (IQR 56-277 days), overall clinical success was achieved in 39 patients (42.9%) (Fig. 2). Long-term clinical success was numerically higher when OTSCs were placed as primary therapy, but the difference was not statistically significant (23/46 or 50% vs 16/45 or 35.6%; $P = .10$) (Fig. 3).

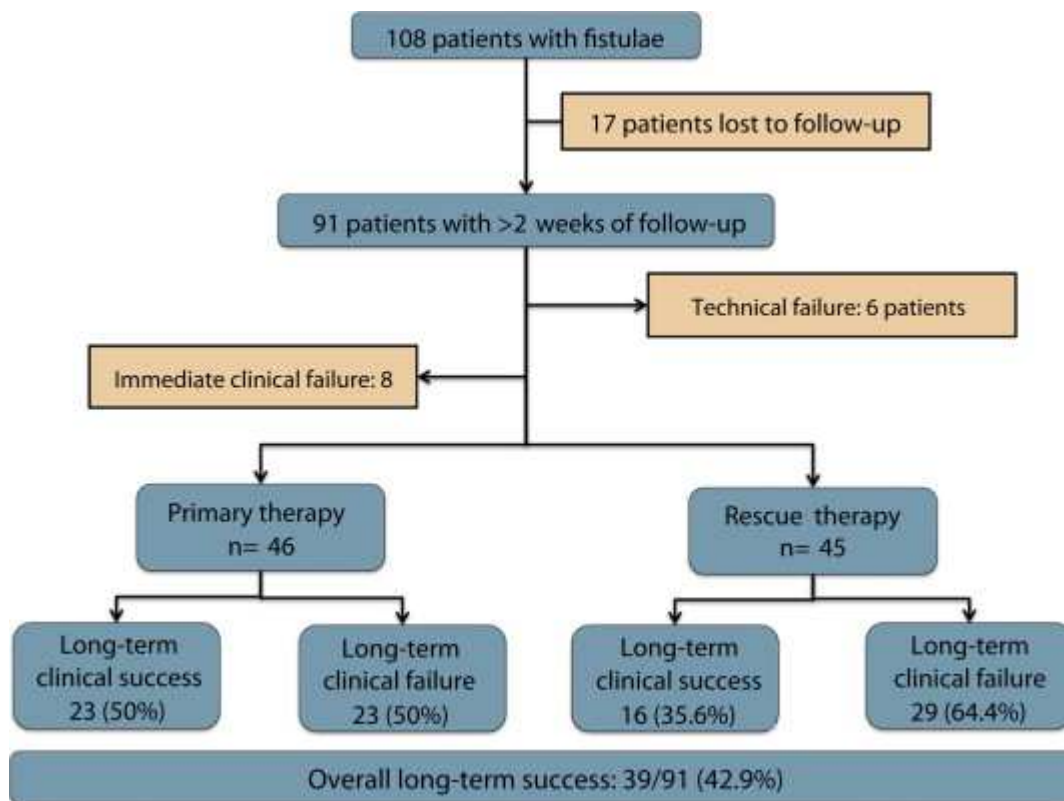


Figure 2.

Flow chart of patients with fistulae who underwent over-the-scope clip placement.

Patients with perforation

A total of 48 (25.5%) patients underwent OTSC placement for closure of perforations, with the most common location being the stomach ($n = 13$, 27.1%), followed by esophagus ($n = 10$, 20.8%), duodenum ($n = 9$, 18.8%), colon ($n = 8$, 16.7%), rectum ($n = 4$, 8.3%), and jejunum/ileum ($n = 4$, 8.3%) (Table 1). The most common etiology was iatrogenic ($n = 36$, 75.0%) (Table 4). OTSC

placement was performed immediately after clinical diagnosis of a perforation in most cases (89.6%) (Table 1). A total of 5 patients (10.4%) had undergone failed attempts at perforation closure. OTSC was used within the first week of defect diagnosis in 4 of these patients (Table 1). The median defect size was 7 mm (IQR 4-11.5 mm), and none of the patients required concomitant endoscopic therapy.

Table 4.

Etiology and previous therapy in patients undergoing OTSC placement for perforation closure

Patients with perforations, n = 48

Etiology of perforation, no. (%)	
Iatrogenic	36 (75.0)
Pathologic (PUD or pancreatitis)	3 (6.3)
Other*	9 (18.7)
Type of therapy prior to OTSC, no. (%)	5 (10.4)
Surgical	2 (4.1)
Percutaneous drainage	1 (2.1)
Endoscopic	1 (2.1)
Surgical and endoscopic	1 (2.1)

OTSC, Over-the-scope clip; PUD, peptic ulcer disease.

*Other included trauma, stent migration, foreign body-related, or spontaneous.

A total of 8 patients were excluded from the analysis because they were lost to follow-up. Technical success was achieved in 39 patients (97.5%), with the deployment of 1 clip in 37 patients and 2 clips in 1 patient. One patient with a large rectal perforation (80 mm) secondary to Rectobag (B. Braun AG, Melsungen, Germany) required a total of 5 OTSC clips for successful perforation closure. Closure failed in 1 patient with a 15-mm duodenal perforation after EMR because of the lesion's necrotic borders (Table 3). Among patients who underwent successful OTSC placement, immediate clinical success was achieved in 37 patients (94.9%).

During a median follow-up period of 207 days (IQR 62-451 days), overall long-term clinical success was achieved in 36 patients (90%) (Fig. 4). Long-term clinical success was higher when OTSC was applied as primary therapy as compared with rescue therapy, but the difference was not statistically significant (32/35 or 91.4% vs 4/5 or 80%; $P = .40$) (Fig. 3).

Patients with leaks

A total of 32 patients underwent OTSC placement for closure of leaks. The most common etiology for leaks was colorectal surgery (n = 15, 46.9%), followed by bariatric surgery (n = 9, 28.1%) and other upper GI surgeries (n = 8, 25%) (Table 5). Leaks occurred most commonly in the rectum (n = 12, 37.5%), followed by the stomach (n = 11, 34.4%). OTSC placement was performed immediately after clinical diagnosis of a leak in 5 patients (15.6%), within 7 days in 7 patients (21.9%), 7 to 30 days in 12 patients (37.5%), and >30 days in 8 patients (25.0%) (Table 1). A total of 15 patients (46.9%) had undergone failed treatment of leaks (Table 5). The median defect size

was 8 mm (IQR 5-10 mm). Concomitant endoscopic therapy was performed in 5 patients (15.6%), all of whom had APC applied to the edges of the leakage site before OTSC placement.

Table 5.

Etiology and previous therapy in patients undergoing OTSC placement for leak closure

Patients with leaks, n = 32

Etiology of leak, no. (%)	
After colorectal surgery	15 (46.9)
Result of bariatric surgery	9 (28.1)
After other upper GI surgery	8 (25.0)
Type of therapy prior to OTSC, no. (%)	15 (46.9)
Surgical	2 (6.3)
Endoscopic	10 (31.2)
Surgical and endoscopic	2 (6.3)
Surgical, endoscopic, and percutaneous drainage	1 (3.1)

OTSC, Over-the-scope clip.

A total of 2 patients were lost to follow-up and excluded from the analysis. Technical success was achieved in 27 patients (90%). Success was achieved with deployment of 1 clip in 25 patients and 2 clips in 2 patients. OTSC placement failed in 3 patients (10%) with leaks located in the lower GI tract, with failure attributed to the fibrotic or retracted nature of defect borders (Table 3). Among 27 patients who underwent successful OTSC placement, immediate clinical success was achieved in 26 patients (96.3%).

The median follow-up period was 202 days (IQR 88-371). Overall long-term clinical success was achieved in 22 patients (73.3%) (Fig. 5). Long-term clinical success was not different when OTSC was applied as primary therapy as compared with rescue therapy (12/16 or 75% vs 10/14 or 71.4%; $P = .60$) (Fig. 3).

Outcomes according to type of defect and therapy (primary vs rescue)

The overall long-term clinical success was highest for perforations (90%), followed by leaks (73.3%), and then fistulae (42.9%). The rate of successful closure of perforations (90%) and leaks (73.3%) was significantly higher than that of fistulae (42.9%) ($P < .05$ for both comparisons); however, there was no significant difference between the overall long-term clinical success rate of closure of perforations and leaks ($P = .06$) (Fig. 6). When the overall long-term clinical success was compared based on type of therapy, the success rate was significantly higher when OTSC was placed as a primary therapy as compared with rescue therapy (69.1% vs 46.9%, respectively; $P = .004$). Across all 3 defect types—perforations, fistulae, and leaks—OTSC performed better when the clip was applied as a primary therapy, although the difference was not statistically significant (Fig. 3).

Predictors of OTSC success

A secondary analysis was performed to evaluate predictors of OTSC success (Table 6). On univariate analysis, there were 3 statistically significant predictors for long-term success: (1) type of defect (perforations and leaks as compared with fistulae; odds ratio [OR] 35.08; $P < .0001$ and OR 5.36; $P = .002$, respectively), (2) primary therapy versus rescue therapy (OR 3.10; $P = .003$), and (3) chronicity of defects (≤ 30 days vs > 30 days) (OR 3.84; $P < .0001$). On multivariate analysis, only the type of defect continued to be significant. Patients who had OTSC placement for perforations and leaks had significantly higher long-term clinical success compared with those who had placement for fistulae (OR 51.4; $P = .002$ and OR 8.36; $P = .002$, respectively) (Table 6).

Table 6.

Univariate and multivariate analyses of predictors of clinical success of OTSC

Variable	Patients with long-term success, n = 97	Patients with long-term failure, n = 43	Univariate analysis		Multivariate analysis	
			OR (95% CI)	P value	Adjusted OR (95% CI) [‡]	P value
Type of defect, no. (%)						
Fistulae	39 (40.2)	38 (88.4)	Ref		Ref	
Perforation	36 (37.1)	1 (2.3)	35.08 (4.58-268.86)	< .0001	51.4 (4.4-601.4)	.002
Leak	22 (22.7)	4 (9.3)	5.36 (1.69-17.01)	.002	8.36 (2.2-32.5)	.002
Size of defect, mean (\pm SD), mm	8.3 (9.1)	8.4 (5.3)		.92	0.97 (0.9-1.0)	.235
Upper GI location, no. (%) [†]	71 (73.2)	29 (67.4)	1.32 (0.6-2.88)	.49	0.45 (0.16-1.3)	.135
Approach as primary therapy, no. (%) [‡]	67 (69.1)	18 (41.9)	3.10 (1.47-6.52)	.003	0.52 (0.2-1.3)	.143
Acute lesions, no. (%) [§]	58 (59.8)	12 (72.1)	3.84 (1.76-8.38)	< .0001	0.61 (0.2-2.0)	.426
Use of traction device, no. (%)	50 (51.5)	26 (60.5)	0.69 (0.33-1.44)	.33	0.89 (0.3-2.2)	.794
Use of concomitant therapy, no. (%)	16 (16.5)	17 (39.5)	0.30 (0.13-0.68)	.003	1.95 (0.7-5.4)	.200

OTSC, Over-the-scope clip; OR, odds ratio; CI, confidence interval; SD, standard deviation.

[‡]Adjusted for all other variables included in the model.

†Compared with lower GI tract location.

‡Compared with rescue therapy.

§Compared with chronic lesions.

Discussion

One of the major challenges of current endoscopic practice is lack of a reliable and durable closure device for treatment of GI defects. Such a device will not only result in avoidance of more invasive approaches for the treatment of various pathologies (eg, acute perforations, anastomotic leaks, and fistulae) but will permit endoscopists to extend new treatment approaches to other GI diseases (eg, full-thickness resection of subepithelial lesions and natural orifice transluminal endoscopic surgery).

Endoscopic options for the closure of GI defects range from direct closure through the application of devices such as metallic clips⁴⁷ and band ligatures, injection of biologically compatible sealants,⁴⁸ and suturing to secondary closure with implantable bioprosthetic grafts or SEMSs.⁴⁹ The success of all of these approaches is limited by technical and anatomic considerations including the size and location of the defect, the type of defect, and accessibility of the defect.

The OTSC results in more vigorous closure than regular through-the-scope clips because of its wider mouth and ability to grip larger amounts of tissue.²⁶ In addition, full-thickness closure is attainable because of greater compressive force.²⁷ There currently exist no robust data to ensure efficacy and safety of OTSCs in various clinical scenarios because only case reports and small case series have been published.

The current study is the largest to-date to assess outcomes of OTSCs in management of GI fistulae, perforations, and leaks. It is a multicenter international study of 188 patients with GI defects, with more than half of the patients undergoing therapy for closure of fistulae. Technical success of OTSC deployment was achieved in more than 90% of cases. Failure of OTSC deployment occurred most commonly in patients with fistulae, all of whom were found to have fistulae with fibrotic and retracted rims, resulting in difficult approximation of the edges despite use of traction devices in the majority of cases. Immediate clinical success was reported in over 90% of patients in this series. Overall long-term clinical success was achieved in about 60.2% of patients and occurred significantly more often in patients who underwent OTSC placement as primary therapy rather than rescue therapy ($P = .004$). This is expected given that the latter group of patients had difficult-to-treat pathology. A large percentage (71/188 or 38%) of patients had undergone failed endoscopic, surgical, and/or radiologic therapy, which may have resulted in relatively lower than expected long-term clinical success. Importantly, there were no short-term or long-term adverse events attributed to OTSC placement.

Outcomes of OTSC were studied according to type of GI defect (fistula vs perforation vs leak) and according to type of therapy (primary vs rescue). OTSCs resulted in long-term clinical success in almost all patients with perforations. The median perforation size was 7 mm, but successful closure was achieved even in larger defects (up to 80 mm). It is expected that multiple OTSCs are needed to close larger defects. Similarly, successful closure of leaks was achieved in the majority of patients (73.3%). Successful closure was attained significantly more in both groups of patients as compared with patients with fistulae, in whom overall long-term clinical success was achieved in less than half. Although this could be a result of inclusion of a high proportion of patients who had undergone failed endoscopic and/or surgical therapy in the fistulae group, it is believed that closure of fistulae is technically challenging because of the lesions' fibrotic edges. Moreover, only a third of patients with fistulae underwent APC ablation; epithelial surfaces within the fistulae may have

persisted in the remainder of patients, which may have resulted in failure of therapy and/or recurrent disease.

OTSCs performed better across all 3 defect types—perforations, fistulae, and leaks—when the clip was applied as primary therapy as opposed to rescue therapy, although the difference was not statistically significant (Fig. 3).

A secondary analysis was performed to evaluate predictors of OTSC success (Table 6). Although type of defect (perforations and leaks vs fistulae) and approach as primary therapy versus rescue therapy were statistically significant predictors for long-term success on univariate analysis, only the type of defect continued to be significant on multivariate analysis. Therefore, type of defect is the most important predictor of long-term success of OTSC closure.

The results of the current study are in accordance with those from prior small case series. In 1 series of 9 patients treated with OTSCs for GI defects, fistula closure was reported in 33% of patients.⁴⁰ Similar to our experience, failure of defect closure was primarily related to the inability to oppose the fibrotic edges of fistulae. In a larger series of 17 patients who underwent OTSC placement for closure of perforations, successful closure was reported in 64.7%, with failure attributed to inflammatory or necrotic margins and larger perforations (>20 mm).³⁹ In the largest U.S. multicenter experience, 38 patients underwent OTSC placement for closure of GI defects, with clinical success reported in 25 patients (65.8%).⁵⁰ The authors also attributed decreased clinical success to the fibrotic nature of the edges of fistulae and leaks. Finally, in the other relatively large OTSC series,³⁸ there were 8 patients with fistulae and 11 patients with perforation. Although long-term success was achieved in all patients with perforations, only 3 patients with fistulae achieved clinical success.

The main limitation of this study is its retrospective nature. In addition, procedures were performed by multiple endoscopists with different overall endoscopic experience and variable expertise with the OTSC device. This may have introduced heterogeneity to the study. Selection bias also may have occurred because the effectiveness of OTSC placement in patients with fistulae, leaks, or perforations that were not deemed appropriate for OTSC placement by the operator cannot be assessed. The study, however, has many strengths. It is a large, multicenter, international study of 188 patients, all with GI defects and with a median follow-up period of 146 days. All patients who underwent OTSC placement for treatment of GI bleeding or for anchoring of stents were excluded. Therefore, the study cohort is homogenous. The large number of patients included allowed performance of univariate and multivariate analysis. All potential confounders, including use of concomitant therapy, were controlled for on multivariate analysis.

In conclusion, OTSC is safe and effective therapy for closure of GI defects (Figure 7, Figure 8, Figure 9 and Figure 10). Clinical success was best achieved in patients undergoing closure of perforations or leaks when OTSC placement was used for primary or rescue therapy. The overall clinical success for the closure of perforations and leaks ranged between 73% and 90%. Successful closure of fistulae was achieved in less than half of the patients. The type of defect is the best predictor of successful long-term closure.

References

- 1
- W.P. Schecter, A. Hirshberg, D.S. Chang, *et al.*
- Enteric fistulas: principles of management

- J Am Coll Surg, 209 (2009), pp. 484–491
- 2
- P.S. Griffith, D.W. Birch, A.M. Sharma, *et al.*
- Managing complications associated with laparoscopic Roux-en-Y gastric bypass for morbid obesity
- Can J Surg [Journal Canadien de Chirurgie], 55 (2012), pp. 329–336
- 3
- T.M. Fullum, K.J. Aluka, P.L. Turner
- Decreasing anastomotic and staple line leaks after laparoscopic Roux-en-Y gastric bypass
- Surg Endosc, 23 (2009), pp. 1403–1408
- 4
- S. Sakuramoto, S. Kikuchi, N. Futawatari, *et al.*
- Laparoscopy-assisted pancreas- and spleen-preserving total gastrectomy for gastric cancer as compared with open total gastrectomy
- Surg Endosc, 23 (2009), pp. 2416–2423
- 5
- S.G. Kim, Y.J. Lee, W.S. Ha, *et al.*
- LATG with extracorporeal esophagojejunostomy: Is this minimal invasive surgery for gastric cancer?
- J Laparoendosc Adv Surg Tech, Part A, 18 (2008), pp. 572–578
- 6
- M.G. Kim, B.S. Kim, T.H. Kim, *et al.*
- The effects of laparoscopic assisted total gastrectomy on surgical outcomes in the treatment of gastric cancer
- J Korean Surg Soc, 80 (2011), pp. 245–250
- 7
- J.D. Smith, P.B. Paty, J.G. Guillem, *et al.*
- Anastomotic leak is not associated with oncologic outcome in patients undergoing low anterior resection for rectal cancer
- Ann Surg, 256 (2012), pp. 1034–1038
- 8
- A. Mirnezami, R. Mirnezami, K. Chandrakumaran, *et al.*
- Increased local recurrence and reduced survival from colorectal cancer following anastomotic leak: systematic review and meta-analysis
- Ann Surg, 253 (2011), pp. 890–899
- 9
- G. Branagan, D. Finnis
- Prognosis after anastomotic leakage in colorectal surgery
- Dis Colon Rect, 48 (2005), pp. 1021–1026
- 10
- A.Z. Fernandez Jr., E.J. Demaria, D.S. Tichansky, *et al.*
- Multivariate analysis of risk factors for death following gastric bypass for treatment of morbid obesity
- Ann Surg, 239 (2004), pp. 698–702 discussion 3
- 11
- L. Flancbaum, S. Belsley
- Factors affecting morbidity and mortality of Roux-en-Y gastric bypass for clinically severe obesity: an analysis of 1,000 consecutive open cases by a single surgeon
- J Gastrointest Surg, 11 (2007), pp. 500–507
-

- 12
- S.K. Zachariah, P.C. Chang, A.S. Ooi, *et al.*
- Laparoscopic sleeve gastrectomy for morbid obesity: 5 years experience from an Asian center of excellence
- *Obes Surg*, 23 (2013), pp. 939–946
- 13
- A.F. Hagel, F. Boxberger, W. Dauth, *et al.*
- Colonoscopy-associated perforation: a 7-year survey of in-hospital frequency, treatment and outcome in a German university hospital
- *Colorect Dis*, 14 (2012), pp. 1121–1125
- 14
- M. Kim, S.W. Jeon, K.B. Cho, *et al.*
- Predictive risk factors of perforation in gastric endoscopic submucosal dissection for early gastric cancer: a large, multicenter study
- *Surg Endosc*, 27 (2013), pp. 1372–1378
- 15
- N.E. Samalavicius, D. Kazanavicius, R. Lunevicius, *et al.*
- Incidence, risk, management, and outcomes of iatrogenic full-thickness large bowel injury associated with 56,882 colonoscopies in 14 Lithuanian hospitals
- *Surg Endosc*, 27 (2013), pp. 1628–1635
- 16
- G.S. Raju, Y. Saito, T. Matsuda, *et al.*
- Endoscopic management of colonoscopic perforations (with videos)
- *Gastrointest Endosc*, 74 (2011), pp. 1380–1388
- 17
- T. Sagawa, S. Kakizaki, H. Iizuka, *et al.*
- Analysis of colonoscopic perforations at a local clinic and a tertiary hospital
- *W J Gastroenterol*, 18 (2012), pp. 4898–4904
- 18
- G.S. Matharoo, M.A. Goldfarb
- Treatment and outcomes of iatrogenic colon perforations at a community teaching hospital
- *Am Surg*, 78 (2012), pp. 975–978
- 19
- T.H. Luning, M.E. Keemers-Gels, W.B. Barendregt, *et al.*
- Colonoscopic perforations: a review of 30,366 patients
- *Surg Endosc*, 21 (2007), pp. 994–997
- 20
- C. Svanes
- Trends in perforated peptic ulcer: incidence, etiology, treatment, and prognosis
- *W J Surg*, 24 (2000), pp. 277–283
- 21
- P.G. van Boeckel, K.S. Dua, B.L. Weusten, *et al.*
- Fully covered self-expandable metal stents (SEMS), partially covered SEMS and self-expandable plastic stents for the treatment of benign esophageal ruptures and anastomotic leaks
- *BMC Gastroenterol*, 12 (2012), p. 19

- 22
- J.S. Kim, B.W. Kim, J.I. Kim, *et al.*
- Endoscopic clip closure versus surgery for the treatment of iatrogenic colon perforations developed during diagnostic colonoscopy: a review of 115,285 patients
- *Surg Endosc*, 27 (2013), pp. 501–504
- 23
- S. Haider, M. Kahaleh
- The use of endoscopic clipping devices in the treatment of iatrogenic duodenal perforation
- *Gastroenterol Hepatol*, 6 (2010), pp. 660–661
- 24
- P.W. Carrott Jr., D.E. Low
- Advances in the management of esophageal perforation
- *Thorac Surg Clin*, 21 (2011), pp. 541–555
- 25
- S.H. Blackmon, R. Santora, P. Schwarz, *et al.*
- Utility of removable esophageal covered self-expanding metal stents for leak and fistula management
- *Ann Thorac Surg*, 89 (2010), pp. 931–936 discussion 6-7
- 26
- D. von Renteln, M.C. Vassiliou, R.I. Rothstein
- Randomized controlled trial comparing endoscopic clips and over-the-scope clips for closure of natural orifice transluminal endoscopic surgery gastrotomies
- *Endoscopy*, 41 (2009), pp. 1056–1061
- 27
- S. Banerjee, B.A. Barth, Y.M. Bhat, *et al.*
- Endoscopic closure devices
- *Gastrointest Endosc*, 76 (2012), pp. 244–251
- 28
- T. Weiland, M. Fehlker, T. Gottwald, *et al.*
- Performance of the OTSC System in the endoscopic closure of iatrogenic gastrointestinal perforations: a systematic review
- *Surg Endosc*, 27 (2013), pp. 2258–2274
- 29
- T. Weiland, M. Fehlker, T. Gottwald, *et al.*
- Performance of the OTSC System in the endoscopic closure of gastrointestinal fistulae—a meta-analysis
- *Min Inv Ther Allied Tech*, 21 (2012), pp. 249–258
- 30
- D. von Renteln, U.W. Denzer, G. Schachschal, *et al.*
- Endoscopic closure of GI fistulae by using an over-the-scope clip (with videos)
- *Gastrointest Endosc*, 72 (2010), pp. 1289–1296
- 31
- M. Sandmann, M. Heike, M. Faehndrich
- Application of the OTSC system for the closure of fistulas, anastomosal leakages and perforations within the gastrointestinal tract [German]
- *Zeitschrift fur Gastroenterologie*, 49 (2011), pp. 981–985
- 32
- R.L. Probst, A. Herold, A.K. Joos, *et al.*
- The anal fistula claw: the OTSC clip for anal fistula closure
- *Colorect Dis*, 14 (2012), pp. 1112–1117

- 33
- J. Pohl, M. Borgulya, D. Lorenz, *et al.*
- Endoscopic closure of postoperative esophageal leaks with a novel over-the-scope clip system
- *Endoscopy*, 42 (2010), pp. 757–759
- 34
- H. Mori, H. Kobara, S. Fujihara, *et al.*
- Rectal perforations and fistulae secondary to a glycerin enema: closure by over-the-scope-clip
- *W J Gastroenterol*, 18 (2012), pp. 3177–3180
- 35
- R. Mennigen, M. Colombo-Benkmann, N. Senninger, *et al.*
- Endoscopic closure of postoperative gastrointestinal leakages and fistulas with the over-the-scope clip (OTSC)
- *J Gastrointest Surg*, 17 (2013), pp. 1058–1065
- 36
- R. Manta, M. Manno, H. Bertani, *et al.*
- Endoscopic treatment of gastrointestinal fistulas using an over-the-scope clip (OTSC) device: case series from a tertiary referral center
- *Endoscopy*, 43 (2011), pp. 545–548
- 37
- T.H. Kothari, G. Haber, N. Sonpal, *et al.*
- The over-the-scope clip system—a novel technique for gastrocutaneous fistula closure: the first North American experience
- *Can J Gastroenterol*, 26 (2012), pp. 193–195
- 38
- A. Kirschniak, N. Subotova, D. Zieker, *et al.*
- The over-the-scope clip (OTSC) for the treatment of gastrointestinal bleeding, perforations, and fistulas
- *Surg Endosc*, 25 (2011), pp. 2901–2905
- 39
- A.F. Hagel, A. Naegel, A.S. Lindner, *et al.*
- Over-the-scope clip application yields a high rate of closure in gastrointestinal perforations and may reduce emergency surgery
- *J Gastrointest Surg*, 16 (2012), pp. 2132–2138
- 40
- S. Disibeyaz, A.S. Koksall, E. Parlak, *et al.*
- Endoscopic closure of gastrointestinal defects with an over-the-scope clip device. A case series and review of the literature
- *Clin Res Hepatol Gastroenterol*, 36 (2012), pp. 614–62
- 41
- R. Bini, F. Coppola, S. Recchia, *et al.*
- Endoscopic treatment of postgastroectomy duodenal fistula with an over-the-scope clip
- 1. *Surg Innov*, 18 (2011), pp. 102–104
- 42
- A. Arezzo, M. Verra, R. Reddavid, *et al.*
- Efficacy of the over-the-scope clip (OTSC) for treatment of colorectal postsurgical leaks and fistulas
- *Surg Endosc*, 26 (2012), pp. 3330–3333
-

- 43
- A. Aly, H.K. Lim
- The use of over the scope clip (OTSC) device for sleeve gastrectomy leak
- J Gastrointest Surg, 17 (2013), pp. 606–608
- 44
- H. Caulfield, N.H. Hyman
- Anastomotic leak after low anterior resection: a spectrum of clinical entities
- JAMA Surg, 148 (2013), pp. 177–182
- 45
- C. Metcalf
- Enterocutaneous fistulae
- J Wound Care, 8 (1999), pp. 141–142
- 46
- A. Repici, N. Pagano, G. Rando, *et al.*
- A retrospective analysis of early and late outcome of biodegradable stent placement in the management of refractory anastomotic colorectal strictures
- Surg Endosc, 27 (2013), pp. 2487–2491
- 47
- J. Romagnuolo
- Endoscopic clips: past, present and future
- Can J Gastroenterol, 23 (2009), pp. 158–160
- 48
- C.S. Huang, D.T. Hess, D.R. Lichtenstein
- Successful endoscopic management of postoperative GI fistula with fibrin glue injection: report of two cases
- Gastrointest Endosc, 60 (2004), pp. 460–463
- 49
- H.J. Choi, B.I. Lee, J.J. Kim, *et al.*
- The temporary placement of covered self-expandable metal stents to seal various gastrointestinal leaks after surgery
- Gut Liver, 7 (2013), pp. 112–115
- 50
- T.H. Baron, L.M. Song, A. Ross, *et al.*
- Use of an over-the-scope clipping device: multicenter retrospective results of the first U.S. experience (with videos)
- Gastrointest Endosc, 76 (2012), pp. 202–208