

AperTO - Archivio Istituzionale Open Access dell'Università di Torino

Choristoma involving the floor of the mouth and the anterior tongue: a case of teratoid cyst with gastric and respiratory epithelia.

This is the author's manuscript

Original Citation:

Availability:

This version is available <http://hdl.handle.net/2318/139892> since

Published version:

DOI:10.1016/j.joms.2013.04.020

Terms of use:

Open Access

Anyone can freely access the full text of works made available as "Open Access". Works made available under a Creative Commons license can be used according to the terms and conditions of said license. Use of all other works requires consent of the right holder (author or publisher) if not exempted from copyright protection by the applicable law.

(Article begins on next page)



UNIVERSITÀ DEGLI STUDI DI TORINO

This Accepted Author Manuscript (AAM) is copyrighted and published by Elsevier. It is posted here by agreement between Elsevier and the University of Turin. Changes resulting from the publishing process - such as editing, corrections, structural formatting, and other quality control mechanisms - may not be reflected in this version of the text. The definitive version of the text was subsequently published in [*J Oral Maxillofac Surg.* 2013 Oct;71(10):1706-11. doi: 10.1016/j.joms.2013.04.020. Epub 2013 Jul 19.].

You may download, copy and otherwise use the AAM for non-commercial purposes provided that your license is limited by the following restrictions:

- (1) You may use this AAM for non-commercial purposes only under the terms of the CC-BY-NC-ND license.
- (2) The integrity of the work and identification of the author, copyright owner, and publisher must be preserved in any copy.
- (3) You must attribute this AAM in the following format: Creative Commons BY-NC-ND license (<http://creativecommons.org/licenses/by-nc-nd/4.0/deed.en>), [+ *Digital Object Identifier link to the published journal article on Elsevier's ScienceDirect® platform*]

Choristoma involving the floor of the mouth and the anterior tongue: a case of teratoid cyst with gastric and respiratory epithelium

^aMonica Pentenero DDS, MSci

^aRoberto Marino DDS

^bUbaldo Familiari MD

^aSergio Gandolfo MD, DDS

^aUniversity of Torino, Department of Oncology, Oral Medicine and Oral Oncology Unit,
Italy

^bPathology Division, AOU S. Luigi Gonzaga, Orbassano, Italy

Corresponding Author:

Dr. Monica Pentenero

Dipartimento di Oncologia

Regione Gonzole 10, 10043 Orbassano (TO) - ITALY

Telephone: +39-011-9026532; Fax: +39-011-9026984

e-mail: monica.pentenero@unito.it

INTRODUCTION

Dysontogenic cysts are malformations seldom observed in the oral cavity, accounting for less than 0.01% of all oral cysts. Among them teratoid cysts showing mesodermal elements are the most unusual presentation and may be lined by gastric, intestinal, respiratory, squamous, ciliated epithelium or even pancreatic structures. Teratoid cysts containing respiratory and gastrointestinal epithelium have typically been called choristomas (tumor-like mass of normal cells with an organized architecture in an abnormal location)[1]. This article presents a case of a choristoma involving both the floor of the mouth and the anterior tongue and characterized by the presence of squamous epithelium with skin adnexa, gastric and respiratory epithelium.

CASE REPORT

A 15-year-old Caucasian boy was referred to our clinic for a soft, painless, intra-oral swelling, slow-growing over the last 5 years. He just complained of progressive dysphagia and dysphonia without any pain. On examination a large painless, movable, soft, sublingual mass pushing up and backward the tongue was observed (Figure 1). The end of the Wharton's ducts were laterally and posteriorly displaced and the overlying mucosa had normal color and texture. There was no evidence of cervical lymphadenopathy. Lacking the characteristic double chin sign, the mass clinically appeared to be confined above the mylohyoid muscle. No medical history or family history of other congenital diseases that may form a mass in the head and neck region was reported.

Magnetic Resonance Imaging (MRI) showed a large smooth-walled, sharply defined, mass above the mylohyoid muscle of about 4.5 cm in diameter, without infiltration to the muscle or bone structures, thus occupying the floor of the mouth and the body of the tongue (Figure 2).

A fine needle aspiration biopsy (FNAB) revealed the presence of epithelial fragments, desquamated cells and cellular debris consistent with the diagnosis of a dysontogenic cyst.

Surgery was performed under general anesthesia with nasotracheal intubation via an intra-oral approach aiming to achieve a complete enucleation. A mucosal incision was made along the midline of the floor of the mouth, starting just behind the lingual fold, and extending along the ventral surface of the tongue as far as surgical needs and cyst dimensions demanded; to improve the access to the cyst a second incision

perpendicular to the first was performed taking care to preserve the Wharton's ducts (Fig 3). The mass overlying the genioglossus muscles was enucleated by blunt dissection of the cyst wall (Fig 4-5) and having obtained a proper hemostasis by bipolar diathermy, the wound was closed with 3x0 silk.

Histopathological examination revealed a cystic dilated lesion with a wall predominantly lined by keratinizing stratified squamous epithelium with dermal appendages (Fig 6) focally interspersed by respiratory (Fig 7) and gastric epithelium (Fig 8). The diagnosis of choristoma was made.

The postoperative course in healing was free of complications. The patient was followed up for 6 years without any sign of recurrence.

DISCUSSION

The floor of the mouth and the tongue may present masses resulting from defective embryonic development (dysontogenic and thyroglossal anomaly). On the basis of the anatomical subsite and relationships between the cyst and the muscles of the floor of the mouth, dysontogenic cysts can be defined as: median genioglossal, median geniohyoid, and lateral. In the literature, congenital cysts on the floor of the mouth are usually generally named as “dermoid” but from an histological point of view, they had been properly classified as epidermoid (lined by just squamous epithelium), true dermoid (when skin adnexa are found within the cyst wall) or teratoid (when also mesodermal elements such as bone, muscle, respiratory and gastrointestinal tissues, and a fibrous capsule are found)[2, 3]. Cysts located on the floor of the mouth account for 1.6% of all the “dermoid” cysts from the head and neck region[4], and among them teratoid cysts are the least common accounting for about 1.8%[5]. Nevertheless the floor of the mouth and the tongue represent the almost exclusive location of oral teratoid cysts as described in a report of 31 cases, where the floor of the mouth was the most frequent location (71% of cases) followed by the tongue (29% of cases)[6].

Among teratoids, cysts containing respiratory and gastrointestinal epithelium have typically been called choristomas[1]. Still the controversy about the nomenclature used for these cysts is evident from the various terms found in the literature (choristomatic cyst, foregut cyst, ciliated epithelial cyst, anterior median lingual cyst, lingual duplication cyst, cystic tumor of the tongue, unusual thyroglossal duct cyst, enterocystoma, alimentary tract cyst, heterotopic gastrointestinal cyst of the oral cavity), so that it has been suggested to nominate them considering the main type of epithelial lining[7, 8].

Oral cysts with gastrointestinal epithelium were first described in 1895[9] and in 1999 almost 40 additional cases had been reported[10]. Conversely cysts showing both gastrointestinal and respiratory other than squamous epithelium seem to be more uncommon with only 3 cases described till 1996[11] and no more than 11 additional cases reported in the following years[6, 12-14]. Such cysts have been hypothesised to arise from endodermal and mesodermal embryonic rests of the primitive foregut trapped within the developing tongue thanks to its close proximity to the developing branchial arches. The foregut leads to the development of the pharynx and respiratory tract from its ventral surface and to the development of esophagus, stomach, proximal part of duodenum, and hepatobiliary system from the dorsal one. This accounts for the gastric, intestinal, respiratory and/or squamous epithelial lining of such cysts.

Lingual choristomas are more frequently identified in the perinatal period[7, 15, 16] or during childhood[8] as causing respiratory or feeding problems, while true dermoid cysts are generally diagnosed in the second and third decades of life, without any sex correlation[17]. Therefore in the present case the quite late onset of symptoms was initially more suggestive for a dermoid cyst rather than a for a choristoma.

The finding of a mass involving the floor of the mouth and/or the tongue in infants or children requires a clinical and imaging assessment in order to differentiate "dermoid" cysts from other entities such as thyroglossal duct cyst, ranula, mucocele, cystic hygroma/lymphangioma, branchial cleft cysts, benign mesenchymal tumors, lymphoepithelial cyst, haemangioma and neurofibroma. An imaging assessment may be also useful to differentiate an intra/extra oral location of the mass and its relationship to the anatomic structures in order to correctly plan the surgical approach. Finally a

FNAB may be useful to confirm the suspect of “dermoid” cysts but it is not able to differentiate among epidermoid, true dermoid or teratoid cysts[18].

There are no controversies on the therapeutic approach of dysontogenic oral cysts, being a complete surgical removal the elective treatment without significant risks of recurrence. Conversely in the literature various surgical techniques with extraoral or transoral approach have been described depending on the size and the location of the mass[19].

Oral “dermoid” cysts are usually benign entities. The progression towards malignant transformation has been reported just in a couple of cases. Devine described the development of a squamous cell carcinoma within a sublingual dermoid cyst[20], while Agaimy reported an intestinal-type adenocarcinoma arising within a teratoid cyst predominantly lined by ciliated respiratory epithelium and gastric epithelium with intervening small islands of intestinal epithelium and non-keratinising squamous epithelium[21]. In both these patients the malignant transformation occurred in the adult-age. The patients had long been aware of the presence of a mass whose sudden and rapid enlargement was responsible for their referral to surgeon. Even if really rare, these two cases support the indication to the surgical removal and an accurate histological assessment of oral “dermoid” cysts.

REFERENCES

1. Batsakis JG, El-Naggar AK, Hicks MJ: Epithelial choristomas and teratomas of the tongue. *Annals of Otolary, Rhinology and Laryngology* 102:567, 1993
2. Teszler CB, El-Naaj IA, Emodi O, Luntz M, Peled M: Dermoid cysts of the lateral floor of the mouth: A comprehensive anatomo-surgical classification of cysts of the oral floor. *J Oral Maxillofac Surg* 65:327, 2007
3. Meyer I: Dermoid cysts (dermoids) of the floor of the mouth. *Oral Surgery, Oral Medicine, Oral Pathology* 8:1149, 1955
4. New GB, Erich JB: Dermoid cysts of the head and neck. *Surg Gynecol Obstet* 65:48, 1937
5. Bonilla JA, Szeremeta W, Yellon RF, Nazif MM: Teratoid cyst of the floor of the mouth. *Int J Pediatr Otorhinolaryngol* 38:71, 1996
6. Shen J, Chen XM, Wang SZ, Wang L, Xiong SC: [Clinicopathological and immunohistochemical study of oral teratoid cyst]. *Zhonghua kou qiang yi xue za zhi = Zhonghua kouqiang yixue zazhi = Chinese journal of stomatology* 40:62, 2005
7. Carlos-Bregni R, Vidaurre EC, Vargas PA, Lopes MA, León JE, Almeida OP: Lingual cyst with gastric epithelium: A clinicopathological and immunohistochemical analysis. *International Journal of Pediatric Otorhinolaryngology Extra* 4:36, 2009
8. Manor Y, Buchner A, Peleg M, Taicher S: Lingual cyst with respiratory epithelium: An entity of debatable histogenesis. *Journal of Oral and Maxillofacial Surgery* 57:124, 1999
9. Foderl O: Uber einen fall von congenitaler ranula glandulae nuhni. *Archiv fur Klinische Chirurgie* 49:530, 1895
10. Said-Al-Naief N, Fantasia JE, Sciubba JJ, Ruggiero S, Sachs S: Heterotopic oral gastrointestinal cyst. *Oral Surgery, Oral Medicine, Oral Pathology, Oral Radiology, and Endodontics* 88:80, 1999

11. Morgan WE, Jones JK, Flaitz CM, Hicks MJ: Congenital heterotopic gastrointestinal cyst of the oral cavity in a neonate: Case report and review of literature. *International Journal of Pediatric Otorhinolaryngology* 36:69, 1996
12. Ćorić M, Seiwerth S, Bumber Ž: Congenital oral gastrointestinal cyst: An immunohistochemical analysis. *European Archives of Oto-Rhino-Laryngology* 257:459, 2000
13. Mandell DL, Ranganathan S, Bluestone CD: Neonatal lingual choristoma with respiratory and gastric epithelium. *Archives of Otolaryngology - Head and Neck Surgery* 128:1321, 2002
14. Joshi R, Cobb AR, Wilson P, Bailey BM: Lingual cyst lined by respiratory and gastric epithelium in a neonate. *Br J Oral Maxillofac Surg* 51:173, 2013
15. Çelik M, Akkaya H, Arda IS, Hiçsönmez A: Congenital teratoma of the tongue: a case report and review of the literature. *Journal of Pediatric Surgery* 41:e25, 2006
16. Wiersma R, Hadley GP, Bosenberg AT, Chrystal V: Intralingual cysts of foregut origin. *Journal of Pediatric Surgery* 27:1404, 1992
17. Vogl TJ, Steger W, Ihrler S, Ferrera P, Grevers G: Cystic masses in the floor of the mouth: value of MR imaging in planning surgery. *AJR Am J Roentgenol* 161:183, 1993
18. Babuccu O, Isiksacan Ozen O, Hosnuter M, Kargi E, Babuccu B: The place of fine-needle aspiration in the preoperative diagnosis of the congenital sublingual teratoid cyst. *Diagn Cytopathol* 29:33, 2003
19. Longo F, Maremonti P, Mangone GM, De Maria G, Califano L: Midline (dermoid) cysts of the floor of the mouth: report of 16 cases and review of surgical techniques. *Plast Reconstr Surg* 112:1560, 2003
20. Devine JC, Jones DC: Carcinomatous transformation of a sublingual dermoid cyst. A case report. *Int J Oral Maxillofac Surg* 29:126, 2000
21. Agaimy A, Raab B, Bonkowsky V, Wunsch PH: Intestinal-type adenocarcinoma arising in a congenital sublingual teratoid cyst. *Virchows Arch* 450:479, 2007

CAPTIONS TO ILLUSTRATIONS

Figure 1: Clinical aspect of the sublingual mass pushing up and backward the tongue

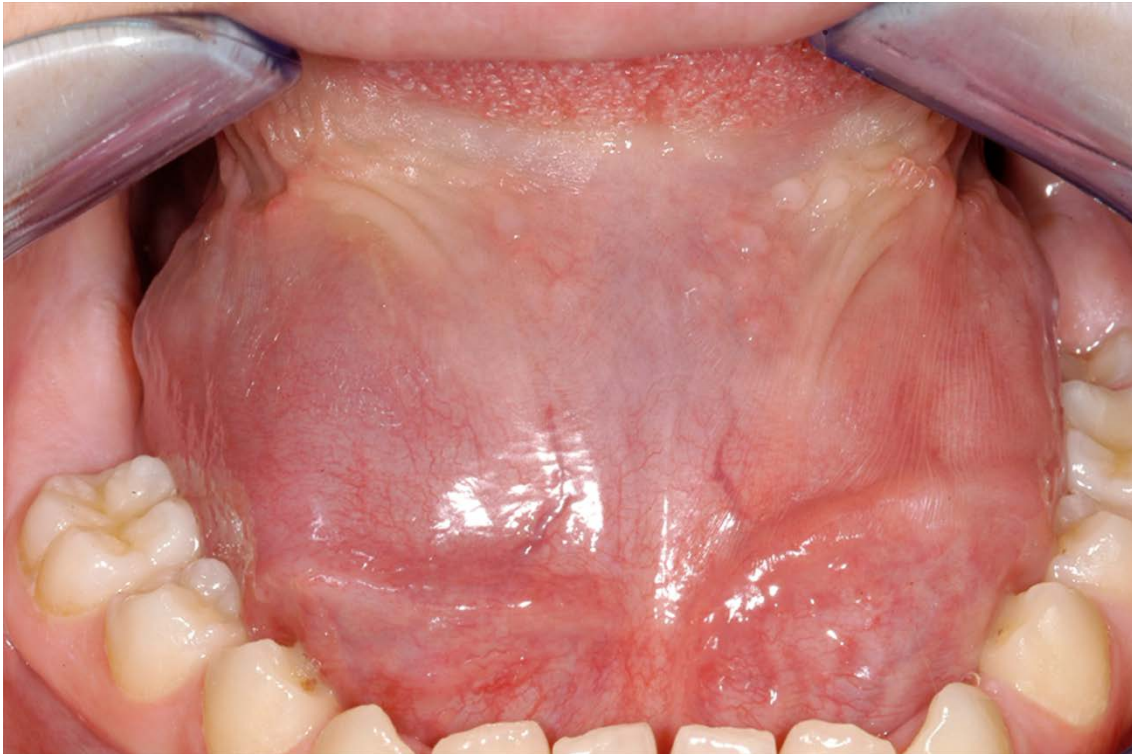

Figure 2: MRI scan showing a smooth-walled, sharply defined, mass with intra-oral location

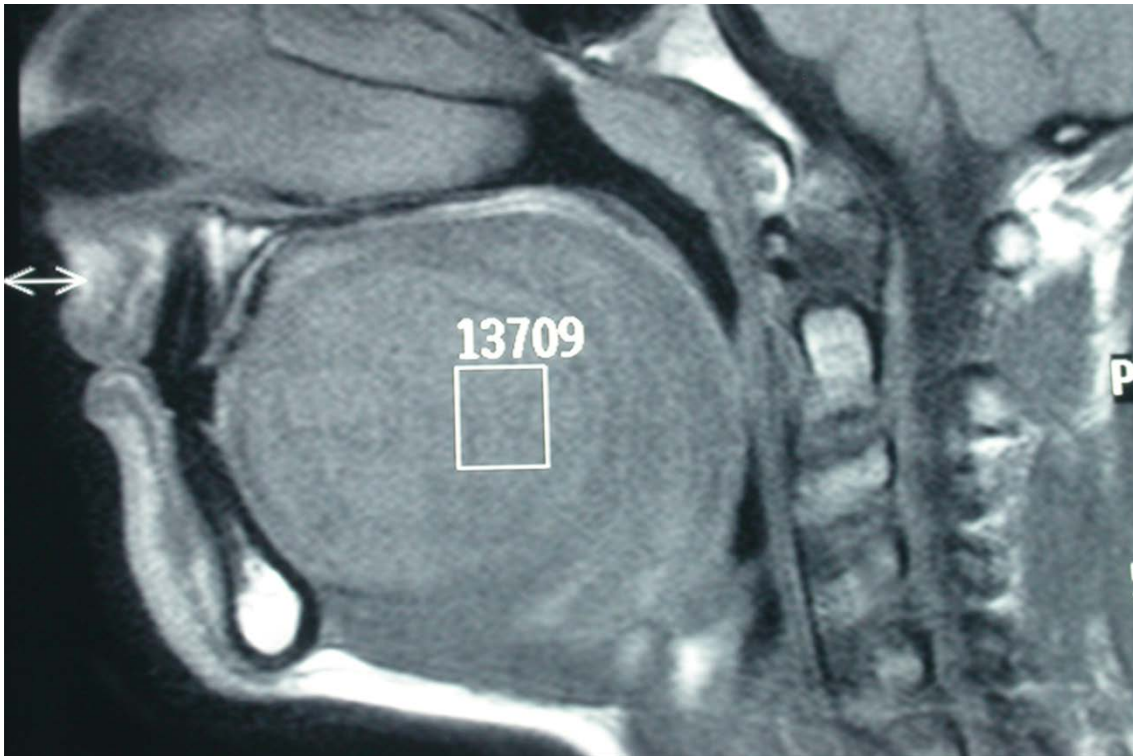


Figure 3: Mucosal incisions for the surgical approach

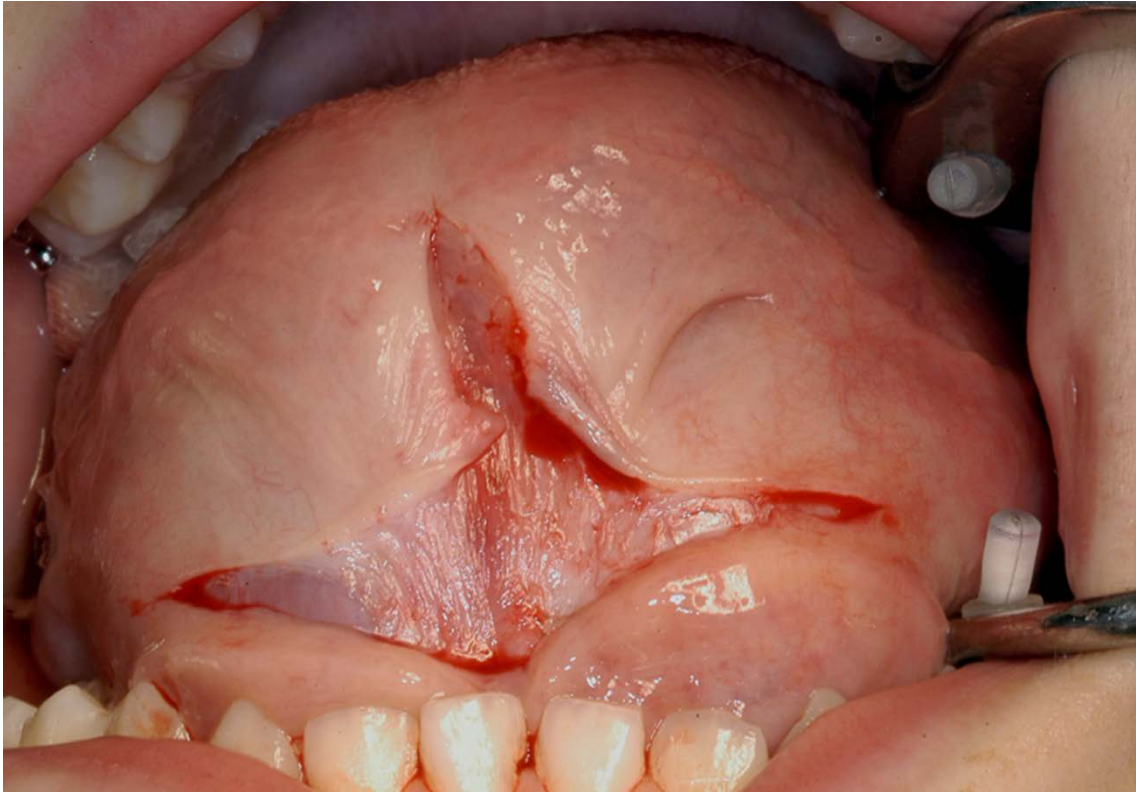


Figure 4: Blunt dissection of the mass

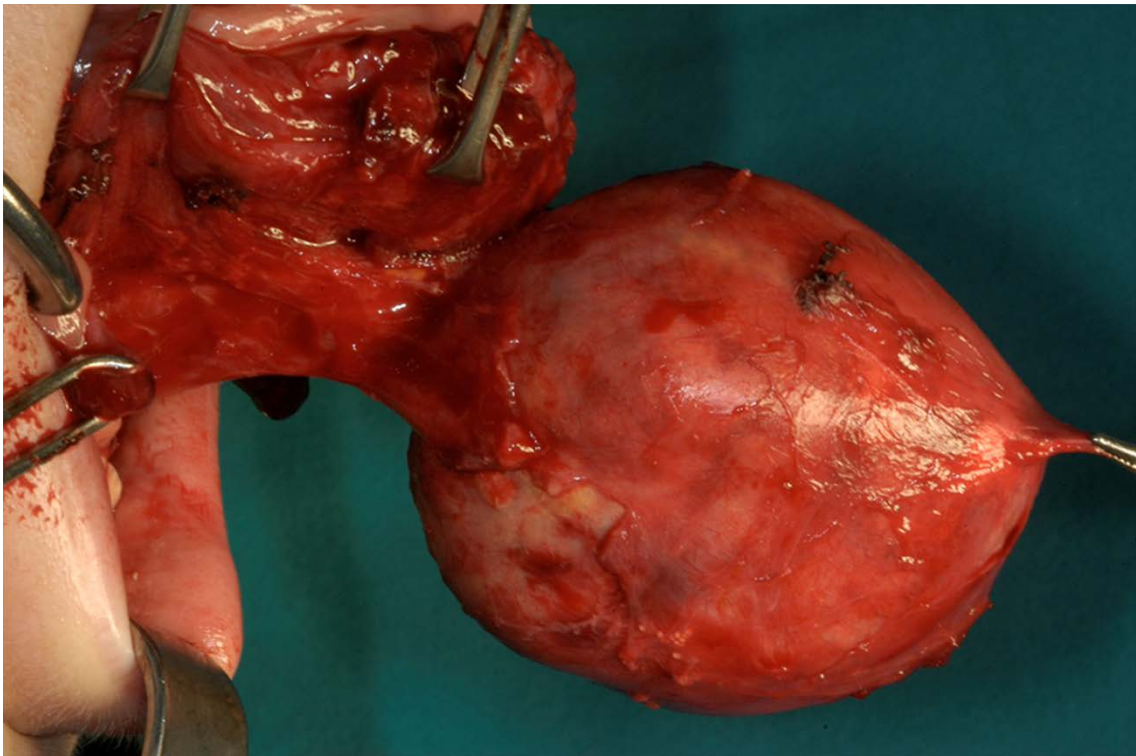


Figure 5: Excised sublingual mass

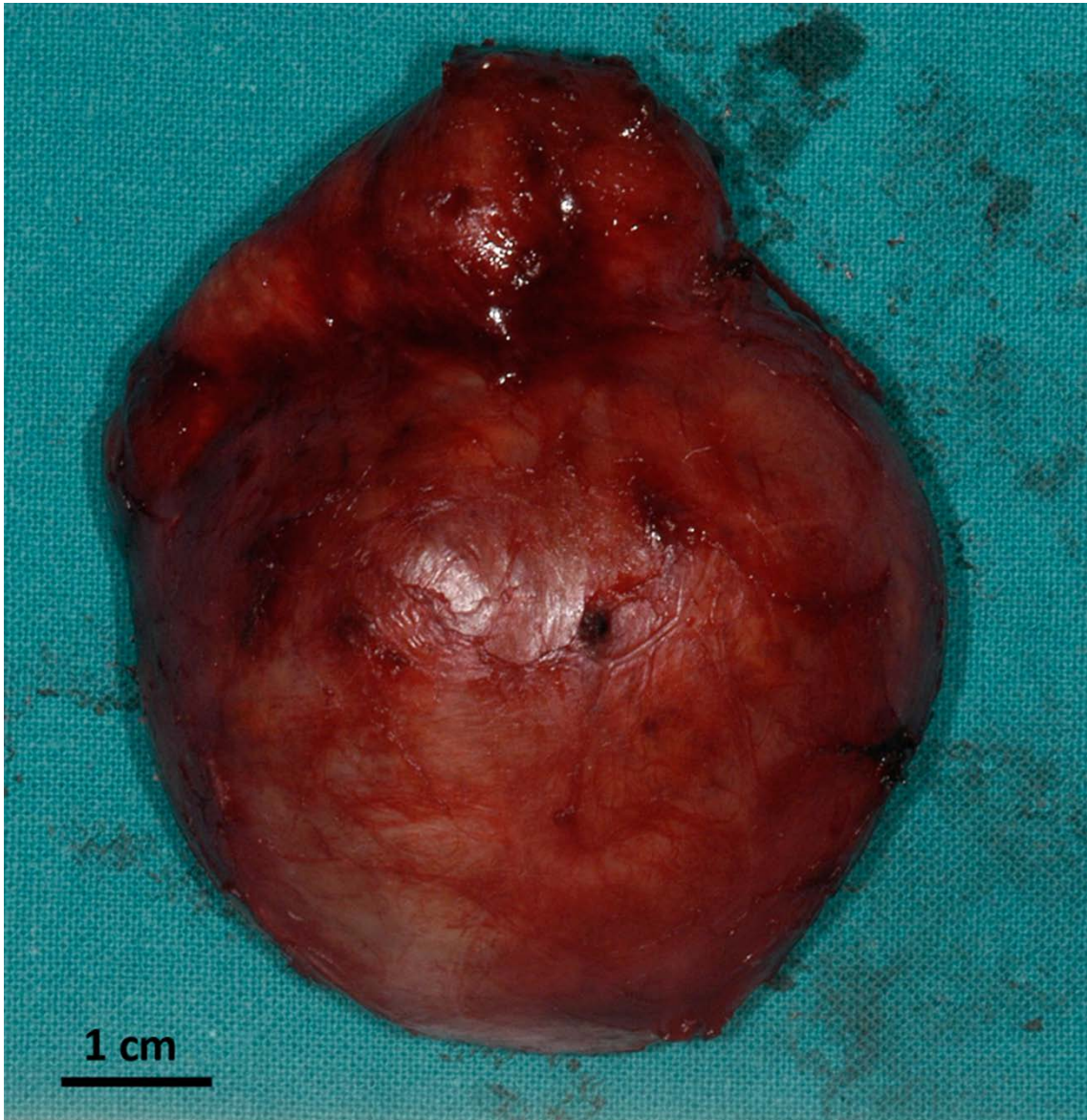


Figure 6: H&E specimen showing a cystic wall predominantly lined by keratinizing stratified squamous epithelium with skin adnexa (e.g. sebaceous glands) (10x)

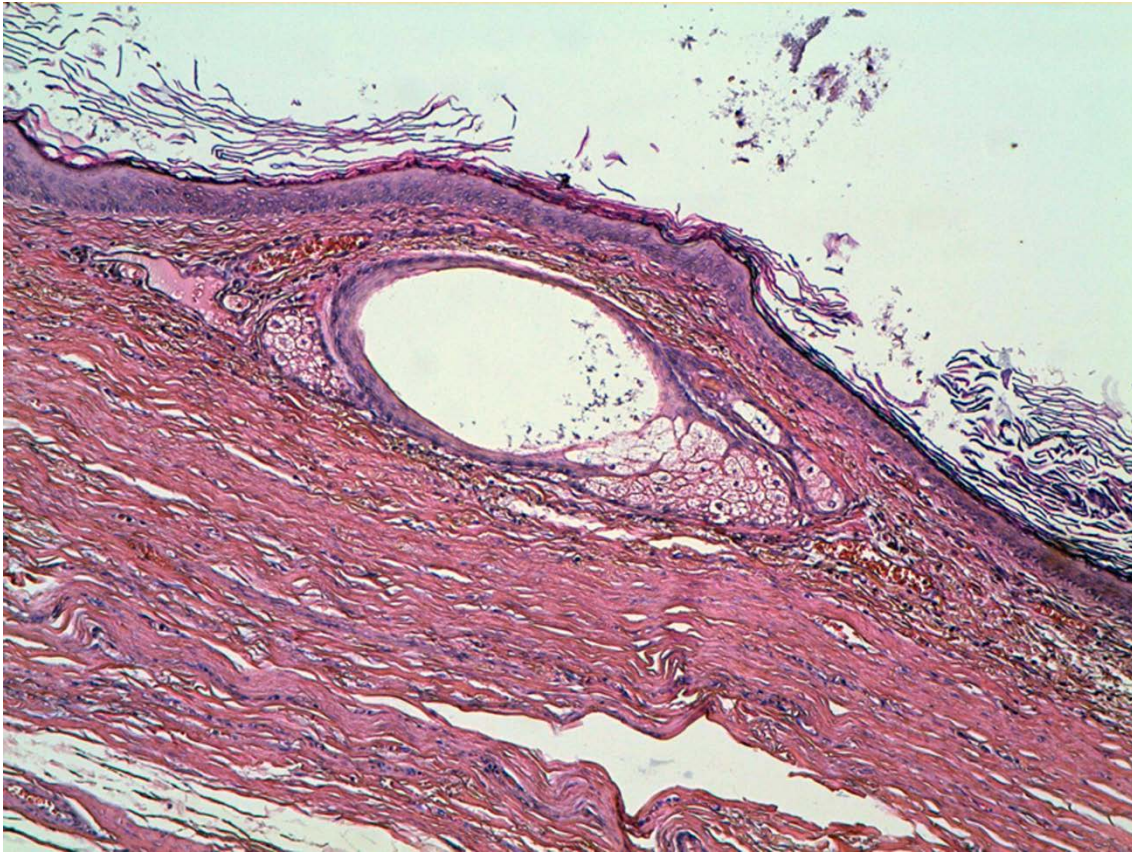


Figure 7: H&E specimen showing respiratory ciliated pseudo-stratified columnar epithelium with bronchial glands (20x)

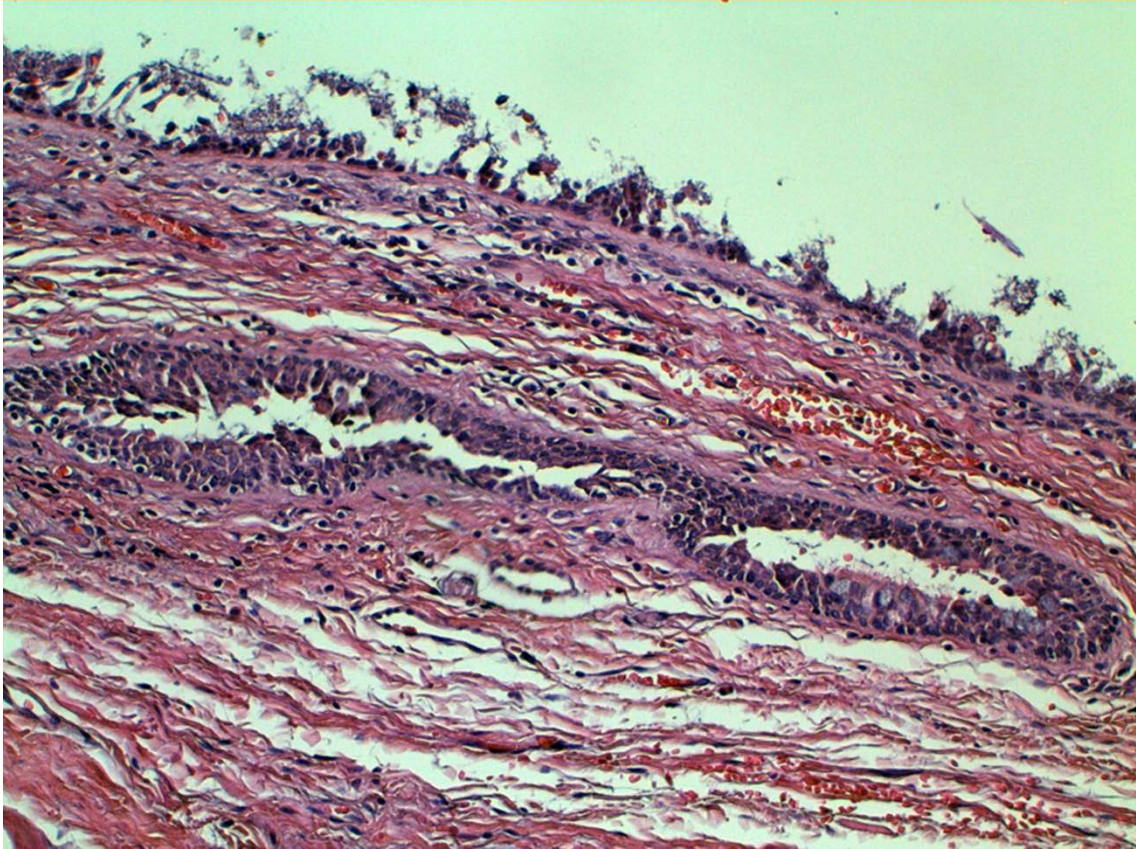


Figure 8: H&E specimen showing gastric epithelium with pyloric glands (20x)

