

Original Article

Dolichocarotids: Echo-Color Doppler Evaluation and Clinical Role

Marco Matteo Ciccone¹, Rakesh K. Sharma², Pietro Scicchitano¹, Francesca Cortese¹, Christian Salerno³, Paola Berchiolla⁴, Giulia Frasso¹, Marco Sassara¹, Mariangela Carbone¹, Pasquale Palmiero⁵, Maria Maiello⁵, Donald J. Voelker², Hanumanth K. Reddy² and Francesco Federico⁶

¹Cardiology Unit, Emergency and Organ Transplantation Department (DETO), University of Bari, Bari, Italy

²University of Arkansas for Medical Sciences, Cardiology Chair, Medical Center of South Arkansas, El Dorado, Arkansas, USA

³Dipartimento di Medicina Traslazionale-Laboratorio Igiene ed Medicina Ambientale, University of Piemonte Orientale "A.Avogadro", Novara, Italy

⁴Dept. of Clinical and Biological Sciences - University of Torino, Torino, Italy

⁵ASL Brindisi-Italy Department of Cardiology, Brindisi District, Italy

⁶Department of Neurology and Psychiatrics, University of Bari, Bari, Italy

Aims: Dolichocarotids (DCs) represent a rare (2-6%) carotid imaging finding in the general population that may be free of clinical significance or be associated with cerebrovascular events. Their detection is traditionally assigned to carotid echo-color Doppler (ECD) and selective angiography (the standard method). The primary aim of this study was to estimate the sensitivity, specificity and accuracy of ECD in detecting DCs. Moreover, we monitored the DC curvature angle and the incidence of TIA, ischemic stroke, myocardial infarction and cardiovascular death over a five-year follow-up period.

Methods: A total of 112 consecutive patients with DCs (80 men, mean age: 61 ± 7 years) were recruited for carotid ECD and carotid angiography due to the persistence of neurological symptoms not well explained on ultrasound evaluations, according to the current guidelines.

Results: ECD proved to have 100% sensitivity in detecting tortuosity and coiling and 96% sensitivity in detecting kinking, with an overall accuracy ranging from 92% to 100%. The specificity was 75% for tortuosity, 91% for kinking and 100% for coiling. During the five-year follow-up period, there was a statistically significant increase in tortuosity ($61 \pm 11^\circ$ at baseline versus $81 \pm 11^\circ$ after five years, $p < 0.001$) and the kinking curvature angle ($97 \pm 3^\circ$ at baseline versus $100 \pm 3^\circ$ at five years, $p < 0.001$), whilst no differences were observed with respect to coiling ($136 \pm 10^\circ$ at baseline versus $138 \pm 11^\circ$ at five years, $p = ns$). Moreover, kinking was found to be more frequently statistically associated with cardiovascular death than tortuosity ($p = 0.005$).

Conclusions: DCs predispose patients to potentially disabling and fatal events. ECD plays a primary role in the detection of DCs and therefore should be considered to be a secure and reproducible technique.

J Atheroscler Thromb, 2014; 21:56-63.

Key words: Dolichocarotids, Echo-color Doppler, Kinking, Coiling, Tortuosity

Introduction

Anatomical variations of the internal carotid artery

Address for correspondence: Marco Matteo Ciccone, Piazza G. Cesare 11 - 70124 Bari Italy

E-mail: marcomatteo.ciccone@uniba.it

Received: January 28, 2013

Accepted for publication: July 21, 2013

(ICA) (i.e., dolichocarotids (DCs)) represent a rare carotid imaging investigation finding, occurring in 2-6% of patients¹⁻³). Angiographic studies have identified three different types of these abnormalities, defined by Weibel and Fields as follows: "kinking, the most frequent morphological subtype, characterized by ICA angulation $< 90^\circ$; tortuosity, with an S- or C-shaped stretch and an angulation $> 90^\circ$; coiling, characterized by an elongated carotid tract forming

Curvature angle

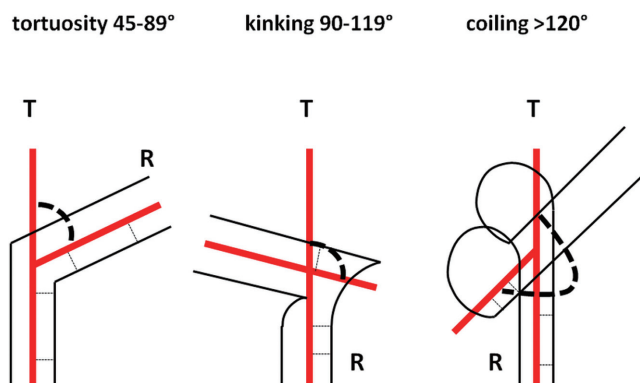


Fig. 1. Schematic representation of the curvature angle of the tree abnormalities measured with goniometry.

T = theoretic vessel direction; R = real vessel direction

one or more loops on their transverse axis⁴⁻⁷).

Patients with such variations may be asymptomatic or can develop cerebrovascular symptoms, including: hemiparesis or hemiplegia, with or without sensory deficits; monocular visual alterations; frontal headaches; homonymous field defects, language defects, syncope, confusion and memory loss⁸).

The detection of these carotid abnormalities is based principally on two specific diagnostic imaging techniques: echo-color Doppler (ECD) and contrast angiography.

In the literature, the correlation between DCs and ischemic cerebral events is based on the findings of retro-perspective studies not evaluating the incidence of the latter⁹⁻¹¹). Nevertheless, some studies have denied the association between these carotid abnormalities and cerebrovascular events, and the literature debate is still open on the exact clinical role DCs¹²).

Moreover, although ECD is a noninvasive and inexpensive technique for carotid artery detection, selective angiography remains the gold standard for assessing such arterial districts¹³).

The study aims were to test the sensitivity, specificity and accuracy of carotid-color Doppler in detecting dolichocarotids and to evaluate the five-year incidence of cerebro-cardiovascular disease, transient ischemic attack (TIA), ischemic stroke, myocardial infarction (MI) and cardiovascular death in patients with DCs.

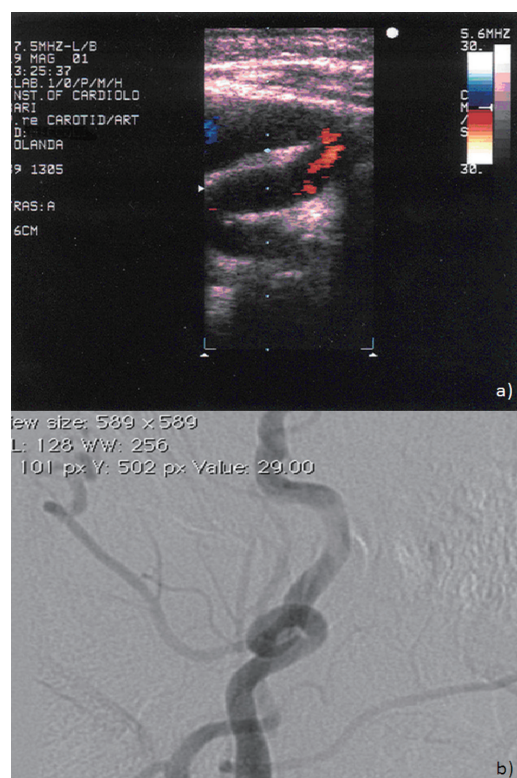

Fig. 2. Internal carotid artery coiling: a) ultrasound and b) angiographic view.

Methods

Study Design

From April 2005 to May 2007, 2,397 consecutive patients admitted to the Outpatient Vascular Section, Department of Cardiology of Bari University General Hospital were investigated. All patients underwent ultrasound evaluations of the carotid vessels due to mild neurological symptoms or syncope or in order to complete their own cardiovascular risk profile (i.e., hypertension, dyslipidemia, etc.). A total of 233 patients received an ultrasonographic diagnosis of DC according to the Weibel and Fields criteria⁷). ECD examinations of 73 patients outlined clear atherosclerosis signs at the carotid level, i.e. plaques causing vascular stenosis (>30% detected on high-definition ECD); we excluded such patients in order to have a sample with clean carotid arteries. A total of 48 patients had no indications for further angiographic assessments and were excluded from our protocol. Furthermore, patients with major comorbidities (cancer, major cardiovascular diseases and other pathologies) were excluded in order to avoid the loss of patients during follow-up. Only 112 Caucasian sub-

Table 1. Cardiovascular risk factors in the study population in relation to each carotid abnormality. Fisher's exact test was used to compare the variables

	Total <i>n</i> =112	Tortuosity <i>n</i> =60	Kinking <i>n</i> =41	Coiling <i>n</i> =11
Age (years)	61 ± 7 y	62 ± 6 y	60 ± 8 y	55 ± 8 y
Males	80	44	29	7
Hypertension (K/C vs T)	107 (95%)	56 (95%)	40 (98%)	11 (100%)
(C vs K)			<i>p</i> =0.65	<i>p</i> =1.00
Dyslipidemia (K/C vs T)	95 (85%)	49 (78%)	37 (90%)	9 (82%)
(C vs K)			<i>p</i> =0.27	<i>p</i> =1.00
Diabetes (K/C vs T)	36 (32%)	22 (37%)	12 (30%)	2 (18%)
(C vs K)			<i>p</i> =0.52	<i>p</i> =0.31
Cigarette (>10/day) (K/C vs T)	51 (45%)	24 (40%)	21 (52%)	6 (28%)
(C vs K)			<i>p</i> =0.31	<i>p</i> =0.51
				<i>p</i> =1.00

Mean value ± SD or number (percentage) of patients K: kinking; C: coiling; T: tortuosity.

jects (80 men, mean age: 61 ± 7 years) were ultimately included in the study and underwent carotid angiography evaluations due to the persistence of neurological symptoms not well explained on ultrasound evaluations, according to the current guidelines¹⁴.

The patients finally enrolled in the study underwent carotid ultrasound and carotid selective angiography, and, at the end of the study, we calculated the dolichocarotid curvature angle.

The curvature angle is defined as the angle between the theoretical median vascular axis and the actual vascular axis obtained by drawing a line through two points in the middle of the vessel and then calculating the radius (expressed in mm) respectively on the predolichocarotid vascular segment and the postdolichocarotid vascular segment. According to these measurements, we defined tortuosity as an angle of 45° to 89°, kinking as an angle of 90° to 120° and coiling as an angle of >121° (**Fig. 1** and **2**).

The results obtained from carotid angiography and ultrasound were compared in order to evaluate the sensitivity, specificity and accuracy of echo-color Doppler.

The patients were monitored throughout the five-year follow-up period to detect changes in the degree of the carotid artery curvature angle and the occurrence of cardiovascular and cerebrovascular events, TIA and ischemic stroke and underwent complete neurological examinations twice a year by a neurologist in order to establish the presence of clinical signs or symptoms secondary to ischemic stroke. A

complete electrocardiogram, blood pressure measurements and assessments of the fasting levels of glucose and plasma lipids were performed two times yearly. We registered no loss of patients during the follow-up period. The general characteristics of the study population are shown in **Table 1**.

Study Population

Among a total of 112 patients analyzed (80 men, mean age: 61 ± 7 years), the carotid echo-color Doppler evaluation detected tortuosity of the ICA in 60 subjects (44 men, mean age: 62 ± 6), kinking in 41 subjects (29 men, mean age: 60 ± 8) and coiling in 11 subjects (seven men, mean age: 55 ± 8). At the first observation, the DC curvature angle in each population group was 61° ± 11° for tortuosity, 97° ± 3° for kinking and 136° ± 10° for coiling. At the end of the five-year follow-up period, we recorded the following values of the carotid curvature angle: 81° ± 11° for tortuosity; 100° ± 3° for kinking; and 138° ± 11° for coiling (**Table 2**).

The distribution of cardiovascular risk factors in our study population (**Table 1**) was as follows: a total of 107 (95%) patients were hypertensive (i.e., a systolic blood pressure [SBP] of >140 mmHg and/or a diastolic blood pressure [DBP] of >90 mmHg or the use of antihypertensive drugs), including 56 (95%) patients with tortuosity, 40 (98%) patients with kinking and 11 (100%) patients with coiling; 95 (85%) patients were hypercholesterolemic (a total cholesterol level of >220 mg/dL or the use of lipid-lowering

Table 2. The curvature angle at baseline and after five years of follow-up

	Baseline	5 years	Average difference	<i>p</i> value
Tortuosity <i>n</i> = 60	61° ± 11°	81° ± 11°	20° ± 9°	< 0.001
Kinking <i>n</i> = 41	97° ± 3°	100° ± 3°	3° ± 1°	< 0.001
Coiling <i>n</i> = 11	136° ± 10°	138° ± 11°	2° ± 3°	NS

Mean ± standard deviation.

drug(s) according to the NCEP ATP III), including 49 (78%) patients with tortuosity, 37 (90%) patients with kinking and nine (82%) patients with coiling; 36 (32%) patients had diabetes [defined as a fasting blood sugar level of > 126 mg/dL on at least two measurements or a blood sugar level during a 75-g oral glucose tolerance test of > 200 mg/dL or the use of antidiabetic drug(s), including 22 (37%) patients with tortuosity, 12 (30%) patients with kinking and two (18%) patients with coiling; and 51 (45%) patients were smokers (10 cigarettes/day for at least three months), including 24 (40%) patients with tortuosity, 21 (52%) patients with kinking and six (28%) patients with coiling¹⁵⁻¹⁷).

We used Fisher's exact test to compare each cardiovascular risk factor with each carotid condition (Table 1). The choice of the statistical evaluation was related to the small sample considered; for each carotid configuration, the number of patients suffering with the cardiovascular risk factor analyzed was too small in each group to perform a multiple regression analysis. In addition, the samples were homogeneous in terms of the distribution of the cardiovascular risk factors, as the test underlined. In fact, the statistical data showed no differences between groups or among the various configurations of the carotid morphology visualized in our examinations.

The study was approved by the ethics committee of Bari University General Hospital and carried out in accordance with the principles of the Helsinki Declaration. All patients provided their informed consent before entering the study.

Carotid Ultrasound Evaluations

All patients underwent complete ultrasound carotid evaluations using the same carotid-color Doppler ultrasonographer (Hewlett Packard Sonos 1000, Andover, MA, USA). To ensure the blindness of the

Table 3. Carotid ultrasound Vs angiography

	Tortuosity	Kinking	Coiling
Sensitivity	100%	96%	100%
Specificity	75%	91%	100%
Accuracy	92%	95%	100%
False negatives	0%	4%	0%
False positives	15%	9%	0%

The numbers are expressed as percentages.

study, the ultrasonographic evaluations were performed by the same operator, who was unaware of the clinical conditions of the patients.

Patients with a short muscular neck, high carotid bifurcation, calcified shadowing plaques, tracheostomy tubes, surgical sutures, postoperative hematomas or bandages, central lines or an inability to lie supine due to respiratory or cardiac disease or to rotate the head due to arthritic disease and those who were not cooperative were excluded from the ultrasound evaluations. The subjects were examined in the supine position with their neck extended and rotated by 45 degrees to the contralateral side. A goniometer was positioned around the neck. Bilateral carotid ultrasound was performed with a high-resolution 7.5-MHz linear array scan head. The common and internal carotid arteries were scanned longitudinally to calculate the "curvature angle" of the vessel that corresponded to the point of maximum angulation of the ICA. The DC images were frozen, printed and recorded using the Sony U-Matic Professional System (Sony Corporation, Japan). The probe position on the goniometer placed around the neck was recorded and calculated.

We reevaluated 30 patients in order to assess the intraobserver variability, which was 0.94, according to the intraclass correlation coefficient (classified as good if over 0.80¹⁸).

Carotid Selective Angiography

The angiographic examinations were conducted by the same experienced operator, who was unaware of the ECD data of each patient. We preferred to access the femoral artery in order to more easily perform cannulation of the common carotid artery. In cases of occlusion of the femoral artery or failure of cannulation, we accessed the brachial artery using a 7-French guiding catheter. Following the administration of local anesthesia with xylocaine, we proceeded with arterial puncture. Selective catheterization of both common carotid arteries was then performed. All investigations were conducted on a conventional X-ray

Table 4. Incidence of major vascular events

	Total <i>n</i> = 112	Tortuosity <i>n</i> = 60	Kinking <i>n</i> = 41	Coiling <i>n</i> = 11
TIA	27 (24%)	14 (23%)	11 (27%)	2 (18%)
Ischemic stroke	16 (14%)	8 (13%)	7 (17%)	1 (9%)
MI	25 (22%)	12 (20%)	9 (22%)	4 (36%)
CV Death	17 (15%)	4 (7%)	11 (27%)*	2 (18%)

Number (percentage); * $p=0.005$ vs tortuosity.

angiography system (Polytron, Siemens). The carotid images were obtained on both sides in at least three planes (using 6 mL of contrast agent, flow: 3 mL/s), recorded on CD-R and printed.

Statistical Analysis

The results are presented as the mean \pm standard deviation or number and percentage of patients. Continuous variables were compared using the paired *t*-test and frequencies were compared using the chi-square test. The sensitivity, specificity and accuracy in detecting tortuosity, kinking and coiling were calculated. Fisher's exact test was used to compare variables. A Cox regression model was fitted to determine the impact of ECD morphology on adverse outcomes, adjusting for the age of the patient at diagnosis. The proportional hazards assumption was verified according to the log minus log method and by examining the Schoenfeld residuals. The results are reported with hazard ratios (HRs) and 95% confidence intervals (CIs). *P* values of <0.05 were considered to be statistically significant.

Results

Comparing carotid ultrasound measurements with the findings of carotid angiograms, we confirmed the sensitivity, specificity and accuracy of ECD in detecting dolichocarotids. Our analysis showed a 100% sensitivity rate in detecting tortuosity and coiling and a 96% sensitivity rate in detecting kinking, with an overall accuracy ranging from 92% to 100% (Table 3). The specificity of the ultrasound technique ranged from 75% for tortuosity, to 91% for kinking, to 100% for coiling (Table 3).

Over the five-year follow-up period we found a statistically significant increase in the curvature angle of carotid arteries suffering from tortuosity ($61 \pm 11^\circ$ at baseline versus $81 \pm 11^\circ$ after five years, $p < 0.001$) and/or kinking ($97 \pm 3^\circ$ at baseline versus $100 \pm 3^\circ$ at five years, $p < 0.001$), whilst no differences were observed in the coiling group ($136 \pm 10^\circ$ at baseline

versus $138 \pm 11^\circ$ at five years, $p = \text{ns}$ (Table 2).

During the five-year follow-up period, 27 (24%) patients suffered from TIA, while 16 (14%) patients had ischemic strokes. All TIA and ischemic stroke events were contralateral to the detected dolichocarotid site. No patients had multiple abnormalities of the ICA. Furthermore, 25 (22%) patients underwent MI and 17 (15%) patients died due to cardiovascular events. No statistically significant differences were observed in the incidence of TIA, ischemic stroke and MI between the three groups (Table 4). Only cardiovascular death demonstrated a higher incidence in the patients with kinking than in those with tortuosity ($p = 0.005$).

A Cox regression model was fitted to determine the impact of ECD morphology on adverse outcomes, adjusting for the age of the patients at diagnosis. The analysis showed that patients with a kinking morphology had a risk of cardiovascular events two-fold higher (HR: 2.08, $p = 0.002$) than that of the patients with tortuosity (Fig. 3). Furthermore, after analyzing each specific cardiovascular event, we found that a kinking morphology was associated with a six-fold increase in the risk of cardiovascular death (HR: 6.06, $p = 0.025$). No significant differences were observed between the different morphologies with respect to the risk of myocardial infarction, stroke or TIA.

Discussion

Our study aimed to establish the sensitivity, specificity and accuracy of carotid-ECD in detecting dolichocarotids, a disease that is often misunderstood as a rare condition associated with occasional ECD evaluation of the carotid arteries. In this study, the use of a five-year follow-up period allowed us to monitor such patients in order to detect the overall incidence of cerebro-cardiovascular diseases (TIA, ischemic stroke, MI and cardiovascular death).

DCs remain a little known disease associated with several pathologic conditions, and their clinical role is not well established. An excessive length of the

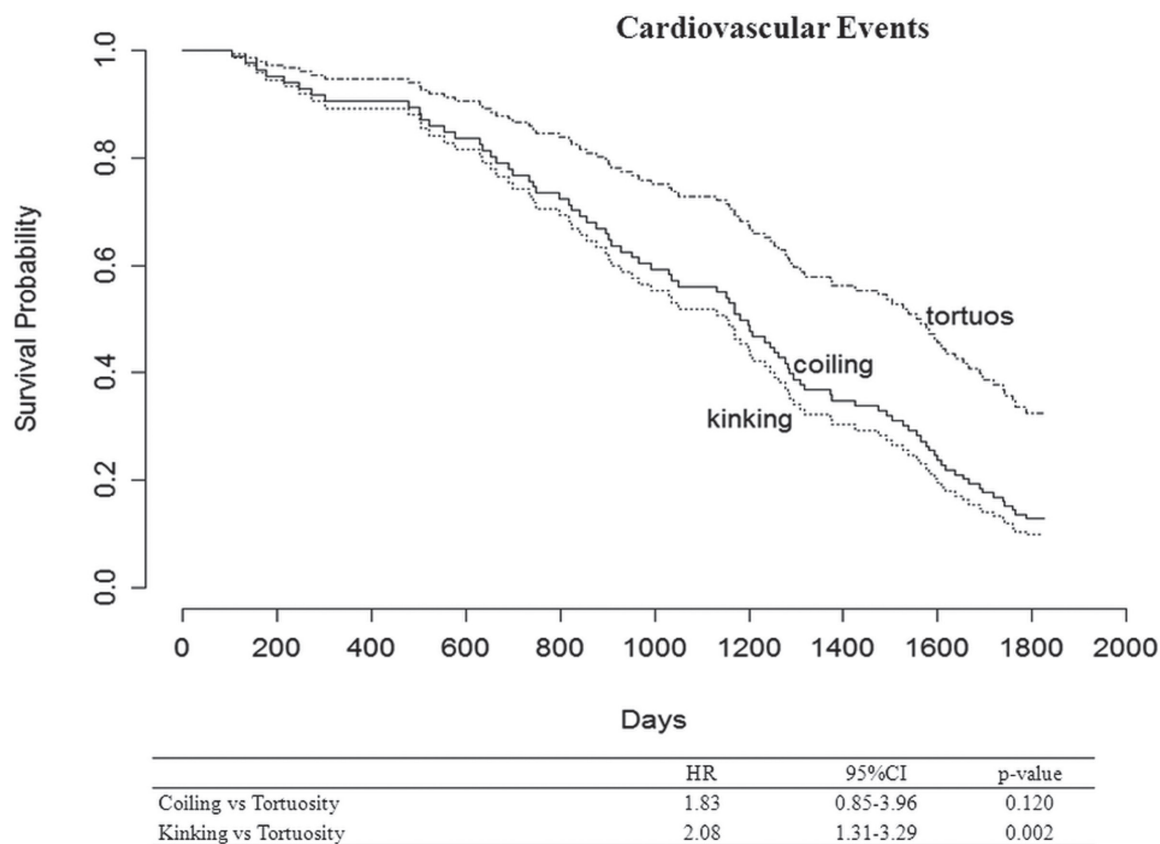


Fig. 3. Survival curves for cardiovascular events adjusted for age at diagnosis.

ICA may be the result of an embryonic development failure with anomalous absorption of the third aortic arch or the upper intersegmental artery with subsequent curving, kinking, tortuosity and looping of the ICA^{11, 19}. More frequently, this disease is linked to vascular structure weakening due to hereditary defects or destruction of the internal elastic layer, such as that due to fibromuscular dysplasia, aging or chronic diseases, such as atherosclerosis and hypertension^{9, 10, 20, 21}.

These carotid abnormalities are related to cerebro-vascular symptoms, although their role in the development of cerebro-vascular events remains controversial.

Mukherjee and Inahar suggested a possible relationship between kinking and hypertension or TIA, while other authors believe atheromatous plaques to be fundamental elements involved in the onset of ischemic stroke in patients suffering from carotid kinking^{3, 5, 21}. Other studies have argued that DCs predispose patients to plaque formation^{12, 22}. Nevertheless, the relationship between DCs and cardiovascular risk factors, as well as cerebral and cardiac ischemic disease, remains controversial, and these abnormalities

have been defined as a curiosity rather than a clinically significant finding¹².

Our study results showed that only tortuosity and kinking may progressively increase with respect to the curvature angle, while that observed in coiling remains stable. Furthermore, comparing the five-year follow-up data for cardiovascular death between patients with kinking and tortuosity, we found a statistically significant increase in this end point in the patients suffering from kinking ($p=0.005$). This finding suggests that these conditions predispose patients to potentially disabling and fatal events. Furthermore, we performed a Cox regression analysis to obtain Kaplan-Meier survival curves. The aim was to evaluate the impact of each ICA anatomical variant on the patient outcomes. Surprisingly, we found a two-fold increase in the rate of cardiovascular events in the patients suffering from kinking compared to that observed in the patients with tortuosity (HR: 2.08, $p=0.002$, **Fig. 3**). Nevertheless, kinking is associated with a greater increase in cardiovascular death than is tortuosity. In fact, we found a six-fold increase in this outcome in patients suffering from kinking compared

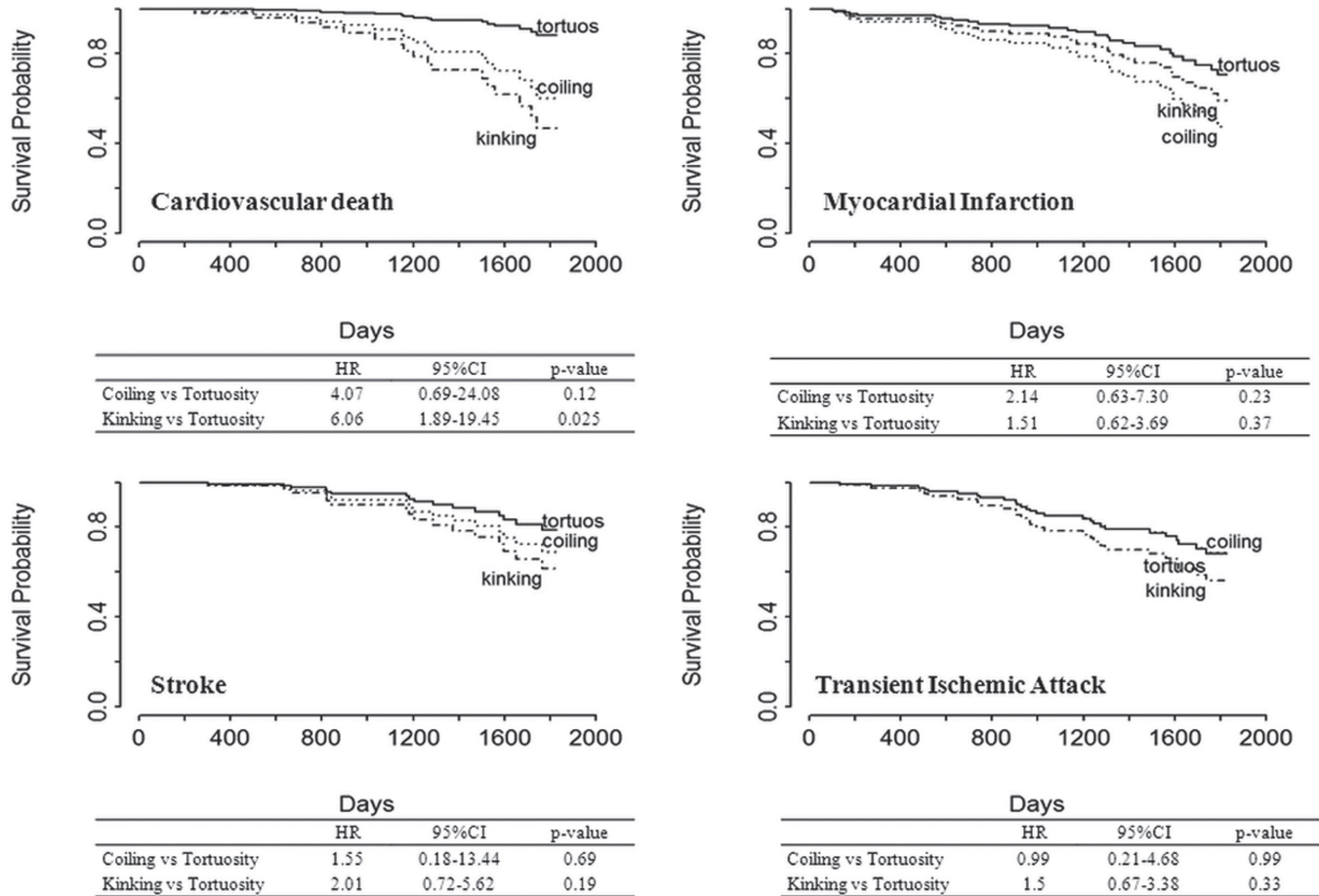


Fig. 4. Survival curves for cardiovascular death (top left), myocardial infarction (top right), stroke (bottom left) and transient ischemic attack (bottom right).

to that observed in those suffering from tortuosity (HR: 6.06, $p=0.025$, **Fig. 4**). Therefore, kinking conditions appear to be much more frequently related to adverse outcomes than tortuosity.

Furthermore, our study confirms the leading role of ECD in the noninvasive evaluation of the carotid arteries. This modality is an inexpensive and noninvasive method comparable to carotid angiography with respect to sensitivity, specificity and accuracy in diagnosing these conditions, providing useful information regarding the morphological configuration and hemodynamic status of the carotid arteries. In particular, our study showed that ultrasound is comparable to angiography in terms of evaluating coiling, with a sensitivity, specificity and accuracy of 100%, and lower accuracy in assessing other carotid abnormalities, as shown in **Table 4**. Nevertheless, even when detecting kinking and tortuosity, the use of ECD should be considered, despite its limitations, considering the invasiveness of angiography, the risks associated with

the use of intravenous contrast and the possibility for procedure-related complications²³.

Limitations

One limitation associated with our study is related to the angiographic evaluations. In fact, we measured the angles using only ultrasonography. Angiography was used only to confirm the diagnosis of the ultrasonographic data in order to not use quantitative methods of evaluation. Therefore, scatterplots and Bland-Altman plots were not created.

Disclosures and Conflicts of Interest

None to declare.

References

- 1) Van Damme H, Gillain D, Désiron Q, Detry O, Albert

- A, Limet R: Kinking of the internal carotid artery: clinical significance and surgical management. *Acta Chir Belg*, 1996; 96: 15-22
- 2) Poulidas GE, Skoutas B, Doundoulakis N, Haddad H, Karkanas G, Lyberiadis D: Kinking and coiling of internal carotid artery with and without associated stenosis. Surgical considerations and long-term follow-up. *Panminerva Med*, 1996; 38: 22-27
 - 3) Koskas F, Bahnini A, Walden R, Kieffer E: Stenotic coiling and kinking of the internal carotid artery. *Ann Vasc Surg*, 1993; 7: 530-540
 - 4) Schechter DC: Dolichocarotid Syndrome. *New York State Journal of Medicine*, 1979; 79: 1391-1397
 - 5) Mukherjee D, Inahar T: Management of the Tortuous Internal Carotid Artery. *Am J Surg*, 1985; 149: 651-655
 - 6) Vannix RS, Joergenson EJ, Carter R: Kinking of the Internal Carotid Artery. *Am J Surg*, 1977; 134: 82-89
 - 7) Weibel JW, Fields WS: Tortuosity, coiling and Kinking of the internal carotid artery. Etiology and radiographic anatomy. *Neurology*, 1965; 15: 7-18
 - 8) Desai B, Toole JF: Kinks, coils, and carotids: a review. *Stroke*, 1975; 6: 649-653
 - 9) Pokrovskii AV, Beloiartsev DF, Timina IE, Adyrkhaev ZA: Clinical manifestations and diagnosis of pathological deformity of the internal carotid artery. *Angiol Sosud Khir*, 2011; 17: 7-18
 - 10) Coyle KA, Smith RB 3rd, Chapman RL, Salam AA, Dodson TF, Lumsden AB, Chaikof EL: Carotid artery shortening: A safe adjunct to carotid endarterectomy. *J Vasc Surg*, 1995; 22: 257-261
 - 11) Lochridge SK, Rossi NP: Symptomatic kinked internal carotid artery. *J Cardiovas Surg*, 1980; 21: 108-111
 - 12) Togay-Işıkay C, Kim J, Betterman K, Andrews C, Meads D, Tesh P, Tegeler C, Oztuna D: Carotid artery tortuosity, kinking, coiling: stroke risk factor, marker, or curiosity? *Acta Neurol Belg*, 2005; 105: 68-72
 - 13) Nederkoorn PJ, van der Graaf Y, Hunink MG: Duplex ultrasound and magnetic resonance angiography compared with digital subtraction angiography in carotid artery stenosis: a systematic review. *Stroke*, 2003; 34: 1324-1332
 - 14) Brott TG, Halperin JL, Abbara S, Bacharach JM, Barr JD, Bush RL, Cates CU, Creager MA, Fowler SB, Friday G, Hertzberg VS, McIff EB, Moore WS, Panagos PD, Riles TS, Rosenwasser RH, Taylor AJ; American College of Cardiology Foundation/American Heart Association Task Force on Practice Guidelines; American Stroke Association; American Association of Neuroscience Nurses; American Association of Neurological Surgeons; American College of Radiology; American Society of Neuroradiology; Congress of Neurological Surgeons; Society of Atherosclerosis Imaging and Prevention; Society for Cardiovascular Angiography and Interventions; Society of Interventional Radiology; Society of NeuroInterventional Surgery; Society for Vascular Medicine; Society for Vascular Surgery; 2011 ASA/ACCF/AHA/AANN/AANS/ACR/ASNR/CNS/SAIP/SCAI/SIR/SNIS/SVM/SVS guideline on the management of patients with extracranial carotid and vertebral artery disease: executive summary: a report of the American College of Cardiology Foundation/American Heart Association Task Force on Practice Guidelines, and the American Stroke Association, American Association of Neuroscience Nurses, American Association of Neurological Surgeons, American College of Radiology, American Society of Neuroradiology, Congress of Neurological Surgeons, Society of Atherosclerosis Imaging and Prevention, Society for Cardiovascular Angiography and Interventions, Society of Interventional Radiology, Society of NeuroInterventional Surgery, Society for Vascular Medicine, and Society for Vascular Surgery. *Vasc Med*, 2011; 16: 35-77
 - 15) Mancía G, De Backer G, Dominiczak A, Cifkova R, Fagard R, Germano G, Grassi G, Heagerty AM, Kjeldsen SE, Laurent S, Narkiewicz K, Ruilope L, Rynkiewicz A, Schmieder RE, Boudier HA, Zanchetti A; ESH-ESC Task Force on the Management of Arterial Hypertension: 2007 ESH-ESC Practice Guidelines for the Management of Arterial Hypertension: ESH-ESC Task Force on the Management of Arterial Hypertension. *J Hypertens*, 2007; 25: 1751-1762
 - 16) National Cholesterol Education Program (NCEP) Expert Panel on Detection, Evaluation, and Treatment of High Blood Cholesterol in Adults (Adult Treatment Panel III). Third Report of the National Cholesterol Education Program (NCEP) Expert Panel on Detection, Evaluation, and Treatment of High Blood Cholesterol in Adults (Adult Treatment Panel III) final report. *Circulation*, 2002; 106: 3143-3421
 - 17) American Diabetes Association. Diagnosis and classification of diabetes mellitus. *Diabetes Care*, 2010; 33: S62-69
 - 18) Fleiss JL. The design and analysis of clinical experiments. New York, NY: Wiley, 1986, pp.5-12
 - 19) Ovchinnikov NA, Rao RT, Rao SR: Unilateral congenital elongation of the cervical part of the internal carotid artery with kinking and looping: two case reports and review of the literature. *Head Face Med*, 2007; 3: 29
 - 20) Quattlebaum Jr JK, Wade JS, Whiddon CM: Stroke Associated with Elongation and Kinking of the Carotid Artery: Long-Term Follow-Up. *Ann Surg*, 1973; 177: 572-579
 - 21) Del Corso L, Moruzzo D, Conte B, Agelli M, Romanelli AM, Pastine F, Protti M, Pentimone F, Baggiani G: Tortuosity, kinking, and coiling of the carotid artery: expression of atherosclerosis or aging? *Angiology*, 1998; 49: 361-371
 - 22) Pellegrino L, Prencipe G: Dolichoarteriopathies (kinking, coiling, tortuosity) of carotid arteries and atherosclerotic disease: an ultrasonographic study. *Cardiologia*, 1998; 43: 959-966
 - 23) Tang TY, U-King-Im JM, Walsh SR, Young VE, Sadat U, Li ZY, Patterson AJ, Varty K, Gillard JH: Invasive and non-invasive modalities of imaging carotid stenosis. *J Cardiovasc Surg*, 2009; 50: 715-725