

AperTO - Archivio Istituzionale Open Access dell'Università di Torino

Clinicopathologic spectrum of cutaneous diseases in patients with hematologic malignancies with or without allogeneic bone marrow transplantation: an observational cohort study in 101 patients.

This is the author's manuscript

Original Citation:

Availability:

This version is available <http://hdl.handle.net/2318/142763> since

Terms of use:

Open Access

Anyone can freely access the full text of works made available as "Open Access". Works made available under a Creative Commons license can be used according to the terms and conditions of said license. Use of all other works requires consent of the right holder (author or publisher) if not exempted from copyright protection by the applicable law.

(Article begins on next page)



UNIVERSITÀ DEGLI STUDI DI TORINO

This is an author version of the contribution published on:

Quaglino P, Nardo T, Fierro MT, Massaia M, Orsucci L, Fava P, Marengo F,
Marra E, Savoia P, Vitolo U, Boccadoro M, Bernengo M.

Clinicopathologic spectrum of cutaneous diseases in patients with
hematologic malignancies with or without allogeneic bone marrow
transplantation: an observational cohort study in 101 patients.

GIORNALE ITALIANO DI DERMATOLOGIA E VENEREOLOGIA
(2013) 148

The definitive version is available at:

<http://www.minervamedica.it/it/riviste/dermatologia-venereologia/articolo.php?cod=R23Y2013N05A0453>

Clinicopathologic spectrum of cutaneous diseases in patients with hematologic malignancies with or without allogeneic bone marrow transplantation: an observational cohort study in 101 patients

P. QUAGLINO 1, T. NARDÒ 1, M. T. FIERRO 1, M. MASSAIA 2, L. ORSUCCI 3, P. FAVA 1 F. MARENCO 1, E. MARRA 1, P. SAVOIA 1, U. VITOLO 3, M. BOCCADORO 2, M. G. BERNENGO 1

1Department of Medical Sciences Dermatologic Division, University of Turin, Turin, Italy

2Hematologic Department University of Turin, Turin, Italy

3Hematologic Division San Giovanni Battista Hospital, Turin, Italy

Abstract

Aim. Objective of the study was to determine the most common cutaneous lesions in patients with haematologic malignancies observed at dermatologic consultation and to identify the impact parameters related to the haematologic condition, like disease type/duration, remission, chemotherapy and transplantation, have on skin manifestations.

Methods. A total of 101 consecutive patients with onco-haematological malignancies referred for dermatological consultation over a two-year period were included in this prospective single-centre observational cohort study.

Results. The most common finding was infection (19.8%), followed by drug adverse reactions (16.8%) and malignant neoplasia (11.9%). Elderly patients and those with a longer disease duration had a higher frequency of cutaneous neoplasia. Squamous cell carcinoma was the most frequent cutaneous neoplasia; three cases of melanoma were diagnosed and had a high Breslow thickness. Cutaneous involvement due to the haematological malignancies was observed in 5 patients. Common chronic dermatoses (psoriasis and eczema) were found in 10% of patients. Transplant had no effect on the percentage of infections or tumours.

Conclusion. Patients with haematological malignancies have a higher incidence of adverse drug reactions with peculiar morphologic features and a lower incidence of common chronic dermatoses than patients referred for dermatological consultation by their general practitioner or other hospital services. Infectious dermatoses were less frequent than in solid organ transplanted patients. The complex variety of cutaneous lesions, the differential diagnostic pitfalls and the prognostic relevance of early skin tumour diagnosis, evidence the importance of a correct dermatological approach.

Key words: Skin diseases - Drug toxicity - Hematologic neoplasms- Bone marrow transplantation.

Onco-hematological patients have a severely impaired immune homeostasis, which may be attributed to the disease itself, chemotherapy, graft-versus-host-disease (GvHD) and its treatment. Consequently, they present frequent and potentially severe infectious complications, that are a primary cause of mortality, particularly after allogeneic haematopoietic stem cell transplantation (HSCT). Moreover, long term survival HSCT patients have an increased risk of developing cancers, especially virus-related.¹

The skin is one of the major target organs for both infectious complications and cancer development. A recent study on more than 2000 transplant recipients reported the occurrence of skin diseases in 45% of patients.² The cumulative incidence of cutaneous tumours increases along with the time from transplantation; a series of papers, predominantly on kidney transplant recipients, showed a cumulative incidence up to 25% with a significant increase paralleling the post-transplant period.³⁻⁷ Cutaneous involvement is also a constant feature of acute and chronic GvHD, one of the major complications after HSCT and is responsible for a decrease in the quality of life and an increase in morbidity and mortality.^{8, 9}

Approximately 40-60% of patients develop GvHD after an allogeneic transplantation and almost all of them have cutaneous lesions.

The challenging differential diagnosis of cutaneous lesions in these patients emphasises the need for a correct dermatological approach. A prospective observational trial reported that dermatological manifestations had a significant impact on haematology practice: 45% of inpatients received topical or systemic skin treatment, 5% had a treatment delay; 11% of patients required extra nursing and 3% prolonged their hospitalization due to dermatological lesions.¹⁰ Moreover, a recent prospective multicenter study demonstrated a lack of agreement in 56.3% of cases between diagnosis suggested by “non-specialists” and dermatologists, showing that common dermatological diseases are often not recognized or misdiagnosed by non-dermatologists.¹¹

In spite of this evidence, to the best of our knowledge, there is no specific literature aimed at the analysis of the spectrum of cutaneous diseases in patients with haematologic malignancies. On the other hand, similar studies have been conducted in solid organ transplant recipients.¹²⁻¹⁶ These data prompted us to perform a prospective observational cohort study on patients with haematologic malignancies referred to our department for a dermatologic consultation, with the aim of determining the spectrum of skin lesions. Our secondary objective was to assess whether the cutaneous manifestations were affected by various parameters related to the hematologic condition, e.g., type of disease, disease duration, remission, chemotherapy and/or bone marrow transplantation.

Materials and methods

Patients

This prospective observational study analyses the clinical records of all the consecutive patients referred for a dermatologic consultation on an out-patient or in-patient basis from the Haematological Departments of our hospital. After having obtained written informed consent, 101 patients were included over a two year period (Table I). Leukemia was the most frequent haematological disease (N.=47: 13 acute myeloid, 6 acute lymphoblastic, 6 chronic myeloid and 20 chronic lymphocytic), 31 patients had non-Hodgkin lymphoma (NHL), 14 multiple myeloma and 9 Hodgkin lymphoma. Sixty-eight of the patients (67.3%) had received previous treatment but were not on chemotherapy at the time of the visit; whilst chemotherapy was ongoing in the remaining 33 patients and 10 of these had three cell lineage bone marrow aplasia. Allogeneic HSCT had been performed in 29 patients (2 with multiple myeloma, 2 Hodgkin's lymphoma, 7 NHL and 18 with leukaemia), 26 of whom had had myelo-ablative HSCT. Their conditioning regimens included different combinations of chemotherapeutic drugs (cyclophosphamide, busulfan, thio-tepa, elphalan, fludarabine) with or without antithymocyte globulin and/or total body irradiation. Non-myeloablative HSCT had been performed in 3/29 patients with reduced intensity conditioning regimen. GvHD prophylaxis following full intensity conditioning regimens included a combination of a calcineurin inhibitor (cyclosporine, tacrolimus) and short course methotrexate.

Overall, 48 patients were in haematological remission after chemotherapy with or without HSCT at the time of the visit. All patients were visited by the same dermatologists (PQ, TN, PS). Any history of previous dermatological diseases and/or skin cancers was investigated. Skin biopsy was required for diagnostic purposes in 32 cases; immuno-histochemistry was used to assess cutaneous involvement due to haematological malignancy.

Statistical analyses

Haematologic disease duration was defined as the time from the date of first diagnosis to the date of first dermatological visit. Non parametric tests were applied to evaluate the distribution of variables and the differences in the distribution of variables were determined by the Fisher's exact test and the Mann-Whitney U test.

Results

Cutaneous diseases

The distribution of dermatological disorders as diagnosed in the total cohort is shown in Figure 1. The most frequent disease was infections, observed in 20 cases (19.8%), followed by adverse drug reactions (17 cases, 16.8%). Twenty-three patients had been referred for a suspicion of skin malignancy, where clinical

and histological examination confirmed malignant tumour in 12 (11.9%), the other 11/23 had a benign neoplasia. A diagnosis of GvHD was made in 9 patients: four had acute GvHD with confluent erythematous edematous lesions and occasional bullae formation (Figure 2A, B), five had chronic GvHD with a lichenoid or sclerodermiform pattern (Figure 2C). Another 5/101 patients (4.9%) presented with papulo-nodular and/or nodular lesions and, on the basis of the clinical and histopathological features, a diagnosis of cutaneous involvement due to leukaemia was made in 2 cases, due to NHL in 2 and in 1 it was due to multiple myeloma (Figure 2 D-F). Common chronic dermatoses were diagnosed in a total of 11 patients, eczema in 5 (4.9%) and psoriasis, which was present at the time of first haematological diagnosis, in 6 (5.9%). The psoriasis worsened in 2/6 patients in association with the development of acute lymphoblastic and acute myeloid leukemia respectively, followed by a marked improvement after complete haematological remission. Two of the 5 patients with eczema had localized allergic contact dermatitis and 3/5 were suffering from a longstanding chronic eczema which had not been modified by the haematologic malignancy. Another 5/101 patients showed immune-mediated dermatoses, i.e., lichenoid dermatitis in 2, 1 had epidermolysis bullosa acquisita, 1 erythema nodosum and 1 cutaneous sarcoidosis; two of these patients were on immunosuppressive drugs after HSCT. Less frequent dermatological diseases included: prurigo (4 cases) and pityriasis rosea (3); another patient, who was affected by acute myeloid leukemia, had disseminated insect bite-like reactions¹⁷.

Infectious diseases

Infections accounted for 19.8% of cases (20 patients).

The most frequent causative agents were viruses (10 cases: 2 herpes simplex and one was disseminated; 3 herpes zoster and one was disseminated; 2 molluscum contagiosum and 3 viral warts) (Figure 3A, B), followed by bacteria (6 cases, folliculitis and impetigo). Fungal infections were observed in 4 patients and 3/4 had tinea corporis, intertrigo and pityriasis versicolor respectively; the latter had disseminated papulo-nodular lesions with a central necrotic and ulcerated area associated to sepsis by *Fusarium* spp., a filamentous fungus which constitutes one of the emerging causes of opportunistic mycoses.

No association was found between the infectious complications and the haematological malignancy, chemotherapy administration, aplasia or haematological remission. Similarly, there was no significant difference in the percentage of cutaneous infections diagnosed in allogeneic HSCT patients compared to the others (24.1% vs. 18.1%).

Adverse drug reactions

Adverse drug reactions occurred in 16.8% of cases (17 patients). The commonly involved causative agents were antibiotics e.g. penicillins, levofloxacin and sulfamethoxazole, ibuprofen, allopurinol and mucolytic agents. Three patients developed a drug reaction to lenalidomide, used for the treatment of multiple myeloma. The most frequent clinical picture was an exanthematic maculo-papular eruption and the presence of chemotherapy-associated thrombocytopenia determined the development of papulo-purpuric vasculitis-like lesions in the lower limbs in 4 patients. Three patients developed flexural erythema involving the inguinal, axillary and elbow folds, due to allopurinol, vancomycin and aracycline, respectively. Other manifestations were related to specific drugs. One patient treated with rituximab developed an urticarial eruption around the cutaneous NHL lesions (Figure 3C). One patient showed gingival hypertrophy after cyclosporin. Two further patients developed flagellate dermatitis, asymptomatic linear pigmented lesions on the trunk and shoulders after bleomycin administration (Figure 3D); one of these patients also presented a nail pigmentation with radial stream.

Drug adverse reactions were significantly more frequent in multiple myeloma (35.7%) than in other haematologic malignancies (13.8%; $P=0.05$), in patients with ongoing chemotherapy (42.4%) compared to those with previous chemotherapy (4.4%; $P<0.001$), in patients who did not achieve haematological remission (24.5%) when compared to those who did (8.3%; $P=0.03$) and in patients in aplasia (40%) vs those with a normal blood cell count (19.8%) (borderline significance: $P=0.06$).

Cutaneous malignancies

A cutaneous neoplasia was diagnosed in 12 patients (11.9%). The most frequent cutaneous neoplasia was squamous cell carcinoma (6 cases), with one case localized in the oral mucosa. One of these patients

developed a regional node involvement during follow-up. Multiple actinic keratosis, mainly localized in the photo-exposed areas, were observed in 3 of these patients. Malignant melanoma was diagnosed in another 3, with a Breslow thickness of 2 mm, 3.5 mm and 8.8 mm respectively (Figure 3E, F); one patient had regional cervical node metastases at diagnosis. Two NHL patients in remission after chemotherapy developed mycosis fungoides, an indolent primary cutaneous T-cell lymphoma, with disseminated patches. Another patient, with Hodgkin lymphoma, developed a diffuse cutaneous Kaposi sarcoma concomitant with a late relapse of her hematological disease.

Cutaneous neoplasia were most frequently observed in elderly patients (median age: 70.5 years) (Mann-Whitney test: $P=0.0044$ when compared to patients without neoplasia) and in patients with a longer disease duration (median 6.5 years) ($P=0.02$) (Figure 4A, B). Patients who had been given hematopoietic stem cell transplantation showed no higher risk of cutaneous neoplasia than those who had not (6.9% vs. 13.9%).

Selected case-reports

A total of 3/101 patients had rare dermatologic diseases that were specifically associated to their hematologic malignancies. A female patient with multiple myeloma showed long-standing firm, yellowish or red-orange plaques and nodules with teleangiectasies and violaceous borders, that although disseminated, had an unusual sparing of the periorbital area. The histologic picture revealed a band-like pattern of necrobiotic granulomatous inflammation, atypical giant cells, cholesterol clefts and plasma cells, characteristic of necrobiotic xanthogranuloma 18 (Figure 2G). This entity is a rare non-X histiocytosis commonly associated with monoclonal gammopathies and multiple myeloma; the skin lesions develop as a reactive granulomatous inflammatory process, not associated with the presence of monoclonal plasma cells. A second patient, with chronic lymphocytic leukaemia on rituximab, presented with erythematous edematous plaques with a central blistering, localized on the lower limb; the histological picture showed a marked cutaneous eosinophilia, fibrinoid "flame figures" and palisading granuloma, diagnostic for Wells' syndrome, classified into the spectrum of eosinophilic cutaneous disorders 19 (Figure 2H). A third patient was a 41-year old female who, 1 year after allogeneic HSCT for acute myeloblastic leukaemia, developed disseminated small keratotic papules with a raised, ridge-like border and a thin central furrow and minimal scaling. The histologic picture showed the typical cornoid lamella characteristic of disseminated Mibelli porokeratosis, a rare disorder of keratinisation usually seen in the clinical setting of immunosuppression 20 (Figure 2I).

Discussion

This prospective clinical study aimed at determining the spectrum of cutaneous diseases in onco-haematologic patients referred for dermatological consultation and to ascertain whether different haematologic malignancies and/or factors related to the haematologic conditions have an impact on skin manifestations. Although similar studies have been carried out in solid organ transplant recipients,¹²⁻¹⁴ to the best of our knowledge, no data are available in onco-haematologic patients with or without HSCT.

Our study showed that infections, adverse drug reactions and neoplasia are the three most common cutaneous diseases found in onco-haematological patients sent for dermatological consultation, which, when summed up, account for almost 50% of our cases. On the other hand only 9% of our patients were referred for cutaneous GVHD, a frequent manifestation in transplanted patients. This unexpected low percentage implies that GVHD diagnosis is managed in the majority of cases by the haematologist, leaving dermatologic consultation only for the more challenging cases. Significant differences in the spectrum of dermatological diseases can be observed between onco-haematological patients and outpatient dermatological consultations from the general practitioner or other hospital medical services, the former being characterised by a higher incidence of adverse drug reactions with peculiar morphologic features and a lower relevance of common chronic dermatoses (eczema and psoriasis). Conversely, the percentage of infectious dermatoses was unexpectedly similar between the two groups and significantly lower than the figures reported for solid organ transplant patients.

The distribution of infections, adverse drug reactions and neoplasia was analysed vis-à-vis with the haematological conditions. HSCT patients did not show any significant increase in infections or neoplasia,

suggesting that the immune homeostasis is already deeply impaired by multi-drug chemotherapies. Only 3 patients in our series underwent non myeloablative HSCT: therefore, the potential reduction in neoplasia or infectious complications could not be evaluated. Multiple myeloma patients had a higher frequency of adverse drug reactions. The drugs most frequently involved as causative agents were the same as in the general population i.e. antibiotics, ibuprofen, allopurinol and mucolytic agents; the reaction was aroused by lenalidomide in 3 patients, which had been used for the treatment of myeloma^{21,22}. The significant increase of adverse drug reactions in patients with ongoing chemotherapy is related to the higher number of drugs taken by these patients. This may well also accounts for the development of adverse drug reactions in patients with aplasia, even if it is hardly understandable how such immune-suppressed patients with markedly reduced white blood cell counts could develop an allergic or immune-mediated reaction. Adverse drug reactions in onco-haematological patients may have peculiar morphologic features, including flexural erythema, urticarial eruptions around the cutaneous NHL lesions (rituximab), flagellate dermatitis (bleomycin) and nail pigmentation. Flexural erythema, where the term systemic drug-related intertriginous and flexural exanthema has recently been proposed, has also been reported in literature in healthy people. Indeed, it is considered to derive from an interplay between a delayed-type immune reaction and local factors such as friction, local skin temperature and eccrine gland distribution, which might explain the characteristic skin location of this eruption.²³ Apart from infections, adverse drug reactions and neoplasia, the remaining 50% of the patients included in this study had a variety of cutaneous manifestations, including skin involvement by the haematologic disorder, e.g., such as leukemia cutis, GvHD, psoriasis, eczema, lichenoid dermatitis, epidermolysis bullosa acquisita, erythema nodosum, cutaneous sarcoidosis, prurigo and pruritus, pityriasis rosea, necrobiotic xanthogranuloma, Wells' syndrome, Mibelli porokeratosis and insect bite-like reactions. As to psoriasis, it is interesting to observe that the development of the haematologic malignancy gave rise to a significant worsening of the cutaneous manifestation, which improved after chemotherapy and haematologic remission. This finding emphasizes the strong influence haematologic diseases have on skin patho-physiology. In fact, the release of pro-inflammatory cytokines and soluble mediators induced by the haematologic neoplasia might well constitute the molecular trigger for the worsening of psoriasis which may then go on to improve with haematologic remission.

The spectrum of dermatological diseases in oncohaematological patients differs from what is observed in outpatient dermatological consultations referred from the general practitioner or other hospital medical services. In a series from the south east of Scotland, 24.2% of visits were for adverse drug reactions, whilst 23.4% were for psoriasis and eczema. Eczema alone accounted for 22.5% of general practitioner consultations with a dermatological basis in another report.²⁵ In a recent prospective cohort study carried out by the Dermatology Department of a Spanish hospital, all inpatient consultations performed over a 1 year period were analysed. Inflammatory dermatosis was the most common diagnosis (35.8%, 160/429 patients), followed by infectious dermatosis (25.7%), while adverse drug reactions accounted for 8.7% of all visits.²⁶ Another series from a Portuguese hospital, showed skin infections (33.2%), eczemas (9.5%) and drug eruptions (7.3%) to be the most common diagnoses²⁷. Only a few patients in our onco-haematologic patients had a diagnosis of psoriasis or eczema (5.9% and 4.9%, respectively); this could be due to the fact that treatment for haematologic malignancies and the prevention of GvHD, e.g., steroids, cyclosporine, can induce remission of eczema and psoriasis in a significant percentage of cases. In patients coming from other medical services for dermatological consultation, drug eruptions were reported to vary between 4.2%²⁸ and 14%,^{26, 29} whilst our series had 16.8%. Indeed, in a recent retrospective study on more than 4000 inpatient dermatologic visits performed for different referral services, the most common diagnosis in patients from the Medical Haematology department was drug eruption, which accounted for 12.2% of visits.³⁰ However, noteworthy is the fact that the percentage of cutaneous neoplasia and infectious derreactions matoses in onco-haematologic patients was similar to that reported in literature for both inpatient and outpatient dermatologic consultations. Conversely, higher values can be expected on the basis of the immunosuppression which characterizes these patients. In fact, the percentage of visits for cutaneous malignant neoplasia in general outpatient referrals was similar (11.6%)²⁴ when compared to our series (11.9%). This finding is not in contrast with the well-proven higher risk of tumours in transplant recipients, where most of these patients undergo regular dermatological consultations, which, on the other hand, are carried out only in a minority of the general population. Thus, in spite of a similar percentage of cutaneous neoplasia observed in the dermatological visits, the true incidence of skin tumours in immune-

suppressed and transplant patients is exceedingly high. As to infectious dermatoses, Fisher et al.³¹ reported 24.4% of outpatient cases, Itin et al. 21.7%,³² in line with our findings. In other studies, the percentage of infectious diseases was either lower (11% in a French report),³³ or higher (29.8% in an Indian Hospital).³⁴ These differences may, in part, be attributed not only to the services analysed (surgery wards have a high incidence of infectious complications), but also to the geographic area and the patients' social conditions. In spite of a similar percentage, infectious dermatoses in onco-haematological patients are more severe and disseminated than are immune-competent outpatient cases.

Moreover, a small percentage of patients in our series (<10%) underwent dermatological evaluation for the onset of cutaneous lesions related to chemotherapy or the underlying onco-haematological disease, such as petechiae, ecchymosis and purpura. These conditions, also known as non specific "leukemids", are a frequent finding in these patients and need to be differentiated with care from the "specific" lesions due to skin involvement by the underlying hematologic disease.³⁵

The distribution of cutaneous diseases in onco-hematological patients was also compared to what has been reported for solid organ transplant recipients. A series of studies have reported that renal transplant recipients run a high risk of developing cutaneous infections. The largest series reported includes 801 organ transplant recipients with dermatological manifestations, where 46% of cases showed cutaneous infections.⁶ In an Italian series of 109 kidney transplant patients,³⁶ 40% of patients with dermatological manifestations had cutaneous infections. Other papers reported higher percentages, between 55% and 66%.³⁷⁻³⁹

In a recent study performed by our group on 282 kidney transplant patients, 99 patients (35.1%) developed cutaneous tumours after transplantation, whilst infectious diseases were observed in 16.7% of cases.⁴⁰ Cutaneous infections appear even more frequent in liver⁴¹ and heart⁴² transplant patients, with percentages as high as 70% of cases. As in our series, viruses and fungi were the most common etiological agents in all these series.⁴³ The heavier immunosuppressive load of longer duration in solid organ transplant patients probably accounts for the higher frequency of cutaneous infections compared to onco-haematological patients.⁴⁴ On the other hand, the percentage of cases diagnosed with skin cancer is quite similar in our series to what has been observed in solid organ transplant recipients. Pre-malignant or malignant skin lesions have been documented in literature in a varying percentage of patients, i.e., up to 35%²⁻⁷, 36,³⁸⁻⁴⁵ and almost all the cases were non melanoma skin cancer. However, 3 of our patients had cutaneous melanoma and all had with a thick primary (2 mm or more) metastases and 1/3 had nodal metastases. One of these cases was a nodular melanoma of recent onset, whilst the lesion had been present for more than 1 year in the other two cases. Melanoma prognosis depends on the Breslow thickness; moreover, the prognosis of post-transplant melanoma >2 mm is even poorer than that of the general population.⁴⁶ These data further emphasise the need for accurate periodic dermatologic examinations, particularly in elderly people with a longer disease duration, so as to favour an early diagnosis and, consequently, improve survival.

In conclusion, the complex variety of cutaneous lesions encountered in these patients, the challenging differential diagnosis and the need for an early identification of cutaneous neoplasia, clearly underline the usefulness of a correct dermatological approach.

Riassunto

Spettro delle patologie cutanee nei pazienti affetti da neoplasie ematologiche, con o senza trapianto allogenico di midollo: studio osservazionale in 101 pazienti

Obiettivo. Determinare la varietà di lesioni cutanee osservabili nei pazienti onco-ematologici che vengono inviati ad un controllo dermatologico e determinare l'influenza della malattia di base (in termini di tipo e durata della malattia, eventuale remissione, chemioterapia, trapianto) sulle manifestazioni cutanee.

Metodi. In questo studio prospettico osservazionale sono stati inclusi tutti i pazienti con patologie onco-ematologiche inviati per una visita dermatologica in un periodo di tempo di 2 anni.

Risultati. Nei 101 pazienti analizzati, le patologie più rappresentate sono state infezioni (19,8%), reazioni avverse a farmaci (16,8%) e neoplasie maligne (11,9%). I tumori cutanei sono risultati più frequenti nei pazienti anziani ed in quelli con malattia di lunga durata. Il più diagnosticato è stato l'epitelioma spinocellulare; tre sono stati i casi di melanoma. Cinque pazienti presentavano un interessamento cutaneo della malattia ematologica di base. Psoriasi ed eczema sono state osservate in una minoranza dei pazienti.

Nei soggetti trapiantati non si è riscontrata una maggiore percentuale di infezioni né di tumori cutanei. Conclusioni. Rispetto ai pazienti che accedono ad una visita dermatologica generica, i pazienti oncoematologici sono caratterizzati da una maggiore incidenza di reazioni avverse a farmaci, spesso con aspetti clinici peculiari e da una minor frequenza delle dermatosi croniche più comuni. Le dermatosi infettive sono meno frequenti rispetto ai pazienti con trapianto di organo solido. La complessa varietà di lesioni cutanee che si possono riscontrare in questi pazienti, la difficoltà nella diagnosi differenziale e la rilevanza prognostica della diagnosi precoce dei tumori cutanei sottolineano la rilevanza di un corretto approccio dermatologico.

Parole chiave: Dermatosi - Farmaci, tossicità – Neoplasie ematologiche - Trapianto di midollo osseo.

References

1. Schulz TF. Cancer and viral infections in immunocompromised individuals. *Int J Cancer* 2009;125:1755-63.
2. W isgerhof HC, Edelbroek JR, de Fijter JW, Feltkamp MC, Willemze R, Bouwes Bavinck JN. Trends of skin diseases in organtransplant recipients transplanted between 1966 and 2006: a cohort study with follow-up between 1994 and 2006. *Br J Dermatol*. 2009. *Br J Dermatol* 2010;162:390-6.
3. W isgerhof HC, Edelbroek JR, de Fijter JW, Haasnoot GW, Claas FH, Willemze R et al. Subsequent squamous- and basal-cell carcinomas in kidney-transplant recipients after the first skin cancer: cumulative incidence and risk factors. *Transplantation* 2010;89:1231-8.
4. Navarro MD, López-Andréu M, Rodríguez-Benot A, Agüera ML, Del Castillo D, Aljama P. Cancer incidence and survival in kidney transplant patients. *Transplant Proc* 2008;40:2936-40.
5. Bichari W, Bartiromo M, Mohey H, Afiani A, Burnot A, Maillard N et al. Significant risk factors for occurrence of cancer after renal transplantation: a single center cohort study of 1265 cases. *Transplant Proc* 2009;41:672-3.
6. Euvrard S, Kanitakis J, Claudy A. Skin cancers after organ transplantation. *N Engl J Med* 2003;348:1681-91.
7. Naldi L, Fortina AB, Lovati S, Barba A, Gotti E, Tessari G et al. Risk of nonmelanoma skin cancer in Italian organ transplant recipients. A registry-based study. *Transplantation* 2000;70:1479-84.
8. Häusermann P, Walter RB, Halter J, Biedermann BC, Tichelli A, Itin P, Gratwohl A. Cutaneous graft-versus-host disease: a guide for the dermatologist. *Dermatology* 2008;216:287-304.
9. W u PA, Cowen EW. Cutaneous graft-versus-host disease—clinical considerations and management. *Curr Probl Dermatol* 2012;43:101-15.
10. Pearson IC, Sirohi B, Powles R, Treleaven J, Mortimer PS. The impact on resources of prevalence and nature of skin problems in a modern intensive haemato-oncology practice. *Hematology* 2004;9:415-23.
11. Maza A, Berbis J, Gaudy-Marqueste C, Morand JJ, Berbis P, Grob JJ et al. Evaluation of dermatology consultations in a prospective multicenter study involving a French teaching hospital. *Ann Dermatol Venereol* 2009;136:241-8.
12. Abel EA. Cutaneous manifestations of immunosuppression in organ transplant recipients. *J Am Acad Dermatol* 1989; 21:167-79.
13. Perera GK, Child FJ, Heaton N, O'Grady J, Higgins EM. Skin lesions in adult liver transplant recipients: a study of 100 consecutive patients. *Br J Dermatol* 2006;154:868-72.
14. Bunney MH, Benton EC, Barr BB, Smith IW, Anderton JL, Hunter JA. The prevalence of skin disorders in renal allograft recipients receiving cyclosporin A compared with those receiving azathioprine. *Nephrol Dial Transplant* 1990;5:379-82.
15. Dufrechou L, Larre Borges A, Nin M, Curi L, González F, Martínez M et al. Cutaneous manifestations in 100 renal and reno-pancreatic recipients of Uruguay. *Transplant Proc* 2011;43:3377-9.
16. Khosravi M, Golchai J, Mokhtari G. Muco-cutaneous manifestations in 178 renal transplant recipients. *Clin Transplant* 2011;25:395-400.
17. Robak E, Robak T. Skin lesions in chronic lymphocytic leukemia. *Leuk Lymphoma* 2007;48:855-65.
18. W ood AJ, Wagner MV, Abbott JJ, Gibson LE. Necrobiotic xanthogranuloma: a review of 17 cases with emphasis on clinical and pathologic correlation. *Arch Dermatol* 2009;145:279-84.

19. Caputo R, Marzano AV, Vezzoli P, Lunardon L. Wells syndrome in adults and children: a report of 19 cases. *Arch Dermatol* 2006;142:1157-61.
20. Schamroth JM, Zlotogorski A, Gilead L. Porokeratosis of Mibelli. Overview and review of the literature. *Acta Derm Venereol* 1997;77:207-13.
21. Magarotto V, Palumbo A. Evolving role of novel agents for maintenance therapy in myeloma. *Cancer J* 2009;15:494-501.
22. Martiniani R, Di Loreto V, Di Sano C, Lombardo A, Liberati AM. Biological activity of lenalidomide and its underlying therapeutic effects in multiple myeloma. *Adv Hematol* 2012;2012:842945.
23. Brazzelli V, Ardighò M, Chiesa MG, Vassallo C, Varettoni M, Borroni RG et al. Flexural erythematous eruption following autologous peripheral blood stem cell transplantation: a study of four cases. *Br J Dermatol* 2001;145:490-5.
24. Benton EC, Kerr OA, Fisher A, Fraser SJ, McCormack SKA, Tidman MJ. The changing face of dermatological practice: 25 years' experience. *Br J Dermatol* 2008;159:413-8.
25. Kerr OA, Tidman MJ, Walker JJ, Aldridge RD, Benton EC. The profile of dermatological problems in primary care. *Clin Exp Dermatol* 2010;35:380-3.
26. Lorente-Lavirgen AI, Bernabeu-Wittel J, Pulpillo-Ruiz A, de la Torre-García JM, Conejo-Mir J. Inpatient dermatology consultation in a Spanish Tertiary Care Hospital: A Prospective Cohort Study. *Actas Dermosifiliogr* 2012 [Epub ahead of print].
27. Fernandes IC, Velho G, Selores M. Dermatology inpatient consultation in a Portuguese university hospital. *Dermatol Online J* 2012;18:16.
28. Antic M, Conen D, Itin PH. Teaching effects of dermatological consultations on nondermatologists in the field of internal medicine. A study of 1290 inpatients. *Dermatology* 2004;208:32-7.
29. Hardwick N, Saxe N. Patterns of dermatology referrals in a general hospital. *Br J Dermatol* 1986;115:167-76.
30. Peñate Y, Guillermo N, Melwani P, Martel R, Borrego L. Dermatologists in hospital wards: an 8-year study of dermatology consultations. *Dermatology* 2009;219:225-31.
31. Fisher M, Bergert H, Marsch WC. The dermatologic consultation. *Hautarzt* 2004;55:543-8.
32. Itin PH. Impact of a department of dermatology within the global concept of a large hospital setting-analysis of 594 consultations requested by non-dermatologists. *Dermatology* 1999;199:79.
33. Lambert A, Delaporte E, Lok C, Froment L, Bailly L, Denoeux JP et al. Skin diseases observed in the dermatology departments of three French university teaching hospitals. *Ann Dermatol Venereol* 2006;133:657-62.
34. W alia NS, Deb S. Dermatology referrals in the hospital setting. *Indian J Dermatol Venereol Leprol* 2004;70:285-7.
35. Prignano F, Mori M, Alaibac M, Santucci M, Bosi A, Pimpinelli N. Specific skin lesions in B-cell chronic lymphocytic leukemia. *G Ital Dermatol Venereol* 1990;125:217-24.
36. Formicone F, Fargnoli MC, Pisani F, Rascente M, Famulari A, Peris K. Cutaneous manifestations in Italian kidney transplant recipients. *Transplant Proc* 2005;37:2527-8.
37. Dicle O, Parmaksizoglu B, Gurkan A, Tuncer M, Demirbas A, Yilmaz E. Skin infections in 401 renal transplant recipients in southern Turkey. *Exp Clin Transplant* 2009;7:133-6.
38. Sandoval M, Ortiz M, Díaz C, Majerson D, Molgó M. Cutaneous manifestations in renal transplant recipients of Santiago, Chile. *Transplant Proc* 2009;41:3752-4.
39. Alper S, Kilinc I, Duman S, Toz H, Ceylan C, Unal I et al. Skin diseases in Turkish renal transplant recipients. *Int J Dermatol* 2005;44:939-41.
40. Savoia P, Stroppiana E, Cavaliere G, Osella-Abate S, Mezza E, Segoloni GP et al. Skin cancers and other cutaneous diseases in renal transplant recipients: a single Italian center observational study. *Eur J Dermatol* 2011;21:242-7.
41. Salard D, Parriaux N, Derancourt C, Aubin F, Bresson-Hadni S, Miguët JP et al. Cutaneous complications following liver transplantation: epidemiologic and clinical study in 86 patients. *Ann Dermatol Venereol* 2002;129:1134-8.
42. Freire-Ruaño A, Crespo-Leiro MG, Muñiz J, Paniagua MJ, Almagro M, Castro-Beiras A. Dermatologic complications after heart transplantation: incidence and prognosis. *Med Clin (Barc)* 2000;115:208-10.

43. Tan HH, Goh CL. Viral infections affecting the skin in organ transplant recipients: epidemiology and current management strategies. *Am J Clin Dermatol* 2006;7:13-29.
44. Kirk AD. Induction immunosuppression. *Transplantation* 2006;82:593-602.
45. Tessari G, Girolomoni G. Non-melanoma skin cancer in solid organ transplant recipients: update on epidemiology, risk factors, and management. *Dermatol Surg* 2012;38:1622-30.
46. Matin RN, Mesher D, Proby CM, McGregor JM, Bouwes Bavinck JN, del Marmol V et al. Skin Care in Organ Transplant Patients, Europe (SCOPE) group. Melanoma in organ transplant recipients: clinicopathological features and outcome in 100 cases. *Am J Transplant*. 2008; 8:1891-900.

Preliminary results were presented at “85° Congresso Nazionale SIDeMaST” held in Rimini, 19-22 may 2010 and at “XIX Giornate di Dermatologia Clinica” held in Rome, 20-22 January 2011.

Acknowledgements.—The authors would like to thank the medical teams of the Haematology Department of University of Turin (Director Prof Mario Boccadoro) and Haematologic Division of S. Giovanni Hospital, Turin (Director Prof Umberto Vitolo) for their kind patient referral, as well as Barbara Wade for her linguistic advice.

Conflicts of interest.—The authors certify that there is no conflict of interest with any financial organization regarding the material discussed in the manuscript.

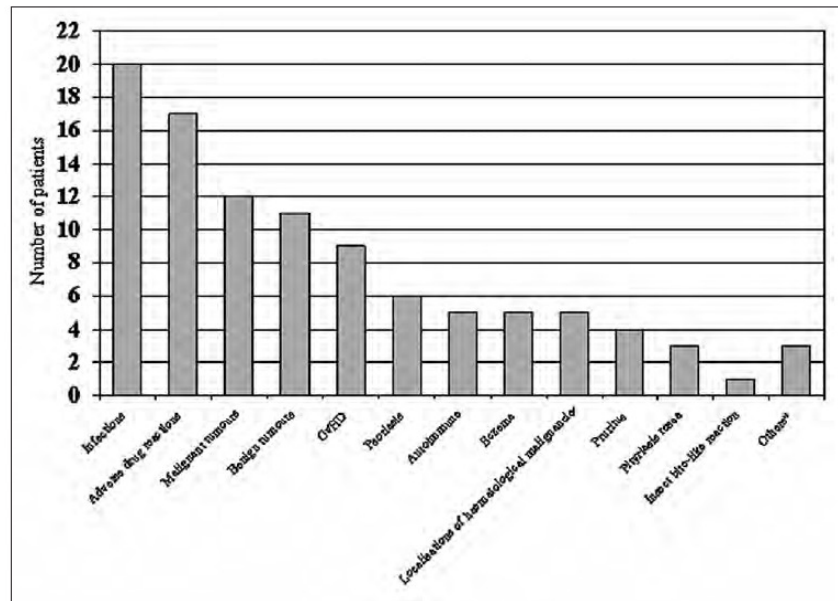


Figure 1.—Distribution of dermatological diseases and manifestations. * Other: specific dermatoses frequently associated with haematologic malignancies.

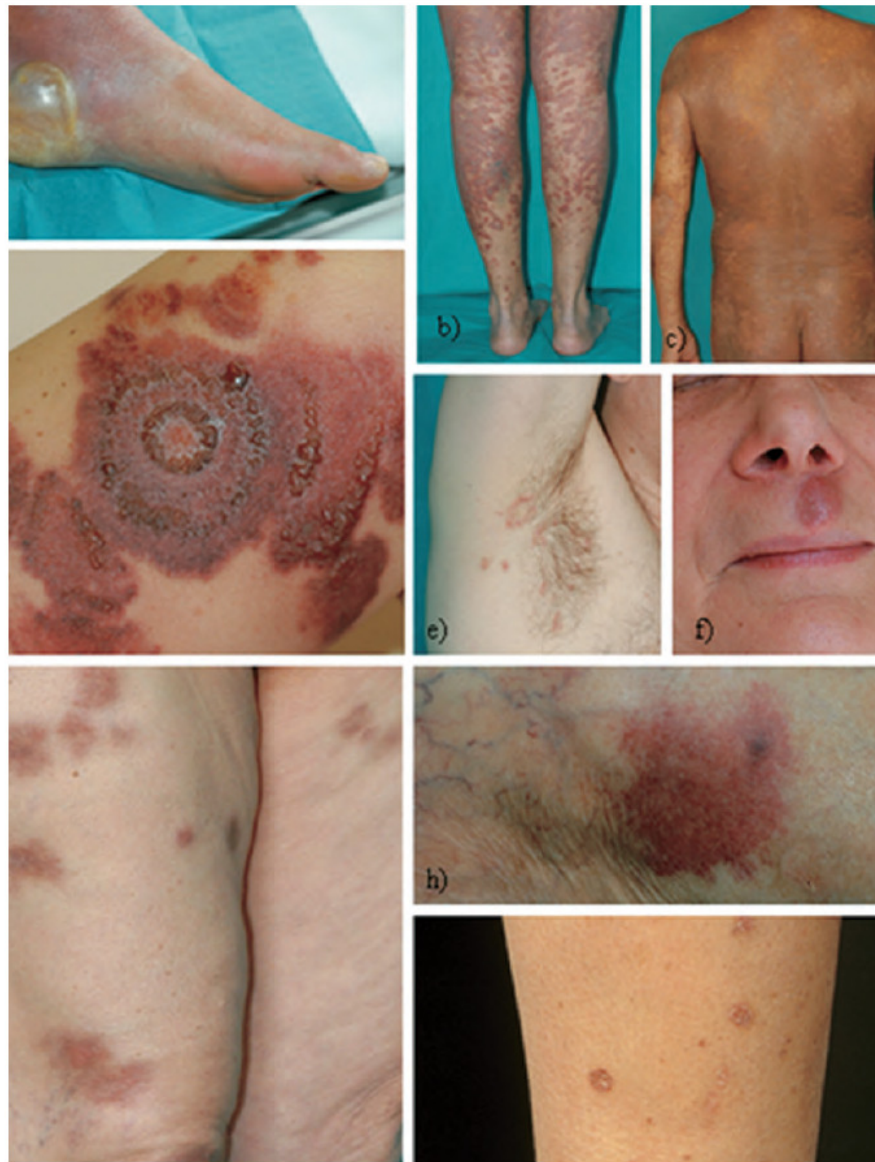

Figure 2.—Representative clinical pictures in patients with onco-haematological malignancies. A) bullous acute GvHD; B) diffuse acute GvHD; C) sclerodermiform deeply indurated chronic GvHD; D) peculiar manifestations of chronic lymphocytic leukaemia localisations with vesico-bullous annular lesions; E) erythematous edematous annular cutaneous localisations of acute lymphocytic leukaemia; F) a nodular infiltrated lesion in a patients with NK lymphoma Epstein-Barr virus related; G) necrobiotic xanthogranuloma; H) Wells' syndrome; I) Mibelli porokeratosis.

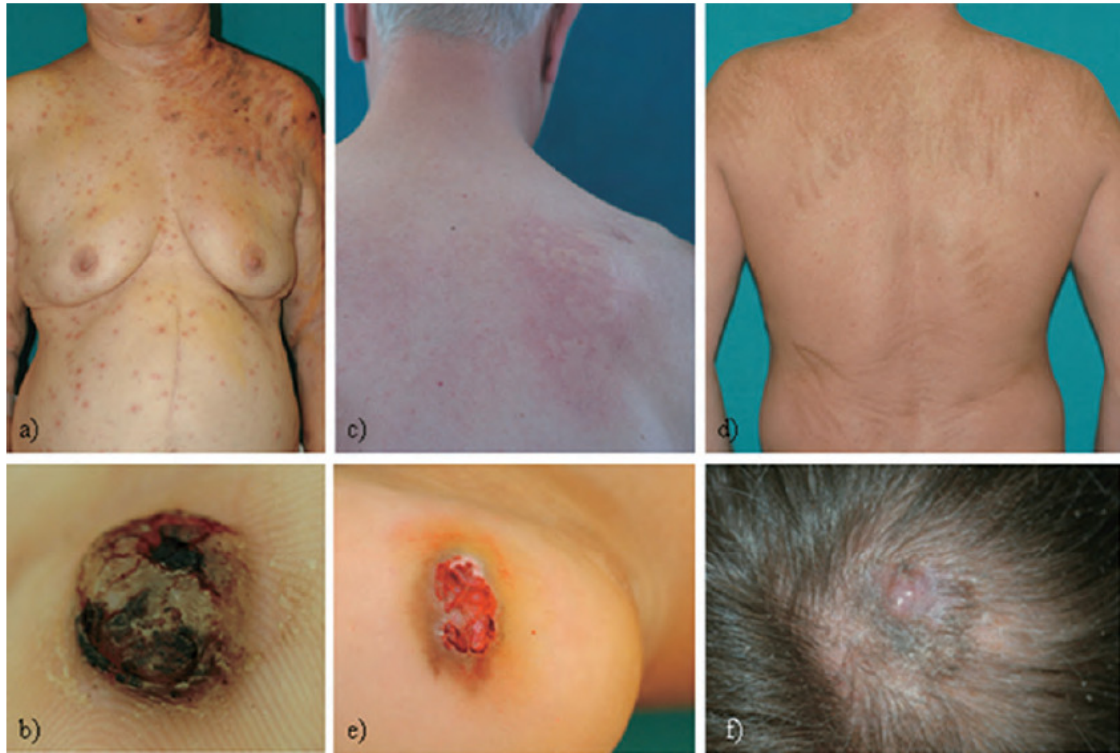

Figure 3.—Infectious dermatoses: A) left shoulder herpes zoster with disseminated lesions; B) giant viral wart localized in the palm of the left hand. Adverse drug reactions: C) urticarial reaction to rituximab localized at the site of cutaneous NHL lesions; D) bleomycinrelated flagellate dermatitis. Skin tumours: E) acromic nodular phase of a superficial spreading melanoma of the scalp, Breslow thickness 8.8 mm; F) ulcerated acral lentiginous melanoma of the foot, Breslow thickness 3.5 mm.

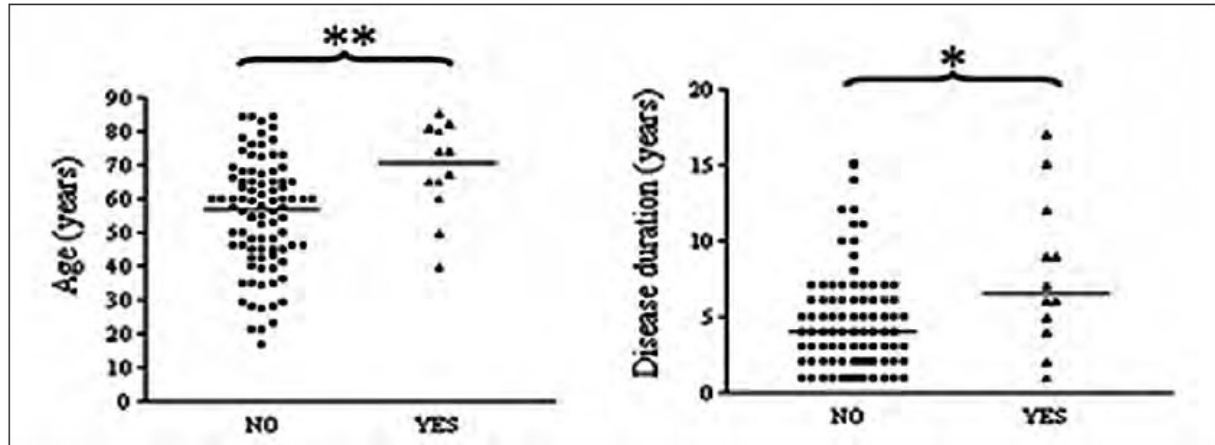


Figure 4.—Skin neoplasia in patients with onco-haematological malignancies. The development of a skin malignant tumour is significantly more frequent in elderly patients (A) and in patients with a longer disease duration. Each dot represents a patient; horizontal bars represent median values. * $P < 0.05$; ** $P < 0.005$.