

AperTO - Archivio Istituzionale Open Access dell'Università di Torino

## Iatrogenic atrial septal defects following atrial fibrillation transcatheter ablation: a relevant entity?

### This is the author's manuscript

*Original Citation:*

*Availability:*

This version is available <http://hdl.handle.net/2318/142152> since

*Published version:*

DOI:10.1093/europace/euu020

*Terms of use:*

Open Access

Anyone can freely access the full text of works made available as "Open Access". Works made available under a Creative Commons license can be used according to the terms and conditions of said license. Use of all other works requires consent of the right holder (author or publisher) if not exempted from copyright protection by the applicable law.

(Article begins on next page)



# UNIVERSITÀ DEGLI STUDI DI TORINO

***This is an author version of the contribution published on:***

*Questa è la versione dell'autore dell'opera:*

[[Europace](#). 2014 Feb 18. [Epub ahead of print] 10.1093/europace/euu020]

***The definitive version is available at:***

*La versione definitiva è disponibile alla URL:*

[[http://europace.oxfordjournals.org/content/early/2014/02/18/europace.euu020.  
long](http://europace.oxfordjournals.org/content/early/2014/02/18/europace.euu020.long)]

# **Iatrogenic atrial septal defects following atrial fibrillation transcatheter ablation: a relevant entity?**

Short title: Iatrogenic atrial septal defects following AF ablation

Matteo Anselmino<sup>a</sup>, Marco Scaglione<sup>b</sup>, Alberto Battaglia<sup>a</sup>, Silvia Muccioli<sup>a</sup>,  
Davide Sardi<sup>b</sup>, Giuseppe Azzaro<sup>b</sup>, Lucia Garberoglio<sup>a</sup>, Salvatore Miceli<sup>b</sup>, Fiorenzo Gaita<sup>a</sup>

<sup>a</sup> Cardiology Division, Department of Internal Medicine, University of Turin, Italy

<sup>b</sup> Division of Cardiology, Cardinal Guglielmo Massaia Hospital, Asti, Italy

Word count: 2327 words, 2 tables, 3 figures, and 17 references

Abstract word count: 250 words

## Corresponding author:

Fiorenzo Gaita, MD Professor

Email : gaitaf@gmail.it; fiorenzo.gaita@unito.it

Department of Medical Sciences, University of Turin

Cardiology Division, Città della Salute e della Scienza Hospital,

Corso Bramante 88, 10126 Turin, Italy

Phone: +39-011-6335570 Fax: +39-011-6966015

## **Abstract**

**Introduction** Previous literature has suggested that iatrogenic atrial septal defects (IASD) may follow left atrial (LA) access by transseptal (TS) puncture, especially in case of single TS for more than one catheter. Aim of the present study is to describe prevalence of patent foramen ovale (PFO) and IASDs in a cohort of atrial fibrillation (AF) patients undergoing redo catheter ablation (CA) procedures in a high volume center accessing LA by standardized, single TS puncture.

**Methods and Results** Patients (n=197) who underwent at least one redo AFCA, between 2004 and 2012, were retrospectively enrolled. Transesophageal echocardiography was performed before each procedure during which LA was accessed via a PFO, if present, or by single TS for both the mapping and ablation catheters.

At baseline PFO was detected in 43 (21.8%) patients. Clinical and echocardiographic parameters recorded did not differ within patients presenting with or without PFO. LA was accessed via PFO in 39 (90.7% of those with PFO) patients during the first procedure. New onset IASD occurred in 11 (5.6%) patients following the first procedure and in one (2.2%) patient following the second procedure. Clinical and echocardiographic parameters did not differ within patients reporting or not IASD. No TS-related complications occurred.

**Conclusion** In the present cohort LA access by PFO or single TS for both the mapping and ablation catheters lead to a small risk of asymptomatic IASD, not increased by redo procedures, confirming that it represents a safe approach. No clinical and/or echocardiographic parameters seemed to predict IASD occurrence.

**Key-words:** atrial fibrillation, ablation, iatrogenic atrial septal defects, patent foramen ovale, transseptal puncture



### **Condensed Abstract**

Literature reports controversial data on iatrogenic atrial septal defects (IASD) following atrial fibrillation catheter ablation. In our cohort left atrium access by patent foramen ovale or single transseptal puncture, for both the mapping and ablation catheters, lead to a small risk of asymptomatic IASD, not increased by redo procedures.

**What's new?**

LA access via a patent foramen ovale (PFO) or a single transseptal (TS) puncture for both the mapping and ablation catheters does not lead to a relevant risk of iatrogenic atrial septal defects (IASD).

Within patients not presenting baseline PFO a minority (6%) reported asymptomatic IASD unpredicted by any clinical or echocardiographic characteristics potentially involved.

In patients undergoing redo atrial fibrillation catheter ablation (AFCA) procedures the present study is, to the best of our knowledge, unique. In fact the proposed left atrium (LA) approach seems extremely safe also in patients undergoing a second procedure. Based on the present data a redo procedure does not increase the risk of IASD.

## **Introduction**

Catheter ablation (CA) has progressively increased its role in the treatment of atrial fibrillation (AF), being proposed to date to more than two-hundred thousand patients worldwide<sup>1</sup>. In the latest decades history, in fact, AFCA has significantly evolved becoming pulmonary vein (PV) isolation and left atrium (LA) linear lines established procedural targets achieving satisfactory long-term outcomes<sup>2,3</sup>. To perform the procedure LA access is achieved by a patent foramen ovale (PFO), when present, or more commonly by a transseptal (TS) puncture. In the latter case, LA access can be obtained both with single TS puncture followed by exchange over the guide wire of a second catheter<sup>2</sup>, or by double TS puncture<sup>4, 5, 6</sup>. To date, whether a TS LA catheterization involves a risk of persistent iatrogenic atrial septal defect (IASD) is controversial. Previous small sample size studies, using transesophageal echocardiography (TEE), reported an incidence from null<sup>7</sup> to 19% of IASD at mid-term follow up after AFCA<sup>5, 6, 8</sup>. The only large sample size study, based on transthoracic echocardiography (TTE), surprisingly reported the absence of IASDs about 1 year following the procedure<sup>9</sup>. In addition if redo procedures requiring new TS punctures increase the incidence of IASD is unknown.

Aim of the present retrospective study is therefore to report the prevalence of PFO at baseline and describe the incidence of IASD by TEE in a large cohort of patients undergoing at least one AFCA redo procedure in a high volume center using a standardized LA approach by single TS puncture.

## Methods

Eight hundred eighty-nine patients referred for AFCA between 2003 and 2012 have been screened. Baseline PFO was present in 206 (23.2%) patients and AF recurrences, over the years, occurred in 433 (48.7%). Within this population the 197 patients (22.2%) who underwent at least one redo procedure were enrolled in the study. Before the indication to AFCA, failure of at least two different antiarrhythmic drugs in controlling symptoms of AF or maintaining sinus rhythm had to be documented. Redo AFCA was proposed in case of recurrences following the first procedure not controlled by one new AAD or in case of patients' refusal of a new AADs. The definition and classification of AF used in this study were based on contemporary published guidelines<sup>10</sup>. All subjects underwent extensive clinical assessment, including: medical history (targeted to presence of heart disease and comorbidities), thromboembolic risk assessment (CHA2DS2-Vasc score) and physical examination. TTE and TEE were performed before the procedure in each patient. The study was conducted in accordance to the latest Declaration of Helsinki and all patients signed an informed consent form before undergoing the AFCA procedure.

*Transthoracic echocardiography.* LA (superior-inferior, lateral-medial, anterior-posterior) and right atrium diameters (superior-inferior, lateral-medial) were recorded at the end of ventricular systole on the M-mode image obtained from the parasternal long axis view or from the apical 2- and 4- chambers two-dimensional views as appropriate. Left ventricle ejection fraction (by the biplane Simpson's method of discs), ventricular wall thickness, lumen diameters and global/segmental kinesis were assessed according to the latest European Association of Echocardiography Guidelines<sup>11</sup>.

*Transesophageal echocardiography.* LA and LA appendage were appraised to exclude the presence of endoluminal thrombi or spontaneous echocontrast/smoke. LA appendage ostium area and peak flow velocity were recorded. The interatrial septum and the fossa ovale were also identified in search of any leakage, supported by the color-doppler technique to describe interatrial shunts. Peripheral venous infusion of an echo-contrast solution (aerated saline solution), both at rest or during Valsalva maneuver was also performed in all patients in search of any interatrial communication (positive in case of microbubbles appearance in the right atrium within three cardiac cycles after the peripheral venous infusion<sup>12, 13, 14</sup>). The following definitions guided PFO and IASD diagnosis. PFO: microbubbles appearance in the right atrium through a passage located in the anterior portion of the inter-atrial septum (in proximity to the fossa ovalis). IASD: microbubbles appearance in the right atrium through an inter-atrial communication located in the posterior portion of the inter-atrial septum (in correspondence of the standard site of TS puncture). In addition, in case PFO or IASD were detected, evaluation of shunt presence and **hemodynamic** influence (Qp/Qs) was performed.

*Ablation procedure.* Procedural details have been reported elsewhere<sup>15</sup>. Briefly, concerning LA access, in the absence of a PFO, a guide wire was introduced into the LA by a single TS puncture (BRK Transseptal Needle, St Jude Medical, MN, USA) with the use of an 8.5F long sheath (Fast-Cath or SL0, St. Jude Medical, MN, USA; the Fast-Cath sheath has been preferentially used in patients presenting with PFO). An irrigated-tip 8F ablation catheter (Navistar or Thermocool, Biosense Webster, CA, USA; or Coolpath, St. Jude, MN, USA) was then advanced into the LA, exchanged over the guide wire, through the same hole (Figure 1). The sheath was continuously perfused with heparinized solution (3000 U of heparin in 500 mL of NaCl 0.9%) at 150 mL/h and

a multipolar 8F catheter (Lasso, Biosense Webster, CA, USA; or Inquiry Optima, St Jude Medical, MN, USA; or Orbiter, Bard, MA, USA) was inserted through the long sheath to map the PVs ostia. A 3-dimensional reconstruction of the LA and PVs ostia, with the use of an electroanatomic mapping system (Carto, Biosense Webster, CA, USA; or Nav-X, St. Jude, MN, USA) was performed in all patients. For paroxysmal AF, the end point of the ablation procedure was to obtain a complete electric PVs isolation. If necessary to interrupt the arrhythmia or in case of a repeat procedure, PVs isolation plus the addition of linear lesions were performed. For persistent AF, PVs isolation was accompanied by the creation of extra linear lesions interconnecting the upper pulmonary veins ostia (roof line), and the left inferior pulmonary vein down to the mitral annulus (left isthmus); when necessary, a line interconnecting the right inferior pulmonary vein to the mitral annulus (right isthmus) and ablation of fragmented atrial electrograms were performed to complete elimination of the potentials. Radiofrequency was applied with power output up to 30 W close to the PV ostia and up to 40 W while creating the roof line and the left mitral isthmus line, with an irrigation rate of 15 to 35 mL/min (0.9% saline infused with the Cool Flow Pump, Biosense Webster, CA, USA) to maintain a tip temperature below 45°.

*Follow up.* All patients were regularly followed by ambulatory visits or telephonic monitoring and performed 24-hour Holter ECG at 1, 3, 6 months and then yearly to identify occurrence of relapses or any new symptom, especially related to thromboembolic events (i.e. transient ischemic attack, cerebro-vascular accident). Three (1.5%) patients received an implantable continuous recorder.

### *Statistical analysis.*

Continuous variables, presented as means  $\pm$  standard deviation (SD), were compared by Student's t-test after normal distribution was confirmed. Categorical variables, presented as counts and percentages, were compared in cross-tabulation tables by means of the Pearson chi-square test. The time between AFCA and echocardiographic follow-up were presented as median and interquartile range (IQR). All tests of significance were two-tailed, and a p value of less than 0.05 was considered to indicate statistical significance. All analyses were performed by SPSS 18.0.

## Results

During the ten year period retrospectively investigated at least one redo AFCA procedure was performed in 197 patients (76.1% males mean age  $57.1 \pm 10$  years) due to symptomatic drug resistant AF relapses. In addition, as shown in details in the flowchart reported in Figure 2, in 45 (22.8%) patients two redo AFCA procedures were performed.

At baseline 43 (21.8%) patients (74.4% males mean age  $55.0 \pm 9$  years) presented a PFO. All PFO were asymptomatic and none presented, at echocardiographic study, significant hemodynamic shunt. As reported in Table 1, clinical or echocardiographic characteristic did not differ within patients presenting or not with a baseline PFO. When described, LA was accessible via the PFO in the majority of cases (39, 90.7%).

Following the AFCA procedure, after a median period of 12 (7–25) months, 11 (5.6% of all, 7.1% of those not presenting baseline PFO) patients developed an asymptomatic IASD (Figure 3). Out of the 45 (22.8%) patients undergoing a second AFCA redo procedure 13 (28.9%) presented a PFO since baseline and 2 (4.4%) had developed an IASD following the first procedure. LA access was achieved via PFO in 8 (61.5%) patients presenting PFO and via IASD in both the two cases that developed one following the first procedure. Following the second AFCA procedure, after a median period of 13 (7–23) months, 1 (2.2% of all, 3.3% of those not presenting PFO/IASD) patient developed an asymptomatic IASD. None of IASD detected in our study presented, at echocardiographic study, a significant hemodynamic shunt. No clinical, echocardiographic and ablation characteristics related to IASD development following the first or second AF ablation procedure (Table 2).



No TS related complication occurred during the total 439 AFCA procedures retrospectively analyzed.

## **Discussion**

The present retrospective study, performed in a large cohort of patients undergoing at least one AFCA redo procedure, supports that LA access via a PFO or a single TS puncture for both the mapping and ablation catheters does not lead to a relevant risk of IASD. In fact, within the patients presenting a baseline PFO, LA was accessed via this spontaneous anatomical path in the majority of cases (91%) without creating long-term complications. Within patients not presenting baseline PFO, a minority (6%) reported, instead, asymptomatic IASD unpredicted by any clinical or echocardiographic characteristics potentially involved.

The first study<sup>7</sup> on this topic was performed on 51 patients undergoing left sided electrophysiological studies **by a single TS puncture**. In this experience, none of the patients reported a post procedural IASD, investigated by TEE, after a mean period of 12 weeks. **Years later, however, Hammerstingl et al.<sup>5</sup> reported in patients undergoing pulmonary vein isolation due to AF a 19% incidence, investigated by TEE, of IASD after a mean period of 9 months. Interestingly this study also compared the single and double TS puncture techniques suggesting a correlation between single TS puncture and IASD. Within the 42 patients enrolled, 8 new onset iASD were reported, all within patients undergoing single TS procedure (n=27). In the latter dataset, in addition, increased baseline pulmonary artery pressure estimated by echocardiography was significantly related to IASD incidence.** Another study by Obel et al.<sup>8</sup> instead, although on a similar follow-up period (33 weeks) described a lower IASD incidence (6.5%) following a similar pulmonary vein isolation procedure **achieved by double TS puncture**. New insights on the

incidence and clinical implications of IASD emerged following the studies by the group of Rillig. These authors, in 2008<sup>6</sup>, performed repeated TEE among 31 patients undergoing pulmonary vein isolation by double TS puncture; the scans were completed immediately after the procedure and at 3, 6 and 12 months thereafter. Immediately after the procedure IASD were detectable in 27 (87%) patients. Spontaneous closure of the IASD was, however, reported in 26 out of 27 (96.3%) already at the 3-month TEE. The only patients in which the defect did not quickly spontaneously close maintained this echocardiographic finding, completely asymptomatic, also at the 6 and 12-months controls. A similar trend towards spontaneous closure was also reported in case of use of different technologies for AFCA. Among 40 patients undergoing pulmonary vein isolation by means of a remote robotic navigation system involving sheaths with a distinct larger outer diameter, the day after the procedure, an IASD was detected in 38 (95%) patients. Spontaneous closure of the IASD was, however, achieved at 6-month follow-up in 30 (79%) patients. Persistence of IASD over the follow-up did not relate to cerebral or cardiac embolic events<sup>16</sup>. In addition, spontaneous closure of post procedural IASD has also been reported following TS puncture due to other indications<sup>17</sup>. In fact, also in the present dataset, time to redo procedure was shorter (7, 2-20 months) for patients who reported IASD compared to those (12.5, 7-26.2) in the other group, but this trend did not reach statistical significance (p value 0.131).

To date, if IASD have this benign evolution also performing a single TS for both mapping and ablation catheters remains instead controversial. One large sample size study<sup>9</sup> retrospectively addressed this topic reporting the absence of IASDs about 1 year following a simplified approach for positioning multiple catheters in the LA by single TS puncture but the data were based on TTE.

With these presumptions the present finding of a low (5.6%) IASD incidence, assessed by TEE, following LA access with both the mapping and ablation catheters by single TS puncture is, indeed, relevant. Surely this result is influenced by the long period between the procedure and the TEE scan. The first redo procedure was, in fact, performed after a median period of 12 months (7–25). However, on the other side, evaluating the prevalence of IASD in a population of patients undergoing redo AFCA procedures due to arrhythmia relapses could have potentially overestimated its presence due to the selective inclusion of patients suffering higher LA pressures.

Concerning, instead, IASD prevalence in patients undergoing redo AFCA procedures the present study is, to the best of our knowledge, unique. Also in patients undergoing a second procedure in fact the proposed LA approach seems extremely safe. Based on the present data a redo procedure does not increase the risk of IASD.

### *Limitations*

First, it should be considered that this study has a retrospective design: all data, although deriving from a single high volume center involving a limited number of experienced operators following a standardized technique, have been retrospectively collected and analyzed. Second, despite all TEE examinations were performed by three experienced physicians, inter-operator accordance and/or agreement may not be examined. In addition, anatomical details concerning each individual PFO and IASD, given the study design, have not been included due to lack of uniform data recording. Third, the limited number of new onset IASD detected, derived from the low incidence of the phenomenon, may have reduced the statistical power of the conclusion. Fourth,

IASD have been evaluated at the time of the redo AFCA procedure and no temporal trend to evaluate the timing of eventual spontaneous closures over time is available.

## **Conclusion**

LA access via a PFO or a single TS puncture for both the mapping and ablation catheters in a large cohort of patients undergoing AFCA did not lead to a relevant risk of IASD both during the first than the redo procedure. IASD are not predicted by any clinical or echocardiographic parameter and represent a sporadic, asymptomatic phenomenon not leading to any clinical/procedural implication.

## References

- <sup>1</sup> Cappato R, Calkins H, Chen SA, Davies W, Iesaka Y, Kalman J et al. : Updated worldwide survey on the methods, efficacy, and safety of catheter ablation for human atrial fibrillation. *Circ Arrhythm Electrophysiol.* 2010 Feb;3(1):32-8.
- <sup>2</sup> Anselmino M, D'Ascenzo F, Amoroso G, Ferraris F, Gaita F: History of transcatheter atrial fibrillation ablation. *J Cardiovasc Med (Hagerstown)* 2012 Jan;13(1):1-8.
- <sup>3</sup> Gaita F, Caponi D, Scaglione M, Montefusco A, Corleto A, Di Monte F, et al. : Long-Term Clinical Results of 2 Different Ablation Strategies in Patients With Paroxysmal and Persistent Atrial Fibrillation. *Circ Arrhythmia Electrophysiol.* 2008;1:269-275.
- <sup>4</sup> De Ponti R, Cappato R, Curnis A, Della Bella P, Padeletti L, Raviele A et al. : Trans-septal catheterization in the electrophysiology laboratory: Data from a multicenter survey spanning 12 years. *Journal of the American College of Cardiology* 2006;47:1037–1042.
- <sup>5</sup> Hammerstingl C, Lickfett L, Jeong K, Troatz C, Wedekind JA, Tiemann K, et al. : Persistence of iatrogenic atrial septal defect after pulmonary vein isolation – an underestimated risk? *Am Heart J* 2006;152(2):362–365.
- <sup>6</sup> Rillig A, Meyerfeldt U, Birkemeyer R, Treusch F, Kunze M, Jung W: Persistent iatrogenic atrial septal defect after pulmonary vein isolation: incidence and clinical implications. *J Interv Card Electrophysiol* 2008;22(3):177–181.
- <sup>7</sup> Fitchet A, Turkie W, Fitzpatrick AP: Transeptal approach to ablation of left-sided arrhythmias does not lead to persisting interatrial shunt: a transesophageal echocardiographic study. *Pacing Clin Electrophysiol.* 1998 Nov;21:2070-2.
- <sup>8</sup> Obel O, Mansour M, Picard M, Ruskin J, Keane D: Persistence of septal defects after transeptal puncture for pulmonary vein isolation procedures. *Pacing Clin Electrophysiol.* 2004;27(10):1411-4.

- <sup>9</sup> Fagundes RL, Mantica M, De Luca L, Forleo G, Pappalardo A, Avella A, et al. : Safety of single transseptal puncture for ablation of atrial fibrillation: retrospective study from a large cohort of patients. *J Cardiovasc Electrophysiol* 2007;18(12):1277–1281.
- <sup>10</sup> Camm AJ, Kirchhof P, Lip GY, Schotten U, Savelieva I, Ernst S et al. : Guidelines for the management of atrial fibrillation: the Task Force for the Management of Atrial Fibrillation of the European Society of Cardiology (ESC). *Eur Heart J*. 2010 Oct;31(19):2369-429.
- <sup>11</sup> Evangelista A, Flachskampf F, Lancellotti P, Badano L, Aguilar R, Monaghan M et al.: European Association of Echocardiography recommendations for standardization of performance, digital storage and reporting of echocardiographic studies. *Eur J Echocardiogr*. 2008 Jul;9(4):438-48
- <sup>12</sup> Lechat P, Mas Y, Lascault G, Loron PH, Theard M, Klimczak M et al. Prevalence of patent foramen ovale in patients with stroke. *N Engl J Med* 1988;318:1148-52.
- <sup>13</sup> Webster M, Smith H, Sharpe D, Chancellor A, Swift D, Bass N et al. Patent foramen ovale in young stroke patients. *Lancet* 1988;332:11-2
- <sup>14</sup> Di Tullio M, Sacco RL, Gopal A, Mohr YJP, Homma S. Patent foramen ovale as risk factor for cryptogenetic stroke. *Ann Intern Med* 1992;117:461-5
- <sup>15</sup> Gaita F, Caponi D, Pianelli M, Scaglione M, Toso E, Cesarani F et al. : Radiofrequency Catheter Ablation of Atrial Fibrillation: A Cause of Silent Thromboembolism?: Magnetic Resonance Imaging Assessment of Cerebral Thromboembolism in Patients Undergoing Ablation of Atrial Fibrillation. *Circulation* 2010; 122:1667-1673.
- <sup>16</sup> Rillig A, Meyerfeldt U, Kunze M, Birkemeyer R, Miljak T, Jackle S et al. : Persistent iatrogenic atrial septal defect after a single-puncture, double-transseptal approach for pulmonary vein isolation using a remote robotic navigation system: results from a prospective study. *Europace* 2010; 12: 331–336.

<sup>17</sup> Omran H, Hardung D, Schmidt H, Hammerstingl C, Luderitz B: Mechanical occlusion of the left atrial appendage. J Cardiovasc Electrophysiol 2003;14:S56–S59.

**Table 1.** Clinical and echocardiographic characteristics of the study population stratified by presence of baseline patent foramen ovale. AF, atrial fibrillation. AP, antero-posterior diameter. BMI, body mass index. CM, cardiomyopathy. EF ejection fraction. HD heart disease. HF heart failure. LA, left atrium. LM, latero-medial diameter. RA, right atrium. SI, supero-inferior diameter. TIA, transient ischemic attack.

Parameter	Total 197 pts	PFO abstent 154 pts (78.2%)	PFO present 43 pts (21.8%)	p value
Age (%)	57.1 ± 10	57.7 ± 10	55.0 ± 9	0.12
Male sex	150 (76.1)	118 (76.6)	32 (74.4)	0.76
BMI	26.8 ± 4	26.7 ± 4	27.0 ± 3	0.64
Arterial hypertension	86 (43.7)	68 (44.2)	18 (41.9)	0.79
Hyperthyroidism	26 (13.2)	22 (14.3)	4 (9.3)	0.46
Hypothyroidism	17 (8.6)	16 (10.4)	1 (2.3)	0.13
Dyslipidemia	48 (24.4)	36 (23.4)	12 (27.9)	0.54
Stroke/TIA	17 (8.6)	12 (7.8)	5 (11.6)	0.54
Diabetes	9 (4.6)	7 (4.5)	2 (4.7)	1.00
Congestive HF	12 (6.1)	9 (5.8)	3 (7.0)	0.73
CHA <sub>2</sub> DS <sub>2</sub> VASc				
0	63 (32.0)	50 (32.5)	13 (30.2)	0.71
1	67 (34.0)	51 (33.1)	16 (37.2)	
2	33 (16.8)	26 (16.9)	7 (16.3)	
> 2	34 (17.2)	27 (17.5)	7 (16.3)	
Structural HD				
Absent	151 (76.6)	117 (76.1)	34 (79.0)	0.53
Ischaemic HD	4 (2.0)	3 (1.9)	1 (2.3)	
Valvular HD	18 (9.2)	15 (9.7)	3 (7.0)	
Hypertrophic CM	17 (8.6)	15 (9.7)	2 (4.7)	
Dilated CM	7 (3.6)	4 (2.6)	3 (7.0)	
Type of AF				
Paroxysmal	76 (38.6)	57 (37.0)	19 (44.2)	0.39
Persistent	121 (61.4)	97 (63.0)	24 (55.8)	
Ecocardiographic features				
EF (%)	58.2 ± 8	58.5 ± 8	57.1 ± 8	0.31
LA diameter (mm)				
AP	46.3 ± 6	46.4 ± 6	45.7 ± 6	0.58
SI	62.9 ± 8	63.2 ± 8	61.8 ± 7	0.42
LM	48.5 ± 8	48.5 ± 8	48.2 ± 8	0.86
RA diameter (mm)				
SI	50.6 ± 8	50.5 ± 8	51.0 ± 8	0.76
LM	40.0 ± 8	39.8 ± 8	40.6 ± 8	0.57
Left appendage flux (cm/sec)	67.7 ± 22	67.2 ± 21	69.6 ± 22	0.56
Left appendage area (cm <sup>2</sup> )	5.0 ± 1	5.0 ± 1	5.0 ± 1	0.85



**Table 2.** Clinical, echocardiographic and ablation characteristics stratified by development of an iatrogenic atrial septal defect following the first or second atrial fibrillation ablation procedure.

AF, atrial fibrillation. Abbreviations as in Table 1.

Parameter	No IASD 185 pts (93.9%)	New IASD 12 pts (6.1%)	p value
Age (%)	56.8 ± 10	60.8 ± 7	0.16
Male sex	141 (76.2)	9 (75.0)	0.92
BMI	26.7 ± 4	27.4 ± 4	0.58
Arterial hypertension	78 (42.2)	8 (66.7)	0.09
Hyperthyroidism	25 (13.5)	1 (8.3)	1.00
Hypothyroidism	16 (8.6)	1 (8.3)	1.00
Dyslipidemia	47 (25.4)	1 (8.3)	0.30
Stroke/TIA	16 (8.6)	1 (8.3)	1.00
Diabetes	8 (4.3)	1 (8.3)	0.43
Congestive HF	12 (6.5)	0 (0)	1.00
CHA <sub>2</sub> DS <sub>2</sub> VASc			
0	60 (32.3)	3 (25.0)	0.72
1	63 (34.1)	4 (33.3)	
2	31 (16.8)	2 (16.7)	
> 2	31 (16.8)	3 (25.0)	
Structural HD			
Absent	140 (75.7)	11 (91.7)	0.69
Ischaemic HD	4 (2.2)	0 (0)	
Valvular HD	18 (9.7)	0 (0)	
Hypertrophic CM	16 (8.6)	1 (8.3)	
Dilated CM	7 (3.8)	0 (0)	
Type of AF			
Paroxysmal	71 (38.4)	5 (41.7)	0.82
Persistent	114 (61.6)	7 (58.3)	
Ecocardiographic features			
EF (%)	58.0 ± 8	60.6 ± 5	0.30
LA diameter (mm)			
AP	46.4 ± 6	44.6 ± 6	0.38
SI	62.9 ± 8	61.9 ± 7	0.71
LM	48.2 ± 8	49.9 ± 7	0.55
RA diameter (mm)			
SI	50.6 ± 8	49.7 ± 7	0.71
LM	39.9 ± 8	39.5 ± 6	0.84
Left appendage flux (cm/sec)	67.7 ± 22	68.7 ± 18	0.88
Left appendage area (cm <sup>2</sup> )	5.0 ± 1	5.4 ± 1	0.42
Ablation approach			
PVI	41 (22.2)	0 (0.0)	0.14
PVI+LL	121 (65.4)	11 (91.7)	
PVI+LL+CFAEs	23 (12.4)	1 (8.3)	

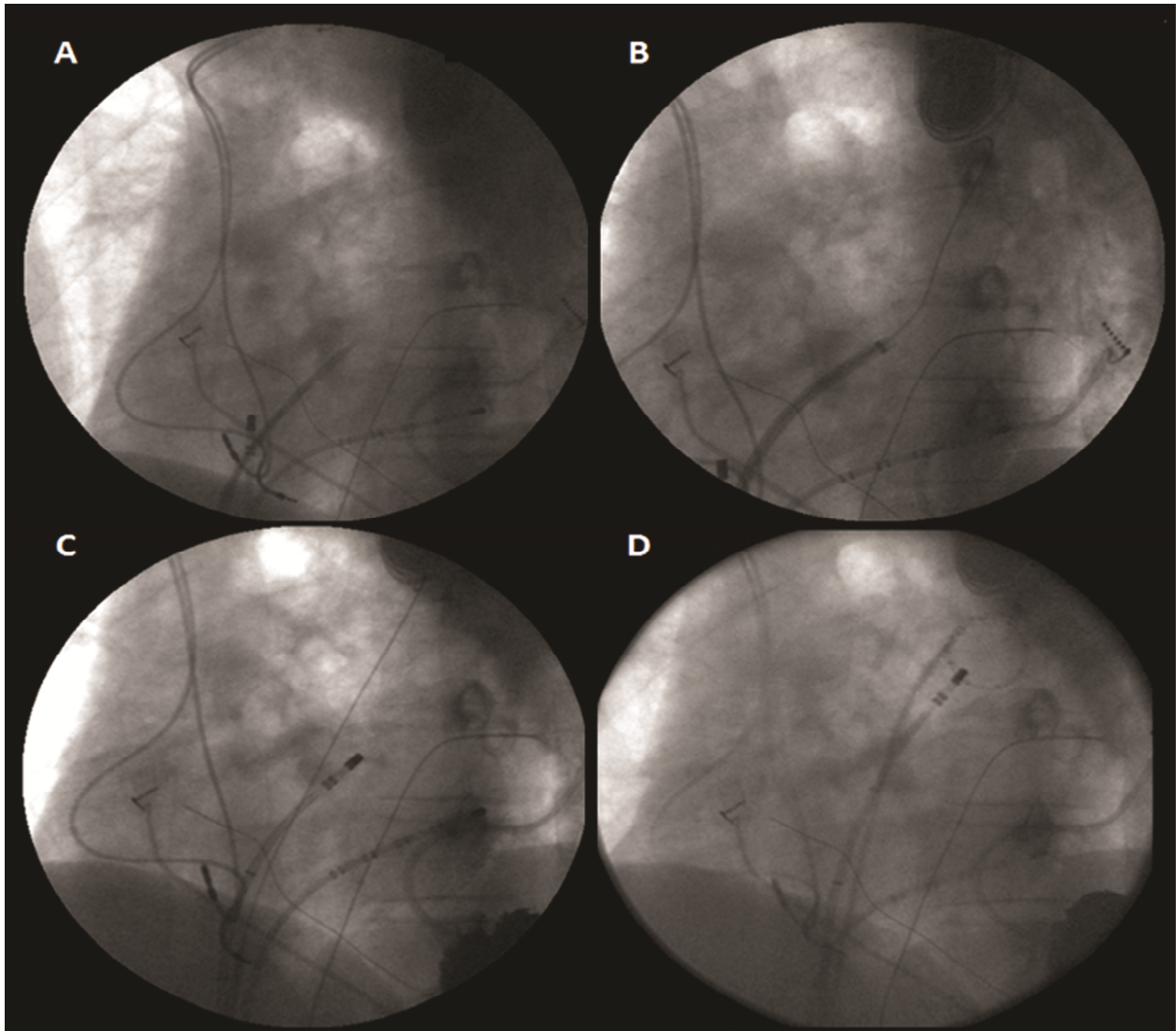
## Figure legends

**Figure 1.** Left atrium was accessed. in absence of a patent foramen ovale. by a guide wire introduced through a single transseptal puncture (panel A) with the use of an 8.5F long sheath and directed towards the left superior pulmonary vein (panel B). The 8F ablation catheter was then advanced into the left atrium. exchanged over the guide wire. through the same hole (panel C) and finally the long sheath was advanced again in the left atrium permitting the introduction of the mapping catheter (panel D).

**Figure 2.** Study flowchart. AFCA. atrial fibrillation catheter ablation; IASD. iatrogenic atrial septal defect; PFO. patent foramen ovale

**Figure 3.** Transesophageal echocardiography 60 degrees mid-esophageal views of the atrial septal before (panel A) and 10 months after (panel B) transcatheter atrial fibrillation ablation showing the presence in the latter of a small iatrogenic atrial septal defect with a not hemodynamically not significant left-right shunt.

Figure 1.



**Figure 2.**

**Figure 3.**