IRIS AperTO

UNIVERSITÀ DEGLI STUDI DI TORINO

AperTO - Archivio Istituzionale Open Access dell'Università di Torino

Response to combined radiotherapy and chemotherapy of a leptomeningeal spread from choroid plexus carcinoma: case report.

This is the author's manuscript

Original Citation:

Availability:

This version is available http://hdl.handle.net/2318/152968 since 2015-07-29T06:02:50Z

Published version:

DOI:10.1007/s10072-014-1983-2

Terms of use:

Open Access

Anyone can freely access the full text of works made available as "Open Access". Works made available under a Creative Commons license can be used according to the terms and conditions of said license. Use of all other works requires consent of the right holder (author or publisher) if not exempted from copyright protection by the applicable law.

(Article begins on next page)

12 October 2024

UNIVERSITÀ DEGLI STUDI DI TORINO

The final publication is available at Springer via http://dx.doi.org/ 10.1007/s10072-014-1983-2

Letter to the Editor

Response to combined radiotherapy and chemotherapy of a leptomeningeal spread from choroid plexus carcinoma: case report

Alessia Pellerino[1]-, Paola Cassoni[2], Renzo Boldorini[3], Lorenzo Pinessi[4] and Roberta Rudà[1]

[1] Department of Neuro-Oncology, University of Turin, Via Cherasco 15, Turin, Italy

[2] Department of Neuropathology, University of Turin, Via Santena 7, Turin, Italy

[3] Department of Neuropathology, University of Piemonte Orientale, Corso Mazzini 18, Novara, Italy

[4] Department of Neuroscience, University of Turin, Via Cherasco 15, Turin, Italy

Alessia Pellerino

Email: alessia.pellerino@alice.it

Dear Editor,

Choroid plexus carcinoma (CPC) is a WHO grade III intraventricular neoplasm that represents 15–20 % of all choroid plexus tumors. Since it mainly occurs in children (representing about 80 % of all CPC), the knowledge of the disease in adult is limited. Surgical resection is a well-established treatment option at diagnosis; however, there are neither a standard adjuvant treatments nor well-defined therapies at progression. Neoplastic meningitis (NM) is an uncommon pattern of recurrence with dismal prognosis, even despite combination of systemic and intrathecal chemotherapy [1, 2].

Case report

In June 2003, a 50-year-old male developed dizziness and progressive gait disturbance. MRI showed an enhancing tumor in the fourth ventricle without any meningeal involvement. After a total surgical resection, the histological examination revealed a CPC (Fig. 1a). MGMT (O6-methylguanine-DNA methyltransferase) promoter was retrospectively analyzed and resulted unmethylated. The patient received adjuvant-involved field radiotherapy (RT) (DFT 42 Gy/21 fractions): the MRI after RT did not show any residual tumor and patient obtained a significant improvement of ataxia lasting until the end of 2010. In January 2011, he developed gait disturbance, loss of strength and radicular pain at L5–S1 on the right side. Spine MRI showed multiple leptomeningeal contrast enhancing lesions (Fig. 2). The patient underwent a C1–C3 laminectomy that confirmed the original histological diagnosis and a lumbar puncture demonstrated malignant cells in the CSF (Fig. 1b). Because of the progressive neurological worsening, the CSF involvement and the presence of a D12–L1 and S1 bulky disease, we treated the patient with an involved-field RT (20 Gy/5 fr) on the bulky disease, followed by 9 cycles of intrathecal ARA-C and 12 cycles of systemic chemotherapy with temozolomide (TMZ) without overlapping toxicities. One month after the start of chemotherapy the patient showed a gradual pain relief, an improvement of the strength of the right side and the Karnofsky performance status progressively improved over time from 50 to 90. CSF cytology became negative while the MRI findings were unchanged. After 12 months of treatment a CSF relapse occurred, but neurological status and neuroimaging findings remained unchanged. In March 2012, TMZ and intrathecal ARA-C were interrupted because of initial signs of hepatotoxicity, however, in July 2014 the patient is still alive.

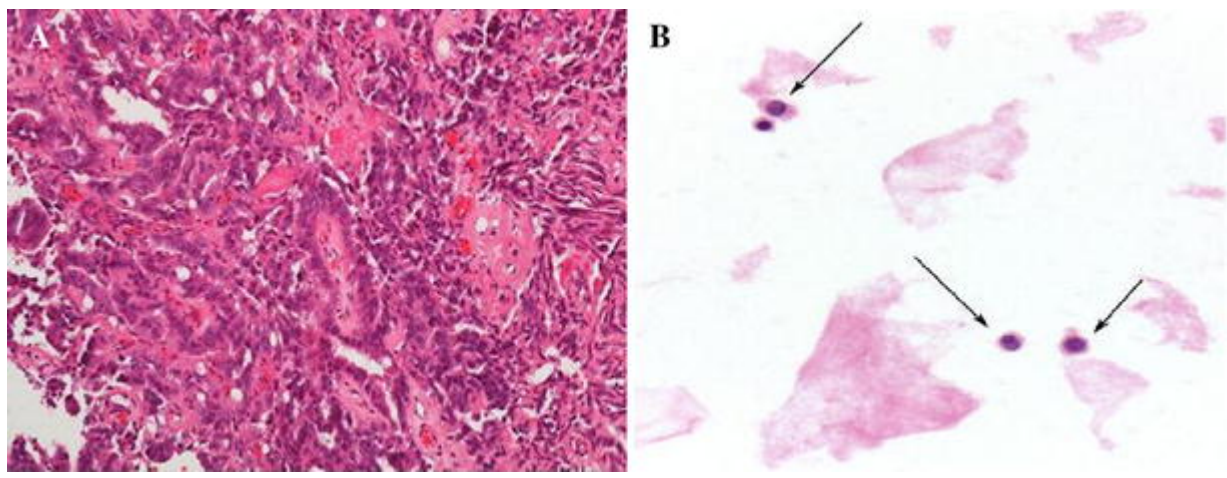

Fig. 1

a Permanent section showing high cellularity, nuclear atypia, poorly structured papillary pattern and an increased mitotic rate, all criteria diagnostic for choroid plexus carcinoma (H&E, original magnification ×20, ×20 and ×40, respectively). b CSF cytology at diagnosis of the neoplastic meningitis: presence of choroid plexus carcinoma cells (one of these in mitotic phase) with prominent nucleoli, chromatin aggregates and large eosinophilic cytoplasm

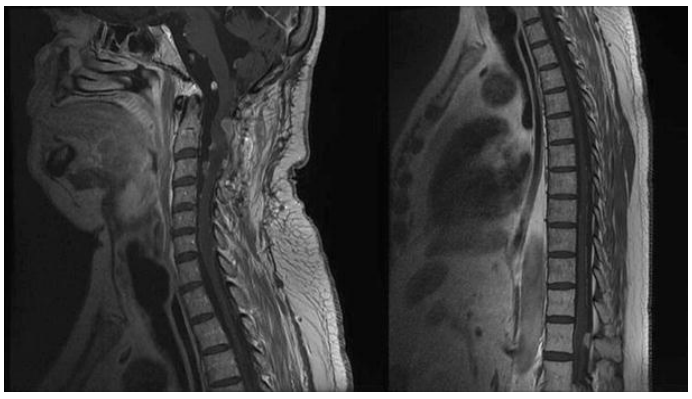

Fig. 2

Multiple nodular and linear enhancing lesions on MRI in the leptomeninges of cervical and dorsal spinal cord at diagnosis

Surgical resection represents the mainstay of therapy for CPC: it can allow an immediate clinical improvement and extent of surgical resection is the most important predictor of PFS. The role of adjuvant RT is still controversial. Several studies report an improvement of the OS and PFS after total and subtotal surgical resection alone. Conversely, some authors suggest craniospinal RT (CSRT) to avoid or delay an early CSF spread [3]; however, as CSRT is associated with a significant risk of neurotoxicity, conformal RT has been proposed as an alternative. A retrospective study comparing the efficacy of adjuvant CSRT versus involved-field RT showed a significant benefit both in terms of PFS and OS for patients treated with CSRT [4]. In our case we chose conformal RT after initial surgery because surgical resection was complete and there was no evidence of dissemination.

When a leptomeningeal spread occurs at tumor progression, involved-field RT on bulky disease has been proposed to obtain a quick palliation of symptoms, remove the blockage of CSF circulation and allow a safe administration of intrathecal chemotherapy. Many different antineoplastic drugs have been employed without a clear advantage of one over the other [5]. A meta-analysis has compared response and survival among patients who received different schedules drugs: the most effective antineoplastic agent appeared to be etoposide [6]. The role of other antineoplastic drugs in addition to etoposide is being investigated. Two choroid plexus papillomas with diffuse NM were treated with TMZ without appreciable changes in the size or distribution of lesions, but both patients had a neurological improvement. Methylation of the MGMT gene promoter, a predictive marker for response to chemotherapy with alkylating agents in glioblastoma, has been found in 58 % of 36 choroid plexus tumors [7], but correlations with TMZ efficacy were not investigated. In one reported-CPC patient with unmethylated MGMT promoter, adjuvant TMZ did not provide any benefit in terms of disease control [8] suggesting that the unmethylated status could predict the lack of response.

Intrathecal ARA-C is approved for the treatment of CNS involvement from hematological malignancies and its use in NM due to primary brain tumors has been reported in few studies only; however, in these series, CPCs have not been included. Up to date only one disseminated CPP was treated with intrathecal ARA-C associated with systemic bleomycin, cysplatinum and etoposide with poor result in term of OS [2].

To best of our knowledge, this is the first report of NM from a CPC with long-lasting neurological and CSF response (11 years) and prolonged survival (>3 years) following a combination of radiotherapy, temozolomide and liposomal cytarabine.

Conflict of interest

There are no conflicts of interest to declare.

References

1. Safaee M, Oh MC, Bloch O, Sun MZ, Kaur G, Auguste KI, Tihan T, Parsa AT (2013) Choroid plexus papillomas: advances in molecular biology and understanding of tumorigenesis. Neuro Oncol 15:255–267

2. Ortega-Martinez M, Cabezudo-Artero JM, Fernandez-Portales I, Pimentel JJ, Gomez de Tejada R (2007) Diffuse leptomeningeal seeding from benign choroid plexus papilloma. Acta Neurochir (Wien) 149:1229–1236

3. Wolff JE, Sajedi M, Coppes MJ, Anderson RA, Egeler RM (1999) Radiation therapy and survival in choroid plexus carcinoma. Lancet 353:2126

4. Mazloom A, Wolff JE, Paulino AC (2010) The impact of radiotherapy fields in the treatment of patients with choroid plexus carcinoma. Int J Radiat Oncol Biol Phys 78:79–845.

Maria BL, Graham ML, Strauss LC, Wharam MD (1985) Response of a recurrent choroid plexus tumor to combination chemotherapy. J Neurooncol 3:259–262

6. Berrak SG, Liu DD, Wrede B, Wolff JE (2011) Which therapy works better in choroid plexus carcinomas? J Neurooncol 103:155–162

7. Hasselblatt M, Muhlisch J, Wrede B, Kallinger B, Jeibmann A, Peters O, Kutluk T, Wolff JE, Paulus W, Fruhwald MC (2009) Aberrant MGMT (O6-methylguanine-DNA methyltransferase) promoter methylation in choroid plexus tumors. J Neurooncol 91:151–155

8. Misaki K, Nakada M, Mohri M, Hayashi Y, Hamada J (2011) MGMT promoter methylation and temozolomide response in choroid plexus carcinoma. Brain Tumor Pathol 28:259–263