

## CASE SERIES

# Are acute subdural hematomas possible without head trauma?

D. Garbossa, R. Altieri, F. M. Calamo Specchia, A. Agnoletti, G. Pilloni, M. Lanotte, R. Spaziante<sup>1</sup>, A. Ducati

Department of Neurosurgery, University of Turin, Turin, <sup>1</sup>Department of Medicine, University of Salerno, Salerno, Italy

## ABSTRACT

Acute subdural hematomas (ASDHs) are rarely reported in the literature. In general, it is due to head trauma, but if the traumatic event is very mild, it is inadequate to explain the ASDH occurrence. Risk factors for the development of spontaneous ASDH include hypertension, vascular abnormalities and deficit of coagulation. We present two cases of ASDH in patients with the coagulation deficit and review of the literature to understand the coagulation factors role and platelet role in the management of ASDHs.

**Key words:** Acute subdural hematomas, anticoagulant therapy, coagulation deficit

## Introduction

Intracranial hemorrhage (ICH) accounts for approximately 10-15% of all cases of stroke, and it is associated with a high mortality rate.<sup>[1]</sup>

Mild traumatic brain injury (TBI) often occurs in elderly patients, many of whom are treated with anticoagulants, which are known to increase the risk of bleeding events.<sup>[2,3]</sup>

Oral anticoagulation therapy (OAT) is associated with a high risk of ICH, even after minor head trauma.<sup>[2,4-8]</sup> As a result, TBI patients with coagulopathy are included in a high-risk group regardless of clinical presentation.<sup>[5,9-12]</sup>

The European Federation of Neurological Societies recommends that patients with a Glasgow coma scale (GCS) of 15 after mild TBI who are over 60 years of age or who are on anticoagulation, need to be admitted to the hospital for 24-h observation.

Posttraumatic ICHs, including epidural hematoma, subdural hematoma (SDH), subarachnoid hemorrhage, intracerebral

hemorrhage, and intraventricular hemorrhage, are usually seen in the initial computed tomography (CT) scan.

Acute subdural hematomas are rarely reported in the literature. They are frequently due to injury at cerebral bridging veins secondary to head trauma.<sup>[13]</sup> ASDHs generally begin to be symptomatic within 72 h and usually occur in young adults.

Spontaneous ASDH is an unusual event, but it is a serious condition. The reported incidences of spontaneous ASDHs relative to total ASDHs have ranged from 2 to 6.7%.<sup>[14-16]</sup>

Risk factors for the development of these hematomas include conditions such as hypertension, vascular abnormalities (such as aneurysm or arteriovenous malformation), or consumption of anticoagulant.<sup>[17]</sup>

Pharmacologic therapy linked with the development of spontaneous ASDH includes especially aspirin,<sup>[14,18]</sup> heparin,<sup>[14]</sup> and warfarin.<sup>[14,19-21]</sup>

Other reports of spontaneous ASDH mention risk factors such as coagulopathies related to coagulation factor deficiencies.<sup>[13,22,23]</sup> Mortality rate has been reported to be between 60% and 76.5%.<sup>[24,25]</sup>

Oral anticoagulation therapy increase the risk of SDH 4-to 15-fold.<sup>[26]</sup> The rate of oral anticoagulant (OAC)-associated SDH is related to the intensity of anticoagulation,<sup>[3]</sup> advanced patient age,<sup>[13]</sup> and perhaps cerebral atrophy.

The absolute rate of SDH can be estimated as approximately 0.2%/y in elderly patients given Oral anticoagulant (OAC) (international normalised ratio [INR] =3).

Access this article online	
Quick Response Code: 	Website: <a href="http://www.asianjns.org">www.asianjns.org</a>
	DOI: 10.4103/1793-5482.146612

## Address for correspondence:

Dr. R. Altieri, Department of Neurosurgery, University of Turin, Turin, Italy. E-mail: [roberto.altieri.87@gmail.com](mailto:roberto.altieri.87@gmail.com)

Infusion of prothrombin complex concentrate appeared to reverse the coagulopathy more rapidly than fresh frozen plasma and was associated with improved outcome in one small study.<sup>[27]</sup>

Early surgical intervention is generally imperative for hematomas with significant mass effect.

The survival rate for surgery within 4 h of acute onset compared with surgery after 4 h is 50-0%, respectively.<sup>[25]</sup> Other favorable variables include a high GCS score upon admission, appropriate pupillary reactivity, and young age.<sup>[25]</sup>

We present two cases of ASDH in patients with the coagulation deficit:

- Female patient with a history of alcoholic cirrhosis
- Male patient with a history of cardiac surgery in OAC.

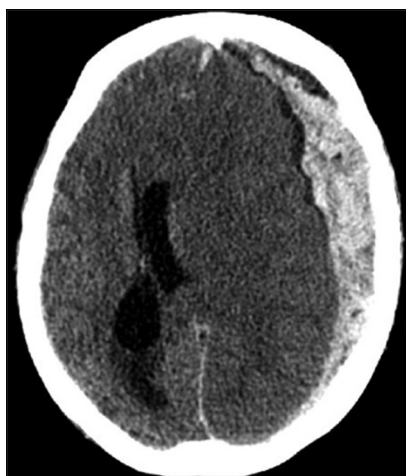
The female patient, aged 59 arrived in an emergency room of our hospital at 9.30 a.m.

On admission to the hospital, the patient presented loss of consciousness, isocoria, midriasis and appropriate pupillary reactivity, decerebration extension at pain response, GCS 5 (E1, V1, M3).

Patient's husband referred a mild TBI after fall at 11.30 p.m. of the day before, history of alcoholic cirrhosis, HBV- and HCV-, with esophageal varix (Grade I), severe platelet deficiency in pancitopenia.

In an emergency room, the anesthesiologist stabilized the patient.

Patient underwent to the neuroimaging examination. CT scan showed acute subdural hematoma (ASDH) on left cerebral hemisphere with important midline structure shift, edema and indirect signs of ischemia [Figure 1]. The patient was diagnosed with ASDH.



**Figure 1:** Computed tomography scan shows acute subdural hematoma on left cerebral hemisphere with important midline structure shift, edema and indirect signs of ischemia

After diagnosis patient was treated with a liquid infusion, Vitamin K, Voluven and proton pump inhibitor drugs before neurosurgical operation.

Decompressive pterional craniotomy was performed, and SDH was removed [Figure 2]. During the operation occurred hematemesis and melena. These events required hemotransfusion and endoscopic hemostasis of esophago-gastric bleeding.

She was conducted in the resuscitation room, and she died 2 days later for cardiac arrest.

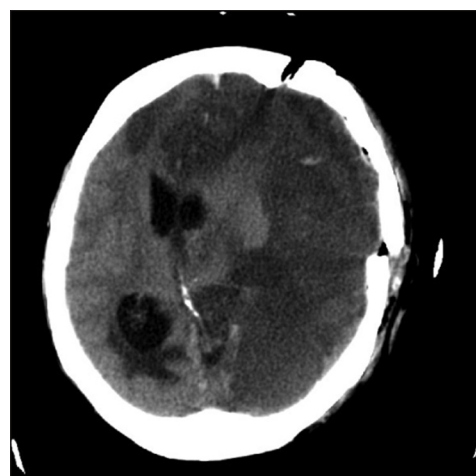
A male patient, 58-year-old, arrived in an emergency room of our hospital complaining an increasing headache, dizziness and vomiting.

On admission to the hospital, he referred a history of cardiac surgery for mitral valve replacement in 2008 and medical therapy with coumadin - 5 mg and cordarone - 20 mg. He denied recent trauma. At neurological examination he was disoriented, confused, presented isocoria and absence of focal deficits. Patient underwent to neuroimaging examination. CT scan showed bilateral ASDH in fronto-temporo-parietal region more thickness in the left hemisphere, compressive effect on sovratentorial ventricular system and edema [Figure 3].

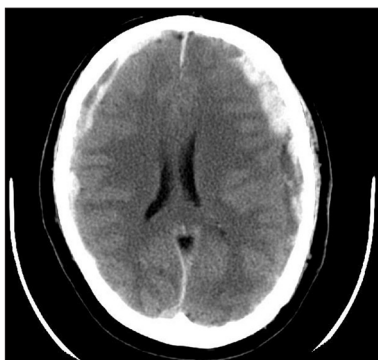Coagulation parameters showed: INR = 2.98, aPtt = 51.3 s., derivated fibrinogen = 491 mg/dl, platelet = 116000/mm<sup>3</sup>.

Neurosurgical operation was delayed for preservation of consciousness state and presence of coagulative deficiency. The patient was treated with physiology and the electrolytic solution, Fenobarbital, Amiodarone and LMWE to replace OAT and adjust coagulative abset.

The day after INR was 2.79, aPtt = 49.6 s., fibrinogen = 579 mg/dl, platelet = 117000/mm<sup>3</sup>.



**Figure 2:** Computed tomography scan of the brain after surgery



**Figure 3:** CT scan showed bilateral ASDH

In the fourth hospitalization day his coagulation parameters were INR = 1.40, activated partial thromboplastin time (aPTT) = 34.4 s., fibrinogen = 663 mg/dl, platelet = 114000/mm<sup>3</sup>. Because of consciousness falling, he retried a CT scan that showed an increase of the hematoma. For these reasons he was immediately treated with a neurosurgical operation.

## Methodology

We report two cases of ASDH in uncoagulated patients:

- Female patient, 59-year-old, history of cirrhosis
- Male patient, 58-year-old, history of mitral valve replacement.

A literature search using PubMed MEDLINE database has been performed. The search terms “nontraumatic ASDH,” “spontaneous ASDH,” were combined with the following terms: “Platelet deficit,” “coagulation deficit.”

## Discussion

In this review of the literature, we compared the incidence of platelet deficiency with dysfunction of coagulation factors in ASDHs.

All conditions resulting in a low platelet count can predispose a patient to ICH. Thrombocytopenia has multiple causes, and one common classification scheme is as follows:

- Decreased platelet production, as seen in certain congenital disorders and cases of bone marrow damage (due to radiation, drugs)
- Increased platelet destruction
- Abnormal sequestration, usually in the spleen, as in cirrhosis
- Multiple causes, as commonly seen in alcoholics.

Intracranial hemorrhage cases induced by thrombocytopenia have been linked to use of certain drugs, as well as to uremia, alcohol use, and liver transplants.

A large number of abnormalities of hemostasis were demonstrated in alcoholics patients.

Thrombocytopenia in these patients is due to associated folate deficiency, splenic sequestration and direct toxic effects of alcohol on the bone marrow. Numerous functional deficits have also been described in the platelets of alcoholics, which are associated with disturbances in ultrastructural morphology.<sup>[28]</sup>

The largest study to date on alcohol use and ICH were conducted by the Honolulu Heart Program, which followed 8006 men between 1965 and 1977 in a prospective study of cardiovascular disease.

Data results further indicated that the alcohol had a greater effect on ICH that were subarachnoid in origin, conferring a 3-4-fold increased risk for moderate and heavy drinkers compared with nondrinkers.<sup>[29]</sup> No study was conducted to verify the incidence of ASDHs in alcoholics.

A lot of drugs have been associated with thrombocytopenia, including certain cytotoxic drugs, antimalarial agents, antiepileptic medications, furosemide, digoxin, and estrogens.<sup>[30]</sup> Any of these drugs could theoretically cause thrombocytopenia that could in turn contribute to ICH in a patient, especially one with other risk factors.

In a 1995 review, Hart, *et al.*, suggested that anticoagulation to a “therapeutic” INR of 2.5-4.5 increases annual risk of ICH by 7-10-fold, to an absolute rate of nearly 1% for high-risk patient groups. Evaluation of individual large series shows great variation in the incidence of anticoagulation-treated patients in whom ICH is a complication, with annual incidences ranging from 0.1% in a 1974 study of 3862 patients to 2.2% in a 1993 study of 186 patients.<sup>[31]</sup>

The most common antiplatelet agent in the world is aspirin. Aspirin works by irreversibly inactivating the enzyme cyclooxygenase, which results in decreased production of the natural platelet aggregate thromboxane A<sub>2</sub>.<sup>[32]</sup> The aspirin therapy is indicated for primary or secondary stroke prevention and primary myocardial infarction prevention, may slightly increase the low baseline risk of ICH, but the increased risk is usually outweighed by the benefits of aspirin.

Aspirin-related ICH has been studied in detail.

The first suggestion that increased incidence of ICH might be a complication in aspirin users is found in Physician’s Health Study, which reported 23 hemorrhagic strokes among 11,037 individuals receiving low-dose aspirin (325 mg every other day) compared with 12 hemorrhagic strokes in 11,034 individuals receiving placebo. This finding was considered noteworthy but of borderline statistical significance ( $P = 0.06$ ).<sup>[33]</sup>

In addition to aspirin, other antiplatelet agents that have grown in popularity in recent years include clopidogrel,<sup>[34]</sup>

abciximab,<sup>[35]</sup> as well as aspirin combined with extended-release dipyridamole.<sup>[36]</sup> Clopidogrel, abciximab, and dipyridamole all act as glycoprotein IIb/IIIa inhibitors in slightly different ways and have different indications [Table 1].

In a small number of studies, the authors have examined the risk of ICH in patients receiving these newer antiplatelet agents.

The most comprehensive data are derived from a metaanalysis conducted by Memon *et al.*,<sup>[37]</sup> in which the authors evaluated 14 randomized trials of intravenous platelet glycoprotein IIb/IIIa receptor inhibitors. The results of the aforementioned metaanalysis, while suggesting that intravenous glycoprotein IIb/IIIa inhibitors did not increase the risk of ICH in anticoagulant-treated patients, failed to provide information on the incidence of hemorrhagic stroke in patients receiving oral formulations of the medications alone. The authors also compared glycoprotein IIb/IIIa inhibitors with a more commonly used antiplatelet agent: Aspirin.

Analysis of current data suggests that the newer antiplatelet agents discussed thus seem to be associated with an ICH risk profile similar to that of aspirin.

Warfarin, heparin, and enoxaparin are currently the most commonly used anticoagulants.

Warfarin is an OAC that interferes with vitamin K metabolism in the liver and results in the synthesis of nonfunctional coagulation factors II, VII, IX, and X, as well as proteins C and S.

Warfarin thus prolongs the PT and is monitored by assessing a standardized form of this test known as the INR.

Heparin, on the other hand, is a parenterally administered anticoagulant agent that acts by potentiating the action of both antithrombin III and tissue factor pathway inhibitor (TFPI), thus prolonging the PTT.<sup>[38]</sup>

Enoxaparin is the most commonly used member of a relatively new class of anticoagulants known as low molecular weight heparins. It is obtained by alkaline degradation of heparin benzyl ester and is approximately one third the molecular size of standard heparin. The mechanism of action of enoxaparin is similar to that of heparin, although enoxaparin has a longer half-life (4.5 compared with 1.1 h) and does not require PTT monitoring.<sup>[39,40]</sup>

Anticoagulation-related bleeding is clinically similar for each of the aforementioned drugs and accounts for 10-20% of all ICHs in different series.<sup>[41-43]</sup> Furthermore, ICH is the most dreaded and least treatable complication of anticoagulation therapy.<sup>[44]</sup>

Aspirin appears to double the risk for ICH, regardless of the dose.<sup>[45]</sup> The combination of aspirin with warfarin probably increases the risk for ICH over similar intensities of anticoagulation without aspirin (pooled data from four randomized trials of OACs show 15 ICHs with aspirin 100-1000 mg/d versus 7 without aspirin).<sup>[31]</sup>

In the second Stroke Prevention in Atrial Fibrillation study, investigators showed that the occurrence of ICH actually negated the reduction in ischemic stroke among older hypertensive patients receiving warfarin.<sup>[46]</sup>

Approximately, 70% of ICH episodes associated with anticoagulation consist of intraparenchymal (cerebral) hemorrhage, whereas most of the remainder are SDHs.<sup>[3]</sup>

## Conclusion

Coagulation and/or bleeding disorders account only for a small but significant risk factor associated with ICH. Blood coagulation and platelet-mediated hemostasis are the two important defense mechanisms against bleeding.

Anticoagulant mechanisms ensure careful control of coagulation and under normal conditions, prevail over the procoagulant forces. In the CNS, however, an imbalance between pro- and anticoagulant systems due to inherited or acquired factors may result in bleeding or thrombotic diseases.

Spontaneous ASDH is a nosological entity rare but extremely serious. In our view it would be appropriate to perform a series of study to understand the most appropriate medical therapy in the management of disease: Is more useful adjust platelet deficiency, coagulation factors disorder, or both?

## References

1. Quinones-Hinojosa A, Gulati M, Singh V, Lawton MT. Spontaneous intracerebral hemorrhage due to coagulation disorders. *Neurosurg Focus* 2003;15:E3.
2. Ferrera PC, Bartfield JM. Outcomes of anticoagulated trauma patients. *Am J Emerg Med* 1999;17:154-6.
3. Hylek EM, Singer DE. Risk factors for intracranial hemorrhage in outpatients taking warfarin. *Ann Intern Med* 1994;120:897-902.
4. Fabbri A, Vandelli A, Servadei F, Marchesini G. Coagulopathy and

**Table 1: Anticoagulation/Antiplatelet Therapy**

Drug	Mechanism of action	Target
Aspirin	Inhibitor of cyclooxygenase	Platelet
Clopidogrel, abciximab, dipyridamole	Inhibitor of glycoprotein IIb/IIIa	Platelet
Warfarin	Vitamine K liver metabolism	Coagulation factors II, VII, IX and X
Heparin	Potentialiation of antithrombin III and TFPI	Antithrombin III inhibit thrombin, coagulation factor IX, X, XI, XII and kallikrein. TFPI inhibit trombin, coagulation factor VII, X
Enoxaparin	Potentialiation of antithrombin III and TFPI	Antithrombin III inhibit thrombin, coagulation factor IX, X, XI, XII and kallikrein. TFPI inhibit trombin, coagulation factor VII, X

TFPI – Tissue factor pathway inhibitor

Garbossa, *et al.*: Spontaneous acute subdural hematomas

- NICE recommendations for patients with mild head injury. *J Neurol Neurosurg Psychiatry* 2004;75:1787-8.
5. Gómez PA, Lobato RD, Ortega JM, De La Cruz J. Mild head injury: Differences in prognosis among patients with a Glasgow Coma Scale score of 13 to 15 and analysis of factors associated with abnormal CT findings. *Br J Neurosurg* 1996;10:453-60.
  6. He J, Whelton PK, Vu B, Klag MJ. Aspirin and risk of hemorrhagic stroke: A meta-analysis of randomized controlled trials. *JAMA* 1998;280:1930-5.
  7. Li J, Brown J, Levine M. Mild head injury, anticoagulants, and risk of intracranial injury. *Lancet* 2001;357:771-2.
  8. Linkins LA, Choi PT, Douketis JD. Clinical impact of bleeding in patients taking oral anticoagulant therapy for venous thromboembolism: A meta-analysis. *Ann Intern Med* 2003;139:893-900.
  9. Arianta C, Caroli M, Balbi S. Management of head-injured patients in the emergency department: A practical protocol. *Surg Neurol* 1997;48:213-9.
  10. Atzema C, Mower WR, Hoffman JR, Holmes JF, Killian AJ, Oman JA, *et al.* Defining "therapeutically inconsequential" head computed tomographic findings in patients with blunt head trauma. *Ann Emerg Med* 2004;44:47-56.
  11. Borczuk P. Predictors of intracranial injury in patients with mild head trauma. *Ann Emerg Med* 1995;25:731-6.
  12. Ibañez J, Arikian F, Pedraza S, Sánchez E, Poca MA, Rodríguez D, *et al.* Reliability of clinical guidelines in the detection of patients at risk following mild head injury: Results of a prospective study. *J Neurosurg* 2004;100:825-34.
  13. Vural M, Yazar C, Durmaz R, Atasoy MA. Spontaneous acute subdural hematoma and chronic epidural hematoma in a child with F XIII deficiency. *J Emerg Med* 2010;38:25-9.
  14. Depreitere B, Van Calenbergh F, van Loon J. A clinical comparison of non-traumatic acute subdural haematomas either related to coagulopathy or of arterial origin without coagulopathy. *Acta Neurochir (Wien)* 2003;145:541-6.
  15. Komatsu Y, Uemura K, Yasuda S, Shibata T, Kobayashi E, Maki Y, *et al.* Acute subdural hemorrhage of arterial origin: Report of three cases. *No Shinkei Geka* 1997;25:841-5.
  16. Nakagawa O. The cases of acute spontaneous subdural hematoma. *No Shinkei Geka* 1996;24:665-9.
  17. Fryburg K, Nguyen HS, Cohen-Gadol AA. Spontaneous acute subdural hematoma due to fondaparinux: Report of two cases. *Surg Neurol Int* 2011;2:44.
  18. O'Brien DF, Basu S, O'Donnell JR, Roberts GA, Phillips J. The impact of aspirin therapy and anticoagulation on the prevalence of spontaneous subdural haematoma. *Ir Med J* 2000;93:244-6.
  19. Ahn ER, Lander G, Bidot CJ, Jy W, Ahn YS. Long-term remission from life-threatening hypercoagulable state associated with lupus anticoagulant (LA) following rituximab therapy. *Am J Hematol* 2005;78:127-9.
  20. Pal D, Gnanalingham K, Peterson D. A case of spontaneous acute subdural haematoma in the posterior fossa following anticoagulation. *Br J Neurosurg* 2004;18:68-9.
  21. Veshchev I, Elran H, Salame K. Recombinant coagulation factor VIIa for rapid preoperative correction of warfarin-related coagulopathy in patients with acute subdural hematoma. *Med Sci Monit* 2002;8:CS98-100.
  22. Agrawal D, Mahapatra AK. Spontaneous subdural hematoma in a young adult with hemophilia. *Neurol India* 2003;51:114-5.
  23. Balak N, Silav G, Kiliç Y, Timur C, Elmaci I. Successful surgical treatment of a hemophilic infant with nontraumatic acute subdural hematoma. *Surg Neurol* 2007;68:537-40.
  24. Arianta C, Ceretti L, Caroli M, Villani R. Acute spontaneous subdural hematomas. *J Neurosurg Sci* 1986;30:197-204.
  25. Missori P, Fenga L, Maraglino C, Rocchi G, Nardacci B, Calderaro G, *et al.* Spontaneous acute subdural hematomas. A clinical comparison with traumatic acute subdural hematomas. *Acta Neurochir (Wien)* 2000;142:697-701.
  26. Mattle H, Kohler S, Huber P, Rohner M, Steinsiepe KF. Anticoagulation-related intracranial extracerebral haemorrhage. *J Neurol Neurosurg Psychiatry* 1989;52:829-37.
  27. Fredriksson K, Norrving B, Strömlblad LG. Emergency reversal of anticoagulation after intracerebral hemorrhage. *Stroke* 1992;23:972-7.
  28. Cowan DH. Effect of alcoholism on hemostasis. *Semin Hematol* 1980;17:137-47.
  29. Donahue RP, Abbott RD, Reed DM, Yano K. Alcohol and hemorrhagic stroke. The Honolulu Heart Program. *JAMA* 1986;255:2311-4.
  30. Burstein SA, Harker LA. Quantitative platelet disorders. In: Bloom AL, Thomas DP, editors. *Haemostasis and Thrombosis*. Edinburgh: Churchill Livingstone; 1981. p. 279-300.
  31. Turpie AG, Gent M, Laupacis A, Latour Y, Gunstensen J, Basile F, *et al.* A comparison of aspirin with placebo in patients treated with warfarin after heart-valve replacement. *N Engl J Med* 1993;329:524-9.
  32. Vane JR. Inhibition of prostaglandin synthesis as a mechanism of action for aspirin-like drugs. *Nat New Biol* 1971;231:232-5.
  33. Final Report on the Aspirin Component of the Ongoing Physicians' Health Study. Steering Committee of the Physicians' Health Study Research Group. *N Engl J Med* 1989;321:129-35.
  34. D'Sa S, Machin SJ. Clopidogrel: A novel antiplatelet agent. *Hosp Med* 1999;60:362-3.
  35. Anderson KM, Califf RM, Stone GW, Neumann FJ, Montalescot G, Miller DP, *et al.* Long-term mortality benefit with abciximab in patients undergoing percutaneous coronary intervention. *J Am Coll Cardiol* 2001;37:2059-65.
  36. Wilterdink JL, Easton JD. Dipyridamole plus aspirin in cerebrovascular disease. *Arch Neurol* 1999;56:1087-92.
  37. Memon MA, Blankenship JC, Wood GC, Frey CM, Menapace FJ. Incidence of intracranial hemorrhage complicating treatment with glycoprotein IIb/IIIa receptor inhibitors: A pooled analysis of major clinical trials. *Am J Med* 2000;109:213-7.
  38. Hampton KK, Preston FE. ABC of clinical haematology. Bleeding disorders, thrombosis, and anticoagulation. *BMJ* 1997;314:1026-9.
  39. Bara L, Samama M. Pharmacokinetics of low molecular weight heparins. *Acta Chir Scand Suppl* 1988;543:65-72.
  40. Spencer FA, Ball SP, Zhang Q, Liu L, Benoit S, Becker RC. Enoxaparin, a low molecular weight heparin, inhibits platelet-dependent prothrombinase assembly and activity by factor-Xa neutralization. *J Thromb Thrombolysis* 2000;9:223-8.
  41. Kase CS. Intracerebral hemorrhage: Non-hypertensive causes. *Stroke* 1986;17:590-5.
  42. Mohr JP, Caplan LR, Melski JW, Goldstein RJ, Duncan GW, Kistler JP, *et al.* The Harvard Cooperative Stroke Registry: A prospective registry. *Neurology* 1978;28:754-62.
  43. Yarnell P, Earnest M. Primary non-traumatic intracranial hemorrhage. A municipal emergency hospital viewpoint. *Stroke* 1976;7:608-10.
  44. Landefeld CS, Goldman L. Major bleeding in outpatients treated with warfarin: Incidence and prediction by factors known at the start of outpatient therapy. *Am J Med* 1989;87:144-52.
  45. Hart RG, Pearce LA. *In vivo* antithrombotic effect of aspirin: Dose versus nongastrointestinal bleeding. *Stroke* 1993;24:138-9.
  46. Warfarin versus aspirin for prevention of thromboembolism in atrial fibrillation: Stroke Prevention in Atrial Fibrillation II Study. *Lancet* 1994;343:687-91.

**How to cite this article:** Garbossa D, Altieri R, Calamo Specchia FM, Agnoletti A, Piloni G, Lanotte M, *et al.* Are acute subdural h! ematomas possible without head trauma?. *Asian J Neurosurg* 2014;9:218-22.

**Source of Support:** Nil, **Conflict of Interest:** None declared.