

AperTO - Archivio Istituzionale Open Access dell'Università di Torino

Spontaneous Age-related Changes of Peripheral Nerves in Cattle: Morphological and Biochemical Studies

This is the author's manuscript

Original Citation:

Availability:

This version is available <http://hdl.handle.net/2318/1523790> since 2017-03-27T14:55:22Z

Published version:

DOI:10.1111/ahe.12177

Terms of use:

Open Access

Anyone can freely access the full text of works made available as "Open Access". Works made available under a Creative Commons license can be used according to the terms and conditions of said license. Use of all other works requires consent of the right holder (author or publisher) if not exempted from copyright protection by the applicable law.

(Article begins on next page)



UNIVERSITÀ DEGLI STUDI DI TORINO

This is an author version of the contribution published on:

Questa è la versione dell'autore dell'opera:

Anatomia, Histologia, Embryologia, 2015, doi: 10.1111/ahe.12177

AUTORI: E. Biasibetti, D. Bisanzio, S. Mioletti, S. Amedeo, A. Iuliano, P. Bianco and M. T. Capucchio

EDITORE: Wiley, 2015, pagg.1-9.

The definitive version is available at:

La versione definitiva è disponibile alla URL

[<http://onlinelibrary.wiley.com/doi/10.1111/ahe.12177/epdf>]

Spontaneous Age-related Changes of Peripheral Nerves in Cattle: Morphological and Biochemical Studies

E. Biasibetti^{1*}, D. Bisanzio², S. Mioletti¹, S. Amedeo¹, A. Iuliano¹, P. Bianco³ and M. T. Capucchio¹

Addresses of authors:¹Department of Veterinary Sciences, University of Torino, Largo Braccini 2, 10095 Grugliasco, Torino, Italy;

² Department of Environmental Sciences, Emory University, 400 Dowman Drive, Atlanta, GA 30322, USA;

³ ASLTo4, via Po 11, 10034 Chivasso, Torino, Italy

*Correspondence:

Tel.: +39 01 167 09035;

Fax: +39 01 167 09031;

e-mail: elena.biasibetti@unito.it

doi: 10.1111/ahc.12177

Summary

Peripheral nerve function is significantly affected by ageing. During ageing process, multiple changes occur on tissue cells and extracellular matrix. The aim of this work was to study the ageing-associated changes of peripheral nerves in adult and old regularly slaughtered cattle compared with young calves, and correlate them to the features reported in humans and laboratory animals. Samples of axial dorsal metacarpal nerves from 44 cows were collected immediately after slaughtering. Each nerve was dissected and divided into two fragments: one used for morphological evaluation (n = 43) and the other one for biochemical analysis (n = 31). Axonal degeneration, demyelination, thickness of perineurium and endoneurium and increase of mast cells were the most important features detected. The mean amount of glycosaminoglycan quantitative content recorded in the samples increased with the age. Axonal degeneration, demyelination and thickness of endoneurium were positively and significantly correlated with biochemistry. The presence of changes affecting the different elements of the peripheral nerves, similar to that reported in humans and in laboratory species, the easy availability of the nerve tissue in this species, the considerable size of the samples and the life conditions more similar to humans than to laboratory animals, allows the authors to consider cattle as a potential good model for the comparative study of spontaneous ageing nerve lesions.

Introduction

Peripheral nerve function is significantly affected by ageing. During ageing process, multiple changes occur on tissue cells and extracellular matrix that have negative effects on the functional capacities of elderly patients (Bahcelioglu et al., 2008). Functional deficits may be the consequence of a loss of nerve fibres (Knox et al., 1989; Behse, 1990; Hashizume and Kanda, 1995), myelin abnormalities (Stanmore et al., 1978; Sharma et al., 1980; Chase et al., 1992; Majeed, 1992), and alterations in nerve connective tissue and vascularization (Knox et al., 1989; Ceballos et al., 1999).

Spontaneous changes in myelin structure and composition have been noticed in ageing rat (Knox et al., 1989; Sugiyama et al., 2002), monkey (Sandell and Peters, 2001; Peters and Sethares, 2002; Sloane et al.,

2003) and human brains (Albert, 1993), and they are hypothesized to mediate age-related cognitive decline (Hinman et al., 2006).

In humans, peripheral nerve lesions were correlated to motor unit loss, axonal atrophy and demyelination caused by oxidative damage to proteins and lipids, and modified transmission of the electrical signal through the neuromuscular junction (Manini et al., 2013). In humans, the conduction velocity rate keeps stable until approximately 30 years of age after which it is subjected to a slow decline. The rate of change has been estimated to decline by 10% from 30 to 60 years of age. Several studies have demonstrated that, with increasing age, there are both a decreased sensory and motor conduction velocity in normal individuals (Werner et al., 2012).

Degenerative lesions have been observed also in the dorsal and ventral roots of the spinal nerves in age

rats (Berg et al., 1962; Vans Teenis and Kroes, 1971; Gilmore, 1972; Burek et al., 1976). These lesions usually begin to appear at around 18 months of age, but are more frequent and severe after 24 months of age. The lesions include segmental demyelination, in both presence and absence of axonal degeneration, macrophage activity and usually little Schwann's cell proliferation.

Abundant mast cells are also observed in addition to a macrophagic response in those nerves showing degenerating lesions. However, their specific role in the ageing degenerative lesions of peripheral nerves remains to be clarified (Vans Teenis and Kroes, 1971; Cotard-Bartley et al., 1981).

Ageing-related changes were also observed in peripheral nerves of mice, and they showed similarity to those described in rats (Goss et al., 2011).

Numerous studies were performed on ageing-associated peripheral nerve disorders in humans and several laboratory animals, but, to our knowledge, no studies on livestock animals have been carried out so far.

Livestock animals represent a potential model to study human diseases because they provide some advantages, as, for example, to be easy to handle, and may share a common environment with humans. Cattle in particular are considered important spontaneous animal models for the understanding of several human infectious diseases such as tuberculosis (Waters et al., 2014), Crohn's disease (Patterson and Allen, 1972) and respiratory syncytial virus infection (Taylor, 2013).

The anatomical size and physiology of the bovine heart and thorax are appropriate to study novel interventions for the clinical management of human heart failure (Bartoli et al., 2013). Moreover, cattle represent a naturally occurring animal model also of Marfan syndrome, an autosomal dominant disorder of the connective tissue characterized by abnormal fibrillin synthesis/processing and abnormal incorporation of fibrillin into the extracellular matrix (Hirano et al., 2012). Study on this spontaneous model has contributed significantly to our understanding of the molecular pathogenesis of these pathologies and provide an important resource for testing new drug therapies.

On the basis of author's knowledge, no morphological or biochemical investigations have been performed on peripheral nerves of healthy adult cattle.

The aim of this work was to study the ageing-associated changes of peripheral nerves in adult and old regularly slaughtered cattle compared with young calves, and to correlate them to the features reported in humans and laboratory animals. The final aim was to evaluate the potential usefulness of cattle as a model for human ageing lesions.

Materials and Methods

The study was performed in accordance with animal welfare regulations (93/119/EC).

Samples of nerves (axial dorsal metacarpal) from 44 cows (32 from 10 to 20 years old and 12 from 12 to 29 months old) were collected immediately after slaughtering at public abattoir (Fig. 1a). Anamnestic data of these animals are described in Table 1. None of these animals reported neuromuscular clinical signs. Each nerve was dissected and divided into two fragments: one used for morphological evaluation ($n = 43$) and the other one for biochemical analysis ($n = 31$).

The samples were separated in three groups based on the animal age classification: group 1 ($n = 16$ animals from 10 to 13 years old, mean age: 11 years); group 2 ($n = 15$ animals from 14 to 20 years old; mean age: 16 years); and group 3 ($n = 12$ animals from 12 to 29 months; mean age: 18 months) which was considered as the control group.

Morphological investigations

To perform the morphological evaluation, nerve samples were fixed for 2 h in 2.5% glutaraldehyde (Weis et al., 2012) and stored at 4°C in 2.5% glutaraldehyde – 4% paraformaldehyde in cacodylate buffer 0.08 m, pH 7.4 (Sandell and Peters, 2001).

Segments of 3 mm in length were then cut, post-fixed in OsO₄ (1%, 2 h), dehydrated through an ascending series of acetone (30, 60, 90 and 100%) for 30 min each and Spurr resin-embedded. From each sample, using the ultramicrotome, semithin sections (0.80 μ m) were obtained and stained with toluidine blue and toluidine blue polychrome (Fig. 1b) (Weis et al., 2012).

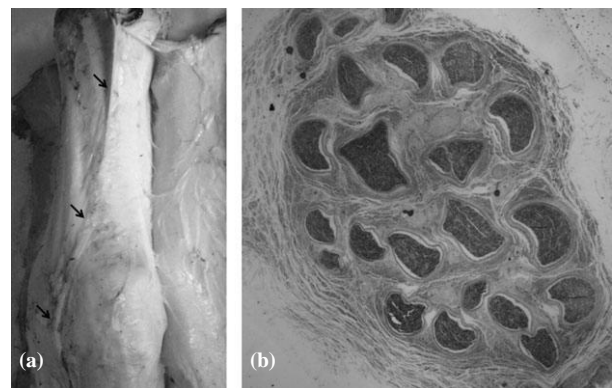


Fig. 1. (a) Dorsal vision of metacarpal articulation, arrow: course of the nerve. (b) Semithin section of axial dorsal metacarpal nerve, toluidine blue stain, 29.

Table 1. Anamnestic data of the animals

Group 1			Group 2			Group 3		
Age (years)	Breed	Sex	Age (years)	Breed	Sex	Age (months)	Breed	Sex
10	Mix breed	F	14	Piedmontese	F	18	Blonde Aquitaine	M
10	Mix breed	F	14	Piedmontese	F	12	Blonde Aquitaine	M
10	Piedmontese	F	15	Mix breed	F	29	Pezzata rossa	M
11	Mix breed	F	15	Mix breed	F	21	Mix breed	M
11	Mix breed	F	15	Pezzata rossa	F	12	Mix breed	M
11	Mix breed	F	15	Mix breed	F	14	Piedmontese	M
11	Piedmontese	F	15	Grigia Alpina	F	19	Mix breed	M
11	Mix breed	F	16	Mix breed	F	17	Piedmontese	F
11	Piedmontese	F	16	Mix breed	F	14	Piedmontese	M
12	Piedmontese	F	16	Mix breed	F	22	Piedmontese	F
12	Mix breed	F	17	Holstein Friesian	F	20	Piedmontese	M
12	Piedmontese	F	17	Piedmontese	F	17	Piedmontese	M
12	Piedmontese	F	17	Piedmontese	F			
13	Piedmontese	F	17	Piedmontese	F			
			18	Mix breed	F			
			18	Pezzata rossa	F			
			20	Pezzata rossa	F			

All the slide sections were then examined under a light microscope by three pathologists.

The severity of microscopical lesions (axonal degeneration, demyelination, increase in perineurium thickness and increase in endoneurium) was classified using the following semiquantitative scoring system: no lesions (0), a low number of focal to multifocal lesions (1), a moderate number of lesions, disseminated through one or more areas (2) or diffuse and severe lesions (3) (Fig 2a,b).

The number of mast cells was counted in five fields (409 – 81 500 mm^2). The median value was calculated.

Biochemical investigations

Biochemical investigations were performed on 31 samples only (nine of group 1, 11 of group 2 and 11 of group 3) because of insufficient tissue sample availability.

Total glycosaminoglycan extraction

For biochemical investigations, tissues were weighted, defatted twice with a mixture of chloroform: methanol (2:1, v/v) and centrifuged, and the resulting pellet was dried in air overnight in acetone. Weighted samples were homogenized in two volumes of distilled water, using a Polytron (Kinematica, Luzern, Switzerland) for 3 min at maximum speed. Proteins were digested by incubation on each occasion with papain (Merck Millipore, Darmstadt, Germany) for 48 h at 40°C. A few drops of octanoic acid were added to prevent bacterial growth. After centrifugation at 11 600 g for 20 min, the supernatant was brought to 7% trichloroacetic acid, held for 1 h at 4°C and centrifuged at 11 600 g for 20 min. The supernatant was diluted with four

volumes of cold ethanol containing 1 per cent potassium acetate, stored overnight at -20°C and centrifuged at 11 600 g for 10 min. The precipitated glycosaminoglycans (GAGs) were finally dissolved in a volume of distilled water proportional to the dry weight of the nerves (Castagnaro et al., 1997).

Quantitative analysis of GAG

The GAGs were analysed quantitatively by the carbazole method (Bitter and Muir, 1962), using glucuronolactone as a standard. The concentration was expressed as microgram uronic acid per milligram of dry tissue.

Statistical analysis

The difference of biochemical results among the groups was tested using one-way ANOVA and by multiple comparisons using the post hoc test Tukey's HSD. The one-way Kruskal–Wallis test and post hoc pairwise Wilcoxon's rank sum tests were performed to investigate differences among the groups when the data did not follow the normal distribution. Correlation among lesion score, perivascular mast cell counts and biochemical results was tested by Spearman's rank correlation test. Analysis was performed by R software (R Development Core Team 2014).

Results

Morphological investigations

Axonal degeneration, demyelination (Fig. 2c,d), thickness of perineurium (Fig. 2e) and endoneurium and increase

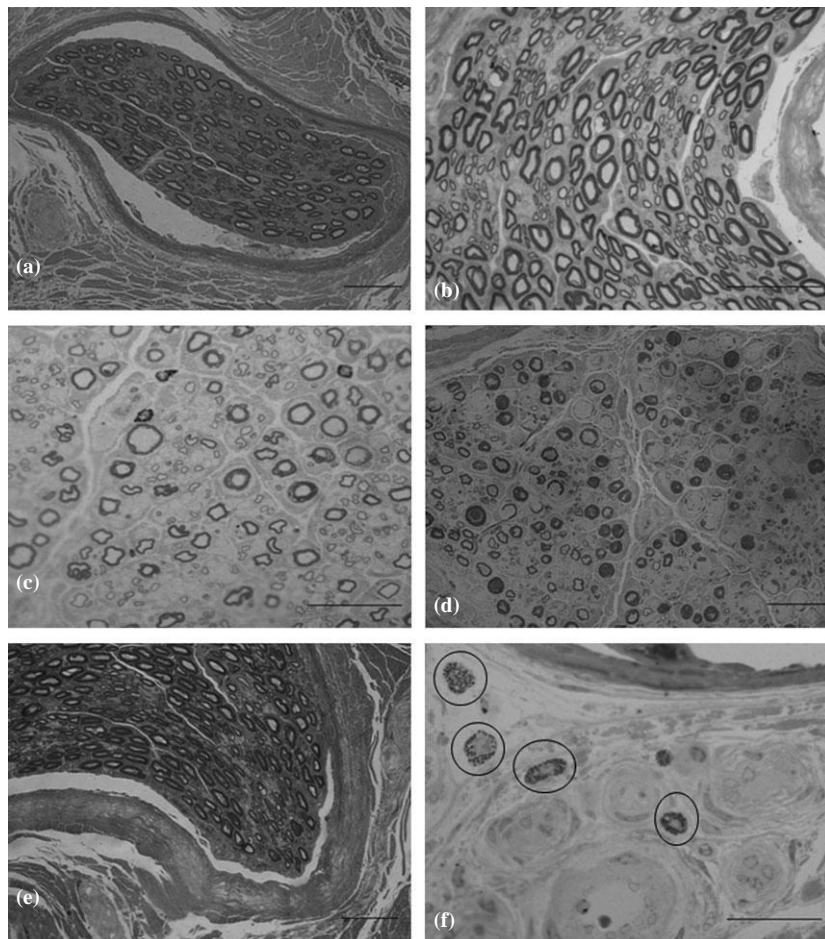


Fig. 2. (a, b). Control sample (score 0). (c) Axonal degeneration (score 1) and demyelination (score 3). (d) Axonal degeneration (score 3) and demyelination (score 3). (e) Thickness of perineurium (score 2). (f) Perivascular mast cells (circles) toluidine blue stain, A, D, E: 409; B, C, F: 609.

of mast cells (Fig. 2f) were the most important features detected in the samples. The total distribution of the main lesions is reported in Table 2.

Axonal degeneration showed different degrees of severity. Most of the samples revealed only focal or multifocal axonal degeneration characterized by size variation, swelling and fragmentation. Moreover, there was also an increase in axonal morphological irregularity.

Generally, moderate to severe demyelination was associated with axonal degeneration or sometimes myelin sheaths surrounding the nerve fibres, showed signs of degeneration.

The myelin sheath of control nerves was generally compact with a uniform thickness and a regular structure. In the pathological samples, there was an increase in the heterogeneity of myelin structure with ageing, showing the presence of several signs of degeneration such as swelling, dilatation, irregular shapes, incisures, separation of lamellae, and myelin loops. Moderate to severe demyelination was frequently observed, sometimes involving numerous nerve fibres.

Axonal degeneration and demyelination were associated with the progressive increase of endoneurial connective tissue between nerve fibres that became more dense.

The increase of perineurium thickness was evaluated on the basis of the control nerves. An important increase in the number of perineurium layers was detected in 15 animals.

A variable number of mast cells were present in all cases, especially located around blood vessels, but occasionally distributed between the myelinated nerve fibres.

The author did not record any variation in the number and size of blood vessels of our specimens.

Only a low number of focal to multifocal lesions were detected in young animals (group 3).

The scores recorded for axonal degeneration, demyelination, thickness of perineurium and endoneurium were significantly different among the groups (Kruskal–Wallis, $P < 0.01$). No significant difference was recorded among group 1 and the other two groups (Fig. 3a). Group 2 showed higher perineurium thickness compared with group 3 (Fig. 3a). Scores of group 1 for axonal degeneration, demyelination and thickness of endoneurium were significantly lower than those calculated for the others groups (Fig. 3b–d). The abundance of perivascular mast cells was significantly different among the

Table 2. Total distribution of the main reported lesions

	Score 0	Score 1	Score 2	Score 3
Axonal degeneration				
Group 1	3 (21.4%)	5 (35.7%)	4 (28.6%)	2 (14.3%)
Group 2	2 (11.8%)	9 (52.9%)	2 (11.8%)	4 (23.5%)
Group 3	10 (83.3%)	2 (16.6%)	0	0
Total	15 (34.9%)	16 (37.2%)	6 (13.9%)	6 (13.9%)
Demyelination				
Group 1	1 (7.2%)	3 (21.4%)	3 (21.4%)	7 (50%)
Group 2	0	2 (11.8%)	7 (41.1%)	8 (47.1%)
Group 3	9 (75%)	3 (25%)	0	0
Total	10 (23.8%)	8 (18.6%)	10 (23.8%)	15 (34.8%)
Thickness of perineurium				
Group 1	6 (42.9%)	2 (14.3%)	5 (35.7%)	1 (7.1%)
Group 2	2 (11.8%)	8 (47%)	7 (41.2%)	0
Group 3	6 (50%)	6 (50%)	0	0
Total	14 (32.5%)	16 (37.2%)	12 (27.9%)	1 (2.3%)
Thickness of endoneurium				
Group 1	1 (7.2%)	3 (21.4%)	3 (21.4%)	7 (50%)
Group 2	0	2 (11.8%)	7 (41.1%)	8 (47.1%)
Group 3	9 (75%)	3 (25%)	0	0
Total	10 (23.8%)	8 (18.6%)	10 (23.8%)	15 (34.8%)

groups (Kruskal–Wallis, $P < 0.01$). Individuals belonging to groups 1 and 2 showed a significantly higher number of perivascular mast cells when compared with individuals in the control group (Fig. 4).

Demyelination (Spearman's $q = 0.50$; $P < 0.01$), thickness of perineurium (Spearman's $q = 0.34$; $P < 0.05$) and endoneurium (Spearman's $q = 0.50$; $P < 0.01$) were positively and significantly correlated with the number of mast cells (median of five counts).

Biochemical investigations

The mean amount of GAG quantitative content (Fig. 5) recorded in the samples increased with the age, but there was no significant difference among the groups (ANOVA, $P = 0.07$, Fig. 5). Axonal degeneration (Spearman's $q = 0.51$; $P < 0.01$), demyelination (Spearman's $q = 0.42$; $P < 0.05$) and thickness of endoneurium (Spearman's $q = 0.42$; $P < 0.05$) were positively and significantly correlated with biochemical data.

Discussion

The main objective of this work was to assess the ageing-related changes occurring in peripheral nerves of adult/aged cattle.

The peripheral nerve function is significantly affected by ageing, and this phenomenon could be related to several factors such as decreased number of nerve fibres (Somorajski, 1974; Knox et al., 1989; Hashizume and

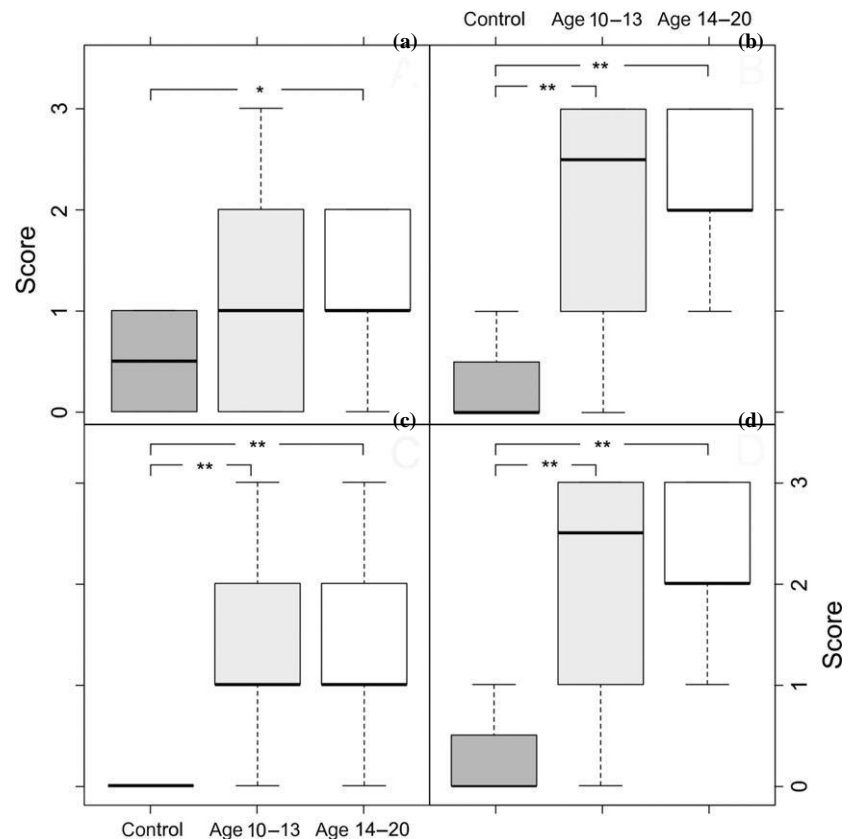


Fig. 3. Box plots illustrating morphological scores for the three groups: control, age 10–13 and age 14–20. The figure shows the scores for thickness of perineurium (a), demyelination (b), axonal degeneration (c) and thickness of endoneurium (d). P-values were calculated by pairwise comparisons performed using Wilcoxon's rank sum test (* $P < 0.05$, ** $P < 0.01$).

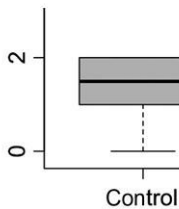


Fig. 4. Box plots illustrating counts of perivascular mast cells number per each group. P-values were calculated by pairwise comparisons performed using Wilcoxon's rank sum test (*P < 0.05, **P < 0.01).

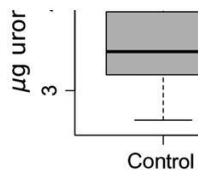


Fig. 5. Box plots illustrating amount of glycosaminoglycan quantitative content per group.

Kanda, 1995), abnormalities of the myelin sheath (Stanmore et al., 1978; Sharma et al., 1980; Grover-Johnson and Spencer, 1981) and alterations of the connective tissue (Knox et al., 1989).

The molecular basis of these ageing-related degenerative changes is not well known (Kirkwood, 2005; Goss et al., 2011), but probably related to alterations of protein expression and/or reduced turnover of nerve regeneration (Navarro and Kennedy, 1989).

The morphological alterations that affect the peripheral nerves seem more severe distally (Thomas et al., 1980; Grover-Johnson and Spencer, 1981). For this reason, the authors decided to examine a peripheral nerve (axial dorsal metacarpal) in a superficial position also easy to draw. Moreover, because in the literature ageing studies generally investigated only the differences between young and old animals, the authors decided to compare three groups involving young, adult and older cattle to verify whether a progression of the lesions could be better identified.

The results of this study show that ageing affects the different elements of the peripheral nerve: axons, myelin, connective tissue cells and extracellular matrix (GAGs component).

Cattle of the present study showed a significant increase in the severity of axonal degeneration, demyelination and thickness of endoneurium between control group in respect to groups 1 and 2. Moreover, a significant increase in thickness of perineurium was detected, but only between groups 1 and 3.

These results are in agreement with those of previous studies performed mainly on rats (Ceballos et al., 1999; Bahcelioglu et al., 2008) as there are no specific data related to the bovine species.

Axonal degeneration (degenerated and fragmented axons) has been highlighted in aged rats, over 24 months of age, in sciatic and tibial nerves (Cotard-Bartley et al., 1981), but also in spinal nerve roots (Berg et al., 1962; Gilmore, 1972). Moreover, optic nerves of rats showed an exponential increase in the number of degenerated axons with age (particularly evident from 24 months of age) (Cepurna et al., 2005). Ageing causes a progressive decrease in the thickness of the myelin sheath, phenomenon generally associated with other morphological abnormalities of the myelin sheath. These features had already been pointed out in spinal nerves (Ceballos et al., 1999), cranial nerves (Bahcelioglu et al., 2008) and optic nerves (Cepurna et al., 2005) of rats. Similar alterations of the myelin sheaths were also detected in the visual cortex of old monkeys (Peters et al., 2000). The endoneurium thickening may be closely associated with demyelination and axonal degeneration of nerve fibres: in fact, the increase of connective tissue seems to invade the space previously occupied by nerve fibres undergoing demyelination and axonal degeneration. A similar phenomenon has been described in the optic nerves of old monkeys (Sandell and Peters, 2001), where the thickness of the trabeculae of fibrous tissue increases to replace nerve fibres that are lost with ageing.

Few data are available regarding the changes of perineurium. Studies performed on spinal nerves of rats showed a decrease in the thickness and number of cell

layers of the perineurium in very old animals (Ceballos et al., 1999).

In the present research, no variation in the number and size of blood vessels was detected according to previous studies performed on rats (Bell and Weddell, 1984; Kihara et al., 1991) that showed as the total area of the blood vessels of the endoneurium should not vary with age. In fact, if many vessels collapse, those remaining increase their diameter, maintaining the overall vascular area unchanged.

As reported in literature, also non-neuronal cells undergo important changes with ageing and particularly macrophages and mast cells increase significantly in number in the endoneurium (Ceballos et al., 1999). In the present research, epineurial perivascular mast cells showed a significant increase with age, positively and significantly correlated with the severity of demyelination, thickness of perineurium and endoneurium. No increase of macrophages was detected. The increase in number of macrophages and mast cells with ageing may reflect the activation of resident cells or the recruitment of blood precursors attracted by degenerative processes. Mast cells are resident cells within the central nervous system of many species (Johnson and Krenger, 1992; Silver et al., 1996).

Studies by Olsson (1968), Olsson and Sjöstrand (1969), Latker et al. (1991) and Esposito et al. (2002) revealed that after injury, mast cells accumulate to the area where repair and inflammation are occurring strongly, suggesting that these cells actively participate in the degeneration and regeneration processes of the nerve. The specific role of these cells remains to be clarified, but their correlation with loss of myelin sheets and changes in the extracellular matrix emphasizes their importance in the nerve remodelling with ageing.

Extracellular matrix is a very important component of the nervous system and plays a prominent role in cell proliferation, migration and preservation of its shape (Luo et al., 2002). Evident changes in the extracellular matrix of the peripheral nerves have been reported in both pathological and non-pathological ageing process (King, 2001; Platt et al., 2003; Yasuda et al., 2003). The extracellular matrix of a peripheral nerve consists mainly of fibrous connective cells that surround the nerve (epineurium, perineurium and endoneurium), collagen, proteins like laminin, and GAGs. GAGs are usually classified into four categories: (1) hyaluronan (HA), (2) chondroitin sulphate (CS) and dermatan sulphate (DS), (3) keratan sulphate (KS) and (4) heparan sulphate and heparin (HS). Apart from HA, GAG chains can join to a protein core to form proteoglycans (PGs) (Siliprandi and Tettamanti, 2011). PGs and GAGs are important in homeostasis, morphogenesis, cell division, repair and neurodegenerative disease (Gandhi and Mancera, 2008; Couchman and Pataki, 2012; Dudas and Semeniken,

2012). Several changes in PG and GAG content are reported in aged animals (Kato et al., 1993; Warburton and Santer, 1997; King, 2001; Platt et al., 2003; Yasuda et al., 2003; Robert et al., 2010), but in author's knowledge, no data are reported in aged cattle.

Biochemical analysis described in the present study revealed an increase of GAG quantitative content between the oldest (2) and the control group (3) positively and significantly correlated with the presence of axonal degeneration, demyelination and thickness of endoneurium.

Due to the essential role of PGs and GAGs in axonal guidance and regeneration (Lin et al., 2011), the increase of GAG content in aged cattle of the present research could be considered closely correlated to degenerative processes of the nerve fibres.

Livestock animals represent spontaneous animal model to study several human diseases to better understand their pathogenesis and to test potential therapeutic agents. No specific studies have been performed on the age-related morphological and biochemical changes in bovine peripheral nerves. Recently, only Schenk et al. (2014) evaluated morphometric and neurophysiologic parameters of peripheral nerves of calves aged from 14 to 85 days, to elucidate the relationship between structure and function (motor nerve conduction velocity). This study permits to investigate the mean fibre diameter and the thickness of the myelin sheath in young calves, concluding that these animals have a higher degree of myelination compared with juvenile humans, presumably helping calves to obtain a good equilibrium, and well-developed locomotory abilities (Schenk et al., 2014).

The presence of morphological changes affecting the different elements of the peripheral nerve as observed in the present research, similar to that reported in humans and in laboratory species, allows the author to suggest the potential usefulness of cattle as a model for ageing lesions in humans. The use of this species provides some advantages, as for example being easy to handle and sharing a common environment with humans. Moreover, because of the dimension of this animal species, the collection of the axial dorsal metacarpal nerve is easy and the volume of the tissue obtained is abundant, sufficient to perform several investigations. However, further studies are needed to better correlate morphological and biochemical data and to assess the effects on nerve function of these progressive degenerative lesions.

Axonal degeneration, demyelination, thickness of perineurium and endoneurium and increase of mast cells were the most important features observed in the adult/old cattle of the present research. The mean amount of GAG quantitative content recorded in the sample tissues increased with the age. Axonal degeneration, demyelination and thickness of endoneurium were positively and

significantly correlated with biochemistry. The presence of changes affecting the different elements of the peripheral nerve, similar to that reported in humans and in laboratory species, the easy availability of the nerve in this species, the considerable size of the samples and the common environment more similar to humans than to laboratory animals, allows the authors to consider cattle as a good potential model for the comparative study of spontaneous ageing nerve lesions.

Acknowledgements

Research activities were funded by University of Torino (ex 60% 2012).

Conflict of Interest

The authors declared no potential conflict of interests with respect to the research, authorship and/or publication of this article.

References

- Albert, M., 1993: Neuropsychological and neurophysiological changes in healthy adult humans across the age range. *Neurobiol. Aging* 14, 623–625.
- Bahcelioglu, M., C. Elmas, A. Kurkcuoglu, E. Calguner, D. Erdogan, D. Kadioglu, and R. Geozil, 2008: Age-related immunohistochemical and ultrastructural changes in rat oculomotor nerve. *Anat. Histol. Embryol.* 37, 279–284.
- Bartoli, C.R., L.C. Sherwood, G.A. Giridharan, M.S. Slaughter, W.B. Wead, S.D. Prabhu, and S.C. Koenig, 2013: Bovine model of chronic ischemic cardiomyopathy: implications for ventricular assist device research. *Artif. Organs* 37, E202–E214.
- Behse, F., 1990: Morphometric studies on the human sural nerve. *Acta. Psychiatr. Scand. Suppl.* 123S, 1–38.
- Bell, M.A., and A.G.M. Weddell, 1984: A morphometric study of intrafascicular vessels of mammalian sciatic nerve. *Muscle Nerve* 7, 524–534.
- Berg, B.N., A. Wolf, and H.S. Simms, 1962: Degenerative lesions of spinal roots and peripheral nerves in aging rats. *Gerontology* 6, 72–80.
- Bitter, T., and H.M. Muir, 1962: A modified uronic acid carbazole reaction. *Anal. Biochem.* 4, 330–334.
- Burek, J.D., A.J. Van Der Kogel, and C.F. Hollander, 1976: Degenerative myelopathy in three strains of aging rats. *Vet. Pathol.* 13, 321–331.
- Castagnaro, M., S. Amedeo, A. Bertolotto, E. Manzardo, A. Riccio, and F. Guarda, 1997: Morphological and biochemical investigations of mitral valve endocardiosis in pigs. *Res. Vet. Sci.* 62, 121–125.
- Ceballos, D., J. Cuadras, E. Verdu, and X. Navarro, 1999: Morphometric and ultrastructural changes with aging in mouse peripheral nerve. *J. Anat.* 195, 563–576.
- Cepurna, W.O., R.J. Kayton, E.C. Johnson, and J.C. Morrison, 2005: Age related optic nerve axonal loss in adult Brown Norway rats. *Exp. Eye Res.* 80, 877–884.
- Chase, M.H., J.K. Engelhardt, A.M. Adinolfi, and S.S. Chirwa, 1992: Age-dependent changes in cat masseter nerve: an electrophysiological and morphological study. *Brain Res.* 586, 279–288.
- Cotard-Bartley, M.P., J. Secchi, R. Glomot, and J.B. Cavanagh, 1981: Spontaneous degenerative lesions of peripheral nerves in aging rats. *Vet. Pathol.* 18, 110–113.
- Couchman, J.R., and C.A. Pataki, 2012: An introduction to proteoglycans and their localization. *J. Histochem. Cytochem.* 60, 885–897.
- Dudas, B., and K. Semeniken, 2012: Glycosaminoglycans and neuroprotection. *Handb. Exp. Pharmacol.* 207, 325–343.
- Esposito, B., A. De Santis, R. Monteforte, and G.C. Baccari, 2002: Mast cells in Wallerian degeneration: morphologic and ultrastructural changes. *J. Comp. Neurol* 445, 199–210.
- Gandhi, N.S., and R.L. Mancera, 2008: The structure of glycosaminoglycans and their interactions with proteins. *Chem. Biol. Drug Des.* 72, 455–482.
- Glimore, S.A., 1972: Spinal nerve root degeneration in aging laboratory rats: a light microscopic study. *Anat. Rec.* 174, 251–258.
- Goss, J.R., D.B. Stolz, A.R. Robinson, M. Zhang, N. Arbuja, P.D. Robbins, J.C. Glorioso, and L.J. Niedernhofer, 2011: Premature aging-related peripheral neuropathy in a mouse model of progeria. *Mech. Ageing Dev.* 132, 437–442.
- Grover-Johnson, N., and P.S. Spencer, 1981: Peripheral nerve abnormalities in aging rats. *J. Neuropathol. Exp. Neurol.* 40, 155–165.
- Hashizume, K., and K. Kanda, 1995: Differential effects of aging on motoneurons and peripheral nerves innervating the hind-limb and forelimb muscles of rats. *Neurosci. Res.* 22, 89–196.
- Hinman, J.D., A. Peters, H. Cabral, D.L. Rosene, W. Hollander, M.N. Rasband, and C.R. Abraham, 2006: Age-related molecular reorganization at the node of Ranvier. *J. Comp. Neurol.* 449, 351–362.
- Hirano, T., T. Matsuhashi, N. Kobayashi, T. Watanabe, and Y. Sugimoto, 2012: Identification of an FBN1 mutation in bovine Marfan syndrome-like disease. *Anim. Genet.* 43, 11–17.
- Johnson, D., and W. Krenger, 1992: Interactions of mast cells with nervous system recent advances. *Neurochem. Res.* 17, 939–951.
- Kato, T., T. Katagiri, Y. Shikama, K. Kurita, I. Toyoshima, A. Hirano, M. Wada, and H. Sasaki, 1993: Heparan sulfate-like immunoreactivity in the spinal cord in motor neuron disease. *Acta Neuropathol.* 85, 663–665.
- Kihara, M., A. Weerasuriya, and P.A. Low, 1991: Endoneurial blood flow in rat sciatic nerve during development. *J. Physiol.* 439, 351–360.
- King, R.H.M., 2001: The role of glycation in the pathogenesis of diabetic polyneuropathy. *Mol. Pathol.* 54, 400–408.
- Kirkwood, T.B., 2005: Understanding the odd science of aging. *Cell* 120, 437–447.

- Knox, C.A., E. Kokmen, and P.J. Dyck, 1989: Morphometric alterations of rat myelinated fibers with aging. *J. Neuropathol. Exp. Neurol.* 48, 119–139.
- Latker, C.H., K.C. Wadhvani, A. Balbo, and S.I. Rapoport, 1991: Blood-nerve barrier in the frog during Wallerian degeneration: are axons necessary for maintenance of barrier function? *J. Comp. Neurol.* 309, 650–664.
- Lin, R., T.W. Rosahl, P.J. Whiting, J.W. Fawcett, and J.C. Kwok, 2011: 6-Sulphated chondroitins have a positive influence on axonal regeneration. *PLoS ONE* 6, e21499.
- Luo, Z.J., R.H.M. King, J. Lewin, and P.K. Thomas, 2002: Effects of nonenzymatic glycosylation of extracellular matrix components on cell survival and sensory neurite extension in cell culture. *J. Neurol.* 249, 424–431.
- Majeed, S.K., 1992: Survey on spontaneous peripheral neuropathy in aging rats. *Arzneimittelforschung* 42, 968–990.
- Manini, T.M., S.L. Hong, and B.C. Clark, 2013: Aging and muscle: a neuron's perspective. *Curr. Opin. Clin. Nutr. Metab. Care* 16, 21–26.
- Navarro, X., and W.R. Kennedy, 1989: The effects of aging on regeneration and sprouting of unmyelinated axons. In: *Peripheral Nerve Changes in the Elderly. New Issues in Neurosciences* (P.K. Thomas, ed.). New York: Wiley & Sons, pp. 125–134.
- Olsson, Y., 1968: Mast cells in the nervous system. *Int. Rev. Cytol.* 24, 27–70.
- Olsson, Y., and J. Sjöstrand, 1969: Proliferation of mast cells in peripheral nerves during Wallerian degeneration: a radioautographic study. *Acta Neuropathol.* 13, 111–121.
- Patterson, D.S., and W.M. Allen, 1972: Chronic mycobacterial enteritis in ruminants as a model of Crohn's disease. *Proc. R. Soc. Med.* 65, 998–1001.
- Peters, A., and C. Sethares, 2002: Aging and the myelinated fibers in prefrontal cortex and corpus callosum of the monkey. *J. Comp. Neurol.* 442, 277–291.
- Peters, A., M.B. Moss, and C. Sethares, 2000: The effects of aging on myelinated nerve fibers in monkey primary visual cortex. *J. Comp. Neurol.* 419, 64–376.
- Platt, C.I., C.A. Krekoski, R.V. Ward, D.R. Edwards, and J. Gavrilovic, 2003: Extracellular matrix and matrix metalloproteinases in sciatic nerve. *J. Neurosci. Res.* 74, 417–429.
- R Core Team 2014: R: A language and environment for statistical computing. R Foundation for Statistical Computing, Vienna, Austria, URL <http://www.R-project.org/>.
- Robert, L., A.M. Robert, and G. Renard, 2010: Biological effects of hyaluronan in connective tissues, eye, skin, venous wall. *Role in aging. Pathol. Biol.* 58, 187–198.
- Sandell, J.H., and A. Peters, 2001: Effects of age on nerve fibers in the rhesus monkey optic nerve. *J. Comp. Neurol.* 429, 541–553.
- Schenk, H.C., K. Haastert-Talini, J. Jungnickel, C. Grothe, H. Meyer, J. Rehage, M. Fehr, J. Bokemeyer, C. Rohn, and A. Tipold, 2014: Morphometric parameters of peripheral nerves in calves correlated with conduction velocity. *J. Vet. Intern. Med.* 28, 646–655.
- Sharma, A.K., S. Bajada, and P.K. Thomas, 1980: Age changes in the tibial and plantar nerves of the rat. *J. Anat.* 130, 417–428.
- Siliprandi, N., and G. Tettamanti, 2011: *Biochimica medica*. In: *Biochimica medica*, (N. Siliprandi and G. Tettamanti, eds.). Padova: Piccin, pp. 1–23.
- Silver, R., A.J. Silverman, L. Vitkovic, and I.I. Lederhendler, 1996: Mast cells in the brain: evidence and functional significance. *Trends Neurosci.* 19, 25–31.
- Sloane, J.A., J.D. Hinman, M. Lubonia, W. Hollander, and C.R. Abraham, 2003: Age-dependent myelin degeneration and proteolysis of oligodendrocyte proteins is associated with the activation of calpain-1 in the rhesus monkey. *J. Neurochem.* 84, 157–168.
- Somorajski, T., 1974: Age differences in the morphology of posterior tibial nerves of mice. *J. Comp. Neurol.* 157, 439–452.
- Stanmore, A., S. Bradbury, and A.G.M. Weddell, 1978: A quantitative study of peripheral nerve fibres in the mouse following the administration of rugs. I. Age changes in untreated CBA mice from 3 to 21 months of age. *J. Anat.* 127, 101–115.
- Sugiyama, I., K. Tanaka, M. Akita, K. Yoshida, T. Kawase, and H. Asou, 2002: Ultrastructural analysis of the paranodal junction of myelinated fibers in 31-month-old rats. *J. Neurosci. Res.* 70, 309–317.
- Taylor, G., 2013: Bovine model of respiratory syncytial virus infection. *Curr. Top. Microbiol. Immunol.* 372, 327–345.
- Thomas, P.K., R.H.M. King, and A.K. Sharma, 1980: Changes with age in the peripheral nerves of the rat. *Acta Neuropathol.* 52, 1–6.
- Vans Teenis, G., and R. Kroes, 1971: Changes in the nervous system and musculature of old rats. *Vet. Pathol.* 18, 320–332.
- Warburton, A.L., and R.M. Santer, 1997: The hypogastric and thirteenth thoracic ganglia of the rat: effects of age on the neurons and their extracellular environment. *J. Anat.* 190, 115–124.
- Waters, W.R., M.F. Maggioli, J.L. McGill, K.P. Lyashchenko, and M.V. Palmer, 2014: Relevance of bovine tuberculosis research to the understanding of human disease: historical perspectives, approaches, and immunologic mechanisms. *Vet. Immunol. Immunopathol.* 15, 113–132.
- Weis, J., Brandner, B., Lammens, M., Sommer, C., and J.M. Vallat, 2012: Processing of nerve biopsies: a practical guide for neuropathologists. *Clin. Neuropathol.* 31, 7–23.
- Werner, R.A., A. Franzblau, H.J. D'Arcy, B.A. Evanoff, and H.C. Tong, 2012: Differential aging of median and ulnar sensory nerve parameters. *Muscle Nerve* 45, 60–64.
- Yasuda, H., M. Terada, K. Maeda, S. Kogawa, M. Sanada, M. Haneda, A. Kashiwagi, and R. Kikkawa, 2003: Diabetic neuropathy and nerve regeneration. *Prog. Neurobiol.* 69, 229–285.