Accuracy of 64-row MDCT in the diagnosis of acute abdomen in the emergency department

[1]Priola AM, MD, [1]Priola SM, MD, [2]Volpicelli G, MD, FCCP, [3]Giraudo MT, PhD, [4]Martino V, MD, [1]Fava C, MD, [1]Veltri A, MD.

[1]Radiology Department, San Luigi Gonzaga University Hospital, Torino, Italy
[2]Department of Emergency Medicine, San Luigi Gonzaga University Hospital, Torino, Italy
[3]Department of Mathematics, University of Torino, Italy
[4] General Surgery, San Luigi Gonzaga University Hospital, Torino, Italy

ABSTRACT

Objective: To assess the accuracy of 64-row computed tomography (CT) in the differential diagnosis of acute abdomen in the emergency department.

Materials and Methods: Prospective analysis of 181 patients with surgically treated acute abdomen.

Results: In 158/181 cases, CT was totally concordant with surgical repertoire. Partial concordance was found in 15 cases. Overall sensitivity was 87.3% when only cases of complete concordance were considered, 95.6% if also partial concordance cases were included.

Conclusion: CT showed high reliability in the differential diagnosis of acute abdomen surgically treated, although associated conditions can sometimes be missed.

INTRODUCTION

Acute abdomen is a clinical condition of acute-onset abdominal pain associated with abdominal tenderness and rigidity, frequently encountered in the Emergency Department (ED) [1]. Abdominal conditions that occur with acute abdomen may be numerous. Diagnostic procedure performed in the ED is crucial to address proper treatment, which is extremely variable ranging from observation and symptomatic therapy in benign self-limiting diseases to urgent surgery in life threatening conditions [1-5]. Early diagnosis is also an important prerequisite, especially in unstable patients [3]. Physical examination has limited accuracy, because different diseases often share the same signs [1-3]. For these reasons, almost all patients presenting with suspected acute abdomen are submitted to radiologic diagnostic procedures, mainly abdominal plain film radiography, sonography and computerized tomography [1, 2, 6]. Developments in technology have allowed in recent years the emergence and widespread of multi-detector computerized tomography (MDCT) [1]. The potential of MDCT in the diagnostic process of acute abdomen in the ED has yet never fully evaluated.

Aim of this study is to evaluate the accuracy of a modern 64-MDCT in the differential diagnosis of non-traumatic surgical acute abdomen in the ED. Moreover, we want to assess the potential of MDCT in detecting not only the main cause of acute abdomen, but also all the associated findings that will emerge during surgery or autopsy. Final aim of the study is to show if there are significant differences in the diagnostic performance of MDCT in various groups of abdominal diseases.

MATERIAL AND METHODS

Study Design

Our study used prospective, consecutive, sample cohort enrollment and data collection. The diagnostic radiologic performance of 64-MDCT was compared with surgical or autopsy findings and analysis of histological examinations.

Setting

The study was conducted at San Luigi Gonzaga University Hospital, North West of Torino,

Northern Italy. The ED serves a primarily adult population with a volume of approximately 50,000 visits per year.

Selection of Participants

Between March 2007 and October 2008 we prospectively studied 181 consecutive outpatients, 108 males and 73 women, aged 17 to 88 years (mean age 58.7 ± 12.0 years). Only patients presenting to the ED with a clinical picture suggestive of non-traumatic acute abdomen, who were submitted to MDCT and subsequent mandatory surgery within 48 hours time, were enrolled in the study.

Diagnostic proceedings

After primary evaluation and blood tests, the attending emergency physician independently ordered the imaging procedure. In 97 patients plain film radiography of the abdomen and in 61 patients abdominal sonography were the diagnostic techniques that preceded the implementation of MDCT. In 49 cases the only imaging procedure was MDCT. MDCT examination (64-row MDCT, Philips Brilliance, MX80001DT, Philips Medical Systems, Eindhoven, The Nederland) was performed by basal and venous scans, after administration of a bolus of iodine contrast media (volume 100-150 ml or 2 ml/kg, rate 2-5 ml/sec, concentration 350 mg I/ml), with extension from diaphragm to symphysis pubis (kVp 120, modulation with range 100-450 mAs, collimation 0.6 mm x 64, thickness and reconstruction interval 1-3 mm). In a minority of cases (19/181), the venous scan was avoided because of contraindication to iodine contrast media administration (allergy or severe renal failure, 7/19) or because the final diagnosis was already obtained by the basal scans (12/19). The venous scan was mostly performed in the portal phase, at about 70-90 sec from contrast media injection, while the arterial phase, at about 20-40 sec, was scanned in case of high suspicion of ischemic bowel or aortic diseases. Oral or rectal administration of contrast media was never used. MDCT examinations were evaluated on a dedicated workstation allowing adequate abdominal windows (width 400-500 HU, level 20-50 HU), using axial images and multi-planar reconstruction in the sagittal, coronal and oblique planes. In cases where intestinal perforation was

suspected, evaluation was extended to the lung windows (width 1500 HU, level -500 HU) to look for signs of air collection.

Data Collection and Processing

Two experienced radiologists, with more than five years experience on abdominal CT readings and emergency diagnostic radiology, evaluated MDCT images independently. Consensus was reached by conference, and disagreements were adjudicated by a third more experienced radiologist (more than ten years experience on CT abdominal imaging in emergency radiology). Radiologic readings were compared with surgical findings, inclusive of histology data, or autopsy. Conditions of "complete concordance" or "incorrect diagnosis" were considered. Moreover, we considered the intermediate condition of "partial concordance" when MDCT correctly identified the main condition at the origin of the clinical picture, but missed some significant associated surgical findings. Cases were divided into four groups according to the condition that caused acute abdomen: bowel obstruction, inflammatory diseases, perforation, various causes (vascular, gynecologic and others), and complete and partial concordance were analyzed by means of 2x2 tables. Confidence intervals were computed following the Wilson score procedure [7] to point out statistically significant differences between complete and partial concordance proportions for all the cases considered and then limited to each of the first three groups of diseases (bowel obstruction, inflammatory diseases and perforation). To assess whether significant differences could be found in the complete concordance or in the partial concordance proportions among the first three groups of diseases, a log-likelihood ratio test with Williams q correction [8] was performed due to the limited size of some samples. A significance level of 5% was always considered. Statistical analysis was performed by a commercial software (Statistica 6.1 for Windows, Statsoft Inc., Tulsa, OK, USA).

RESULTS

Among 181 cases enrolled, 175 patients were submitted to surgery and 6 patients died before surgery (hypovolemic shock and following cardiac arrest in aortic aneurysm rupture). One elderly

patient with intestinal occlusion due to bowel cancer, died immediately after surgery complicated by a severe septic shock. In all cases (n = 181) it was possible to obtain a final diagnosis related to surgical outcome or autopsy (Table 1). During the period of the study, patients with clinical picture of acute abdomen then submitted to surgery never showed negative MDCT examination. MDCT allowed a correct diagnosis with detection of all the associated findings in 158/181 cases. In 15/181 patients (8.3%) we found a partial concordance between MDCT readings and surgical findings. In these cases, MDCT correctly detected the main cause of acute abdomen, but missed some associated conditions. In only 8 cases out of 181 (4.4%) the MDCT reading was considered incorrect diagnosis after comparison with the surgery findings. The overall sensitivity in the detection of the main condition and the associated findings was 87.3%. When we consider the potential of MDCT in the identification of the major disease in acute abdomen, without considering its ability in the detection of associated conditions thus merging the categories “complete concordance” and “partial concordance”, the overall sensitivity rises to 95.6%. The Wilson score intervals computed at a 95% level significance for the proportions of complete concordance and of partial concordance for all the cases considered did not overlap ([0.8165-0.9138] for complete concordance and [0.9152-0.9774] for partial concordance). This hints to a better performance of MDCT in the detection of the main cause of acute abdomen with respect to the detection of all the associated conditions. The same analysis was performed for each of the three main groups of diagnosis separately (bowel obstruction, inflammatory diseases and perforation). The Wilson score intervals for the proportions of complete concordance and of partial concordance overlapped in all the three groups, more evidently for the occlusion and perforation groups. The log-likelihood ratio test with Williams q correction performed on the complete concordance data for the first three groups of diseases did not reveal at a 5% level a significant difference between the proportions in each group. An analogous result was found for the partial concordance proportions for the same groups, though the value of the statistics in this case was near to the critical one. The possibility to

consider a larger number of cases for all the diseases could allow establishing a possible better distinction between the performances of MDCT in the different situations.

In the group with bowel obstruction MDCT identified the condition in 96% of cases (73/77). In all these patients, MDCT documented the transition zone between the stretched and regular bowel loops (Fig. 1). In most cases (44/77), obstruction was due to cancer (Fig. 2) followed by adhesions (18/77), complicated incisional or internal/external hernia (8/77), intussusception of large and small bowel (5/77), volvulus (2/77). In 3 cases of occlusion, the MDCT diagnostic hypothesis explaining obstruction was wrong. The first two cases were hypothesized adhesions, while the final diagnoses were cancer in one and volvulus in the other; the third case was a hypothesized intussusception due to polyp, while the final diagnosis was intussusception due to adhesion. In the same group, we had also 3 cases of partial concordance between MDCT and surgery. They were: two cases of right colon cancer, correctly detected by MDCT, which failed in the diagnoses of the associated gastric and parietal fistulas; one case of complicated abdominal wall hernia, where MDCT did not diagnose trans-mural necrosis.

In the 62 patients with abdominal inflammatory diseases, the most frequent intra-operative diagnosis was acute diverticulitis (25/62) (Fig. 3), followed by acute appendicitis (16/62), and cholecystitis (15/62) (Fig. 4). The MDCT allowed correct diagnosis of either the origin of inflammation, its extension and complications in 54/62 cases. We had only one misdiagnosis, when radiologist hypothesized acute diverticulitis and associated colonic wall thickening highly suspicious for cancer. In this case, the surgical finding confirmed the diagnosis of acute diverticulitis, but the following histology excluded cancer. In this group there have been also seven cases of partial concordance: in two cases of acute appendicitis MDCT was not able to detect abscess in one and fistula in the other; in three cases of acute diverticulitis MDCT did not detect covered perforation in two and abscess in the third; in two cases of acute cholecystitis gallstones were not visualized.

In the perforation group (n = 19), the most frequent condition was gastro-duodenal ulcer (9/19), followed by colon cancer (6/19), Crohn's disease (2/19), iatrogenic causes (2/19). MDCT detected only the free intra-peritoneal air without visualizing perforation in one case of gastric ulcer of the anterior wall and two cases of duodenal ulcer. Moreover, we had two cases of partial concordance: in one case of covered perforation of the posterior duodenal wall due to peptic ulcer, MDCT did not visualize the inflammation of the hepatic-duodenal ligament; in a second case, MDCT detected a gastric covered perforation but missed the main lesion due to cancer.

Minor causes of acute abdomen resulted vascular and gynecological conditions, and they were grouped in the "various causes" for statistical reason. Vascular diseases were mainly aortic rupture (12/15) (Fig. 5) and 3 ischemic. In this latter group (n = 15), MDCT showed two partial concordance cases, due to its inability to locate the rupture despite hematoma was correctly detected. In the subgroup of gynecological conditions (n = 5), MDCT reading gave incorrect diagnosis in one case of ovarian torsion and was partially concordant in one case of rupture of an ovarian cyst with associated tube-ovarian abscess.

DISCUSSION

Acute abdomen is quite common in the ED. An incidence of about 4-5% was described in a previous study [1]. The most frequent causes are intestinal diseases, both inflammatory and obstructive [1-3]. Very often history, physical examination and laboratory tests do not allow a proper and safe diagnostic conclusion, while imaging plays a crucial role in the ED especially in life-threatening situations [1-3, 6]. Conventional radiology is of limited usefulness because it has low sensitivity in the diagnosis of acute abdomen, particularly when compared to other imaging modalities [9, 10]. The plain film study is useful only to confirm occlusion and perforation, even if sonography and CT are still almost always required [1, 6]. In recent years the progression of technology has brought to the development of more sophisticated computerized tomography devices, with the implementation of multi-detector modality. This progress has led to the increasing

use of computerized tomography, and MDCT is increasingly replacing conventional radiology as first line diagnostic modality [11, 12]. Multi-detector devices allow for fast examinations and broad view with more defined images [13]. Moreover, radiation exposure could be reduced by using a focused technique that limits the examination to the region of interest, as in case of examination of the right iliac fossa when appendicitis is suspected [14, 15]. Modern software also enables multi-planar reconstruction (MPR), which enhances the quality and definition of axial images. For example, MPR allows better analyses of distended loops in case of intestinal obstruction, improving the ability of the reader to detect the exact point of transition and the cause of obstruction [1, 16].

Our study is a further demonstration of the high diagnostic efficacy of MDCT in acute abdomen in the ED. In the group of patients with bowel obstruction MDCT showed very high sensitivity, and the wide use of MPR technology allowed accurate localization of the transition zone in most cases. Bowel obstruction is a frequent cause of acute abdomen. Conditions causing obstruction may involve the small bowel, mostly post-surgical adhesions, and the large bowel, mostly colon cancer (Fig. 2). CT showed high diagnostic accuracy with values of sensitivity and specificity above 90% in some previous studies, being particularly useful not only in detecting the site and the cause of obstruction, but also in the evaluation of the severity of obstruction and its complications, which is essential to decide surgical or conservative treatment [17, 18]. In the study of Megibow et al. the condition causing bowel obstruction was correctly identified in 85% of cases and CT studies were considered decisive in changing the orientation from conservative to surgical treatment in 23% of cases [17]. The use of MDCT in our study gave better results in terms of correct diagnosis of the condition in the bowel obstruction group (96%), but even more so when we consider that the use of MPR allowed correct identification of the transition zone (Fig. 1) in all patients of this latter group. However, literature shows that sensitivity of MDCT drops when partial obstruction of the small intestine due to adherences is the main cause of acute abdomen, This is due to the low specificity of some radiologic signs, such as extra-luminal compression and kinking on the intestinal wall [19].

These conditions are better investigated with CT enteroclysis, which however may not be applied to severely ill patients in the emergency setting [20].

Inflammatory conditions were the other most frequent causes of acute abdomen in the ED, particularly appendicitis, diverticulitis and cholecystitis [1]. This trend was confirmed in our study. In some previous studies, MDCT showed high diagnostic accuracy in acute appendicitis, with a reported sensitivity value ranging from 90% to 100% owing to a considerable reduction of unnecessary surgery [21, 22]. MDCT is also useful in the identification of any complications, but generally fails in the visualization of fissuring of the appendix, while other associated conditions, like periappendiceal gas or abscess are highly specific even if scarcely sensitive [23]. In our study, in 1 among 3 cases appendiceal perforation was not visualized by MDCT. Moreover, in females MDCT has some limitations because radiologic and clinical signs are not easily differentiated from pelvic gynecological diseases [2, 3, 6]. For these reasons, young females with suspected appendicitis are better analyzed by sonography as first level imaging, followed by MDCT only when diagnosis is still in doubt. Literature reports very high level of sensitivity of MDCT in the diagnosis of acute diverticulitis and its complications (97-98%) [24]. Highly specific radiologic signs are considered parietal thickening and adipose stranding [24]. MDCT is less accurate only in the early stages of acute diverticulitis and generally fails to predict the exact extension of the parietal involvement. Another limitation can be the differential diagnosis with colorectal cancer, particularly when the parietal thickening is not circumferential [1, 6]. In acute cholecystitis the most appropriate imaging method is sonography. MDCT shows similar level of accuracy in the diagnosis of the disease, but limitations in the visualization of gallstones [25].

In a recent study, MDCT showed its usefulness in selected cases of intestinal perforation [6]. Limitations of this technique in the exact localization of the perforation site are well known, and this was confirmed by our data [26]. Especially perforation of the first duodenal

segment and anterior gastric wall are not very well detected by MDCT, although it is generally possible to predict the perforation site by looking at the disposition of intra-peritoneal air [27]. Detection of the perforation site by MDCT is generally possible in 80-85% of cases when MPR is applied to improve the image definition, but diagnosis relies on indirect radiologic signs rather than direct visualization of the intestinal wall break [27, 28]. These signs are regional parietal thickening with some contiguous fluid collection and air bubbles in the peri-visceral adipose tissue [1].

Vascular anomalies causing acute abdomen are quite rare, having an incidence of about 1-2% of all the patients presenting in the ED with acute abdominal pain [29]. The recent evolution of MDCT technology, based on the ability to obtain multiphase studies of rapid implementation, finer collimation and vascular MIP reconstructions in different planes of space, greatly improved its diagnostic ability in many vascular diseases. Particularly, diagnostic sensitivity of MDCT in the ischemic bowel disease rapidly improved in recent years from 65% to 95-100% [30]. Diagnostic accuracy of MDCT in the visualization of tromboembolic vascular occlusion is nowadays similar to angiography, even in the earliest stages of occlusion when parietal damage is not yet visible [6, 30]. MDCT is also crucial in the diagnosis of acute disease of the abdominal aorta. Diagnostic accuracy of MDCT in the detection of aortic rupture is close to 100%, due to its ability in the visualization of retroperitoneal ematoma, small discontinuities of the aortic calcifications and some radiologic signs like the high attenuating peripheral crescent sign, the indistinct aortic wall and the frank contrast medium extravasation [29, 31].

Finally, our study showed that MDCT is highly accurate in the detection of the main condition that causes acute abdomen. However, MDCT sometimes fails in detecting all associated conditions that arise after surgery. It is therefore justified the distinction of the two categories of partial and complete concordance that we used in our analysis. Even if the

partial concordance of MDCT find with surgery is high, emergency physicians and surgeons should consider the possibility of misdiagnosed associated conditions. This study showed that these features of the diagnostic effectiveness of MDCT do not statistically change in the different groups of diseases analyzed in our series.

LIMITATIONS

The main limitation of our study is the moderate number of patients with vascular and gynecological diseases. For this reason our series cannot be considered highly representative of all the conditions that can be encountered in acute abdomen. Moreover, this limitation makes comparison of diagnostic efficacy of MDCT in different groups of diseases less significant. This limitation is due to the fact that our Institution is not the regional referral hospital for vascular and gynecological diseases. Nevertheless, this is the first substantial series that has allowed a statistical analysis of the effectiveness of a modern 64-row MDCT in the diagnosis of acute abdomen in the ED.

CONCLUSION

Modern MDCT is effective and highly sensitive in the differential diagnosis of non-traumatic acute abdomen in the ED. This method demonstrates its full potential in identifying bowel obstruction, perforation, inflammatory and vascular diseases as the main causes of acute abdomen, but has some limitation in detecting all the associated conditions that arise after surgery and histological examination.

REFERENCES

1. Stoker J, van Randen A, Laméris W, Boermeester MA. Imaging patients with acute abdominal pain. Radiology 2009;253:31-46.
2. Macari M, Balthazar EJ. The acute right lower quadrant: CT evaluation. Radiol Clin North Am 2003;41:1117-1136.
3. Green JM. When is faster better? Operative timing in acute care surgery. Current Opinion in Critical Care 2008;14:423-427.
4. Priola AM, Priola SM, Cataldi A, Marci V, Fava C. Acute abdomen as an unusual presentation of hepatic PEComa. A case report. Tumori 2009;95:123-128.
5. Priola AM, Priola SM. Retained intra-abdominal surgical instrument: a rare condition of acute abdomen. ANZ J Surg 2010;80(10):758.
6. Mangini M, Carrafiello G, Laganà D, Palma L, Novario R, Dionigi G, Neri C, Fugazzola C. Non-traumatic acute bowel disease: differential diagnosis with 64-row MDCT. Emerg Radiol 2008;15:171-178.
7. Hogg RV, Tanis EA. Probability and statistical interference. 6th edition, 2001, Prentice Hall, Upper Saddle River.
8. Sokal RR, Rohlf FJ. Biometry: The principles and practice of statistics in biological research. 3rd edition, 1995, W.H. Freeman, New York, ISBN 0-7167-2411-1.
9. MacKersie AB, Lane MJ, Gerhardt RT, Claypool HA, Keenan S, Katz DS, Tucker JE. Nontraumatic acute abdominal pain:unenhanced helical CT compared with three-view acute abdominal series. Radiology 2005;237:114-122.
10. Dhillon S, Halligan S, Goh V, Matravers P, Chambers A, Remedios D. The therapeutic impact of abdominal ultrasound in patients with acute abdominal symptoms. Clin Radiol 2002;57:268-271.

11. Laméris W, van Randen A, van Es HW, van Heesewijk JP, van Ramshorst B, Bouma WH, ten Hove W, van Leeuwen MS, van Keulen EM, Dijkgraaf MG, Bossuyt PM, Boermeester MA, Stoker J; OPTIMA study group. Imaging strategies for detection of urgent conditions in patients with acute abdominal pain: diagnostic accuracy study. BMJ 2009;338-b2431.
12. Grassi R, Di Mizio R, Pinto A, Romano L, Rotondo A. Serial plain abdominal film findings in the assessment of acute abdomen: spastic ileus, hypotonic ileus, mechanical ileus and paralytic ileus. Radiol Med 2004;108:56-70.
13. Leschka S, Alkadhi H, Wildermuth S, Marincek B. Multidetector computed tomography of acute abdomen. Eur Radiol 2005;15:2435-2447.
14. Rao PM, Rhea JT, Noveline RA, McCabe CJ, Lawrason JN, Berger DL, Sacknoff R. Helical CT technique for the diagnosis of appendicitis: prospective evaluation of focused appendix technique. Radiology 1997;202:139-144.
15. Fefferman NR, Roche KJ, Pinkney LP, Ambrosino MM, Genieser NB. Suspected appendicitis in children: focused CT technique for evaluation. Radiology 2001;220:691-695.
16. Stabile Ianora AA, Moschetta M, Lorusso V, Scandapane A. Atypical appendicitis: diagnostic value of volume-rendered reconstructions obtained with 16-slice multidetector-row CT. Radiol Med 2010;115:93-104.
17. Megibow AJ. Bowel obstruction: evaluation with CT. Radiol Clin North Am 1994;32:861-870.
18. Frager D, Rovno HD, Baer JW, Bashist B, Friedman M. Prospective evaluation of colonic obstruction with computed tomography. Abdom Imaging 1998;23:141-146.
19. Petrovic B, Nikolaidis P, Hammond NA, Grant TH, Miller FH. Identification of adhesions on CT in small-bowel obstruction. Emerg Radiol 2006;12:88-93.

20. La Seta F, Buccellato A, tesè L, Biscaldi E, Rollandi GA, Barbiera F, Cappabianca S, Di Mizio R, Grassi R. Multidetector-row CT enteroclysis: indications and clinical applications. Radiol Med 2006;111:141-158.
21. Iwahashi N, Kitagawa Y, Mayumi T, Kohno H. Intravenous contrast-enhanced computed tomography in the diagnosis of acute appendicitis. World J Surg 2005;29:83-87.
22. Hong JJ, Cohn SM, Ekeh AP, Newman M, Salama M, Leblang SD. A prospective randomized study of clinical assessment versus computed tomography for the diagnosis of acute appendicitis. Surg Infect 2003;4:231-239.
23. Bixby SD, Lucey BC, Soto JA, Theysohn JM, Ozonoff A, Varghese JC. Perforated versus nonperforated acute appendicitis: accuracy of multidetector CT detection. Radiology 2006;241:780-786.
24. Kircher MF, Rhea JT, Kihiczac D, Novelline RA. Frequency, sensitivity, and specificity of individual signs of diverticulitis on thin-section helical CT with colonic contrast material: experience with 312 cases. Am J Roentgenol 2002;178:1313-1318.
25. Rubens DJ. Hepatobiliary imaging and its pitfalls. Radiol Clin North Am 2004;42:257-278.
26. Rubesin SE, Levine MS. Radiologic diagnosis of gastrointestinal perforation. Radiol Clin North Am 2003;41:1095-1115.
27. Hainaux B, Agneessens E, Bertinotti R, De Maertelaer V, Rubesova E, Capelluto E, Moschopoulos C. Accuracy of MDCT in predicting site of gastrointestinal tract perforation. Am J Roentgenol 2006;187:1179-1183.
28. Ghekiere O, Lesnik A, Millet I, Hoa D, Guillon F, Taourel P. Direct visualization of perforation sites in patients with a non-traumatic free pneumoperitoneum: added diagnostic value of thin transverse slices and coronal and sagittal reformations for multidetector CT. Eur Radiol 2007;17:2302-2309.

29. Bhalla S, Menias CO, Heiken JP. CT of acute abdominal disorders. Radiol Clin North Am 2003;41:1153-1169.
30. Wiesner W, Hauser A, Steinbrich W. Accuracy of multidetector row computed tomography for the diagnosis of acute bowel ischemia in a non-selected study population. Eur Radiol 2004;14:2347-2356.
31. Siegel CL, Cohan RH, Korobkin M, Alpern MB, Courneya DL, Leder RA. Abdominal aortic aneurysm morphology: CT features in patients with ruptured and nonruptured aneurysms. Am J Roentgenol 1991;163:1123-1129.

FIGURE LEGENDS

Figure 1: MDCT showing transition zones (arrows) between intestinal loops in cases of complete obstruction due to (A) volvulus of the distal ileum; (B) intussusception of the ileum; (C) colon cancer; and (D) laparocele. Images c and d are sagittal MPR. Asterisks indicate the main condition causing obstruction.

Figure 2: Enhanced MDCT study showing intestinal obstruction due to right colon cancer (asterisk) involving liver and gallbladder (thick arrow). The radiologic study reveals also the associate condition of fistula between colon and duodenum (thin arrow).

Figure 3: Enhanced MDCT showing a case of acute diverticulitis with severe concentric thickening of the intestinal wall (asterisk). The study reveals also some pericolonic fluids and inhomogeneity of the pericolonic fat (thin arrows). The associated condition of an anterior abscess collection touching the muscular layers is also detected (thick asterisk).

Figure 4: (A) Enhanced MDCT study in a case of acute abdomen due to emphysematous cholecystitis. The gallbladder shows thickened walls (thin arrow) and is filled by air bubbles mixed with some hypodense fluid content (thick arrow). The associated condition of a contiguous abscess collection due to parietal rupture of the organ is also detected (asterisk). (B) and (C) surgery confirmed the radiologic diagnoses.

Figure 5: A case of spontaneous rupture of abdominal aorta. Enhanced MDCT emergency study shows aortic fissuring indicated by interruption of parietal calcifications (thick arrow), extravasation of contrast medium (thin arrow), and retroperitoneal hematoma (asterisk).

Table 1: Concordance between MDCT findings and final diagnosis after surgery or autopsy in 181 cases of non-traumatic acute abdomen in the ED

Final diagnosis	Patients (n=181)	Complete concordance	Partial concordance	Incorrect diagnosis
Bowel obstruction	**77 (42.5)**	**71 (92.2)**	**3 (3.9)**	**3 (3.9)**
Cancer	*44*	*41*	*2*	*1*
Adhesions	*18*	*17*	*0*	*1*
Hernia	*8*	*7*	*1*	*0*
Intussusception	*5*	*5*	*0*	*0*
Volvulus	*2*	*1*	*0*	*1*
Inflammatory diseases	**62 (34.3)**	**54 (87.1)**	**7 (11.3)**	**1 (1.6)**
Diverticulitis	*25*	*21*	*3*	*1*
Appendicitis	*16*	*14*	*2*	*0*
Cholecystitis	*15*	*13*	*2*	*0*
Meckel's diverticulum	*3*	*3*	*0*	*0*
Crohn disease	*2*	*2*	*0*	*0*
Inflammatory pseudotumor	*1*	*1*	*0*	*0*
Intestinal perforation	**19 (10.5)**	**14 (73.7)**	**2 (10.5)**	**3 (15.8)**
Gastric ulcer	*3*	*2*	*0*	*1*
Duodenal ulcer	*6*	*3*	*1*	*2*
Iatrogenic	*2*	*2*	*0*	*0*
Cancer	*6*	*5*	*1*	*0*
Crohn disease	*2*	*2*	*0*	*0*
Vascular diseases	**15 (8.3)**	**13 (86.7)**	**2 (13.3)**	**0 (0.0)**
Intestinal infarction	*3*	*3*	*0*	*0*
Aortic rupture	*10*	*8*	*2*	*0*
Aortic dissection	*1*	*1*	*0*	*0*
Aortic thrombosis	*1*	*1*	*0*	*0*
Gynecological diseases	**5 (2.8)**	**3 (60.0)**	**1 (20.0)**	**1 (20.0)**
Ectopic pregnancy	*1*	*1*	*0*	*0*
Uterus torsion	*1*	*1*	*0*	*0*
Ovarian torsion	*1*	*0*	*0*	*1*
Ovarian cyst rupture	*1*	*1*	*0*	*0*
Mucinous cystoaden. rupture	*1*	*0*	*1*	*0*
Surgical foreign body	*1*	*1*	*0*	*0*
Gastric cancer	*1*	*1*	*0*	*0*
Colon cancer	*1*	*1*	*0*	*0*

Numbers in brackets represent the percentages of the total cases (second column) and the percentages for each group of diagnosis (third, fourth and fifth column)

Figure 1

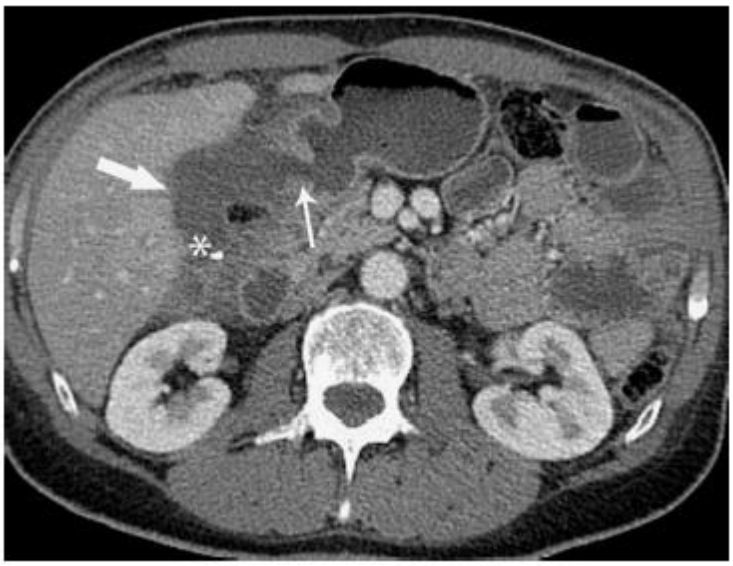

Figure 2

Figure 3

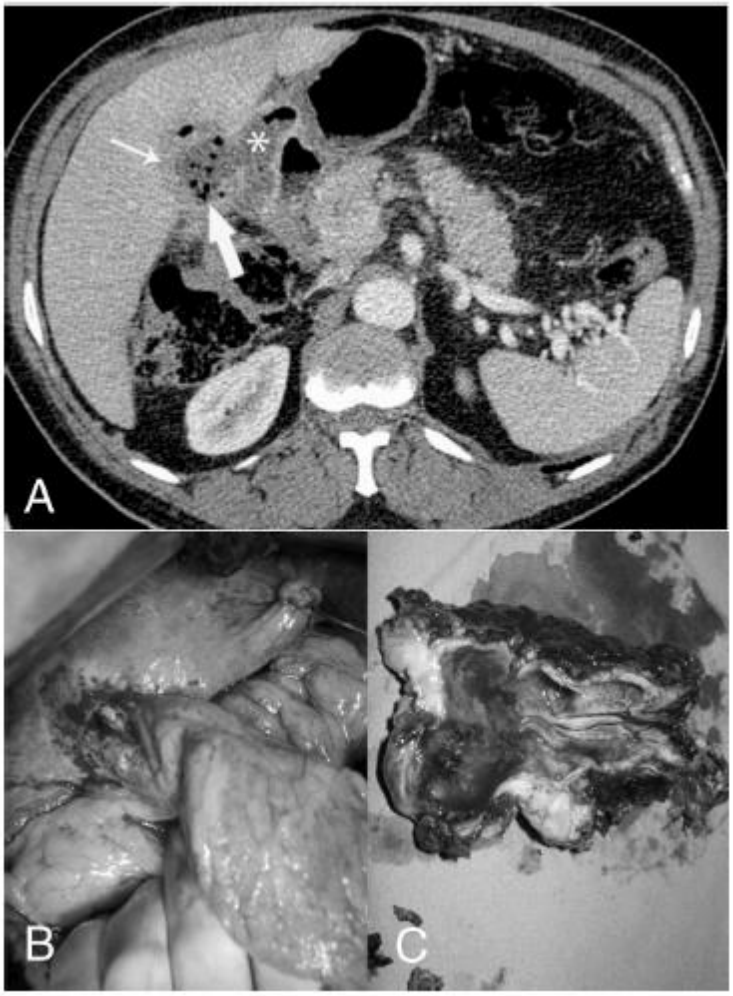

Figure 4

Figure 5