

AperTO - Archivio Istituzionale Open Access dell'Università di Torino

Complications during colonoscopy: prevention, diagnosis, and management

This is the author's manuscript

Original Citation:

Availability:

This version is available <http://hdl.handle.net/2318/1525945> since 2015-10-01T13:29:41Z

Published version:

DOI:10.1007/s10151-015-1344-z

Terms of use:

Open Access

Anyone can freely access the full text of works made available as "Open Access". Works made available under a Creative Commons license can be used according to the terms and conditions of said license. Use of all other works requires consent of the right holder (author or publisher) if not exempted from copyright protection by the applicable law.

(Article begins on next page)



UNIVERSITÀ DEGLI STUDI DI TORINO

This is an author version of the contribution published on:

Questa è la versione dell'autore dell'opera:

[Techniques in coloproctology, 19(9):505-513,2015 - DOI : 10.1007/s10151-015-1344-z]

The definitive version is available at:

La versione definitiva è disponibile alla URL:

<http://link.springer.com/article/10.1007%2Fs10151-015-1344-z>

Complications during colonoscopy: prevention, diagnosis, and management

- R. Manta, F. Tremolaterra, A. Arezzo, M. Verra, G. Galloro, L. Dioscoridi, F. Pugliese, A. Zullo, M. Mutignani and 1 more

¹Diagnostic and Interventional Digestive Endoscopy Unit, Niguarda Cà-Granda Hospital, Milano, Italy, r.manta@libero.it.

Abstract

Colonoscopy is largely performed in daily clinical practice for both diagnostic and therapeutic purposes. Although infrequent, different complications may occur during the examination, mostly related to the operative procedures. These complications range from asymptomatic and self-limiting to serious, requiring a prompt medical, endoscopic or surgical intervention. In this review, the complications that may occur during colonoscopy are discussed, with a particular focus on prevention, diagnosis, and therapeutic approaches.

Keywords

Colon Complications Colonoscopy Lower endoscopy Perforation Bleeding

Introduction

Colonoscopy is commonly performed worldwide for diagnosis and treatment of different diseases, as well as for colorectal cancer screening in developed countries. Although colonoscopy is generally safe and well tolerated, particularly when a conscious sedation is performed, nearly one-third of patients complain of transient gastrointestinal symptoms. These include bloating (until to 25 %), abdominal discomfort (10.5 %), diarrhea (6.3 %), nausea (4 %), and self-limiting bleeding (3.8 %) [1–4]. Fortunately, major complications are uncommon. In a systematic review of 12 studies including 57,742 screening colonoscopies, the rate of serious adverse events was found to be as low as 0.28 % [5]. Another study, based on a database of 2.3 million colonoscopies performed between 1997 and 2004, found that a complication requiring hospitalization occurred in 1.9 per 1000 colonoscopies [6]. In addition, >85 % of major complications were observed following an interventional colonoscopy [5]. Of note, a near sevenfold increased risk of bleeding or perforation has been observed following polypectomy [7]. Overall, the procedure-related mortality was reported to be as low as 0.09 % [8]. This review specifically focused on prevention, diagnosis, and therapeutic approaches of colonoscopy-related complications, while those associated with bowel preparation, which is performed before colonoscopy, are available elsewhere [9, 10].

Cardiopulmonary adverse events

Different types of cardiopulmonary adverse events have been described in the literature. Fluctuations in the heart rate and/or oxygen saturation are relatively common, but they are generally mild and probably of minor clinical relevance [11]. Significant complications are prolonged hypoxia, cardiac arrhythmias, vasovagal syndrome, hyper- or hypotension, and myocardial ischemia [10]. The incidence of these complications varies between 0.2 and 0.5 %, with a mortality rate ranging from 0.03 to 0.05 % [12]. Risk factors predisposing to cardiopulmonary adverse events include advanced age, associated comorbidities (particularly pulmonary diseases), anemia, presence of active bleeding, obesity, long-lasting or emergency procedures, and American Society of Anesthesiologists (ASA) III–IV class [13].

Excessive sedation may cause hypoxemia, aspiration, hypotension, arrhythmias, and vasovagal syndrome. Transient hypoxemia has been described in 0.23 % of cases, while prolonged hypoxemia is extremely rare, the incidence being only 7.8 on 100,000 colonoscopies [14]. It is noteworthy that the association between midazolam and an opioid, such as meperidine, increases the risk of hypoxemia as compared to the use of midazolam as a single agent [12]. Patients with severe chronic obstructive pulmonary disease (COPD) are at increased risk of hypercapnia during colonoscopy. Therefore, sedation in these patients should be appropriately balanced, and the endoscopic examination should be discontinued in case of excessive difficulty in colonoscope progression or excessive pain during the procedure. A review on sedation-related complications, including those occurring with propofol use, has been recently published [15].

Hypotension occurs in 0.48 % of colonoscopies, and it may depend not only on sedation but also on dehydration secondary to bowel preparation [12]. The vasovagal syndrome has been reported to occur in 0.19 % of colonoscopies, and it is maybe the result of a painful intubation, especially in the presence of a short mesosigma or patient anxiety [16]. The most frequent cardiac arrhythmia is sinus tachycardia [17], whereas bradycardia occurs in 0.28 % of cases, and more serious arrhythmias are extremely rare [12, 18].

When a severe disease (such as heart disease or COPD) is present, a careful evaluation of risk by a specialist before colonoscopy may be useful. Appropriate pulse-oximetry monitoring before, during, and after the procedure, and the adoption of minimum effective dose of sedatives, especially in patients with COPD, is mandatory. In addition, if the patient develops vasovagal syndrome or severe hypotension, the procedure should be stopped as should any infusion of fluids or atropine. Similarly, emergency colonoscopies in unstable patients should be avoided to reduce the risk of complications.

Perforation

Undeniably, perforation is the most worrying complication of diagnostic or therapeutic colonoscopy. In diagnostic colonoscopy, a perforation may develop either

during or immediately after the examination. The mechanisms involved are mechanical trauma caused by direct pressure from the endoscope against the colon wall (usually in the rectosigmoid segment or in the rectum during the retroflexion maneuver of the endoscope in a small rectum) or barotrauma due to excessive distension of the bowel (usually in the cecal region). Perforations occurring in diagnostic colonoscopies are generally large (>2 cm), while those that occur postoperatively due to thermal injury, such as argon plasma coagulation or electrocautery, are smaller. Both degree and duration of electrocautery play a role [19, 20]. An experimental study on polypectomy in pigs found that the use of tungsten instead of steel snares was significantly associated with a lower depth of tissue injury, suggesting a potential effect on reducing the risk of perforation [21]. The presence of adhesions, severe diverticular disease, mucosal inflammation, stenosis, comorbidities, advanced age, incorrect use of cutting or coagulation current, and limited operator experience are associated with a higher risk of perforation in diagnostic colonoscopies [6, 7, 22–24].

As expected, the incidence of perforation after therapeutic colonoscopy is distinctly higher than after diagnostic colonoscopy, and the risk varies according to the procedure (Table 1). Following standard polypectomy with snare, a perforation develops more frequently when polyps are >1 cm in the right colon or >2 cm in the left colon or when multiple polyps are removed [17, 25]. The mortality rate associated with iatrogenic perforation ranges from 0 to 0.65 % [26]. It has been suggested that an incidence of perforation greater than 1 out of 500 colonoscopies or greater than 1 out of 1000 in screening colonoscopies should prompt an audit for revision of procedures [27].

Table 1

Incidence rates of perforation associated with colonoscopy procedures

Procedure	Perforation (%)
Screening colonoscopy	0.01–0.1
Snare polypectomy	0.17
Endoscopic mucosal resection (EMR)	0–5
Endoscopic submucosal dissection (ESD)	5–10
Anastomotic stricture dilation	0–6
Crohn's disease stricture dilation	0–18
Colonic stent placement	4
Decompressive probe positioning	2

Perforation may occur during dilation of colonic stenosis, generally performed in Crohn's disease patients in one or more sessions. A systematic review found that a dilation-related perforation in these patients occurred in 13 (2 %) out of 347 cases, and no death plausibly related to pneumatic dilatation was described [28]. Another recent review evaluated data of balloon dilatation of benign rectal anastomotic strictures [29]. Overall, there were 9 (1.1 %) perforations following 850 procedures performed on 405 patients.

Stenting of either neoplastic or benign strictures is another therapeutic procedure potentially causing colon perforation. A recent meta-analysis found that perforation occurred in 207 (7.4 %) out of 4086 patients who underwent colorectal stent placement [30]. Stent type, benign etiology, and bevacizumab therapy were identified as risk factors for perforation following stenting as well as postprocedural reintervention dilation with the stent in situ, while intraprocedural stricture dilation either before or after stent placement was not associated with perforation. Local mucosal resections, including endoscopic mucosal resection (EMR) and endoscopic submucosal dissection (ESD), are increasingly performed to remove early neoplastic lesions in the colon. A definite risk of complications following these procedures is reported, even in expert hands (Fig. 1a). A meta-analysis of four Japanese studies, with data concerning 566 EMR and 661 ESD procedures, found that procedure-related complications occurred in 37 (5.8 %) and 56 (8.4 %) cases, respectively [31].

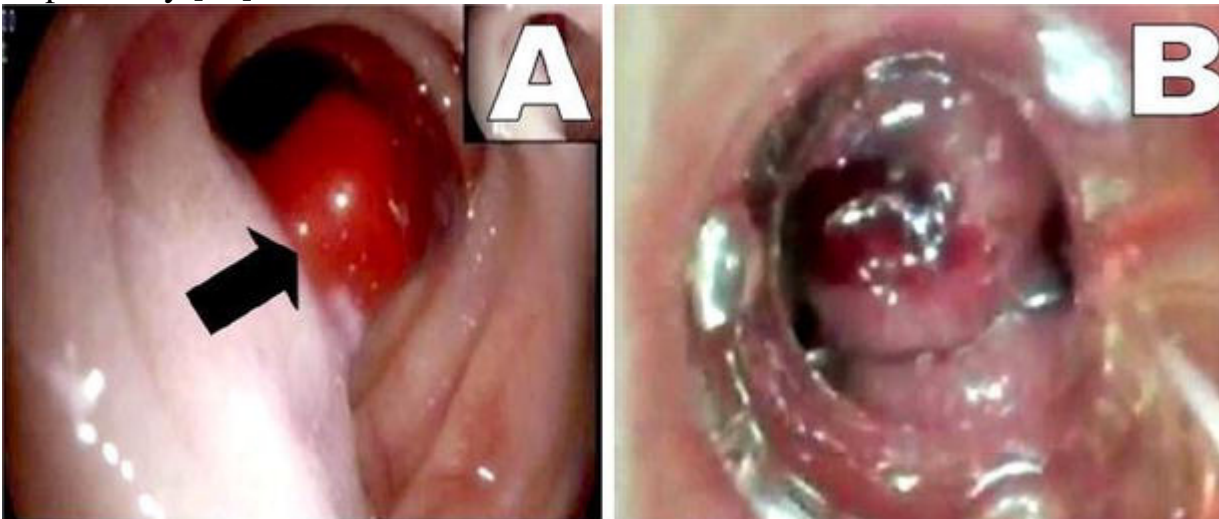


Fig. 1
Postpolypectomy bleeding (*black arrow*) (**a**) and endoscopic treatment with an over-the-scope clip (**b**)

Prevention

During the diagnostic phase, colonoscopy progression should be performed gently and cautiously, and loop formation should be avoided [32]. When abdominal pain occurs during the examination, alternative maneuvers (ancillary maneuver, compression, decubitus changes) should be used, and when an objective difficulty in progressing is observed, to desist is better than to inflict damage. The use of a pediatric colonoscope (or a standard gastroscope) may facilitate the passage through a substenotic or fixed colonic segment, which may occur in the sigmoid tract with diverticula. A judicious use of air insufflation may reduce the risk of perforation due to a barotrauma, especially in the presence of visceral stenosis [33]. The use of CO₂ or water, instead of air, further minimizes bowel distension, abdominal discomfort, and the risk of perforation [34–36]. However, some studies reported that water use for bowel distension could affect the adenoma detection rate [37, 38].

In the interventional procedures, the diathermy snare must be accurately positioned by promoting the lifting of the mucosa from the underlying muscle. It is also important to limit the amount of tissue included in the loop to a maximum of 2 cm. A prepolypectomy, submucosal injection of saline solution for creating a fluid cushion which separates the mucosa–submucosa layers (lifting) has been found to reduce the risk of electrocoagulative damage of muscularis propria [24]. Special attention should be paid during removal of polyps in the cecal region, where the thin wall may predispose to perforation. The use of mixed current mode may lead to far less deep tissue damage than pure coagulation mode. Some studies reported an increased risk of perforation in the course of small polyp removal with a hot biopsy forceps [39], while a low risk is associated with cold snaring polypectomy [40, 41].

As far as stenting treatment of malignant stenosis is concerned, a higher rate of perforation was reported in patients receiving chemotherapy with bevacizumab [42–44]. Therefore, stent placement in these patients should be discouraged. In addition, dilation of a stenotic area before or after stent placement is not advisable [45]. Similarly, dilation of either tumoral masses or actively inflamed segments in Crohn's disease patients should be avoided [28]. Finally, limited operator experience, i.e., during the learning curve, is associated with an increased risk perforation during EMR or ESD procedures [46, 47].

Diagnosis

Generally, a perforation occurs during or within the first 24 h after the procedure [48–50]. This is an advantage for both early detection and prognosis. Indeed, the colon is still clean so that the infection risk is reduced. During colonoscopy, the diagnosis is usually performed by direct vision of the wall defect or, after resection, by the so-called target sign, i.e., evidence of a muscle layer section on the resected lesion. In case of suspicion, an abdominal X-ray (1b) and/or abdominal CT scan (1c), with or without soluble contrast, are indicated. A late perforation should be suspected when abdominal pain, distension, signs of circumscribed peritonitis, fever, and/or leukocytosis occur following the procedure. The onset of generalized peritonitis, sepsis, and hemodynamic instability represents negative prognostic factors [51], requiring urgent surgery. The conventional surgical treatment of perforative complications is associated with a relatively high morbidity (between 5 and 30 %) and mortality [52].

Treatment

The management of colonic perforation depends on several factors, such as the site and characteristics of damage, and the clinical condition of the patient. Endoscopic treatment with endoclip positioning allows the closure of perforations, with a success rate ranging from 60 to 100 %, the success being higher in smaller defects [53]. However, a recent case report described a successful closure of a large colonic perforation (30 mm), following an endoscopic resection of a submucosal leiomyoma,

by applying seven endoclips [54]. Another device, available since 2007, is the over-the-scope clip (OTSC, Ovesco GmbH, Tuebingen, Germany). This system consists of a nitinol clip shaped as a ‘trap’ or ‘bear trap,’ making it possible to include a larger amount of tissue (≥ 20 mm). In a case series, treatment with OTSC application achieved a success rate of 100 % in 11 patients without a recurrence [55]. A systematic review on OTSC use in gastrointestinal perforations showed a procedural success rate as high as 80–100 %, and a clinical success rate ranging from 57 to 100 %, without major complications [56]. More recent studies showed resolution of perforation in 95 % of cases, as well as in over 80 % of anastomotic leakages, suggesting that OTSC positioning may reduce the need for surgery in several patients [57, 58]. When presence of extraluminal infection is excluded or the cavity is adequately drained by another route, partially or totally covered stents may be used to allow the closure of perforation. However, there is a high probability of stent migration, even in the presence of stenosis, and a potential risk of intolerance or tenesmus in the case of low rectal stent positioning. Finally, the assessment of safety and effectiveness of a novel suturing device, the Overstitch endoscopic suturing device (Apollo Endosurgery, Austin, TX, USA), is ongoing, so that the endoscopist will have another ‘ace up his/her sleeve’ to repair bowel perforation before resorting to a surgical approach [59, 60].

Bleeding

Bleeding is usually associated with polypectomy or other operative procedures and rarely develops following a diagnostic colonoscopy [61–63] (Fig. 2a). Indeed, the overall rate of bleeding varies from 0.1 to 1 % [1], being distinctly lower following diagnostic or screening examinations without polypectomy (0.2–0.4 %) than following operative colonoscopies with polypectomy (near 1 %) [64]. After polypectomy, bleeding can occur immediately, after a few days (usually 5–7) or even after 3–4 weeks [65]. Basically, the use of cutting or mixed current causes immediate bleeding, whereas pure coagulation current is associated with delayed hemorrhage [66, 67]. However, the use of mixed current far outweighs the risk of immediate bleeding, which is usually easily controlled. Higher rates of immediate (10 %) and delayed (14 %) bleeding were reported following resection of large (> 2 cm) polyps, especially in the right colon [3, 20, 68–74]. A retrospective evaluation of 4592 polypectomies showed that for every 1-mm increase in polyp diameter, the risk of hemorrhage increased by 9 % [75]. The role of polyp size in bleeding has also been confirmed in another analysis on 6617 polypectomies performed in Japan [73]. Sessile polyp, multiple polypectomies, unfavorable histology (villous or tubulovillous histotype), use of anticoagulants or dual antiplatelet therapy, presence of coagulopathy or cardiovascular diseases, and limited experience in operative endoscopy (< 80 procedures) are additional risk factors for bleeding [20, 50, 67, 76, 77].

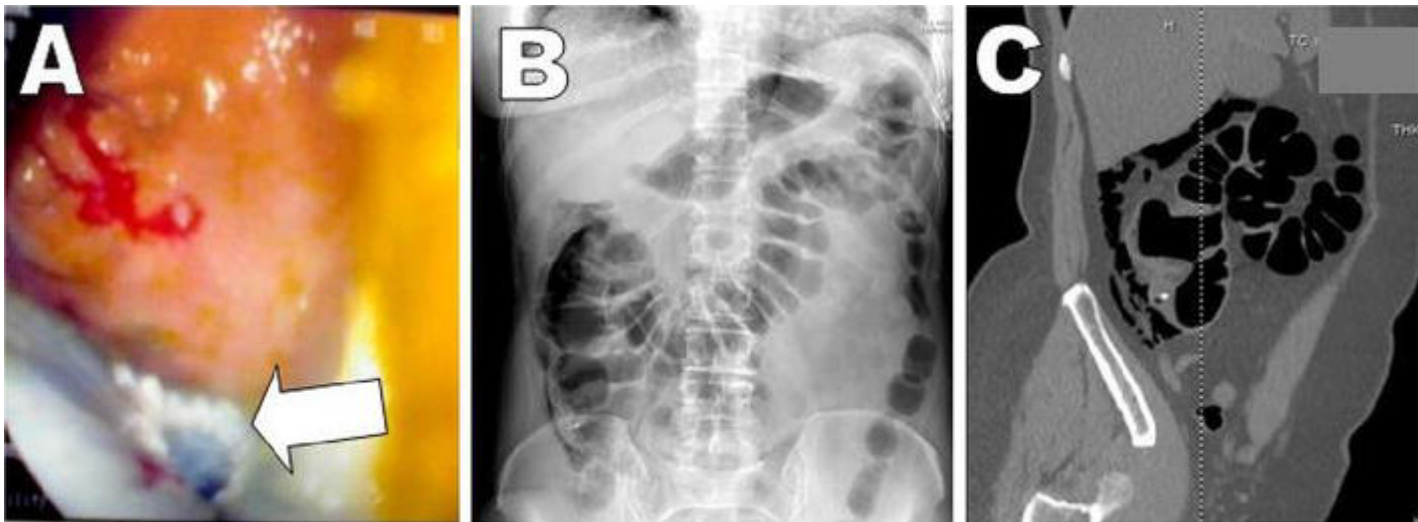

Fig. 2

Postendoscopic mucosal resection (EMR) perforation (*white arrow*) (a) with free air in the abdomen on X-ray (b) and computed tomography scan (c)

Prevention

The injection of saline or other fluids to dissociate the base of the polyp from the submucosal arterioles is thought to reduce the risk of hemorrhage. Addition of adrenaline in the solution can lower the incidence of immediate bleeding without affecting delayed hemorrhage [78, 79]. The diathermic snare needs to be closed slowly, coagulation current should be used predominantly, and the grip of polypoid tissue in the diathermic snare should not exceed 2 cm. For larger pedunculated polyps, the effectiveness of detachable snare positioning has been demonstrated [80], while the effectiveness of endoclips affixed to the base of the stalk is more controversial [81, 82]. Likewise, the use of hemoclips after polypectomy as bleeding prophylaxis is still a matter of debate [83–85]. Based on the available data, the prophylactic placement of endoscopic clips seems to be a cost-effective strategy only for those patients receiving antiplatelet or anticoagulation therapy [86]. However, if the polyp is very large (>2 cm) and positioned proximal to the splenic flexure, application of clips to prevent delayed bleeding could be a prudent approach. For small polyp resection, the use of a mini-snare without electrocautery instead of hot biopsy forceps is recommended [33]. Indeed, polypectomy with hot biopsy causes more submucosal damage, and it is associated with an increased risk of bleeding, especially when used in the right colon [32, 87].

Several studies showed that the use of aspirin is not associated with an increased risk of postpolypectomy bleeding, and therefore, aspirin therapy should not be interrupted for preventive purposes [69, 88]. However, in the presence of polyps at potentially higher risk of complications (for instance very large lesions, right localization), suspension of aspirin taken for primary cardiovascular prevention from 5 days before until 5 days after polypectomy would appear to be a judicious approach. Similarly, the American Society for Gastrointestinal Endoscopy (ASGE) guidelines recommend discontinuation of oral anticoagulants 5 days before the procedure, and replacement

with low molecular weight heparin in patients at high risk of thromboembolism [89, 90]. Although warfarin should be reintroduced on the evening of the procedure, a delayed resumption of therapy should be considered, at least for high-risk polypectomies [67].

Diagnosis

The diagnosis of immediate bleeding is usually intraprocedural. The diagnosis of delayed bleeding is made within 48 h in most cases, and it is heralded by the appearance of frank rectal bleeding or by detection of anemia with or without associated systemic symptoms of hemodynamic instability.

Treatment

Bleeding is essentially treated with an endoscopic approach, and surgery should be reserved only for those patients in whom endoscopic hemostasis is not effective. In case of mild bleeding, submucosal injection of adrenaline solution (dilution 1:10,000) can be effective, while in the presence of more severe hemorrhage, especially when the source of bleeding is visible, the application of endoclips ensures an high success rate [91, 92]. It should be considered that in case of bleeding after resection of pedunculated polyps, the stalk can be grasped and held tightly for a few minutes with the same diathermic snare. Then, a detachable snare or endoclips can be easily placed at the base. When massive bleeding after removal of a large and standard endoscopic clips are not sufficient to ensure an adequate compression of a large vessel, the application of an OTSC has been found to be successful without complications [93] (Fig. 2b). Hemostasis with electrocautery should be used with caution, particularly in the ascending colon, due to the increased risk of perforation.

During local mucosal resection (EMR, ESD), when clips may interfere with the procedure, application of monopolar current or bipolar forceps for oozing-type bleeding is particularly useful in the case of arterial bleeding [94]. In case of unsuccessful of endoscopic hemostasis, there is an indication for arterial embolization or surgery.

Postpolypectomy electrocoagulation syndrome

The reported incidence of postpolypectomy syndrome ranges from 0.003 to 0.1 % [1]. It is due to a full-thickness damage of colon wall by electrocoagulation during a polypectomy. The transmural burn reaching the serosa causes localized peritoneal irritation not associated with a radiologically evident perforation [95]. It occurs most frequently after removal of large sessile polyps or large (>2 cm) lateral spreading tumor (LST), which generally require greater amounts of current [22]. Fasting, intravenous antibiotic therapy, and hospitalization when needed generally resolve the symptoms in a few days. The submucosal injection of large amount of fluids would theoretically minimize the occurrence of this complication. Of note, the accidental

capture in the diathermy snare of a portion of the adjacent normal, i.e., without submucosal injection, can cause transmural burn syndrome in the involved area [22].

Infections

Transient bacteremia after a colonoscopy with or without polypectomy occurs in approximately 4 % of cases. However, these events are rarely symptomatic and usually not clinically relevant [96]. Sporadic cases of *Salmonella*, *Klebsiella*, *Enterobacter*, *Serratia*, and hepatitis B and C virus transmission have been described in the literature [97, 98], generally associated with an accidentally ineffective reprocessing of colonoscope. A recent review established that almost all cases of infection after colonoscopy are the consequence of defective endoscope cleaning or poor adherence to the procedures recommended in the guidelines [99, 100]. As a result, the only way to reduce the infection risk is a careful observation of standard cleaning procedures [94, 101].

Neither the American Heart Association nor the ASGE recommends antibiotic prophylaxis prior to colonoscopy in routine practice [94, 102]. However, sporadic cases of endocarditis have been described [103], so that prophylaxis in high-risk patients, such as those with prosthetic heart valves or previous endocarditis, would be appropriate. The decision should be performed on a case-by-case basis with the cooperation of a cardiologist [97].

Gas explosion

Large bowel explosions during colonoscopy have been reported only rarely but, as expected, with serious consequences. Indeed, a review of 9 cases reported 8 colonic perforations and 1 death following bowel explosion [104]. Explosion occurs when the concentration of hydrogen or methane in the colon is so high that the electrocautery energy used during an operative procedure may trigger the combustion in the presence of oxygen. The use of non-absorbable sugars, such as mannitol, lactulose, and sorbitol, for bowel preparation is an additional contributing factor [105, 106]. Similarly, an inadequate cleaning of the colon, particularly when only enemas are used as in the case of rectosigmoidoscopies, may predispose to the colon explosion during an operative procedure [107]. As a preventive measure, insufflation with CO₂, instead of air, has been proposed [108].

Miscellaneous complications

Rare complications of colonoscopy include hematoma or rupture of the spleen [109], acute appendicitis [110], ischemic colitis [111], and strangulation of hernias [112]. Chemical colitis due to glutaraldehyde has been also reported, when it used for sterilization and the endoscope was not properly rinsed, requiring hospitalization in some cases [113]. Chemical colitis due to peracetic acid has been also described, but it is generally self-limiting, and without consequence for the patient [114].

Conclusions

Colonoscopy has an important diagnostic and therapeutic role in the management of many colonic diseases. Its use in colorectal cancer screening has been implemented in several developed countries. Therefore, thousands of colonoscopies are performed every day worldwide. Although colonoscopy is generally a safe procedure, some adverse events and complications may occur. The knowledge of different complications, their estimated frequency, and the risk factors involved are crucial for early diagnosis and management in order to reduce the risks for the patient and to improve the quality of colonoscopy.

Ethical approval

This article does not contain any studies with human participants or animals performed by any of the authors.

References

1.

Ko CW, Dominitz JA (2010) Complications of colonoscopy: magnitude and management. *Gastrointest Endosc Clin N Am* 20:659–671

2.

Ko CW, Riffle S, Shapiro JA et al (2007) Incidence of minor complications and time lost from normal activities after screening or surveillance colonoscopy. *Gastrointest Endosc* 65:648–656

3.

Zubarik R, Fleischer DE, Mastropietro C et al (1999) Prospective analysis of complications 30 days after outpatient colonoscopy. *Gastrointest Endosc* 50:322–328

4.

Bini EJ, Firoozi B, Choung RJ, Ali EM, Osman M, Weinshel EH (2003) Systematic evaluation of complications related to endoscopy in a training setting: a prospective 30-day outcomes study. *Gastrointest Endosc* 57:8–16

5.

Whitlock EP, Lin JS, Liles E, Beil TL, Fu R (2008) Screening for colorectal cancer: a targeted, updated systematic review for the U.S. Preventive Services Task Force. *Ann Intern Med* 149:638–658

6.

Chukmaitov A, Bradley CJ, Dahman B, Siangphoe U, Warren JL, Klabunde CN (2013) Association of polypectomy techniques, endoscopist volume, and facility type with colonoscopy complications. *Gastrointest Endosc* 77:436

7.

Rabeneck L, Paszat LF, Hilsden RJ et al (2008) Bleeding and perforation after outpatient colonoscopy and their risk factors in usual clinical practice. *Gastroenterology* 135:1899–1906

8.

Fisher DA, Maple JT, Ben-Menachem T, ASGE Standards of Practice Committee et al (2011) Complications of colonoscopy. *Gastrointest Endosc* 74:745

9.

Parra-Blanco A, Ruiz A, Alvarez-Lobos M et al (2014) Achieving the best bowel preparation for colonoscopy. *World J Gastroenterol* 20:17709–17726

10.

Hassan C, Bretthauer M, Kaminski MF et al (2013) Bowel preparation for colonoscopy: European Society of Gastrointestinal Endoscopy (ESGE) guideline. *Endoscopy* 45:142–150

11.

Cotton PB, Eisen GM, Aabakken L et al (2010) A lexicon for endoscopic adverse events: report of an ASGE workshop. *Gastrointest Endosc* 71:446–454

12.

Arrowsmith JB, Gerstman BB, Fleischer DE, Benjamin SB (1991) Results from the American Society for Gastrointestinal Endoscopy/U.S. Food and Drug Administration collaborative study on complication rates and drug use during gastrointestinal endoscopy. *Gastrointest Endosc* 37:421

13.

Sharma VK, Nguyen CC, Crowell MD, Lieberman DA, de Garmo P, Fleischer DE (2007) A national study of cardiopulmonary unplanned events after GI endoscopy. *Gastrointest Endosc* 66:27

14.

Jurell KR, O'Connor KW, Slack J et al (1994) Effect of supplemental oxygen on cardiopulmonary changes during gastrointestinal endoscopy. *Gastrointest Endosc* 40:665

15.

Triantafillidis JK, Merikas E, Nikolakis D, Papalois AE (2013) Sedation in gastrointestinal endoscopy: current issues. *World J Gastroenterol* 19:463–481

16.

Herman LL, Kurtz RC, McKee KJ, Sun M, Thaler HT, Winawer SJ (1993) Risk factors associated with vasovagal reactions during colonoscopy. *Gastrointest Endosc* 39:388–391

Lieberman DA, Wuerker CK, Katon RM (1985) Cardiopulmonary risk of esophagogastroduodenoscopy. Role of endoscope diameter and systemic sedation. *Gastroenterology* 88:468–472

17.

Gupta SC, Gopalswamy N, Sarkar A, Suryaprasad AG, Markert RJ (1990) Cardiac arrhythmias and electrocardiographic changes during upper and lower gastrointestinal endoscopy. *Mil Med* 155:9–11

Raju GS, Saito Y, Matsuda T, Kaltenbach T, Soetikno R (2011) Endoscopic management of colonoscopic perforations (with videos). *Gastrointest Endosc* 74:1380–1388

Heldwein W, Dollhopf M, Rosch T et al (2005) The Munich Polypectomy Study (MUPS): prospective analysis of complications and risk factors in 4000 colonic snare polypectomies. *Endoscopy* 37:1116–1122

18..

Galloro G, Magno L, Ruggiero S et al (2013) Comparison between tungsten and steel polypectomy snares: evaluation of depth of colonic thermal wall injury in a pig model. *Endoscopy* 45:121–126

19.

Bielawska B, Day AG, Lieberman DA, Hookey LC (2014) Risk factors for early colonoscopic perforation include non-gastroenterologist endoscopists: a multivariable analysis. *Clin Gastroenterol Hepatol* 12:85–92

Dafnis G, Ekbohm A, Pahlman L, Blomqvist P (2001) Complications of diagnostic and therapeutic colonoscopy within a defined population in Sweden. *Gastrointest Endosc* 54:302–329

Iqbal CW, Cullinane DC, Schiller HJ, Sawyer MD, Zietlow SP, Farley DR (2008) Surgical management and outcomes of 165 colonoscopic perforations from a single institution. *Arch Surg* 143:701–716

20.

Choo WK, Subhani J (2012) Complication rates of colonic polypectomy in relation to polyp characteristics and techniques: a district hospital experience. *J Interv Gastroenterol* 2:8–11

21.

Putcha RV, Burdick JS (2003) Management of iatrogenic perforation. *Gastroenterol Clin North Am* 32:1289–1309

22.

Rex DK, Petrini JL, Baron TH et al (2006) Quality indicators for colonoscopy. *Gastrointest Endosc* 63(suppl 4):S16–S28

23.

Hassan C, Zullo A, De Francesco V et al (2007) Systematic review: endoscopic dilatation in Crohn's disease. *Aliment Pharmacol Ther* 26:1457–1464

24.

Ragg J, Garimella V, Cast J, Hunter IA, Hartley JE (2012) Balloon dilatation of benign rectal anastomotic strictures—a review. *Dig Surg* 29:287–291

25.

Van Halsema EE, van Hooft JE, Small AJ et al (2014) Perforation in colorectal stenting: a meta-analysis and a search for risk factors. *Gastrointest Endosc* 79:970–982

26.

Wang J, Zhang XH, Ge J, Yang CM, Liu JY, Zhao SL (2014) Endoscopic submucosal dissection vs endoscopic mucosal resection for colorectal tumors: a meta-analysis. *World J Gastroenterol* 20:8282–8287

27.

Church J (1995) *Endoscopy of the colon and rectum*. Igaku Shoin/Williams and Wilkins Publishers, New York

28.

Woltjen JA (2005) A retrospective analysis of cecal barotrauma caused by colonoscope air flow and pressure. *Gastrointest Endosc* 61:37–45

29.

Riss S, Akan B, Mikola B et al (2009) CO₂ insufflation during colonoscopy decreases post-interventional pain in deeply sedated patients: a randomized controlled trial. *Wien Klin Wochenschr* 121:464–468

30.

Leung CW, Kaltenbach T, Soetikno R, Wu KK, Leung FW, Friedland S (2010) Water immersion versus standard colonoscopy insertion technique: randomized trial shows promise for minimal sedation. *Endoscopy* 42:557–563

31.

Leung JW, Mann SK, Siao-Salera R et al (2009) A randomized, controlled comparison of warm water infusion in lieu of air insufflation versus air insufflations for aiding colonoscopy insertion in sedated patients undergoing colorectal cancer screening and surveillance. *Gastrointest Endosc* 70:505–510

32.

Leung FW, Amato A, Ell C et al (2012) Water-aided colonoscopy: a systematic review. *Gastrointest Endosc* 76:657–666

33.

Radaelli F, Paggi S, Amato A, Terruzzi V (2010) Warm water infusion versus air insufflation for unsedated colonoscopy: a randomized, controlled trial. *Gastrointest Endosc* 72:701–719

34.

Weston AP, Campbell DR (1995) Diminutive colonic polyps: histopathology, spatial distribution, concomitant significant lesions, and treatment complications. *Am J Gastroenterol* 90:24–28

35.

Tappero G, Gaia E, De Giuli P, Martini S, Gubetta L, Emanuelli G (1992) Cold snare excision of small colorectal polyps. *Gastrointest Endosc* 38:310–313

36.

Deenadayalu VP, Rex DK (2005) Colon polyp retrieval after cold snaring. *Gastrointest Endosc* 62:253–256

37.

Small AJ, Coelho-Prabhu N, Baron TH (2010) Endoscopic placement of self-expandable metal stents for malignant colonic obstruction: long-term outcomes and complication factors. *Gastrointest Endosc* 71:560–572

38.

Manes G, de Bellis M, Fuccio L et al (2011) Endoscopic palliation in patients with incurable malignant colorectal obstruction by means of self-expanding metal stent: analysis of results and predictors of outcomes in a large multicenter series. *Arch Surg* 146:1157–1162

39.

Cennamo V, Fuccio L, Mutri V et al (2009) Does stent placement for advanced colon cancer increase the risk of perforation during bevacizumab-based therapy? *Clin Gastroenterol Hepatol* 7:1174–1176

40.

Harrison ME, Anderson MA, Appalaneni V et al (2010) The role of endoscopy in the management of patients with known and suspected colonic obstruction and pseudo-obstruction. *Gastrointest Endosc* 71:669–679

41.

Huang C, Huang RX, Xiang P, Qiu ZJ (2012) Current research status of endoscopic submucosal dissection for colorectal neoplasms. *Clin Invest Med* 35:158–164

42.

Yoshida N, Yagi N, Naito Y, Yoshikawa T (2010) Safe procedure in endoscopic submucosal dissection for colorectal tumors focused on preventing complications. *World J Gastroenterol* 16:1688–1695

43.

Kapetanios D, Beltsis A, Chatzimavroudis G, Katsinelos P (2012) Post polypectomy bleeding: incidence, risk factors, prevention, and management. *Surg Laparosc Endosc Percutan Tech* 22:102–117

44.

Hotta K, Yamaguchi Y, Saito Y, Takao T, Ono H (2012) Current opinions for endoscopic sub-mucosal dissection for colorectal tumors from our experiences: indications, technical aspects and complications. *Dig Endosc* 24(Suppl. 1):110–116

45.

Burgess NG, Metz AJ, Williams SJ et al (2014) Risk factors for intraprocedural and clinically significant delayed bleeding after wide-field endoscopic mucosal resection of large colonic lesions. *Clin Gastroenterol Hepatol* 12:651–661

46.

Samalavicius NE, Kazanavicius D, Lunevicius R et al (2013) Incidence, risk, management, and outcomes of iatrogenic full-thickness large bowel injury associated with 56,882 colonoscopies in 14 Lithuanian hospitals. *Surg Endosc* 27:1628–1635

47.

Luning TH, Keemers-Gels ME, Barendregt WB, Tan AC, Rosman C (2007) Colonoscopic perforations: a review of 30,366 patients. *Surg Endosc* 21:994–997

48.

Trecca A, Gaj F, Gagliardi G (2008) Our experience with endoscopic repair of large colonoscopic perforations and review of the literature. *Tech Coloproctol* 12:315–321

49.

Magdeburg R, Collet P, Post S, Kaehler G (2008) Endoclipping of iatrogenic colonic perforation to avoid surgery. *Surg Endosc* 22:1500–1504

50.

Kirschniak A, Subotova N, Zieker D, Königsrainer A, Kratt T (2011) The Over-The-Scope Clip (OTSC) for the treatment of gastrointestinal bleeding, perforations, and fistulas. *Surg Endosc* 25:2901–2905

51.

Weiland T, Fehlker M, Gottwald T, Schurr MO (2013) Performance of the OTSC System in the endoscopic closure of iatrogenic gastrointestinal perforations: a systematic review. *Surg Endosc* 27:2258–2274

52.

Arezzo A, Verra M, Reddavid R, Cravero F, Bonino MA, Morino M (2012) Efficacy of the over-the-scope clip (OTSC) for treatment of colorectal postsurgical leaks and fistulas. *Surg Endosc* 26:3330–3333

53.

Haito-Chavez Y, Law JK, Kratt T et al (2014) International multicenter experience with an over-the-scope clipping device for endoscopic management of GI defects (with video). *Gastrointest Endosc* 80:610–622

54.

Pauli EM, Delaney CP, Champagne B, Stein S, Marks JM (2013) Safety and effectiveness of an endoscopic suturing device in a human colonic treat-and-resect model. *Surg Innov* 20:594–599

55.

González-Panizo-Tamargo F, Rojas-Sánchez A, Miranda-García P, Juzgado-Lucas D, Vázquez-Sequeiros E (2014) Endoscopic management of common pathologies with a new suturing system. *Rev Esp Enferm Dig* 106:413–417

56.

Wexner SD, Garbus JE, Singh JJ, SAGES Colonoscopy Study Outcomes Group (2001) A prospective analysis of 13,580 colonoscopies. Reevaluation of credentialing guidelines. *Surg Endosc* 15:251–261

57.

Waye JD, Kahn O, Auerbach ME (1996) Complications of colonoscopy and flexible sigmoidoscopy. *Gastrointest Endosc Clin N Am* 6:343–377

58.63.

Kavic SM, Basson MD (2001) Complications of endoscopy. *Am J Surg* 181:319–332

59.

Warren JL, Klabunde CN, Mariotto AB et al (2009) Adverse events after outpatient colonoscopy in the Medicare population. *Ann Intern Med* 150:849–857

60.

Singaram C, Torbey CF, Jacoby RF (1995) Delayed postpolypectomy bleeding. *Am J Gastroenterol* 90:146–147

61.

Van Gossum A, Cozzoli A, Adler M, Taton G, Cremer M (1992) Colonoscopic snare polypectomy: analysis of 1485 resections comparing two types of current. *Gastrointest Endosc* 38:472–475

62.

Parra-Blanco A, Kaminaga N, Kojima T, Endo Y, Tajiri A, Fujita R (2000) Colonoscopic polypectomy with cutting current: is it safe? *Gastrointest Endosc* 51:676–681

63.

Saito Y, Uraoka T, Yamaguchi Y et al (2010) A prospective, multicenter study of 1111 colorectal endoscopic submucosal dissections (with video). *Gastrointest Endosc* 72:1217–1225

64.

Sorbi D, Norton I, Conio M, Balm R, Zinsmeister A, Gostout CJ (2000) Postpolypectomy lower GI bleeding: descriptive analysis. *Gastrointest Endosc* 51:690–696

65.

Hurlstone DP, Sanders DS, Cross SS et al (2004) Colonoscopic resection of lateral spreading tumours: a prospective analysis of endoscopic mucosal resection. *Gut* 53:1334–1339

66.

Consolo P, Luigiano C, Strangio G et al (2008) Efficacy, risk factors and complications of endoscopic polypectomy: ten year experience at a single center. *World J Gastroenterol* 14:2364–2369

67.

Kim HS, Kim TI, Kim WH et al (2006) Risk factors for immediate postpolypectomy bleeding of the colon: a multicenter study. *Am J Gastroenterol* 101:1333–1341

68.

Watabe H, Yamaji Y, Okamoto M et al (2006) Risk assessment for delayed hemorrhagic complication of colonic polypectomy: polyp-related factors and patient-related factors. *Gastrointest Endosc* 64:73–78

69.

Buddingh KT, Herngreen T, Haringsma J et al (2011) Location in the right hemi-colon is an independent risk factor for delayed post-polypectomy hemorrhage: a multi-center case-control study. *Am J Gastroenterol* 106:1119–1124

70.

Sawhney MS, Salfiti N, Nelson DB, Lederle FA, Bond JH (2008) Risk factors for severe delayed postpolypectomy bleeding. *Endoscopy* 40:115–119

71.

Singh M, Mehta N, Murthy UK, Kaul V, Arif A, Newman N (2010) Postpolypectomy bleeding in patients undergoing colonoscopy on uninterrupted clopidogrel therapy. *Gastrointest Endosc* 71:998–1005

72.

Witt DM, Delate T, McCool KH et al (2009) Incidence and predictors of bleeding or thrombosis after polypectomy in patients receiving and not receiving anticoagulation therapy. *J Thromb Haemost* 7:1982–1989

73.

Hsieh YH, Lin HJ, Tseng GY et al (2001) Is submucosal epinephrine injection necessary before polypectomy? A prospective, comparative study. *Hepatogastroenterology* 48:1379–1382

74.

Di Giorgio P, De Luca L, Calcagno G, Rivellini G, Mandato M, De Luca B (2004) Detachable snare versus epinephrine injection in the prevention of postpolypectomy bleeding: a randomized and controlled study. *Endoscopy* 36:860–863

75.

Iishi H, Tatsuta M, Narahara H, Iseki K, Sakai N (1996) Endoscopic resection of large pedunculated colorectal polyps using a detachable snare. *Gastrointest Endosc* 44:594–597

76..

Luigiano C, Ferrara F, Ghersi S et al (2010) Endoclip-assisted resection of large pedunculated colorectal polyps: technical aspects and outcome. *Dig Dis Sci* 55:1726–1731

77.

Shioji K, Suzuki Y, Kobayashi M et al (2003) Prophylactic clip application does not decrease delayed bleeding after colonoscopic polypectomy. *Gastrointest Endosc* 57:691–694

78.

Feagins LA, Nguyen AD, Iqbal R, Spechler SJ (2014) The prophylactic placement of hemoclips to prevent delayed post-polypectomy bleeding: an unnecessary practice? A case control study. *Dig Dis Sci* 59:823–828

79.

Quintanilla E, Castro JL, Rabago LR et al (2012) Is the use of prophylactic hemoclips in the endoscopic resection of large pedunculated polyps useful? A prospective and randomized study. *J Interv Gastroenterol* 2:183–188

80.

Liaquat H, Rohn E, Rex DK (2013) Prophylactic clip closure reduced the risk of postpolypectomy hemorrhage: experience in 277 clipped large sessile or flat colorectal lesions and 247 control lesions. *Gastrointest Endosc* 77:401–407

81.

Parikh ND, Zanicco K, Keswani RN, Gawron AJ (2013) A cost-efficacy decision analysis of prophylactic clip placement after endoscopic removal of large polyps. *Clin Gastroenterol Hepatol* 11:1319–1324

82.

Gilbert DA, DiMarino AJ, Jensen DM et al (1992) Status evaluation: hot biopsy forceps. *Gastrointest Endosc* 38:753–756

83.

Hui AJ, Wong RM, Ching JY, Hung LC, Chung SC, Sung JJ (2004) Risk of colonoscopic polypectomy bleeding with anticoagulants and antiplatelet agents: analysis of 1657 cases. *Gastrointest Endosc* 59:44–48

84.

Anderson MA, Ben-Menachem T, Gan SI et al (2009) Management of antithrombotic agents for endoscopic procedures. *Gastrointest Endosc* 70:1060–1070

85.

Zuckerman MJ, Hirota WK, Adler DG et al (2005) ASGE guideline: the management of low-molecular-weight heparin and nonaspirin antiplatelet agents for endoscopic procedures. *Gastrointest Endosc* 61:189–194

86.

Jacques J, Legros R, Chaussade S, Sautereau D (2014) Endoscopic haemostasis: an overview of procedures and clinical scenarios. *Dig Liver Dis* 46:766–776

87.

Arezzo A, Verra M, Cravero F, Reddavid R, Morino M (2011) How to place hemoclips to achieve hemostasis of a bleeding diverticulum. *Dig Dis Sci* 56:1589–1590

88.

Manta R, Galloro G, Mangiavillano B et al (2013) Over-the-scope clip (OTSC) represents an effective endoscopic treatment for acute GI bleeding after failure of conventional techniques. *Surg Endosc* 27:3162–3164

89.

Takizawa K, Oda I, Gotoda T et al (2008) Routine coagulation of visible vessels may prevent delayed bleeding after endoscopic submucosal dissection—an analysis of risk factors. *Endoscopy* 40:179–183

90.95.

Waye JD (1981) The postpolypectomy coagulation syndrome. *Gastrointest Endosc* 27:184

91.

Nelson DB (2003) Infectious disease complications of GI endoscopy: part II, exogenous infections. *Gastrointest Endosc* 57:695–711

92.

Dwyer DM, Klein EG, Istre GR, Robinson MG, Neumann DA, McCoy GA (1987) Salmonella newport infections transmitted by fiberoptic colonoscopy. *Gastrointest Endosc* 33:84–87

93.

Nelson DB, Barkun AN, Block KP et al (2001) Technology status evaluation report. Transmission of infection by gastrointestinal endoscopy. *Gastrointest Endosc* 54:824–828

94.

American Society for Gastrointestinal Endoscopy (2003) Multi-society guideline for reprocessing flexible gastrointestinal endoscopes. *Gastrointest Endosc* 58:1–8

95.

Wilson W, Taubert KA, Gewitz M et al (2007) Prevention of infective endocarditis. *Circulation* 116:1736–1754

96.

Petersen BT, Chennat J, Cohen J et al (2011) Multisociety guideline on reprocessing flexible gastrointestinal endoscopes: 2011. *Gastrointest Endosc* 73:1075–1084

97.

Banerjee S, Shen B, Baron TH et al (2008) Antibiotic prophylaxis for GI endoscopy. *Gastrointest Endosc* 67:791–798

98.

Schembre DB (2000) Infectious complications associated with gastrointestinal endoscopy. *Gastrointest Endosc Clin N Am* 10:215–232

99.

Ladas SD, Karamanolis G, Ben-Soussan E (2007) Colonic gas explosion during therapeutic colonoscopy with electrocautery. *World J Gastroenterol* 13:5295–5298

100.

Avgerinos A, Kalantzis N, Rekoumis G, Pallikaris G, Arapakis G, Kanaghinis T (1984) Bowel preparation and the risk of explosion during colonoscopic polypectomy. *Gut* 25:361–364

101.

La Brooy SJ, Avgerinos A, Fendick CL, Williams CB, Misiewicz JJ (1981) Potentially explosive colonic concentrations of hydrogen after bowel preparation with mannitol. *Lancet* 1:634–636

102.

- Monahan DW, Peluso FE, Goldner F (1992) Combustible colonic gas levels during flexible sigmoidoscopy and colonoscopy. *Gastrointest Endosc* 38:40–43
- 103.
- Hofstad B (2007) Explosion in rectum. *Tidsskr Nor Laegeforen* 127:1789–1790
- 104.
- Rao KV, Beri GD, Sterling MJ, Salen G (2009) Splenic injury as a complication of colonoscopy: a case series. *Am J Gastroenterol* 104:1604–1605
- 105.
- Izzedine H, Thauvin H, Maisel A, Bourry E, Deschamps A (2005) Post-colonoscopy appendicitis: case report and review of the literature. *Am J Gastroenterol* 100:2815–2817
- 106.
- Arhan M, Onal IK, Odemis B, Ibiş M, Saşmaz N (2009) Colonoscopy-induced ischemic colitis in a young patient with no risk factor. *Am J Gastroenterol* 104:250–251
- 107.
- Chae HS, Kim SS, Han SW et al (2002) Herniation of the large bowel through a post traumatic diaphragmatic defect during colonoscopy: report of a case. *Dis Colon Rectum* 45:1261–1262
- 108.
- Ahishali E, Uygur-Bayramicli O, Dolapcioglu C et al (2009) Chemical colitis due to glutaraldehyde: case series and review of the literature. *Dig Dis Sci* 54:2541–2545
- 114.
- Morini S, Campo SM, Zullo A, Guarini A, Ridola L, Hassan C (2009) Chemical colitis induced by peracetic acid: further evidence. *Endoscopy* 41:383