

AperTO - Archivio Istituzionale Open Access dell'Università di Torino

Is laparoscopic surgery the best treatment in fistulas complicating diverticular disease of the sigmoid colon? A systematic review

This is the author's manuscript

Original Citation:

Availability:

This version is available <http://hdl.handle.net/2318/1529664> since 2016-01-22T14:42:13Z

Published version:

DOI:10.1016/j.ijssu.2015.11.007

Terms of use:

Open Access

Anyone can freely access the full text of works made available as "Open Access". Works made available under a Creative Commons license can be used according to the terms and conditions of said license. Use of all other works requires consent of the right holder (author or publisher) if not exempted from copyright protection by the applicable law.

(Article begins on next page)



UNIVERSITÀ DEGLI STUDI DI TORINO

This is an author version of the contribution published on:

Questa è la versione dell'autore dell'opera:

International Journal of Surgery, Volume 24, Part A, Pages 95–100, 2015,

DOI: doi:10.1016/j.ijisu.2015.11.007

The definitive version is available at:

La versione definitiva è disponibile alla URL:

<http://www.sciencedirect.com/science/article/pii/S1743919115013114>

Is laparoscopic surgery the best treatment in fistulas complicating diverticular disease of the sigmoid colon? A systematic review

- Roberto Cirocchi^a, Alberto Arezzo^b, Claudio Renzi^c, Giovanni Cochetti^d, Vito D'Andrea^e, Abe Fingerhut^f, Ettore Mearini^d, Gian Andrea Binda^g
- ^a Department of Digestive Surgery and Liver Unit, University of Perugia, St Maria Hospital, Viale Tristano di Joannuccio, 1, 05100 Terni, Italy
- ^b Department of Surgical Sciences, University of Turin, C.So Dogliotti, 38, 10126 Torino, Italy
- ^c Department of General and Oncologic Surgery, University of Perugia, S. Andrea delle Fratte, Piazzale Menghini, 1, 06157 Perugia, Italy
- ^d Department of Surgical and Biomedical Science, Institute of Urological, Andrological Surgery and Minimally Invasive Techniques, University of Perugia, Viale Tristano di Joannuccio, 1, 05100 Terni, Italy
- ^e Department of Surgical Sciences, 'Sapienza' University of Rome, Viale Regina Elena 324, 00185 Rome, Italy
- ^f Section for Surgical Research (Prof Uranues), Department of Surgery, Medical University of Graz, Auenbruggerplatz 29, 8036 Graz, Austria
- ^g Department of General Surgery, Galliera Hospital, Mura Delle Cappuccine, 14, 16128 Genoa, Italy

Highlights

- Laparoscopy in diverticular fistula may reduce complications compared to open surgery.
 - No significant difference for recurrence, early reintervention, need for diversion.
 - Outcomes of laparoscopic primary anastomosis should be interpreted with caution.
-

Abstract

Introduction

Laparoscopic surgery is considered in the treatment of diverticular fistula for the possible reduction of overall morbidity and complication rate if compared to open surgery. Aim of this review is to assess the possible advantages deriving from a laparoscopic approach in the treatment of diverticular fistulas of the colon.

Methods

Studies presenting at least 10 adult patients who underwent laparoscopic surgery for sigmoid diverticular fistula were reviewed. Fistula recurrence, reintervention, Hartmann's procedure or proximal diversion, conversion to laparotomy were the outcomes considered.

Results

11 non randomized studies were included. Rates of fistula recurrence (0.8%), early reintervention (30 days) (2%) and need for Hartmann's procedure or proximal diversion (1.4%) did not show significant difference between laparoscopy and open technique.

Discussion

there is still concern about which surgery in complicated diverticulitis should be preferred. Laparoscopic approach has led to less postoperative pain, shorter hospital stay, faster recovery and better cosmetic results. Laparoscopic resection and primary anastomosis is a possible approach to sigmoid fistulas but its advantages in terms of lower mortality rate and postoperative stay after colon resection with primary anastomosis should be interpreted with caution. When there is firm evidence supporting it, it is likely that minimally invasive surgery should become the standard approach for diverticular fistulas, thus achieving adequate exposure and better visualization of the surgical field.

Conclusion

The lack of RCTs, the small sample size, the heterogeneity of literature do not allow to draw statistically significant conclusions on the laparoscopic surgery for fistulas despite this approach is considered safe.

Keywords

- Diverticular fistula; Diverticulitis; Laparoscopic surgery; Colon; Bladder
-

1. Introduction

Colonic diverticular disease is widespread in Western countries and its incidence increases with aging. Whereas 80–85% of patients affected by diverticula remain asymptomatic, 15% develop symptomatic diverticular disease, but no inflammatory signs. About 10%–20% of individuals suffering from diverticulosis will have acute diverticulitis and only 2% develop complications of diverticulitis such as abscess, fistula, obstruction or hemorrhage [1] and [2]. Complications of diverticulitis include intra-abdominal perforation, external cutaneous fistulas or viscerovisceral fistulas (small bowel, kidney, uterus, bladder, vagina) or fistulas which penetrate in the retroperitoneal space. The majority of perforations and fistulas occurs in the sigmoid colon, the colonic tract most frequently involved by diverticula. Starting from the less frequent ones diverticular fistulas may present as colovaginal, coloenteric, colouterine, colocutaneous, or colovesical [3]. Management of diverticular fistulas is surgical since fistulas generally do not close spontaneously. Despite this the presence of a fistula is rarely an indication for urgent surgery. While open surgery is still the preferred way to approach acute diverticulitis and its complications, laparoscopy, initially reserved to uncomplicated diverticulitis [4], is gaining acceptance in the treatment of diverticular fistulas for the possible reduction of overall morbidity and better postoperative outcome and faster recovery when compared to open surgery [5] and [6]. Aim of the present review is to analyze the outcomes deriving from laparoscopic elective surgical treatment of diverticular fistulas of the colon.

2. Materials and methods

The methodology of the Preferred Reporting Items for Systematic reviews and Meta-Analysis (PRISMA) statement [7] was used.

2.1. Inclusion criteria

Published randomized and non-randomized studies in which at least 10 adult patients (age ≥ 18 years) underwent laparoscopic surgical treatment for colonic fistula secondary to sigmoid diverticular disease were included in this review.

2.2. Exclusion criteria

Studies were excluded from the analysis if the outcomes of interest were not reported or it was not possible to evaluate them based on the published results.

2.3. Interventions

Operations involving fully laparoscopic, laparoscopic assisted surgery, or hand-assisted laparoscopy surgery were included.

2.4. Systematic literature search

A systematic literature research for studies published in English between January 1991 and March 2015 was accomplished consulting EMBASE and PubMed databases.

The literature search in PubMed was performed using the string “colocutaneous AND fistula OR (coloenteric AND fistula) OR (colovaginal AND fistula) OR (colovesical AND fistula) OR (diverticular AND fistula)”.

Two authors independently performed online bibliography searches in order to identify titles and abstracts of interest. Full texts of relevant articles were further assessed for inclusion in the study. In the case of multiple trials enrolling the same patients, either the most recent study or the one with the best methodological quality was included in the analysis.

2.5. Outcomes

Primary outcome

- Rate of fistula recurrence

Secondary outcomes

- Rate of reoperation for post-operative complications
- Rate of Hartmann's procedure or proximal diversion
- Rate of conversion to laparotomy

2.6. Data extraction

We developed a data extraction sheet based on the Cochrane Consumers and Communication Review Group's data extraction template [8]. Two authors (RC and CR) independently retrieved data of the included studies. A third author (GC) checked the extracted data. Disagreements were solved through discussion and, if necessary, by involving an independent fourth author (AA).

2.7. Statistical analysis

Two authors (CR and RC) performed the statistical analysis in line with recommendations from the PRISMA statement and the Cochrane Handbook for Systematic Reviews. Reported data were not homogeneous. For this reason we did not conduct a meta-analysis across studies. Instead, descriptive characteristics were reported for each article.

2.8. Assessment of methodological quality of the included studies

The included comparative studies were assessed by CR and RC for their methodological quality using the revised and modified grading system of the Scottish Intercollegiate Guidelines Network [9]. The included case series were assessed using the checklist for the quality of case series of the National Institute for Health and Clinical Excellence (NICE) [10].

3. Results

3.1. Search outcomes

The combined search strategy identified 1186 citations, of which 29 were judged to be potentially eligible based on title or abstract, or both, and the full texts were obtained. After a full text review, 18 studies were excluded [11], [12], [13], [14], [15], [16], [17], [18], [19], [20], [21], [22], [23], [24], [25], [26], [27] and [28] while 11 trials were judged to be eligible and were included in the review (Table 1) [29], [30], [31], [32], [33], [34], [35], [36], [37], [38] and [39]. The PRISMA flow diagram for systematic review is presented in Fig. 1.

Table 1.

Characteristics of the included studies.

Author, year of publication – City, nation – type of trial	Type of diverticular pathology: type of diverticular fistula	Type of laparoscopic treatment follow-up [months, mean (range)]	Treatment of sigmoid colon	Treatment of fistula	Quality of the included studies
Spector 2014 [29]	24 colovesical fistula	Hand assisted laparoscopic NA	19 sigmoidectomy 2 anterior resection	NA	Fair (11/20) ^a
Abbas 2013 [30] Los Angeles (USA) Retrospective cohort study	21 patients chronic diverticulitis: 15 colovesical, 4 colovaginal, 2 colocutaneous	Laparoscopic assisted 15 (1–72)	12 sigmoidectomy 9 anterior resection	NA	Fair (12/20) ^a
Marney 2013 [31] Townsville (Australia) Retrospective cohort study	15 patients with colovesical fistulas	Laparoscopic assisted 12.4 (1–37)	15 sigmoidectomy and primary anastomosis	Primary suture placement in significant bladder defect or left to heal without primary closure in minor defect	Fair (6/8) ^b
Royds 2012 [32] Dublin (Ireland) Retrospective cohort study	102 patients with complicated diverticular disease: 21 colovesical, 2 colovaginal, 1 colouterine	Laparoscopic assisted NA	NA	NA	Good (7/8) ^b
Martel 2010 [33] Ottawa (Canada) Retrospective cohort study	183 patients with diverticular disease: 9 colovesical, 5 colovaginal, 2 colocutaneous, 2 otherwise specified	NA NA	NA	NA	Fair (11/20) ^a
Engledow 2007 [34] Colchester (UK) Retrospective cohort study	31 patients with sigmoid diverticular fistulae: 22 colovesical, and 9 colovaginal	Fully laparoscopic 3 months, 6 months, 4 years	31 sigmoidectomy and primary anastomosis A omental pathc was placed into the pelvis between colon	Fistulectomy + treatment of bladder: 2 primary suture placement 29 left to heal without primary closure	Fair (6/8) ^b

Author, year of publication – City, nation – type of trial	Type of diverticular pathology: type of diverticular fistula	Type of laparoscopic treatment follow-up [months, mean (range)]	Treatment of sigmoid colon	Treatment of fistula	Quality of the included studies
Nguyen 2006 [35] New York (USA) Retrospective cohort study	14 patients with diverticular disease complicated by fistulae: 8 colovesical, 5 enterocolic, 1 colovaginal, 1 colosalpingal, 1 colocutaneous	Laparoscopic assisted NA	14 sigmoidectomy and primary anastomosis	and bladder or vagina Fistulectomy + treatment of bladder: 3 primary suture placement 5 left to heal without primary closure Enteroenteric fistula: segmental resection of bowel in 3 and primary bowel repair in 2 Vaginal cuff was left alone in 2 Falloppian tubes were left intact in the patient with colosalpingeal fistula	Fair (5/8) ^b
Bartus 2005 [36] Dallas (USA) Prospective cohort study	36 patients with diverticular disease: 34 colovesical, 2 colovaginal	Hand-assisted laparoscopic NA	34 sigmoidectomy and primary anastomosis	NA	Fair (11/20) ^a
Laurent 2005 [37] Liege (Belgium) Retrospective cohort study	16 patients with diverticular disease complicated by fistulae: 11 colovesical, 4 colovaginal, 1 colocutaneous	Laparoscopic assisted NA	11 sigmoidectomy and primary anastomosis	Fistulectomy + treatment of bladder: 11 primary suture placement	Fair (6/8) ^b
Pugliese 2004 [38] Milan (Italy) Prospective cohort study	103 patients treated for Hinchey I–III sigmoid diverticulitis: 17 colovesical, 8 enterocolic, 6 colovaginal	Laparoscopic assisted NA	17 sigmoidectomy and primary anastomosis	Fistulectomy + treatment of bladder: 1 primary suture placement 16 left to heal without primary closure	Fair (6/8) ^b
Menenakos 2003 [39]	18 patients with	Fully laparoscopic	18 sigmoidectomy	Fistulectomy + treatment of bladder: 6 stapling	Fair (5/8) ^b

Author, year of publication – City, nation – type of trial	Type of diverticular pathology: type of diverticular fistula	Type of laparoscopic treatment follow-up [months, mean (range)]	Treatment of sigmoid colon	Treatment of fistula	Quality of the included studies
Athens (Greece) Prospective cohort study	complicated sigmoid diverticulitis: 15 colovesical and 3 colovaginal	61.7 (8–99)	and primary anastomosis	device placement 2 primary suture placement 2 resection of the vesical wall and two-layer closure of the defect	

NA: not available.

a

Evaluation of methodological qualities of comparative included studies assessed using the revised and modified grading system of the Scottish Intercollegiate Guidelines Network [9]. (see supplementary online material *1).

b

Evaluation of methodological qualities of the case series included assessed using the checklist for the quality of case series of the National Institute for Health and Clinical Excellence (NICE) [10]. (see supplementary online material *2).

Table options

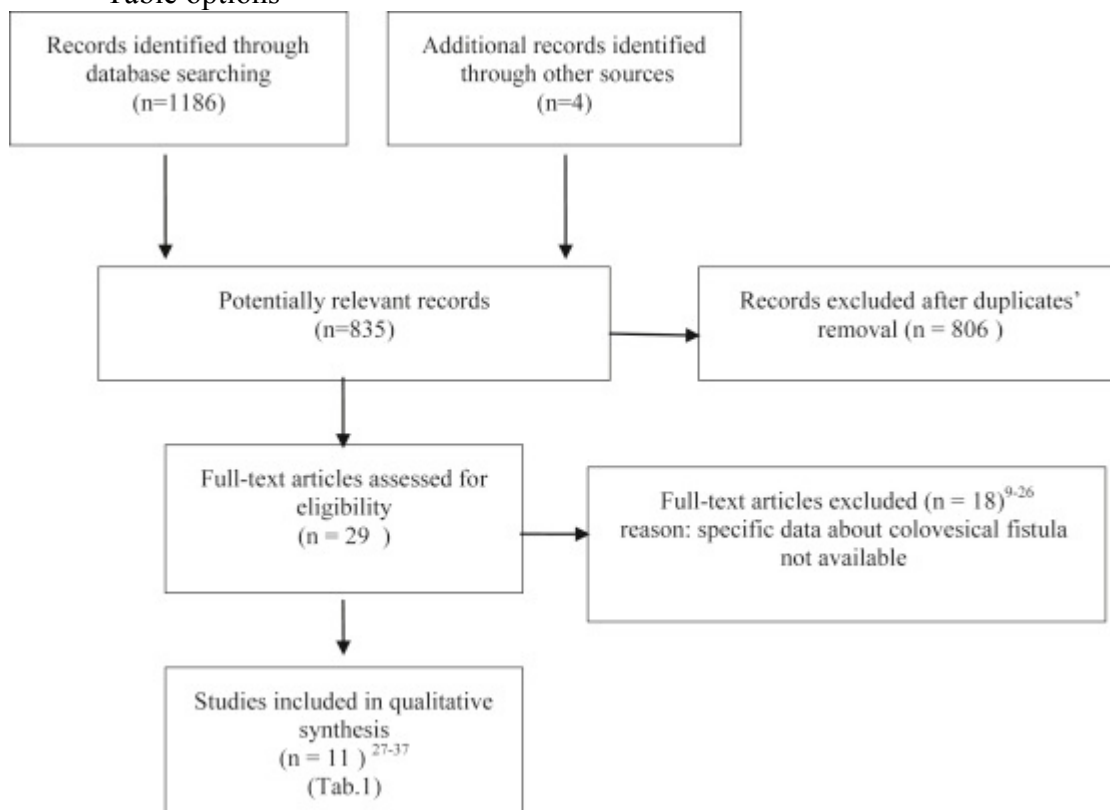


Fig. 1.

PRISMA flow chart of literature search.

Figure options

3.2. Characteristics of the included studies

Outcomes of the interventions concerned a total of 250 patients with 254 fistulas (Table 1): 188 colovesical fistulas, 45 colovaginal fistulas, 13 coloenteric, 6 colocutaneous, 1 colosalpingal and 1 colouterine. The majority of surgical interventions were performed with laparoscopic assisted technique [31], [32], [35], [37] and [38], a few with fully laparoscopic technique [30], [34] and [39] or hand-assisted technique [29] and [36].

3.3. Risk of bias of the included studies

The number of patients analyzed is exiguous. Furthermore, these data came from ten studies in which the number of included patients is underpowered for the analyzed outcomes. A big heterogeneity is present in terms of surgical skill, laparoscopic technique, severity of the diverticular disease and type of fistulas. Follow up is missing in most of the included studies and if reported is often short.

3.4. Quality assessment of included studies

The methodological quality for each of the included clinical controlled trials (CCT) was “fair”; the mean score was 11.3 points out of 20 (Table 1). The methodological quality of case series, was “fair”, with a mean score of 5.9 points out of 8.0 (Table 1). Bartus et al. performed an intention to treat analysis [36]. Data were prospectively collected in two comparative studies [32] and [35] and in three case series [32], [34] and [37].

3.5. Primary outcomes

Rate of fistula recurrence is reported in 6 studies [29], [30], [34], [35], [37] and [39] for 121 patients with only one case of colovesical fistula recurrence was reported [39]. The rate of fistula recurrence was 0.8% (1/121) (Table 2). Only 4 studies [30], [31], [34] and [39] reported the duration of follow-up, which ranged between 1 [30] and [31] and 99 months [39].

Table 2.

Primary and secondary outcomes.

Author, year of publication	Rate of fistula recurrence	Rate of reoperation for post-operative complications	Rate of Hartmann's procedure or proximal diversion	Rate of laparotomic conversion
Spector 2014 [29]	8.3% (2/24)	0	0	0
Abbas 2013 [30]	0	10% (2/21)	5% (1/21)	0
Marney 2013 [31]	NA	0	0	33.3% (5/15)
Royds 2012 [32]	NA	NA	35% ^a (14/40)	10.8 ^a (4/40)
Martell 2010 [33]	NA	NA	21% ^b (8/39)	11.1% (2/18)
Engledow 2007 [34]	0	0	3.2% (1/31)	29% (9/31)
Nguyen 2006 [35]	0	7.1% (1/14)	0	35.7% (5/14)
Bartus 2005 [36]	NA	0	NA	25% (9/36)
Laurent 2005 [37]	0	0	0	18.7% (3/16)
Pugliese 2004 [38]	NA	NA	NA	NA
Menenakos 2003 [39]	5.5% (1/18)	NA	NA	5.5% (1/18) ^c

NA: not available.

a

Rate in all patients with complicated diverticulitis (operated on in elective setting).

b

Rate in all patients with complicated diverticulitis.

c

Conversion to laparoscopic assisted surgery.

Table options

3.6. Secondary outcomes

Rate of reoperation for post-operative complications is reported in 7 studies [29], [30], [31], [34], [35], [36] and [37] including a total of 144 patients. Only Nguyen [35] and Abbas [30] reported three reinterventions for complications in the first 30 days (2%) (Table 2).

Rate of Hartmann's procedure or proximal diversion is reported in 8 studies: 2 studies presented cumulative data over all the patients presenting with complicated diverticulitis

[32] and [33] and 6 studies presented analytical data for fistulas [29], [30], [31], [34], [35] and [37]. Of the 140 patients with fistulas only Engledow [34] and Abbas [30] reported two proximal diversions (1.4%). Otherwise in the 40 patients with complicated diverticulitis the stoma rate was between 21% [33] and 35% [32] (Table 2).

Rate of laparotomic conversion is reported in 9 studies. The conversion rate to open surgery was relatively high 19.7% (34/172), ranging between 0 [29] and 35.7% [35]. It was not possible to extract results from Pugliese [32] and Royds [38]. Menenakos [39] converted one patient to assisted laparoscopy (Table 2).

4. Discussion

The present review aims to verify if laparoscopy is to be considered a suitable choice of treatment for diverticulitis complicated with fistulas. These were classified as colovesical (74%), colovaginal (18%), coloenteric (5%), colocutaneous (2%), colosalpingal (0.5%) and colouterine fistulas (0.5%). Compared to series operated by open surgery, we observed a higher incidence of colovesical fistulas (74% vs. 44%) and a much lower incidence of colocutaneous fistulas (2% vs. 28%) perhaps because before the advent of laparoscopic surgery diagnostics and medical therapy were different from the actual ones [40]. Because of its inflammatory nature, diverticulitis was initially thought to be a contraindication for a laparoscopic approach [41], [42], [43] and [44], but with the improvement of the technology and mainly the increasing experience, minimally invasive surgery for diverticulitis became a common surgical strategy [17], leading to many advantages including less postoperative pain, shorter hospital stay, faster recovery to normal activity and better cosmetic results. Recent reports describing the laparoscopic approach for colovesical fistulas treatment clearly show that resection and primary anastomosis is possible [34], [45], [46], [47], [48] and [49]. Indeed the outcome of laparoscopic surgery is similar in patients with chronic diverticulitis with colonic fistula compared with patients without fistula [30]. The treatment of diverticular fistulas, in particular of colovesical fistulas, is feasible in different ways: bowel resection and primary colic anastomosis applying omental plasty and covering ileostomy [50], anterior resection, partial colectomy and Hartmann procedure [51], laparoscopic sigmoid resection and primary anastomoses or temporary colostomy with or without resection of the bladder wall [6]. The present analysis shows that in selected cases, laparoscopic treatment of diverticulitis complicated by fistula, offers similar rates of fistula recurrence (0.8%) compared to laparotomy. It would be of extreme interest to

compare outcomes to the different characteristics and surgical techniques, but unfortunately data are too few to allow any statistical interpretation. In the majority of cases, when the fistula was small and Hinchey classification up to grade 2b, the non-colic side of the fistula was not treated at all, but abandoned [32]. Larger colovesical fistulas were usually closed with sutures as by Laurent [37] and Marney [31] or in few cases with suturing devices [39]. A urinary catheter was usually left in situ for 5–7 days following surgery for colovesical fistula only, while it was removed on the second or third post-operative day for colovaginal fistulae [34]. In truth, these data refer extensively to a single study [36] contributing for about two thirds of the analyzed cases. Also the analysis of reoperation for post-operative complications at 30 days (2%) and need for Hartmann's procedure or proximal diversion (1.4%) did not show significant difference between laparoscopy and open technique, although events useful for the analysis are not reported. It has to be noted that the rate of conversion to laparotomy, which is often reported, is relatively high, as it is reported in about one fifth of the cases (19.7%). In a series of 36 patients with fistulas complicating diverticular disease, Bartus et al. reported a 25% conversion rate [36]. Fourteen patients with enteric fistulas complicating diverticular disease underwent elective laparoscopically assisted sigmoid resections: 5 patients (36%) were converted to open, due to severe adhesions or a large inflammatory phlegmon impairing safe and effective dissection [35]. Laparoscopic and robotic techniques have similar outcomes in the elective management of complicated diverticulitis with colovesical fistulas, also if robotic surgery may decrease conversion rate compared with the laparoscopic approach [52]. The subgroup of hand assisted laparoscopic colectomy presented the best results (Table 2), but the number of the patients treated with this approach is very low [29] and [36]. Recently, a laparoscopic conservative treatment of colovesical fistula performing a fistulectomy without colic resection was reported; the authors describe this technique as safe and feasible, with low risk of recurrence if the fistula is not due to diverticulitis or when the diverticular disease does not extensively involve the bowel wall [11]. Nevertheless, this study is a report of only two cases and a prospective study with a larger sample size is necessary to evaluate the outcomes of this original technique. Several limitations of the present analysis should be exposed. First, the rate of fistula recurrence, our primary outcome, is reported in a limited number of studies, probably due to the non-frequent incidence, and short follow-up. Despite the secondary outcomes are more represented in literature, the small number of events reported impaired the statistical significance of difference between groups. On the other hand, results of case

series of less than 10 patients, are in contrast with these conclusions, (i.e. no case of conversion to laparotomy is reported). But this is most probably linked to the consideration that small series with unfavorable results are unlikely to be published and of scarce interest for the authors themselves. Therefore, we believe that excluding studies enrolling under 10 patients is a correct approach to the analysis. In conclusion, large prospective studies, possibly comparative trials should focus on the topic of laparoscopic treatment, in order to establish if the usual advantages of laparoscopy compared to open surgery, in terms of reduced morbidity and hospital stay, are confirmed even in this environment. Nevertheless, with increasing experience, it is likely to forecast that minimally invasive surgery should become the standard approach when there is firm evidence supporting it. An adequate view of the surgical field is one of the major problems in the repair of fistulas, especially those between the rectum and lower urinary tract, so a better view could be a real effective arrow in the hand of supporters of the laparoscopic approach [53].

5. Conclusions

The lack of RCTs, the small sample size, and the heterogeneity of published papers do not allow us to draw statistically significant conclusions on the laparoscopic surgical management of sigmoid fistulas due to complicated diverticulitis despite it is well known that this approach is safe if performed by experienced surgeons.

manuscript. CR analyzed the data drafted and revised the paper. EM, VA critically revised the manuscript.

References

- [1]
- G. Cochetti, E. Cottini, R. Cirocchi, *et al.*
- Laparoscopic conservative surgery of colovesical fistula: is it the right way?
- Videosurgery Miniinv, 8 (2) (2013), pp. 162–165
- [2]
- J. Desiderio, S. Trastulli, C. Listorti, *et al.*
- Surgical approach of complicated diverticulitis with colovesical fistula:
technical note in a particular condition
- Cent. Eur. J. Med., 7 (5) (2012) 578-5

- [3]
- B.P. Colcock
- Surgical management of complicated diverticulitis
- Surg. Clin. North. Am., 48 (3) (1968), pp. 543–551
- [4]
- A. Lauro, A. Alonso Poza, R. Cirocchi, *et al.*
- Laparoscopic surgery for colon diverticulitis
- Minerva Chir., 57 (1) (2002), pp. 1–5
- [5]
- R. Cirocchi, E. Farinella, S. Trastulli, F. Sciannameo, R.A. Audisio
- Elective sigmoid colectomy for diverticular disease. Laparoscopic vs open surgery: a systematic review
- Colorectal Dis., 14 (6) (2012), pp. 671–683
- [6]
- R. Cirocchi, G. Cochetti, J. Randolph, *et al.*
- Laparoscopic treatment of colovesical fistulas due to complicated colonic diverticular disease: a systematic review
- Tech. Coloproctol., 18 (10) (2014), pp. 873–885
- [7]
- D. Moher, A. Liberati, J. Tetzlaff, D.G. Altman
- Preferred reporting items for systematic reviews and meta-analyses: the PRISMA statement
- PLoS Med., 6 (7) (2009), p. e1000097
- [8]
- Cochrane Consumers and Communication Review Group
- Data Extraction Template for Cochrane Reviews. Version 1.5.0
- (2013) updated 8 Feb 2013. Available at: <http://cccr.org/cochrane.org/author-resources> (accessed 05.01.14)
- [9]
- Scottish Intercollegiate Guidelines Network (SIGN) Guidelines. Available at: <http://www.sign.ac.uk/guidelines/fulltext/50/checklist3>. (accessed 20.03.09)
- [10]
- National Institute for Health and Clinical Excellence. Available at: http://www.nice.org.uk/nicemedia/pdf/Appendix_04_qualityofcase_series_form_preop.pdf. NICE Clinical Guidelines, Appendix 4 Quality of Case Series Form. last updated: 30 March 2010. (accessed 18.06.12).
- [11]
- G. Cochetti, E. Lepri, E. Cottini, *et al.*
- Laparoscopic conservative treatment of colo-vesical fistulas following trauma and diverticulitis: report of two different cases

- Cent. Eur. J. Med., 8 (6) (2013), pp. 790–794
- [12]
- T. Marcucci, S. Giannessi, F. Giudici, S. Riccadonna, A. Gori, F. Tonelli
- Management of colovesical and colovaginal diverticular fistulas our experience and literature reviewed
- Ann. Ital. Chir., 85 (2013)
- [13]
- G.P. Abraham, K. Das, K. Ramaswami, *et al.*
- Minimally invasive reconstruction of colovesical fistula
- J. Laparoendosc. Adv. Surg. Tech. Part B Videoscopy, 22 (2012)
- [14]
- O.A. Castillo, A. Rodriguez-Carlin, G. Campana, A. Perez
- Fístula colovesical secundaria a enfermedad diverticular: cirugía laparoscópica electiva
- Rev Chil. Cirugía, 64 (3) (2012), pp. 278–281
- [15]
- T. Hirata, H. Yokomizo, Y. Kimura, *et al.*
- Clinical study of 5 cases of colon diverticulitis with colovesical fistula treated laparoscopically
- Jpn. J. Gastroenterol. Surg., 44 (4) (2011), pp. 468–473
- 2.
- [16]
- J.D. Andrade-Platas, J.G. Morales-Montor, L.E. González-Monroy, *et al.*
- Cierre de fístula colovesical con resección de sigmoides por laparoscopia
- Re.v Mex. Urol., 69 (2) (2009), pp. 79–82
- 3.
- [17]
- C.T. Lu, Y.H. Ho
- Elective laparoscopic surgical management of recurrent and complicated sigmoid diverticulitis
- Tech. Coloproctol., 12 (3) (2008), pp. 201–206
- [18]
- T. Takaba, J. Moriyama, T. Yokoyama, S. Matoba, T. Sawada
- Five cases of diverticulitis with colovesical fistula treated by laparoscopic surgery
- J. Jpn. Surg. Assoc., 69 (3) (2008), pp. 614–619
- [19]
- A. Nishimura, Y. Kawachi, S. Makino, K. Nikkuni, T. Shimizu

- A case of sigmoid colon diverticulitis with a vesicosigmoidal fistula treated by laparoscopic surgery
- J. Jpn. Surg. Assoc., 68 (10) (2008), pp. 2553–2557
- [20]
- C. Zapletal, G. Woeste, W.O. Bechstein, C. Wullstein
- Laparoscopic sigmoid resections for diverticulitis complicated by abscesses or fistulas
- Int. J. Colorectal. Dis., 22 (12) (2007), pp. 1515–1521
- [21]
- S.W. Lee, J. Yoo, N. Dujovny, T. Sonoda, J.W. Milsom
- Laparoscopic vs. hand-assisted laparoscopic sigmoidectomy for diverticulitis
- Dis. Colon Rectum, 249 (4) (2006), pp. 464–469
- [22]
- A. Tsivian, S. Kyzer, A. Shtricker, S. Benjamin, A. Ami Sidi
- Laparoscopic treatment of colovesical fistulas: technique and review of the literature
- Int. J. Urol., 13 (2006), pp. 664–667
- [23]
- N. Pokala, C.P. Delaney, K.M. Brady, A.J. Senagore
- Elective laparoscopic surgery for benign internal enteric fistulas: a review of 43 cases
- Surg. Endosc., 19 (2) (2005), pp. 222–225
- [24]
- K. Moorthy, T. Shaul, R.J.E. Foley
- The laparoscopic management of benign bowel fistulas
- JSLS, 8 (4) (2004), pp. 356–358
- [25]
- J.P. Regan, B.A. Salky
- Laparoscopic treatment of enteric fistulas
- Surg. Endosc., 18 (2) (2004), pp. 252–254
- [26]
- Q.A. Eijsbouts, M.A. Cuesta, L.M. de Brauw, C. Sietses
- Elective laparoscopic-assisted sigmoid resection for diverticular disease
- Surg. Endosc., 11 (7) (1997), pp. 750–753

- [27]
- J.S. Joo, F. Agachan, S.D. Wexner
- Laparoscopic surgery for lower gastrointestinal fistulas
- Surg. Endosc., 11 (1997), pp. 116–118
- [28]
- P.J. Hewett, R. Stitz
- The treatment of internal fistulae that complicate diverticular disease of the sigmoid colon by laparoscopically assisted colectomy
- Surg. Endosc., 9 (4) (1995), pp. 411–413
- [29]
- R. Spector, V. Bard, O. Zmora, S. Avital, N. Wasserberg
- Hand-assisted laparoscopic colectomy for colovesical fistula associated with diverticular disease
- Surg. Laparosc. Endosc. Percutaneous Tech., 24 (3) (2014), pp. 251–253
- [30]
- M.A. Abbass, A.T. Tsay, M.A. Abbas
- Laparoscopic resection of chronic sigmoid diverticulitis with fistula
- JSLS, 17 (4) (2013), pp. 636–640
- [31]
- L.A. Marney, Y.H. Ho
- Laparoscopic management of diverticular colovesical fistula: experience in 15 cases and review of the literature
- Int. Surg., 98 (2) (2013), pp. 101–109
- [32]
- J. Royds, J.M. O’Riordan, E. Eguare, D. O’Riordan, P.C. Neary
- Laparoscopic surgery for complicated diverticular disease: a single-centre experience
- Colorectal Dis., 14 (10) (2012), pp. 1248–1254
- [33]
- G. Martel, A. Bouchard, C.M. Soto, É.C. Poulin, J. Mamazza, R.P. Boushey
- Laparoscopic colectomy for complex diverticular disease: a justifiable choice?
- Surg. Endosc., 24 (9) (2010), pp. 2273–2280
- [34]
- A.H. Engledow, F. Pakzad, N.J. Ward, T. Arulampalam, R.W. Motson
- Laparoscopic resection of diverticular fistulae: a 10-year experience

- Colorectal Dis., 9 (7) (2007), pp. 632–634
- [35]
- S.Q. Nguyen, C.M. Divino, A. Vine, M. Reiner, L.B. Katz, B. Salky
- Laparoscopic surgery for diverticular disease complicated by fistulae
- JSLS, 10 (2) (2006), pp. 166–168
- View Record in Scopus
- [36]
- C.M. Bartus, T. Lipof, C.M. Sarwar, *et al.*
- Colovesical fistula: not a contraindication to elective laparoscopic colectomy
- Dis. Colon Rectum, 48 (2) (2005), pp. 233–236
- [37]
- S.R. Laurent, B. Detroz, O. Detry, C. Degauque, P. Honoré, M. Meurisse
- Laparoscopic sigmoidectomy for fistulized diverticulitis
- Dis. Colon Rectum, 48 (1) (2005), pp. 148–152
- [38]
- R. Pugliese, S. Di Lernia, F. Sansonna, *et al.*
- Laparoscopic treatment of sigmoid diverticulitis: a retrospective review of 103 cases
- Surg. Endosc., 18 (9) (2004), pp. 1344–1348
- [39]
- E. Menenakos, D. Hahnloser, K. Nassiopoulos, C. Chanson, V. Sinclair, P. Petropoulos
- Laparoscopic surgery for fistulas that complicate diverticular disease
- Langenbecks Arch. Surg., 388 (3) (2003), pp. 189–193
- [40]
- G.V. Rodkey, C.E. Welch
- Diverticulitis and diverticulosis of the colon
- R. Turell (Ed.), Disease and Rectum, WB Saunders Company, Philadelphia (1969), pp. 697–722
- [41]
- H.D. Vargas, R.T. Ramirez, G.C. Hoffman, *et al.*
- Defining the role of laparoscopic assisted sigmoid colectomy for diverticulitis
- Dis. Colon Rectum, 43 (2000), pp. 1726–1731
- [42]
- A.P. Fine
- Laparoscopic surgery for inflammatory complications of acute sigmoid diverticulitis
- JSLS, 5 (2001), pp. 233–235

- [43]
- E.C. Poulin, C.M. Schlachta, J. Mamazza, P.A. Seshadri
- Should enteric fistulas from Crohn's disease or diverticulitis be treated laparoscopically or by open surgery? A matched cohort study
- Dis. Colon Rectum, 43 (2000), pp. 621–626
- [44]
- F. Köckerling, C. Schneider, M.A. Reymond, *et al.*
- Laparoscopic colorectal surgery study group, laparoscopic resection of sigmoid diverticulitis. Results of a multicenter study
- Surg. Endosc., 13 (1999), pp. 567–571
- [45]
- G. Anania, L. Vedana, M. Santini, L. Scagliarini, S. Giaccari, G. Resta, G. Cavallesco
- Complications of diverticular disease: surgical laparoscopic treatment
- G. Chir., 35 (5–6) (2014), pp. 126–128
- [46]
- T.H. Tvedskov, H. Ovesen, M. Seiersen
- Laparoscopic operation for colovesical fistula
- Ugeskr. Laeger, 170 (2008), p. 159
- [47]
- A.Y. Afifi, T.J. Fusia, K. Feucht, M.W. Paluzzi
- Laparoscopic treatment of appendicovesical fistula: a case report
- Surg. Laparosc. Endosc., 4 (1994), pp. 320–324
- [48]
- L.V. Titu, N. Zafar, S.M. Phillips, G.L. Greenslade, A.R. Dixon
- Emergency laparoscopic surgery for complicated diverticular disease
- Colorectal Dis., 11 (2009), pp. 401–404
- [49]
- Q.A. Eijsbouts, J. de Haan, F. Berends, C. Sietses, M.A. Cuesta
- Laparoscopic elective treatment of diverticular disease. A comparison between laparoscopic-assisted and resection-facilitated techniques
- Surg. Endosc., 14 (2000), pp. 726–730
- [50]
- H. Myaso, K. Iwakawa, Y. Hamada, *et al.*
- Ten cases of colovesical fistula due to sigmoid diverticulitis
- Hiroshima J. Med. Sci., 64 (1–2) (2015), pp. 9–13
- [51]
- Q.H. Kiani, M.L. George, E.A. Carapeti, A.M. Schizas, A.B. Williams
- Colovesical fistula: should it be considered a single disease?

- Ann. Coloproctol., 31 (2) (2015), pp. 57–62
- [52]
- V. Maciel, H.J. Lujan, G. Plasencia, *et al.*
- Diverticular disease complicated with colovesical fistula: laparoscopic versus Robotic Management
- Int. Surg., 99 (3) (2014), pp. 203–210
- [53]
- G. Scozzari, A. Arezzo, M. Morino
- Enterovesical fistulas: diagnosis and management
- Tech. Coloproctol., 14 (4) (2010), pp. 293–30