

Occurrence of *Macrorhabdus ornithogaster* in canary breeding in Piedmont. A preliminary study

A. Dogliero^{1*}, G. Rossi², F. De Angelis¹, P. Nebbia¹, P. Robino¹

¹Department of Veterinary Sciences, University of Turin, Grugliasco, Turin, Italy; ²Department of Veterinary Sciences, University of Camerino, Matelica, Macerata, Italy.

*Corresponding Author: Tel +39 0116709057 Fax +39 011 2369049 e-mail address: andrea.dogliero@gmail.com

Introduction

Macrorhabdus ornithogaster, also known as “megabacterium” or avian gastric yeast (AGY), is a novel anamorphic ascomycetous yeast that belongs in its own new genus, with a worldwide distribution^{1,2,3,4}. Megabacteria has been found in both psittacine and passerine species, both in captivity and in the wild.

It is usually found colonizing the mucosal surface of the isthmus existing between the proventriculus and ventriculus⁵ of a wide diversity of bird species and currently represent a potential threat to bird breeders. Clinical signs include weight loss in spite of a good appetite, regurgitation, diarrhea, depression, maldigestion, ruffled feathers and death^{3,6}.

The main purpose of this study was to assess the presence of this yeast in breeding canaries (*Serinus canaria*) distributed in Piedmont.

Materials and methods

This study was conducted in 9 canary (*Serinus canaria*) breeding centers in three provinces of Piedmont (Torino, Asti and Cuneo) between June 2014 and February 2015. Breeding colonies were composed from 50 to 300 animals: in 8 centers some birds showed symptoms of “going light” syndrome (weight loss: 89%; diarrhea and sudden death: 22% of the cases) while in one breeding the canaries were apparently healthy. Smears were prepared from fecal samples and examined by microscopic test for the presence and identification of *M. ornithogaster*. Level of shedding of AGY was evaluated using a scale from 0 to 6⁷. From dead animals, tissue samples were examined by histopathological analysis.

Results and discussion

All 9 examined breeding centers were positive for *M. ornithogaster* both microscopic and histological analysis. Interestingly, we found an high number of *Atoxoplasma* spp. in feces, with a co-infestation amounted to 66%.

Gross necropsy findings were not specific. Birds were typically thin to emaciated and had little or no body fat. From dead animals, tissue samples were examined by histology, confirming a picture of *Macrorhabdus* infection, with presence of microorganisms located especially in the proventricular isthmus region. The affected areas, showed a deep and heavy yeasts colonization, with mucosal glands filled by yeasts and mucins, and with swollen and sometimes cystic glandular aspect. Histologically, affected birds typically showed marked disruption of the koilin layer with disorganization and degeneration, and there were large numbers of yeasts which had a matchstick or logjam appearance. Lymphoplasmacytic to heterophilic inflammation may be present, and there may be foci of hemorrhage. In the proventriculus, there was mucous cell hyperplasia with a thick layer of mucus covering the mucosal surface.




Fig. 1 Colour’s canaries are the breeders and young are the main and more bred in captivity. When pairs are dissolved, at the end of the breeding season, put together in large aviaries; this aggravates the contamination degree among infect birds with others.




Fig. 2 AGY positive canary showing ruffled feathers, depression and chronic weight loss.




Fig. 3

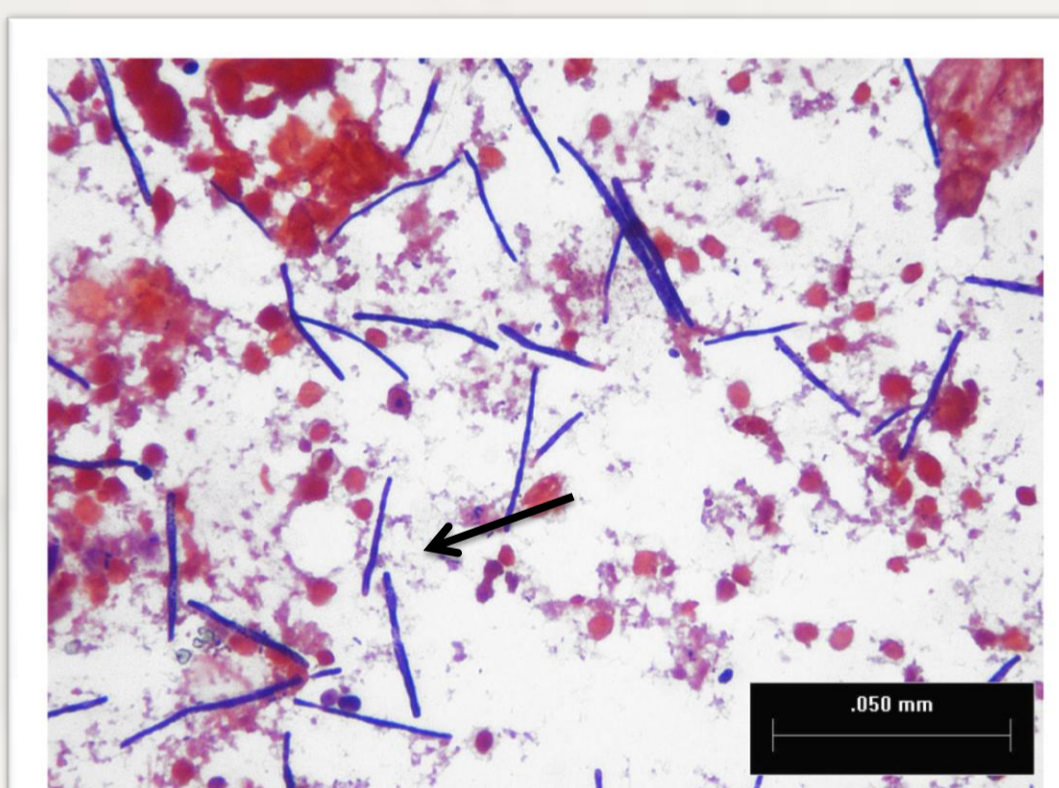


Fig. 4

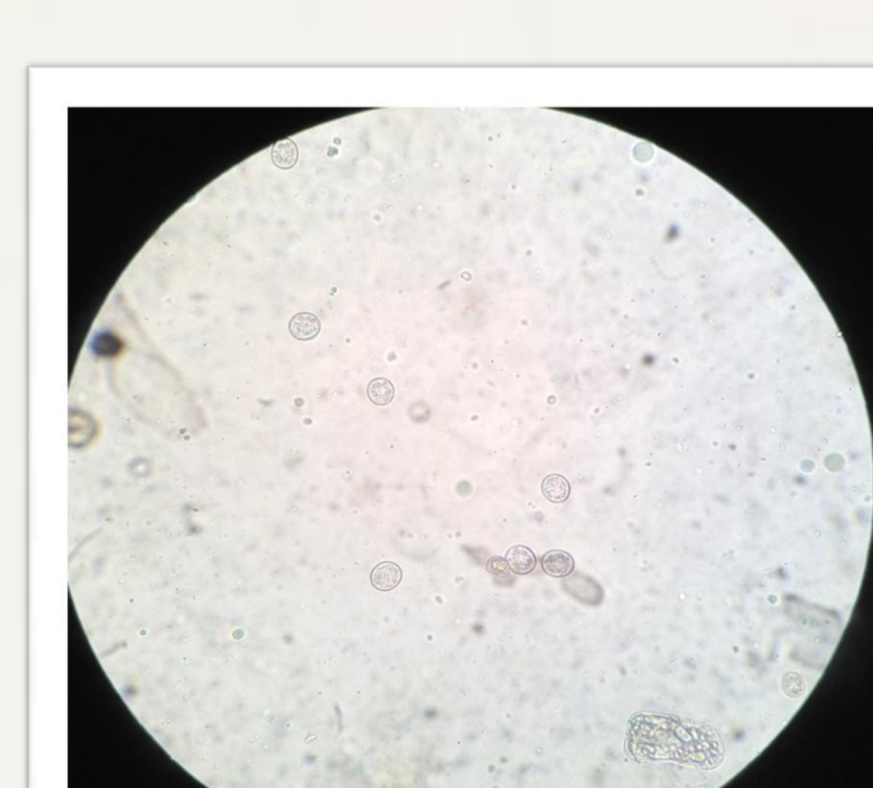


Fig. 5

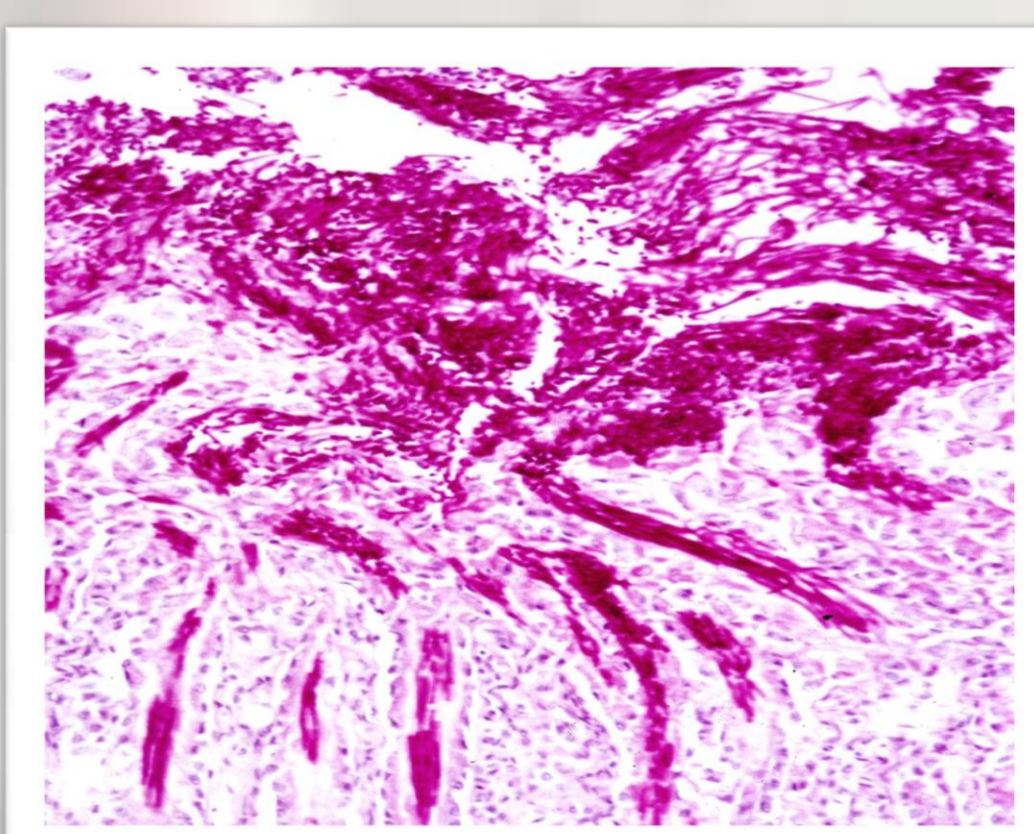


Fig. 6

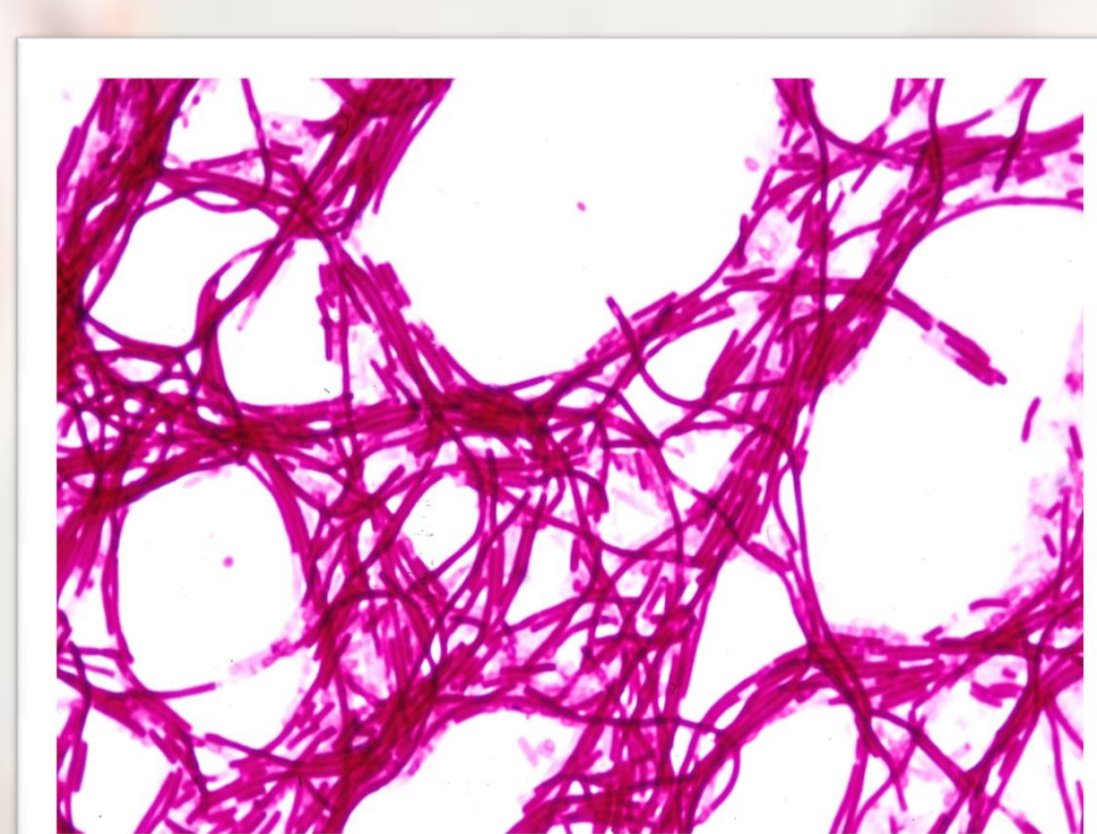


Fig. 7

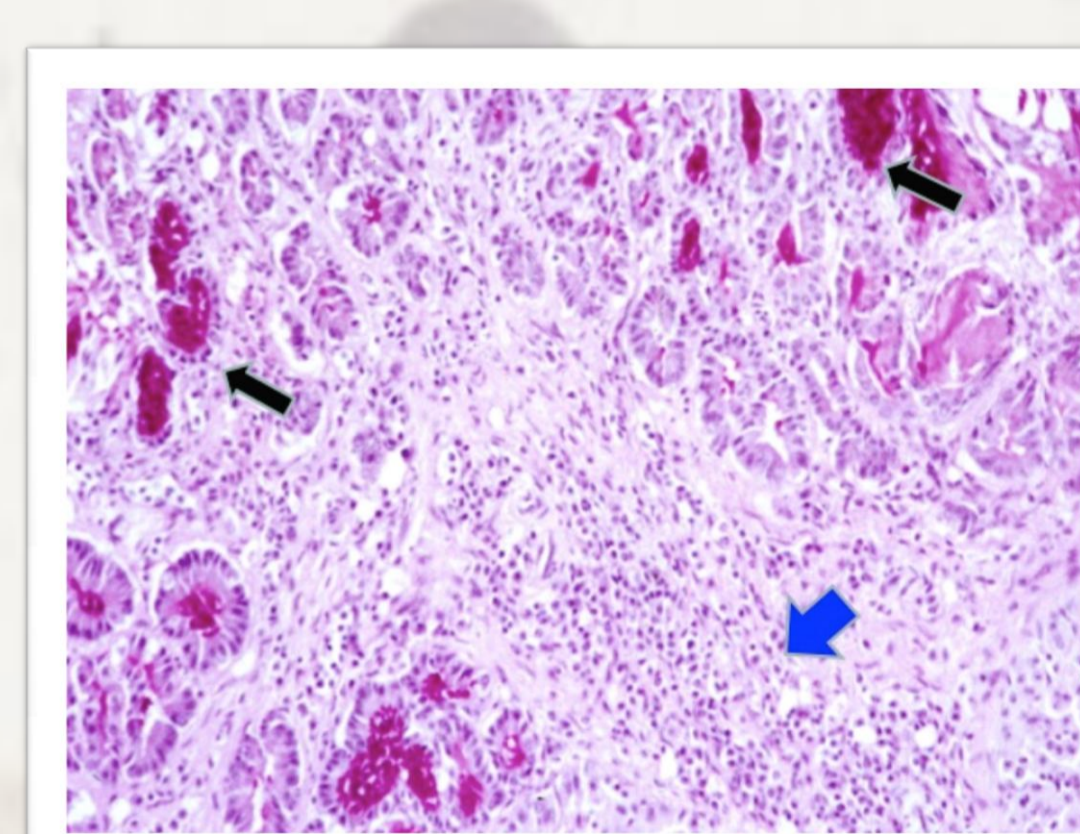


Fig. 8

Fig. 3 Preparation of a smear by impregnated feces swab rubbing.

Fig. 4 Gram-stained image of AGY in smear prepared from canary fecal sample (black arrow).

Fig. 5 High presence of *Atoxoplasma* spp. oocysts in one fecal sample of AGY positive birds.

Fig. 6 Heavily colonized proventriculus by AGY: PAS staining highlights electively yeasts cells with a magenta-pink colour.

Fig. 7 Smear of mucus taken directly from a colonized proventriculus surface by AGY; it is clearly visible the strong yeast concentration of rod form. PAS⁺ staining.

Fig. 8 Heavily colonized proventriculus by AGY: PAS staining. Numerous glands appear dept involved of yeasts PAS⁺. Note the appearance of swollen glands (black arrows) and the strong lymphoplasmacytic inflammation at level of mucosal corium (blue arrow).

Our results confirm that *M. ornithogaster* is widespread in our aviaries and, under some circumstances, can behave as pathogen. The health and economic impact of this microorganism is not yet documented, as well as the therapeutic aspects are yet to study.

We plan to continue our work focusing particularly on the pharmacological treatment, using methods considered historically effective as amphotericin B or Nystatin, but expensive and particularly toxic, and alternative drugs or probiotics that increase the microbial flora and defenses of the immune system.

References

- Hargreaves RC. A fungus commonly found in the proventriculus of small pet birds. In: 30th Western Poultry Disease and 15th Poultry Health Symposium. Davis, CA: University of California at Davis. 1981;75-76.
- Tsai SS, Park JH, Hirai K and Itakura C. Catarrhal proventriculitis associated with a filamentous organism in pet birds. Japanese Journal of Veterinary Research 1992;40:143-148.
- Filippich LJ and Parker MG. Megabacteria in birds in Australia. Australian Veterinary Practitioner. 1993;23:72-76.
- Pennycott TW, Ross HM, McLaren IM, Park A, Hopkins GF and Foster G. Causes of death of wild birds of the family Fringillidae in Britain. Veterinary Record. 1998;143:155-158.
- Tomaszewski EK, Logan KE, Kurtzman CP, Snowden KF and Phalen DN. Phylogenetic analysis indicates the “megabacterium” of birds is a novel anamorphic ascomycetous yeast, *Macrorhabdus ornithogaster*, gen. nov.sp. nov. International Journal of Systematic and Evolutionary Microbiology. 2003;3:1201-1205.
- Baker JR. Clinical and pathological aspects of “going light” in exhibition budgerigars (*Melopsittacus undulatus*). Veterinary Record. 1985;116:406-408.
- Lanzarot P, Blanco JL, Alvarez-Perez S, Abad C, Cutuli MT, Garcia ME. Prolonged fecal shedding of ‘ megabacteria ’ (*Macrorhabdus ornithogaster*) by clinically healthy canaries (*Serinus canaria*). Medical Mycology. 2013; 51: 888–891.