

Bosentan and Fosamprenavir: an effective and safe combination in an HIV-infected patient with pulmonary arterial hypertension

A. Di Biagio¹, L. De Hoffer¹, R. Prinapori¹, M. Cheli², S. Bonora³,
L. Taramasso¹, M. Balbi², A. D'Avolio³, C. Viscoli¹

¹Infectious Diseases, Department of Internal Medicine, University of Genoa, IRCCS San Martino Hospital, IST, Genoa, Italy

²Cardiology Unit, Department of Internal Medicine, University of Genoa, IRCCS San Martino Hospital, IST, Genoa, Italy

³Infectious Diseases, Department of Medical Sciences, University of Turin, Amedeo di Savoia Hospital, Turin, Italy

ABSTRACT: Pulmonary arterial hypertension (PAH) is an increasingly recognized complication of HIV disease associated with significant morbidity and mortality. The prevalence of PAH is estimated to be 0.5% in HIV-infected patients compared to the 0.02% in non HIV-infected patients. A beneficial effect of anti-retroviral therapy on the course of HIV-related PAH has not been clearly established. Bosentan, a dual endothelin-1 receptor antagonist, may be an effective approach to treatment of PAH in HIV-infected patients. We report a first case of a successful therapy with bosentan in an HIV-infected patient treated with fosamprenavir/ritonavir based-regimen.

— **Key words:** HIV, Pulmonary arterial hypertension, Bosentan, Fosamprenavir, Protease inhibitor.

INTRODUCTION

Pulmonary arterial hypertension (PAH) is a distinct subgroup of pulmonary hypertension that comprises heritable, drug and toxin induced, idiopathic and secondary forms associated with specific diseases such as human immunodeficiency virus (HIV) infection, connective tissue disease, and portal hypertension. PAH is defined by a mean pulmonary artery pressure at rest ≥ 25 mm Hg in presence of a pulmonary capillary wedge pressure ≤ 15 mm Hg¹.

HIV-infected patients have an increased risk of PAH compared to general population. Mechanism underlying the increased risk of PAH in HIV is still not clearly elucidated. The prevalence of PAH is estimated to be 0.5% in HIV-infected patients compared to the 0.02% in HIV seronegative people². PAH onset is independent from age, race, duration of HIV disease (expressed as the time from diagnosis of HIV infection to time of PAH diagnosis), and ongoing highly active antiretroviral therapy (HAART), while resulted to be associated with intravenous drug use³. There was no overall difference with

regard to lymphocyte T CD4+ cells count, but the proportion of patients with a lymphocyte T CD4+ count of less than 200/mm³ was significantly higher in those with PAH³.

PAH prevalence remained unchanged even after introduction of HAART, being right heart failure a major cause of death in this population³.

Two orally active endothelin receptor antagonists are currently approved for the treatment of PAH: the dual receptor-antagonist bosentan and the most selective ET(A) receptor-antagonist ambrisentan. These drugs have the advantage of oral formulation, and have shown efficacy on improving exercise capacity, quality of life and hemodynamics in HIV infected patients with PAH, both in short-term and long term⁴.

However, limited data regarding both the impact of HAART in the disease pathogenesis and progression⁵ and the patterns of drug-drug interactions between HAART and compounds used for the treatment of PAH are available^{6,7}. We report a case of a successful therapy for PAH with bosentan in a HIV-infected patient in stable fosamprenavir/ritonavir (fAPV/r) based-regimen.

CASE REPORT

A 43 year-old Caucasian woman was diagnosed with HIV-1 and hepatitis C virus co-infections in 1989.

Her past medical history included intravenous drug use from 1982 to 1986. She started HAART in 1998 with zidovudine + lamivudine and nevirapine with poor adherence in the first years. After pregnancy (2002) and the birth of an HIV-negative child, the patient improved adherence to the same therapy, and CD4+ cell reached a stable count of more 500 cell/mm³ with HIV-RNA persistently below 50 copies/ml.

In 2007, the patient complained of hemoptysis and mild dyspnea, at this time she was receiving tenofovir (300 mg) plus emtricitabine (200 mg) once daily and twice-daily fAPV/r (100/700 mg); HIV-RNA was below 50 copies/ml, and a lymphocyte T CD4+ was 515 cell/mm³ (25%).

Computer Tomography (CT) scan showed pulmonary micro nodules, in absence of fibrosis or signs of pulmonary embolism; a moderate (40 mm) ectasia of the trunk and both left (27 mm) and right (25 mm) branches of pulmonary artery (PA) were also reported. Microbiological exams of sputum and bronchoalveolar lavage were negative, including detection of mycobacteria. Esophagogastrosocopy was unremarkable. Presence of an increased estimated systolic pulmonary pressure (PAPs 65 mmHg) was noticed at echocardiography; however, due to progressive spontaneous clinical improvement and absence of cardiac dilatation or right ventricular function impairment signs, no further test was recommended at that time. In the following years the patient continued HAART and regular follow-up without any symptom.

In January 2011 dyspnea and asthenia reappeared, along with episodes of hemoptysis. A new pulmonary CT scan showed progression of the arterial dilatation (PA trunk 42 mm, left PA 30 mm, right PA 30 mm). She was thus referred to the pulmonary hypertension unit of our institution; echocardiography highlighted increased esti-

mated pulmonary pressures (PAPs 55 mmHg, PAP mean (PAPm) 34 mmHg), signs of initial right ventricular (RV) dilation (33 mm) and septal pressure overload. Accordingly, right heart catheterization confirmed severe pulmonary hypertension with high pulmonary vascular resistances and preserved right ventricular function (PAPs 95/35 mmHg, PAPm 57 mmHg, Wedge 14 mmHg, Cardiac Index 3.15 L/min/m², pulmonary vascular resistance (PVR) 635 dynes/sec/cm⁻⁵). N-terminal prohormone of brain natriuretic peptide (NT-proBNP) was 131 ng/L. Treatment with ambrisentan was started but discontinued after 1 week for clinically confirmed hypersensitivity.

After a short wash-out, treatment with bosentan was introduced at the dosage of 62.5 mg twice-daily, without any modification of HAART. Due to previous intolerance and potential drug-drug interaction with a boosted protease inhibitor (PI), a slower 8-week titration of the endothelin receptor antagonist was planned; two weeks after bosentan initiation, measurement of fAPV therapeutic drug monitoring (TDM) by a validated high-performance liquid chromatography/photodiode array detection (HPLC-PDA)⁸ was performed at the end of dosing interval (T0) and 2 hours post drug intake (T2). (Figure 1). Since fAPV plasma concentrations were in the expected range and no side effects were reported, bosentan dose was increased to 125 mg twice-daily. fAPV TDM was repeated one month after bosentan titration (Figure 1, dashed line). For both dosages, fAPV plasma exposure resulted to be higher in the second measurement as compared to the first (1390 ng/ml vs 1492 ng/ml at T0 and 4232 ng/ml vs 5036 ng/ml at T2). Tolerability of both therapies and a discrete benefit on both exercise capacity (+28m at 6-minute walk test) and symptoms were confirmed.

At 12 months of follow-up, HIV-RNA was persistently below <50 copies/ml and lymphocyte CD4+ cell count was 514 cells/mL. Laboratory data excluded hepatic toxicity and the patient did not report any further episode of hemoptysis nor other symptoms related to PAH.

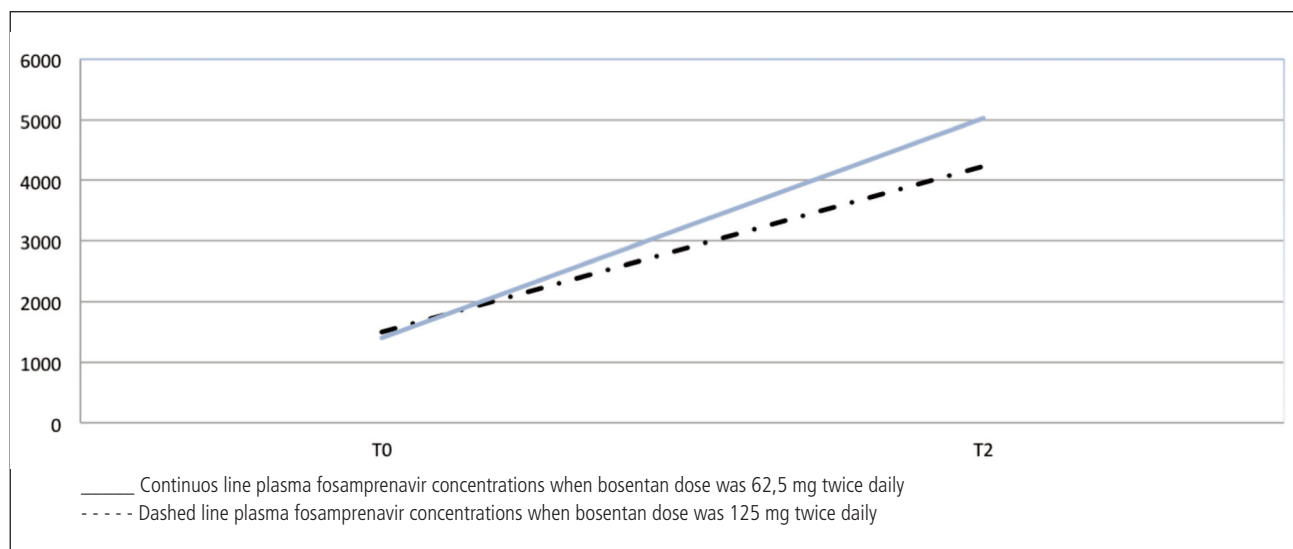


Figure 1. Fosamprenavir concentrations values in the course of different dosage of bosentan. T0: Fosamprenavir *C*rough before administration; T2: Fosamprenavir *C* 2 hours after administration.

Eight months later, follow-up right heart catheterization confirmed satisfactory response to first line therapy (PAPs 70 mmHg; PAP diastolic 5 mmHg; PAPm 42 mmHg; Cardiac Index 3.72 L/min/m²; PVR 421 dynes/sec/cm⁻⁵).

DISCUSSION

This is the first case report of co-administration of bosentan and fAPV/r in the clinical setting. TDM of fAPV concentration with two different dosages of bosentan showed a moderate increase of the PI concentration with no clinical implication. In fact, no modification of HAART efficacy and tolerability has been observed in the follow up. Bosentan has been estimated to have both CYP-3A4 and CYP2C9-inducing properties⁹, and could be therefore related to a theoretical decrease of concomitant PI concentrations, known substrates of CYP3A4. In our HIV-infected patients, as opposite, a possible dose-related effect of bosentan in increasing fAPV concentration was observed (Figure 1). Although in a single case no conclusion can be drawn, our follow up confirmed the maintenance of adequate plasma exposure of fAPV. Unfortunately, measurements of bosentan plasma levels were not available. However, optimal tolerability of the treatment and absence of bosentan toxicity in the follow up suggested that the theoretical increase of bosentan concentration associated to concomitant boosted PI¹⁰ was not clinically significant in our patient.

PAH is a relevant comorbidity in HIV-infected patients, requiring clinical awareness and specific treatment. Due to the substantial lack of clinical information on pharmacological compatibility of endothelin receptor antagonist and HAART, facing a high potential for drug-drug interaction, our case supports the safe and effective coadministration of bosentan and fAPV boosted by ritonavir.

REFERENCES

1. Hoeper MM. Definition, classification, and epidemiology of pulmonary arterial hypertension. *Semin Respir Crit Care Med* 2009; 30: 369-375.
2. Grubb JR, Moorman AC, Baker RK, Masur H. The changing spectrum of pulmonary disease in patients with HIV infection on antiretroviral therapy. *AIDS* 2006; 20: 1095-1097.
3. Sitbon O, Lascoux-Combe C, Delfraissy JF, Yeni PG, Raffi F, De Zuttere D, Gressin V, Clerson P, Sereni D, Simonneau G. Prevalence of HIV-related pulmonary arterial hypertension in the current antiretroviral therapy era. *Am J Respir Crit Care Med* 2008; 177: 108-113.
4. Degano B, Yaïci A, Le Pavec J, Savale L, Jaïs X, Camara B, Humbert M, Simonneau G, Sitbon O. Long-term effects of bosentan in patients with HIV-associated pulmonary arterial hypertension. *Eur Respir J* 2009; 33: 92-98.
5. Zuber JP, Calmy A, Evison JM, Hasse B, Schiffer V, Wagels T, Nuesch R, Magenta L, Ledergerber B, Jenni R, Speich R, Opravil M. Swiss HIV Cohort Study Group. Pulmonary arterial hypertension related to HIV infection: improved hemodynamics and survival associated with antiretroviral therapy. *Clin Infect Dis* 2004; 38: 1178-1185.
6. Dingemans J, van Giersbergen PL, Patat A, Nilsson PN. Mutual pharmacokinetic interactions between bosentan and lopinavir/ritonavir in healthy participants. *Antivir Ther* 2010; 15: 157.
7. Hardy H, Backman ES, Farber HW. Successful bosentan and non nucleoside reverse transcriptase inhibitor-based therapy in a patient with acquired immunodeficiency syndrome and pulmonary arterial hypertension. *Pharmacotherapy* 2010; 30: 139e-144e.
8. D'Avolio A, Baietto L, Siccardi M, Sciandra M, Simiele M, Oddone V, Bonora S, Di Perri G. An HPLC-PDA method for the simultaneous quantification of the HIV integrase inhibitor raltegravir, the new non nucleoside reverse transcriptase inhibitor etravirine, and 11 other antiretroviral agents in the plasma of HIV-infected patients. *Ther Drug Monit* 2008; 30: 662-669.
9. Spangler ML, Saxena S. Warfarin and bosentan interaction in a patient with pulmonary hypertension secondary to bilateral pulmonary emboli. *Clin Ther* 2010; 32: 53-56.
10. GlaxoSmithKline. Lexiva (fosamprenavir) package insert. Research Triangle Park, NC, 2012.