

AperTO - Archivio Istituzionale Open Access dell'Università di Torino

Comparative profile of cutaneous adverse events: BRAF/MEK inhibitor combination therapy versus BRAF monotherapy in melanoma.

This is the author's manuscript

Original Citation:

Availability:

This version is available <http://hdl.handle.net/2318/157152> since 2016-06-21T13:31:33Z

Published version:

DOI:10.1016/j.jaad.2014.09.002. Epub 2014 Oct 16.

Terms of use:

Open Access

Anyone can freely access the full text of works made available as "Open Access". Works made available under a Creative Commons license can be used according to the terms and conditions of said license. Use of all other works requires consent of the right holder (author or publisher) if not exempted from copyright protection by the applicable law.

(Article begins on next page)

Published in final edited form as:

J Am Acad Dermatol. 2014 December ; 71(6): 1102–1109.e1. doi:10.1016/j.jaad.2014.09.002.

Comparative profile of cutaneous adverse events: BRAF/MEK inhibitor combination therapy versus BRAF monotherapy in melanoma

Martina Sanlorenzo, MD^{1,2}, Aditi Choudhry, MD¹, Igor Vujic, MD^{1,3}, Christian Posch, MD^{1,3}, Kim Chong, MD¹, Katia Johnston¹, Melissa Meier, MD¹, Simona Osella-Abate, MSc², Pietro Quaglino, MD², Adil Daud, MD¹, Alain Algazi, MD¹, Klemens Rappersberger, MD³, and Susana Ortiz-Urda, MD PhD¹

¹University of California San Francisco, Mt. Zion Cancer Research Center, 2340 Sutter Street N461, 94115 San Francisco – USA

²Department of Medical Sciences, Section of Dermatology, University of Turin - Italy

³The Rudolfstiftung Hospital, Academic Teaching Hospital, Medical University Vienna, Department of Dermatology, Juchgasse 25, 1030 Vienna – Austria

Abstract

Background—BRAF and MEK inhibitors frequently cause cutaneous adverse events.

Objective—To investigate the cutaneous safety profile of BRAF inhibitors versus BRAF- and MEK-inhibitor combination regimens.

Methods—We performed a retrospective cohort study, collecting data from 44 melanoma patients treated either with BRAF inhibitors (vemurafenib or dabrafenib) or BRAF- and MEK-inhibitor combination regimens (vemurafenib+cobimetinib or dabrafenib+trametinib). Patient characteristics, as well as the occurrence and severity of cutaneous adverse events are described.

Results—The development of cutaneous adverse events was significantly less frequent ($p=0.012$) and occurred after longer treatment time ($p=0.025$) in patients treated with BRAF- and MEK-inhibitor combination regimen compared to patients treated with BRAF inhibitor monotherapy. Among patients who received both BRAF inhibitor treatment and the combination of BRAF- and MEK-inhibitor at different time points during their treatment course, the development of squamous cell carcinoma or keratoacanthoma was significantly less frequent when they received the combination regimen ($p=0.008$). Patients receiving vemurafenib developed more

© 2014 by the American Academy of Dermatology, Inc. All rights reserved.

Correspondence should be addressed to: Martina Sanlorenzo, MD, University of California San Francisco, Department for Dermatology, Mt. Zion Cancer Research Center, 2340 Sutter Street N461, 94115 San Francisco – USA, martina.sanlorenzo@hotmail.it phone: +1 650 224 8265.

The authors state no conflict of interest

Publisher's Disclaimer: This is a PDF file of an unedited manuscript that has been accepted for publication. As a service to our customers we are providing this early version of the manuscript. The manuscript will undergo copyediting, typesetting, and review of the resulting proof before it is published in its final citable form. Please note that during the production process errors may be discovered which could affect the content, and all legal disclaimers that apply to the journal pertain.

cutaneous adverse events ($p=0.001$) and in particular more photosensitivity ($p=0.010$) than patients who did not.

Limitations—Limited number of patients.

Conclusion—Combination regimen with BRAF- and MEK-inhibitors shows fewer cutaneous adverse events and longer cutaneous adverse event-free interval compared to BRAF inhibitor monotherapy.

Keywords

histology; inflammation; rash; squamous cell carcinoma; therapy; cutaneous adverse event

INTRODUCTION

Pharmacological inhibition of the mitogen-activated protein kinases (MAPK) pathway by targeting the mutant v-Raf murine sarcoma viral oncogene homolog B1 (BRAF) is a milestone in the management of metastatic melanoma. BRAF-inhibitors (BRAFi), such as vemurafenib and dabrafenib, have been associated with prolonged progression-free and overall survival^{1,2}. MEK inhibitors (MEKi), such as cobimetinib³ and trametinib have also been associated with improved progression-free and overall survival in BRAF⁴ mutant melanoma and neuroblastoma rat sarcoma viral oncogene homolog (NRAS)⁵ mutant melanoma. Despite these advances in melanoma treatment, disease progression occurs in approximately 50% of patients within 6 to 7 months of commencing therapy with either a BRAFi or MEKi^{1,2,6,7}. This is due to several mechanisms of resistance, most of which seem to rely on reactivation of the MAPK pathway^{8–10}. Therefore, in order to avoid or delay resistance to a single drug, combination therapies with BRAFi and MEKi have been explored¹¹. In phase 1 and 2 studies, combination regimens showed improved progression-free survival over single inhibitor therapy¹². Vemurafenib and dabrafenib are approved by the Food and Drug Administration (FDA) for the treatment of patients with unresectable or metastatic melanoma with a BRAF V600E mutation, as detected by an FDA-approved test. The recommended dosages of vemurafenib and dabrafenib are 960 mg and 150 mg, respectively, both taken orally twice daily. Trametinib is approved for the treatment of patients with unresectable or metastatic melanoma with BRAF V600E and V600K mutations, as detected by an FDA-approved test, and the recommended dose is 2 mg orally once daily. Ongoing clinical trials are exploring these drugs in an adjuvant setting for stage III (AJCC) patients¹³. Treatment with vemurafenib causes a multitude of cutaneous adverse events, such as exanthema, photosensitivity, palmarplantar dysesthesia or hand-foot syndrome (HFS), alopecia, pruritus, keratosis pilaris-like eruptions (KP), actinic keratosis (AK), hyperkeratosis, skin papillomas, keratoacanthomas (KA) and cutaneous squamous-cell carcinomas (SCC)^{1,7,14–16}. The most frequent cutaneous adverse events of dabrafenib are hyperkeratosis, papilloma, alopecia, and palmar-plantar erythrodysesthesia syndrome. Trametinib is more frequently related with the development of acneiform dermatitis or alopecia^{4,17}. Less is known about the cutaneous adverse events related to cobimetinib. In a phase Ib trial where cobimetinib was administered in combination with a pan-PI3K inhibitor, 50% of the patients developed a cutaneous rash¹⁸. Interestingly, when BRAF- and

MEK inhibitor drugs are combined, the development of cutaneous adverse events specific for each drug appear to be reduced^{6,12}.

The number of patients treated with BRAF and MEK inhibitor combination is increasing, and a better understanding of the type and morphology of related cutaneous adverse events and their management is needed. In this retrospective study, we collected data on 44 patients treated with either a BRAF inhibitor alone or the combination of a BRAFi and a MEKi (BRAFi+MEKi). We have clinically and histologically characterized the cutaneous adverse events of BRAFi monotherapy and of combination regimens.

MATERIALS AND METHODS

We performed a retrospective cohort study, and included patients with stage IV or unresectable stage III melanoma¹⁹ who received BRAFi monotherapy or BRAFi+MEKi combination therapy. All patients were treated and followed-up at the University of California, San Francisco (UCSF) between November 2009 and August 2013. Thirty-two patients received treatment with a BRAFi and 23 patients received BRAFi+MEKi combination. Eleven patients received both BRAFi monotherapy and BRAFi+MEKi regimen at different time points during their treatment. Among the patients treated with a BRAFi: 27 received vemurafenib (PLX4032) at a dose of 960 mg bid (phase III clinical trial, NCT01006980), and 5 patients received dabrafenib (GSK2118436) at a dose of 150 mg bid (phase III clinical trial, NCT01227889). In the BRAFi+MEKi group, 15 patients received a combination of dabrafenib at 150 mg bid and trametinib (GSK1120212) at 2 mg daily (phase II clinical trial, NCT01072175), and 8 patients received a combination of vemurafenib at 960 mg bid on days 1–28 of each cycle and cobimetinib (GDC-0973) at 60 mg daily on days 1–21 of each cycle (phase Ib clinical trial, NCT01271803). All treatment decisions were made by the patient's medical oncologist. Collected data included patient demographics, course of the disease, medications (previous chemotherapy and immunotherapy – including interleukin-2, interferon or anti-CTLA 4 antibodies), cutaneous adverse events, the treatment of those adverse events, and the response to treatment. Patients were evaluated at baseline by a dermatologist with full body skin exams (FBSE) and followed-up at four- to six-week intervals or upon patient request, in case of development of cutaneous adverse events. All cutaneous adverse events were ascertained by a dermatologist based on clinical and histological findings. Adverse events were graded based on the National Cancer Institute's Common Terminology Criteria for Adverse Events (CTCAE) Version 4.03 (v4.03: June 14th 2010)²⁰ (Table 1S). The study design has been reviewed and approved by the Committee on Human Research of the University of California, San Francisco.

Statistical analyses were performed using Stata 12.0 Statistical Software. Comparisons between independent groups were performed using Fisher's exact test. The confidence intervals (CIs) calculation was performed for the estimated frequencies, considering the variable as binomial (0/1) and using an exact binomial confidence interval. Comparisons between correlated groups were performed using McNemar's exact test. Kaplan–Meier curves were used to analyze the time of development of cutaneous adverse events, and the statistical comparisons between groups were done using the log-rank test. To analyze the

safety profile of vemurafenib, either as monotherapy or in combination, we compared patients who received vemurafenib to those who did not receive the drug, assessing if they ever developed the event of interest. A p-value <0.05 was considered significant.

RESULTS

A total of 44 patient charts were reviewed. Thirty-two patients were treated with a BRAFi as monotherapy (27 with vemurafenib, 5 with dabrafenib) and 23 were treated with a combination of BRAFi+MEKi (8 with vemurafenib+cobimetinib, 15 with dabrafenib +trametinib). The baseline characteristics of the patients in the study groups are outlined in Table 1. None of the patients included in the study experienced grade 4 or 5 cutaneous adverse events. Grade 3 cutaneous adverse events were recorded in eight patients treated with the single agent vemurafenib, and in 2 patients during BRAFi+MEKi combination therapy (one treated with vemurafenib + cobimetinib, and one treated with dabrafenib + trametinib).

Thirty-three patients received single treatment regimen (either BRAFi or BRAFi+MEKi combination but not both) during their disease history; a detailed list of all the cutaneous adverse events recorded in these patients is reported in Table 2, and representative clinical pictures are presented in Figure 1. Eleven patients received both a BRAFi alone, and BRAFi +MEKi combination at different time points during their treatment course. A detailed description of their cutaneous adverse events is reported in Table 3. Out of these eleven patients, eight received the same BRAFi (vemurafenib or dabrafenib) both as monotherapy and in combination with MEKi.

Among the patients who received only single treatment regimen (either BRAFi monotherapy or BRAFi+MEKi combination treatment) during their disease history, we observed that cutaneous adverse events occurred more frequently during BRAFi monotherapy than during BRAFi+MEKi combination therapy (N=21/21, 100%, 95% CI 83.9–100 vs N=8/12, 66.67%, 95% CI 34.9–90.1; p=0.012). Kaplan-Meier curves showed a significant difference in the time of development of cutaneous adverse events between BRAFi monotherapy and BRAFi+MEKi combination therapy (p=0.0246). The median cutaneous adverse event-free interval was 28 days (range 7–470) for BRAFi monotherapy, and 122.5 days (range 7–341) for BRAFi+MEKi combination therapy. Kaplan-Meier curves comparing all four treatment groups also demonstrated a significant difference (p=0.0002); the median cutaneous adverse event-free interval was 28.5 (range 7–470) days for vemurafenib, 26 (range 14–106) days for dabrafenib, 10 (range 7–13) days for vemurafenib+cobimetinib and 150.5 (range 19–341) days for dabrafenib+trametinib (Figure 2).

Among the 11 patients who received both BRAFi monotherapy and BRAFi+MEKi combination treatment at different time points during their disease course, 10 developed cutaneous adverse events during BRAFi monotherapy (90.9%, 95% CI 58.7–99.8), and 5 developed cutaneous adverse events during BRAFi+MEKi combination therapy (45.5%, 95% CI 16.7–76.6)(p=0.2188). Four out of 11 patients developed actinic keratosis during BRAFi monotherapy and no one developed it during combination treatment (36.4%, 95% CI 10.9–69.2 vs 0%, 95% CI 0–28.5; p=0.0156). Three out of 11 patients developed SCC or

KA during BRAFi monotherapy, and no one developed SCC or KA during combination treatment (27.3%, 95% CI 6–61 vs 0%, 95% CI 0-28.5; $p=0.0078$).

Twenty-nine out of 44 patients received vemurafenib either in monotherapy or in combination. They developed cutaneous adverse events significantly more frequently than patients who never received vemurafenib ($N=29/29$, 100%, 95% CI 88.1-100 vs $N=10/15$, 66.7%, 95% CI 38.4-88.2; $p=0.001$). Thirteen out of 29 patients treated with vemurafenib (44.8%, 95% CI 26.4-64.3), and one out of 15 patients who did not receive vemurafenib (6.7%, 95% CI 0.2-31.9) developed photosensitivity ($p=0.010$).

DISCUSSION

Following approval by the FDA, targeted inhibitors have become an important treatment modality for patients with BRAF mutant melanoma. It is anticipated that the number of patients receiving a single or combinational inhibitor treatment will increase significantly in the near future. For this reason, knowledge about the incidence and the appearance of cutaneous adverse events associated with targeted inhibitor therapy is critical for optimal patient care. In this study we present the data on patients treated with two different BRAFi (vemurafenib or dabrafenib), and two different combination regimens of a BRAFi and MEKi (vemurafenib + cobimetinib or dabrafenib + trametinib).

Among our patients who received single treatment regimen (either BRAFi monotherapy or BRAFi+MEKi combination treatment), cutaneous adverse events occurred more frequently and faster during BRAFi therapy than during BRAFi+MEKi combination therapy. In particular, we observed a longer cutaneous adverse event-free interval during treatment with a combination of dabrafenib and trametinib.

The development of actinic keratosis, a well-known precursor of SCC, was frequent during monotherapy with both BRAFi. It has been reported that the development of cutaneous SCC during BRAFi therapy is caused by activation of the MAPK pathway in keratinocytes with preexisting RAS mutations commonly found in chronically sun damaged skin. Although BRAF inhibitors potentially reduce RAF signaling in BRAF mutant cells, leading to apoptosis and tumor shrinkage, they cause increased CRAF signaling in wild type cells, leading to the development of SCC^{21–23}. The concomitant administration of a MEKi reduces this activation and therefore has preventive effects on the development of SCC and KA¹¹. Interestingly, the 11 patients who received both BRAFi and BRAFi+MEKi at different time points, developed actinic keratosis and SCC or KA significantly less frequently during the combination treatment.

Photosensitivity is another well-known adverse event experienced during vemurafenib treatment^{1,7,14}. Previous studies speculated that this is due to the chemical structure of the drug and UVA exposure²⁴, rather than due to BRAF inhibition and the subsequent consequences on MAPK signaling. In our experience, also, photosensitivity was more frequent in patients treated with vemurafenib. Regardless of the treatment regimen, anytime a patient receives vemurafenib, particular attention should be given to sun exposure prevention measures.

The most common adverse event previously reported during trametinib monotherapy is acneiform dermatitis^{5,12,17,25}. The mechanism triggering this reaction is still unknown, but a fundamental role of the PI3K/AKT pathway has been hypothesized. Indeed, MEKi relieves a negative feedback loop in the PI3K/AKT pathway leading to increased AKT signaling²⁶ that is known to play a central role in acne pathogenesis^{27,28}. Another hypothesis previously reported is that these acneiform eruptions could be a result of drug-induced apoptosis of keratinocytes disturbing epidermal homeostasis¹⁷. In our study, trametinib was only administered in combination with a BRAFi, and as reported previously, acneiform eruptions appeared to be less frequent with this combination compared to historical data pertaining to MEKi alone^{11,17}.

Eight patients treated with BRAFi and only two treated with the combination regimen had to reduce the inhibitor dosage or interrupt the treatment due to cutaneous adverse events. In the BRAFi group, dosage reduction or interruption of treatment had to be done for patients treated with vemurafenib who developed the following cutaneous adverse events: maculopapular rash (4 patients), acneiform rash (3 patients), and oral blisters (1 patient). Two patients in the BRAFi+MEKi group developed panniculitis-like reaction, which did not respond to non-steroidal anti-inflammatory drugs (NSAID). Interestingly, one patient treated with the combination of vemurafenib (days 1–28 of each cycle) and cobimetinib (days 1–21 of each cycle) reported a correlation between the severity of xerosis, acneiform rash, and pre-existing psoriasis with the drugs' schedule. The skin condition improved during combination regimen and worsened when the MEKi was withheld.

From the results of this study, we conclude that each inhibitor and each combination has a particular cutaneous safety profile. Knowledge of expected cutaneous adverse events can help clinical decision-making during follow-up.

Acknowledgments

We are indebted to Ann Lazar, PhD (Assistant professor –The Clinical & Translational Science Institute (CTSI), University of California, San Francisco) for her help in the statistical analysis.

Funding sources: This study was supported by the National Cancer Institute of the National Institutes of Health under award number K08CA155035. The content is solely the responsibility of the authors and does not necessarily represent the official views of the National Institutes of Health. The authors are also grateful to Timothy Dattels, the Melanoma Research Alliance and the National Center for Advancing Translational Sciences, the National Institutes of Health (through UCSF-CTSI Grant Number UL1 TR000004) for their generous support.

References

1. Chapman PB, Hauschild A, Robert C, et al. Improved survival with vemurafenib in melanoma with BRAF V600E mutation. *N Engl J Med*. 2011; 364(26):2507–2516. 10.1056/NEJMoa1103782 [PubMed: 21639808]
2. Hauschild A, Grob J-J, Demidov LV, et al. Dabrafenib in BRAF-mutated metastatic melanoma: a multicentre, open-label, phase 3 randomised controlled trial. *Lancet*. 2012; 380(9839):358–365. 10.1016/S0140-6736(12)60868-X [PubMed: 22735384]
3. LoRusso P, Shapiro G, Pandya SS, et al. A first-in-human phase Ib study to evaluate the MEK inhibitor GDC-0973, combined with the pan-PI3K inhibitor GDC-0941, in patients with advanced solid tumors. *J Clin Oncol*. 2012; 30(suppl):abstr 2566. Available at: <http://meetinglibrary.asco.org/content/94732-114>.

4. Flaherty KT, Robert C, Hersey P, et al. Improved survival with MEK inhibition in BRAF-mutated melanoma. *N Engl J Med.* 2012; 367(2):107–114.10.1056/NEJMoa1203421 [PubMed: 22663011]
5. Ascierto PA, Schadendorf D, Berking C, et al. MEK162 for patients with advanced melanoma harbouring NRAS or Val600 BRAF mutations: a non-randomised, open-label phase 2 study. *Lancet Oncol.* 2013; 14(3):249–256.10.1016/S1470-2045(13)70024-X [PubMed: 23414587]
6. Flaherty KT, Robert C, Hersey P, et al. Improved survival with MEK inhibition in BRAF-mutated melanoma. *N Engl J Med.* 2012; 367(2):107–114.10.1056/NEJMoa1203421 [PubMed: 22663011]
7. Sosman JA, Kim KB, Schuchter L, et al. Survival in BRAF V600-mutant advanced melanoma treated with vemurafenib. *N Engl J Med.* 2012; 366(8):707–714.10.1056/NEJMoa1112302 [PubMed: 22356324]
8. Nazarian R, Shi H, Wang Q, et al. Melanomas acquire resistance to B-RAF(V600E) inhibition by RTK or N-RAS upregulation. *Nature.* 2010; 468(7326):973–977.10.1038/nature09626 [PubMed: 21107323]
9. Poulidakos PI, Persaud Y, Janakiraman M, et al. RAF inhibitor resistance is mediated by dimerization of aberrantly spliced BRAF(V600E). *Nature.* 2011; 480(7377):387–390.10.1038/nature10662 [PubMed: 22113612]
10. Johannessen CM, Boehm JS, Kim SY, et al. COT drives resistance to RAF inhibition through MAP kinase pathway reactivation. *Nature.* 2010; 468(7326):968–972.10.1038/nature09627 [PubMed: 21107320]
11. Flaherty KT, Infante JR, Daud A, et al. Combined BRAF and MEK inhibition in melanoma with BRAF V600 mutations. *N Engl J Med.* 2012; 367(18):1694–1703.10.1056/NEJMoa1210093 [PubMed: 23020132]
12. Flaherty KT, Infante JR, Daud A, et al. Combined BRAF and MEK inhibition in melanoma with BRAF V600 mutations. *N Engl J Med.* 2012; 367(18):1694–1703.10.1056/NEJMoa1210093 [PubMed: 23020132]
13. [Accessed September 18, 2013] Home - ClinicalTrials.gov. Available at: <http://clinicaltrials.gov/>
14. Flaherty KT, Puzanov I, Kim KB, et al. Inhibition of mutated, activated BRAF in metastatic melanoma. *N Engl J Med.* 2010; 363(9):809–819.10.1056/NEJMoa1002011 [PubMed: 20818844]
15. Manousaridis I, Mavridou S, Goerd S, Leverkus M, Utikal J. Cutaneous side effects of inhibitors of the RAS/RAF/MEK/ERK signalling pathway and their management. *J Eur Acad Dermatol Venereol J EADV.* 2013; 27(1):11–18.10.1111/j.1468-3083.2012.04546.x
16. Mattei PL, Alora-Palli MB, Kraft S, Lawrence DP, Flaherty KT, Kimball AB. Cutaneous effects of BRAF inhibitor therapy: a case series. *Ann Oncol Off J Eur Soc Med Oncol ESMO.* 2013; 24(2): 530–537.10.1093/annonc/mds292
17. Anforth R, Liu M, Nguyen B, et al. Acneiform eruptions: A common cutaneous toxicity of the MEK inhibitor trametinib. *Australas J Dermatol.* 2013;10.1111/ajd.12124
18. Shapiro G, LoRusso P, Kwak EL, et al. Clinical combination of the MEK inhibitor GDC-0973 and the PI3K inhibitor GDC-0941: A first-in-human phase Ib study testing daily and intermittent dosing schedules in patients with advanced solid tumors. *J Clin Oncol.* 2011; 29(suppl):2011. abstr 3005. Available at: <http://meetinglibrary.asco.org/content/80274-102>. [PubMed: 21502544]
19. Balch CM, Gershenwald JE, Soong S-J, et al. Final version of 2009 AJCC melanoma staging and classification. *J Clin Oncol Off J Am Soc Clin Oncol.* 2009; 27(36):6199–6206.10.1200/JCO.2009.23.4799
20. National Cancer Institute Common Terminology Criteria for Adverse Events v4.0. NCI,NIH, DHHS; 2009. NIH publication # 09–7473
21. Hatzivassiliou G, Song K, Yen I, et al. RAF inhibitors prime wild-type RAF to activate the MAPK pathway and enhance growth. *Nature.* 2010; 464(7287):431–435.10.1038/nature08833 [PubMed: 20130576]
22. Su F, Viros A, Milagre C, et al. RAS mutations in cutaneous squamous-cell carcinomas in patients treated with BRAF inhibitors. *N Engl J Med.* 2012; 366(3):207–215.10.1056/NEJMoa1105358 [PubMed: 22256804]
23. Oberholzer PA, Kee D, Dziunycz P, et al. RAS mutations are associated with the development of cutaneous squamous cell tumors in patients treated with RAF inhibitors. *J Clin Oncol Off J Am Soc Clin Oncol.* 2012; 30(3):316–321.10.1200/JCO.2011.36.7680

24. Dummer R, Rinderknecht J, Goldinger SM. Ultraviolet A and Photosensitivity during Vemurafenib Therapy. *N Engl J Med*. 2012; 366(5):480–481.10.1056/NEJMc1113752 [PubMed: 22296092]
25. Falchook GS, Lewis KD, Infante JR, et al. Activity of the oral MEK inhibitor trametinib in patients with advanced melanoma: a phase 1 dose-escalation trial. *Lancet Oncol*. 2012; 13(8):782–789.10.1016/S1470-2045(12)70269-3 [PubMed: 22805292]
26. Turke AB, Song Y, Costa C, et al. MEK inhibition leads to PI3K/AKT activation by relieving a negative feedback on ERBB receptors. *Cancer Res*. 2012; 72(13):3228–3237.10.1158/0008-5472.CAN-11-3747 [PubMed: 22552284]
27. Smith TM, Gilliland K, Clawson GA, Thiboutot D. IGF-1 induces SREBP-1 expression and lipogenesis in SEB-1 sebocytes via activation of the phosphoinositide 3-kinase/Akt pathway. *J Invest Dermatol*. 2008; 128(5):1286–1293.10.1038/sj.jid.5701155 [PubMed: 17989724]
28. Melnik BC. FoxO1 - the key for the pathogenesis and therapy of acne? *J Dtsch Dermatol Ges J Ger Soc Dermatol JDDG*. 2010; 8(2):105–114.10.1111/j.1610-0387.2010.07344.x

CAPSULE SUMMARY

- BRAF- and MEK-inhibitors frequently cause cutaneous adverse events.
- Combination of BRAF- and MEK-inhibitors shows fewer cutaneous adverse events and longer cutaneous adverse event-free interval compared to BRAF inhibitor monotherapy.
- The knowledge of expected cutaneous adverse events can help clinical decision-making during follow-up

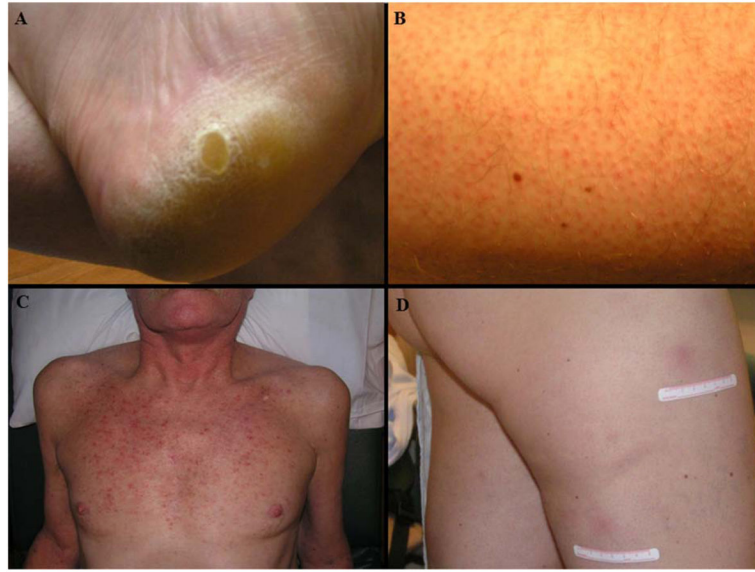


Figure 1. Cutaneous adverse events developed during BRAF inhibitor monotherapy: (1A) Palmar-Plantar Erythrodysesthesia; (1B) Keratosis pilaris; during BRAF- and MEK-inhibitor combinations: (1C) Acneiform rash; (1D) Erythema nodosum

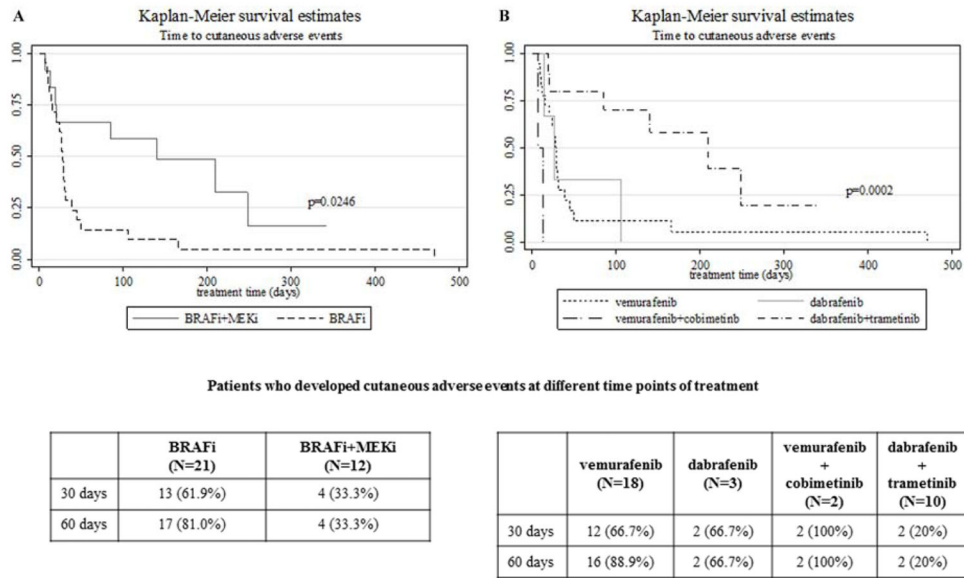


Figure 2. Kaplan-Meier curves. (2A) The onset of cutaneous adverse events is at an earlier time point in patients treated with BRAF inhibitor than patients treated with BRAF- and MEK-inhibitor combinations. (2B) Patients treated with dabrafenib+trametinib have longer adverse-free events interval.

Table 1

Characteristics of patients included in the study

| | BRAFⁱ (N=32) | | BRAFⁱ+MEKⁱ (N=23) | |
|---|--------------------------------|-------------------------|--|--------------------------------------|
| | vemurafenib (N=27) | dabrafenib (N=5) | vemurafenib +cobimetinib (N=8) | dabrafenib +trametinib (N=15) |
| Median age at the beginning of treatment – years (range) | 60.2 (18.3–87.9) | 60.4 (48.9–72.5) | 56.49 (19.9–70.3) | 55.1(33.9–70.1) |
| Median duration on treatment-months (range) | 8.2 (1–33.8) | 5.1 (0.9–9.3) | 5.9 (1.4–14.5) | 13.0 (1.8–30.3) |
| Sex- | | | | |
| Female | 10 (37%) | 3 (60%) | 4 (50%) | 9 (60%) |
| Male | 17 (63 %) | 4 (40%) | 4 (50 %) | 6 (40%) |
| BRAF mutation | | | | |
| V600E | 19 (70.4%) | 3 (60%) | 8 (100%) | 13 (86.7%) |
| V600K | 4 (14.8%) | 2 (40%) | - | 2(13.3%) |
| V600R | 1 (3.7%) | - | - | - |
| K601E | 2 (7.4%) | - | - | - |
| L597R | 1 (3.7%) | - | - | - |
| Stage of disease | | | | |
| 3B | 1 (3.7%) | - | - | - |
| 3C | 1 (3.7%) | - | - | - |
| 4 | 25 (92.6%) | 5 (100%) | 8 (100%) | 15 (100%) |
| Previous Chemotherapy | 14 (51.9%) | 2 (40%) | 4 (50%) | 6 (40%) |
| Previous Immunotherapy[£] | 15 (55.6%) | - | 5 (62.5%) | 7 (46.7%) |
| Current Immunotherapy | 3 (11.1%) | 1 (20%) | - | - |
| History of non-melanoma skin cancer | 9 (33.3%) | 1 (20%) | 5 (62.5%) | - |

[£]Immunotherapy included Interleukin-2, Interferon OR Ipilimumab (anti-CTLA 4 antibody)

Table 2

Cutaneous adverse events reported during BRAFi monotherapy and during BRAFi+MEKi combination therapy in patients who received single treatment regimen (either BRAFi monotherapy or BRAFi+MEKi combination treatment but not both)

| | BRAFi (N=21) | | BRAFi + MEKi (N=12) | |
|--|------------------------|---------------------|--------------------------------|-------------------------------|
| | vemurafenib (N=18) | dabrafenib (N=3) | vemurafenib +cobimetinib (N=2) | dabrafenib +trametinib (N=10) |
| | <i>no. (% [95%CI])</i> | | | |
| Any cutaneous side effect | 18 (100 [81.5–100]) | 3 (100 [29.2–100]) | 2 (100 [15.8–100]) | 6 (60 [26.2–87.8]) |
| Photosensitivity | 4 (22.2 [6.4–47.6]) | 1 (33.3 [0.8–90.6]) | 2 (100 [15.8–100]) | 0 (0 [0–30.8]) |
| Actinic keratosis (AK) | 8 (44.4 [21.5–69.2]) | 2 (66.7 [9.4–99.2]) | 1 (50 [1.3–98.7]) | 1 (10 [2.5–44.5]) |
| Cutaneous squamous-cell carcinoma (SCC) and Keratoacanthoma (KA) | 4 (22.2 [6.4–47.6]) | 0 (0 [0–70.8]) | 1 (50 [1.3–98.7]) | 0 (0 [0–30.8]) |
| Alopecia | 2 (11.1 [1.4–34.7]) | 0 (0 [0–70.8]) | 0 (0 [0–84.2]) | 0 (0 [0–30.8]) |
| Maculopapular rash | 8 (44.4 [21.5–69.2]) | 0 (0 [0–70.8]) | 0 (0 [0–84.2]) | 3 (30 [6.7–65.2]) |
| Acneiform rash | 1 (5.6 [0.1–27.3]) | 1 (33.3 [0.8–90.6]) | 1 (50 [1.3–98.7]) | 2 (20 [2.5–55.6]) |
| Eczema | 0 (0 [0–18.5]) | 0 (0 [0–70.8]) | 0 (0 [0–84.2]) | 3 (30 [6.7–65.2]) |
| Pruritis | 6 (33.3 [13.3–59]) | 1 (33.3 [0.8–90.6]) | 0 (0 [0–84.2]) | 0 (0 [0–30.8]) |
| Xerosis | 2 (11.1 [1.4–34.7]) | 0 (0 [0–70.8]) | 0 (0 [0–84.2]) | 3 (30 [6.7–65.2]) |
| Panniculitis-like reaction | 3 (16.7 [3.6–41.4]) | 1 (33.3 [0.8–90.6]) | 0 (0 [0–84.2]) | 3 (30 [6.7–65.2]) |
| Keratosis pilaris (KP) | 3 (16.7 [3.6–41.4]) | 1 (33.3 [0.8–90.6]) | 0 (0 [0–84.2]) | 1 (10 [2.5–44.5]) |
| Warts | 4 (22.2 [6.4–47.6]) | 0 (0 [0–70.8]) | 1 (50 [1.3–98.7]) | 1 (10 [2.5–44.5]) |
| Palmar-Plantar Erythrodysesthesia or Hand-Foot Syndrome (HFS) | 1 (5.6 [0.1–27.3]) | 0 (0 [0–70.8]) | 1 (50 [1.3–98.7]) | 1 (10 [2.5–44.5]) |
| Nevi changes | 1 (5.6 [0.1–27.3]) | 0 (0 [0–70.8]) | 0 (0 [0–84.2]) | 0 (0 [0–30.8]) |
| Acrochordon (Skin Tag) | 1 (5.6 [0.1–27.3]) | 0 (0 [0–70.8]) | 0 (0 [0–84.2]) | 2 (20 [2.5–55.6]) |
| Oral Blisters | 1 (5.6 [0.1–27.3]) | 0 (0 [0–70.8]) | 0 (0 [0–84.2]) | 0 (0 [0–30.8]) |

Table 3

Cutaneous adverse events reported in patients who received at different time points during their treatment course both BRAFi monotherapy and BRAF+MEKi combination therapy

| | BRAFi (N=11) | | BRAFi + MEKi (N=11) | |
|--|-----------------------|-------------------|---------------------------------|-------------------------------|
| | vemurafenib (N=9) | dabrafenib (N=2) | vemurafenib + cobimetinib (N=6) | dabrafenib + trametinib (N=5) |
| | <i>no. (%[95%CI])</i> | | | |
| Any cutaneous side effect | 9 (100 [66.4–100]) | 1 (50 [1.3–98.7]) | 3 (50 [11.8–88.2]) | 2 (40 [5.3–85.3]) |
| Photosensitivity | 7 (77.8 [40–97.2]) | 0 (0 [0–84.2]) | 1 (16.7 [0.4–64.1]) | 0 (0 [0–52.2]) |
| Actinic keratosis (AK) | 4 (44.4 [13.7–78.8]) | 0 (0 [0–84.2]) | 0 (0 [0–45.9]) | 0 (0 [0–52.2]) |
| Cutaneous squamous-cell carcinoma (SCC) and Keratoacanthoma (KA) | 3 (33.3 [7.5–70.1]) | 0 (0 [0–84.2]) | 0 (0 [0–45.9]) | 0 (0 [0–52.2]) |
| Alopecia | 3 (33.3 [7.5–70.1]) | 0 (0 [0–84.2]) | 0 (0 [0–45.9]) | 0 (0 [0–52.2]) |
| Maculopapular rash | 2 (22.2 [2.8–60]) | 0 (0 [0–84.2]) | 0 (0 [0–45.9]) | 2 (40 [5.3–85.3]) |
| Acneiform rash | 2 (22.2 [2.8–60]) | 0 (0 [0–84.2]) | 1 (16.7 [0.4–64.1]) | 0 (0 [0–52.2]) |
| Eczema | 0 (0 [0–33.6]) | 0 (0 [0–84.2]) | 1 (16.7 [0.4–64.1]) | 2 (40 [5.3–85.3]) |
| Xerosis | 3 (33.3 [7.5–70.1]) | 1 (50 [1.3–98.7]) | 1 (16.7 [0.4–64.1]) | 1 (20 [0.5–71.6]) |
| Panniculitis-like reactions | 2 (22.2 [2.8–60]) | 0 (0 [0–84.2]) | 2 (33.3 [4.3–77.7]) | 0 (0 [0–52.2]) |
| Keratosis pilaris (KP) | 3 (33.3 [7.5–70.1]) | 0 (0 [0–84.2]) | 1 (16.7 [0.4–64.1]) | 0 (0 [0–52.2]) |
| Warts | 2 (22.2 [2.8–60]) | 0 (0 [0–84.2]) | 1 (16.7 [0.4–64.1]) | 0 (0 [0–52.2]) |
| Palmar-Plantar Erythrodysesthesia or Hand-Foot Syndrome (HFS) | 1 (11.1[0.3–48.2]) | 1 (50 [1.3–98.7]) | 0 (0 [0–45.9]) | 0 (0 [0–52.2]) |