

AperTO - Archivio Istituzionale Open Access dell'Università di Torino

Diode laser ablation of a tracheal osteochondroma in a dog

This is the author's manuscript

Original Citation:

Availability:

This version is available <http://hdl.handle.net/2318/1592598> since 2017-05-15T15:05:29Z

Published version:

DOI:10.1111/jsap.12485

Terms of use:

Open Access

Anyone can freely access the full text of works made available as "Open Access". Works made available under a Creative Commons license can be used according to the terms and conditions of said license. Use of all other works requires consent of the right holder (author or publisher) if not exempted from copyright protection by the applicable law.

(Article begins on next page)

This is the author's final version of the contribution published as:

Bottero, Enrico; Cagnasso, Aurelio; Gianella, Paola. Diode laser ablation of a tracheal osteochondroma in a dog. *JOURNAL OF SMALL ANIMAL PRACTICE*. 57 (7) pp: 382-385.
DOI: 10.1111/jsap.12485

The publisher's version is available at:

<http://doi.wiley.com/10.1111/jsap.12485>

When citing, please refer to the published version.

Link to this full text:

<http://hdl.handle.net/>

Diode laser ablation of a tracheal osteochondroma in a dog

Enrico Bottero, DVM, Aurelio Cagnasso, DVM, Paola Gianella, DVM, PhD,
DACVIM

From the Department of Veterinary Sciences, University of Turin, Largo P. Braccini
2, 10095 Grugliasco (TO), Italy (Cagnasso, Gianella); Poliambulatorio Veterinario
Argentina, Via Levà 58, Arma di Taggia (IM), Italy (Bottero)

No grants or other form of financial support was provided in writing up this case
report. None of the authors have any financial or other conflicts of interest related to
any products used in this study or with other people or organisation that could
inappropriately influence or bias the content of this case report.

Corresponding author: Dr. Gianella Paola

Department of Veterinary Sciences, University of Turin, Largo P. Braccini 2, 10095
Grugliasco (Turin), Italy

Tel.: + 39 011 6709074

paola.gianella@unito.it

A 4-month-old Golden Retriever underwent laryngoscopy/tracheoscopy for severe inspiratory dyspnea. A tracheal mass almost completely obstructing the lumen was noted. Histopathology was consistent with osteochondroma. Successful endoscopic diode laser ablation of the tumour and follow up are described.

Keywords - Canine, Tracheal tumours, Endoscopy, Diode laser

Word count - 1446

Introduction

Primary tracheal tumours are rare in dogs but may include both benign (i.e., osteochondroma) and malignant tumours (i.e., adenocarcinoma, chondrosarcoma, lymphosarcoma, osteosarcoma, plasmacytoma, and squamous cell carcinoma) (Chaffin *et al.* 1998, Weigt *et al.* 2001, Withrow 2001, Fossum 2002, Ramirez *et al.* 2015). Except for osteochondroma (Dubielzig & Dickey 1978, Aron *et al.* 1980, Carlisle *et al.* 1991, Fossum *et al.* 2002, Ramirez *et al.* 2015) and rhabdomyosarcoma (Yanoff *et al.* 1996), they most frequently occur in older animals. Osteochondromas, reportedly the most common (Morrison 1980, Carlisle *et al.* 1991, Ramirez *et al.* 2015), are benign solitary cartilaginous growths that undergo endochondral ossification. The most frequently affected sites are the vertebrae, ribs, and long bones. Lesion growth typically ceases at skeletal maturity but continued growth is suggestive of malignant transformation, which may occur years after the initial diagnosis of osteochondroma (Jacobson & Kirberger 1996, Green *et al.* 1999). Localisation in extraskkeletal sites, including the trachea, has been reported (Dubielzig & Dickey 1978, Troy 1978, Aron *et al.* 1980, Morrison 1980, Ramirez *et al.* 2015). Diagnosis is by thorax and neck radiography, endoscopy or computed tomography (CT), and biopsy of the mass for histopathological examination. Surgery is the treatment of choice in veterinary medicine, while laser ablation has been demonstrated to be curative in benign lesions in human medicine (Dorros & Seeley 1991, Du Rand *et al.* 2011). This case report describes the occurrence of a tracheal osteochondroma successfully treated with diode laser under endoscopic visualisation in a young pure-breed dog.

Case History

A 4-month-old male, intact Golden Retriever was presented for examination because of sudden onset of severe inspiratory dyspnea followed by a single syncopal episode. In the weeks before presentation, cough, exercise intolerance, inspiratory stridor and orthopnea were noted during excitement. Vaccinations were current and monthly heartworm preventative therapy had been given since 2 months of age. Except for an inspiratory stridor and a moderate obstructive breathing pattern, physical examination was otherwise normal. No neurologic deficits, arrhythmia, heart murmur, or pulse abnormalities were detected. Complete blood count (CBC), biochemistry panel, dorsoventral thoracic radiographs, and resting electrocardiogram were all unremarkable. Based on clinical signs, an upper airway obstruction was suspected and the single syncopal episode was considered as possibly secondary to hypoxia rather than cardiac or neurologic in origin. Laryngoscopy/tracheoscopy was performed with the owner's consent. Preanaesthetic sedation was achieved with 0.2 mg/kg butorphanol (Dolorex, Intervet Italia, Milan, Italy) administered intravenously, followed by 5 minutes preoxygenation by way of flow-by oxygen with the breathing circuit immediately before the induction with propofol (Propofol Kabi; Fresenius Kabi Italia, Isola della Scala [VR], Italy). Light general anaesthesia was obtained. Laryngoscopy was performed via an oral approach with the dog in sternal recumbency. A 4.9 mm x 60 cm flexible video-endoscope (EB-270S Fujinon, Saitama, Japan) was used. The images were recorded using a digital video converter (Canopus ADVC110, Grass Valley, Montreal, Quebec, Canada) connected to a FireWire 800-equipped Mac computer (Apple MacBook Pro-Core i7 processor 2.2 GHz 15.4 inch). Laryngeal function appeared to be normal. A hard, smooth mass covered by normal-appearing mucosa, almost completely obstructing the tracheal lumen and arising from the ventral tracheal wall, was noted approximately 2.5 cm below the vocal cords (Fig. 1, left). A small cuffed endotracheal tube was then placed caudally to the mass to ensure oxygen delivery and control ventilation, while anaesthesia was maintained with a constant intravenous infusion of propofol (Propofol Kabi; Fresenius Kabi Italia, Isola della Scala [VR], Italy). A sample for intraoperative

cytologic examination was collected using a transbronchial aspiration needle (NAD-NN6-18-120, Endo-Technik, Solingen, Germany) passed through the working channel (Fig. 1, right). The specimen contained occasional ciliated cells in an osteoid matrix, with occasional, multiple apparently benign mesenchymal cells. Several attempts with a transbronchial biopsy needle (PE1-RUND-18-160 round, fenestrated cups, tapered 1.8 mm-160 cm, Endo-Technik) and rigid biopsy forceps passed alongside the endoscope yielded small samples of normal-appearing mucosa. Again with the owner's consent, bronchoscopic-guided (9.3 mm x 110 cm flexible video-gastroscope, EG-250 WR5, Fujinon) laser ablation of the mass was attempted using a 600 µm diameter, 8 W power, 980 µm wavelength diode laser (Quanta System, Varese, Italy) to obtain adequate biopsy samples and temporary relief of airway obstruction. The laser fibre was inserted into the working channel (2.8 mm) of the video-gastroscope and oriented to direct the laser fibre tip toward the dorsal aspect of the tracheal mass. The laser was discharged in continuous mode until the mass was completely ablated (Fig. 2, left and right). The endoscopic field was intermittently irrigated with sterile saline solution (NaCl 0.9%) to prevent overheating of the normal tracheal tissue surrounding the mass. In addition, intermittent suction (-0.40 Bar) by means of an electric surgical suction pump (Askir C30, Vetefarma, Cuneo) connected to the video-gastroscope was performed to remove smoke, fluids, and small debris from the airways. The total operating time was 50 minutes. At the end of the procedure, an area of approximately 2 cm of brownish scar tissue was visible on the ventral wall of the trachea. During the procedure, the tracheal mass was cut into several smaller portions, some of which were retrieved with the grasping forceps passed alongside the endoscope. Recovery was uneventful. The dog was discharged the next day with a prescription of carprofen (Rimadyl; Zoetis Italia Srl) (2 mg/kg s.i.d. PO the first day, followed by 1 mg/kg SID for 7 days) plus misoprostole (Cytotec; Pharmacia Italia, Milan, Italy) (2 mcg/kg s.i.d. PO for 7 days). Histopathology of the mass was consistent with osteochondroma. At home, other than some episodes of dry cough in the days following discharge, the dog was free of clinical signs both at rest and during excitement. About 2 months later, a second tracheoscopy to inspect the site of laser

ablation revealed normal tracheal appearance and diameter, apart from a small area of brownish scar tissue at the ablation site (Fig. 3). The dog was free of clinical signs at one-year follow-up.

Discussion

Tracheal osteochondroma is rare in dogs. Clinical manifestations include acute onset of dyspnea, as in this case, or a progressive history of upper airway obstruction, including respiratory distress, coughing, and exercise intolerance (Dubielzig & Dickey 1978, Fossum 2002, Ramirez *et al.* 2015). A tracheal mass is easily detected on radiographs as a mass narrowing or obstructing the tracheal lumen. Endoscopy or computed tomography (CT) are useful complementary diagnostic procedures to facilitate biopsy and appraisal of the extent of the mass, or to show anatomical details of the involved region and evaluate extension of the mass, respectively (Roach & Krahwinkel 2009, Wu & Shepard 2013, Acar *et al.* 2015). In the present case, the owner declined radiography and CT of the trachea because of the costs involved; and the tumour was initially missed. Treatment options for tracheal tumours are limited but include radical surgical excision, although this may not always be possible depending on the size and the nature of the mass (Roach & Krahwinkel 2009). Prognosis is excellent when surgical excision is complete, primarily because the trachea can be readily resected and anastomosed (Hough *et al.* 1977, Fossum 2002, Ramirez *et al.* 2015). However, successful treatment of tracheal osteochondromas and leiomyoma have also been reported in dogs without tracheal resection (Troy 1978, Black *et al.* 1981).

In recent years, interventional bronchoscopy has rapidly evolved in human medicine. Laser tumour debulking via flexible bronchoscopy provides immediate relief of symptoms and can be curative in benign lesions (Du Rand *et al.* 2011). In veterinary medicine, the use of diode laser therapy has recently been reported for the treatment of canine epiglottis chondrosarcoma (De Lorenzi *et al.* 2015); to our knowledge, no reports exist concerning tracheal tumour management. In the present case, the procedural guidelines described for veterinary patients were followed (Sullins 2002) and no serious complications were observed during the immediate postoperative period or reported by the owner during the subsequent follow up. While Nd:YAG laser therapy is widely used for airway

tumour management in humans (Du Rand *et al.* 2011), diode lasers are replacing Nd:YAG lasers in veterinary surgery because they are smaller, more efficient and cost-effective, and can cut and vaporise tissue with a minimal thermal effect (Dorros & Seeley 1991, Sullins 2002). A further advantage of this relatively new technology is that it can be guided through a flexible quartz fibre and used through an endoscope, as in the present case (Abitbol & Sataloff 2014), which enhances visibility and permits removal of smoke from airways during the procedure (Sullins 2002). Further study of diode laser efficacy in veterinary tracheal surgery is desirable. Following the successful outcome in this case, this technique may be considered in the treatment for benign tracheal tumours in carefully selected cases.

References

- Abitbol, J. & Sataloff, R. T. (2014) Laryngeal laser surgery. In Surgical Techniques in Otolaryngology – Head and Neck Surgery: Laryngeal Surgery. Ed R. T. Sataloff. Jaypee Brothers Medical Publishers, New Delhi, India. pp 42-43
- Acar, T., Bayraktaroglu, S., Ceylan, N., *et al.* (2015) Computed tomography findings of tracheobronchial system diseases: a pictorial essay. *Japanese Journal of Radiology* **33**, 51-58
- Aron, D. N., Devires, R., & Short, C. E. (1980) Primary Tracheal Chondrosarcoma In A Dog: A Case Report With Description Of Surgical And Anesthetic Techniques. *Journal Of The American Animal Hospital Association* **16**, 31-37
- Black, A. P., Liu, S. & Randolph, J. F. (1981) Primary Tracheal Leiomyoma In A Dog. *Journal Of The American Veterinary Medical Association* **179**, 905-907
- Carlisle, C.H., Biery, D.N., & Thrall, D.E. (1991) Tracheal and laryngeal tumors in the dog and cat: literature review and 13 additional patients. *Veterinary Radiology* **32**, 229–235
- Chaffin, K., Cross, A.R., Allen, S.W., *et al.* (1998) Extramedullary plasmacytoma in the trachea of a dog. *Journal Of The American Veterinary Medical Association* **212**, 1579–1581
- De Lorenzi, D., Bertocello, D. & Dentini, A. (2015) A Dentini. Intraoral diode laser

- epiglottectomy for treatment of epiglottis chondrosarcoma in a dog. *Journal of Small Animal Practice* doi: 10.1111/jsap.12356
- Dubielzig, R.R. & D.L. Dickey (1978) Tracheal osteochondroma in a young dog. *Veterinary Medicine Small Animal Clinician* **73**, 1288-1290
- Du Rand, I.A., Barber, P.V., Goldring, J., *et al.* (2011) British Thoracic Society guideline for advanced diagnostic and therapeutic flexible bronchoscopy in adults. *Thorax* **66**, iii1- iii21
- Dorros, G. & Seeley, D. (1991) Understanding lasers. In: Types of lasers. Mount Kisco (NY), Futura. pp 55-57
- Fossum, T.W. (2002) Laryngeal and tracheal tumors. In: Small Animal Surgery. 2nd edn. Ed T.W. Fossum. Mosby, St Louis, MO, USA. pp 745-748
- Green, E.M., Adams, W.M. & Steinberg, H. (1999) Malignant transformation of solitary spinal osteochondroma in two mature dogs. *Veterinary Radiology Ultrasound* **40**, 634-637
- Hough, J. D., Krahwinkel, D. J., Evans, A. T., *et al.* (1977) Tracheal osteosarcoma in a dog. *Journal of the American Veterinary Medical Association* **170**, 1416-1418
- Jacobson, L.S. & Kirberger, R.M. (1996) Canine multiple cartilaginous exostoses: unusual manifestations and a review of the literature. *Journal of the American Veterinary Medical Association* **32**, 45-51
- Morrison, R.R. (1980) Surgical removal of an intratracheal nodule of ectopic bone and cartilage. *Canadian Veterinary Journal* **21**, 290-291
- Ramirez, G.A., Altimira, J. & Vilafranca, M. (2015) Cartilaginous tumors of the larynx and trachea in the dog: literature review and 10 additional cases (1995-2014). *Veterinary Pathology* pii: 0300985815579997
- Roach, W. & Krahwinkel, D.J. Jr. (2009) Obstructive lesions and traumatic injuries of the canine and feline tracheas. *Compendium of Continuing Education Veterinary*, **31** (2), E6
- Sullins, C.E. (2002) Diode laser and endoscopic laser surgery. *Veterinary Clinic Small Animal Journal* **32**, 639-648

Troy, G.C. (1978) Surgical Removal Of A Tracheal Osteochondroma. *Canine Practice* **5**, 47

Weigt, A.K., McCracken, M.D. & Krahwinkel, D.J. (2001) Extramedullary plasmacytoma in the canine trachea: case report and literature review. *Compendium of Continuing Education for the Practicing Veterinarian* **23**,143-152

Withrow, S.J. (2001) Tumors of the respiratory system. In Small animal clinical oncology. 3rd ed. Eds Withrow, S.J., MacEwen, E.G. WB Saunders Co, Philadelphia. pp 354–377

Wu, C.C. & Shepard, J.A.O. (2013) Tracheal and airway neoplasms. *Seminars in Roentgenology* **48**, 354-364

Yanoff, S.R., Fuentealba, C., Boothe, et al. (1996) Tracheal Defect And Embryonal Rhabdomyosarcoma In A Young Dog. *Canadian Veterinary Journal* **37**, 172-173

Figure legends

Figure 1: Endoscopic view of the cervical trachea before laser ablation. Note the smooth mass covered by normal-appearing mucosa, almost completely obstructing the tracheal lumen and arising from the ventral tracheal wall (left). Transbronchial aspiration needle being used to obtain a sample for intraoperative cytologic examination (right)

Figure 2: Endoscopic view of the cervical trachea before (left) and after (right) laser ablation of the mass. Note the fragments of coagulated neoplastic tissue on the ventral wall of the trachea.

Figure 3: Endoscopic view of the cervical trachea. Note the small brownish focal scar tissue on the ventral wall of the trachea at the ablation site.

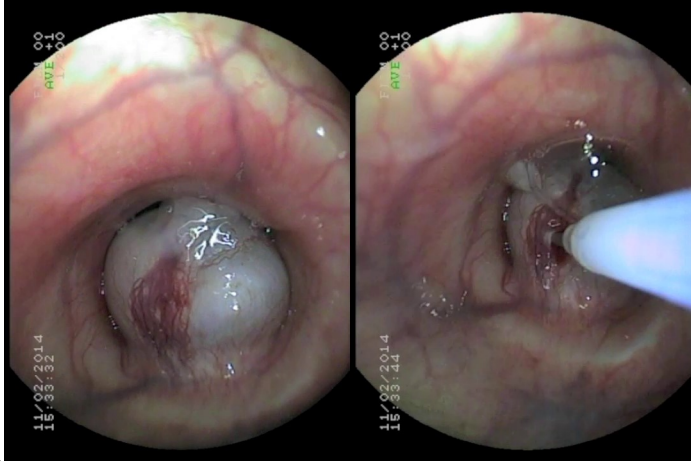


Figure 1

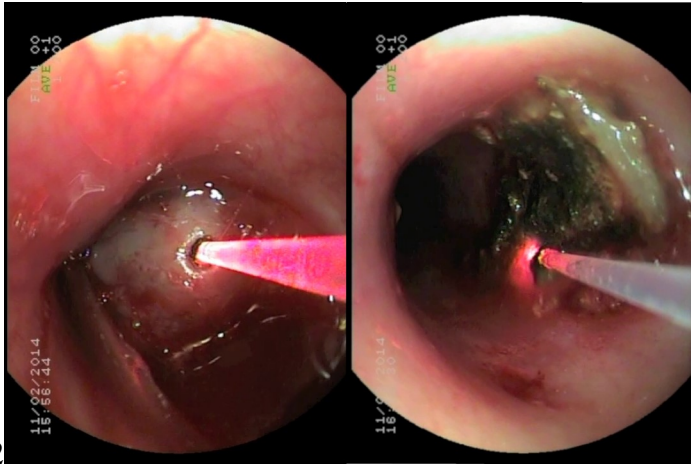


Figure 2

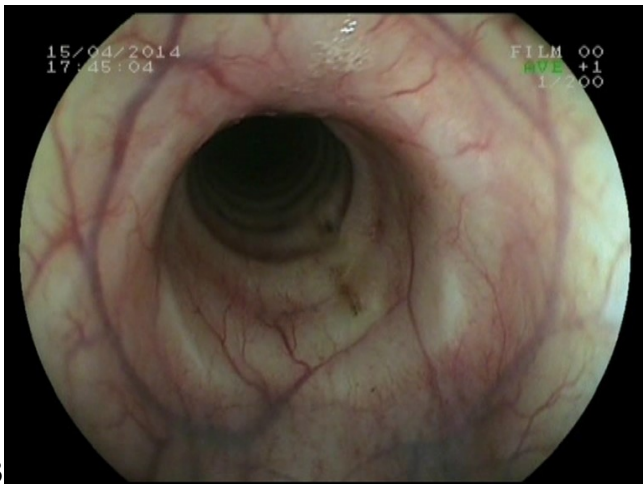


Figure 3