

AperTO - Archivio Istituzionale Open Access dell'Università di Torino

The role of nail-videocapillaroscopy in early diagnosis of scleroderma

This is the author's manuscript

Original Citation:

Availability:

This version is available <http://hdl.handle.net/2318/140388> since 2016-10-20T16:28:03Z

Published version:

DOI:10.1016/j.autrev.2012.11.006

Terms of use:

Open Access

Anyone can freely access the full text of works made available as "Open Access". Works made available under a Creative Commons license can be used according to the terms and conditions of said license. Use of all other works requires consent of the right holder (author or publisher) if not exempted from copyright protection by the applicable law.

(Article begins on next page)

This Accepted Author Manuscript (AAM) is copyrighted and published by Elsevier. It is posted here by agreement between Elsevier and the University of Turin. Changes resulting from the publishing process - such as editing, corrections, structural formatting, and other quality control mechanisms - may not be reflected in this version of the text. The definitive version of the text was subsequently published in AUTOIMMUNITY REVIEWS, 12 (8), 2013, 10.1016/j.autrev.2012.11.006.

You may download, copy and otherwise use the AAM for non-commercial purposes provided that your license is limited by the following restrictions:

- (1) You may use this AAM for non-commercial purposes only under the terms of the CC-BY-NC-ND license.
- (2) The integrity of the work and identification of the author, copyright owner, and publisher must be preserved in any copy.
- (3) You must attribute this AAM in the following format: Creative Commons BY-NC-ND license (<http://creativecommons.org/licenses/by-nc-nd/4.0/deed.en>), 10.1016/j.autrev.2012.11.006

The publisher's version is available at:

<http://linkinghub.elsevier.com/retrieve/pii/S1568997212002856>

When citing, please refer to the published version.

Link to this full text:

<http://hdl.handle.net/2318/140388>

The role of nail-videocapillaroscopy in early diagnosis of scleroderma

Daniela Rossi, Alessandra Russo, Erika Manna, Giovanni Binello, Simone Baldovino, Savino Sciascia, Dario Roccatello

Department of Rare, Immunologic, Hematologic Diseases and Transfusion Medicine, Research Center of Immunopathology and Rare Diseases (CMID), Giovanni Bosco Hospital and University of Turin, Italy

Abstract

Raynaud's phenomenon (RP) is a clinical sign of precocious abnormal microcirculation and can be considered a major risk factor for the development of connective tissue disease, especially systemic sclerosis (SSc). Nailfold videocapillaroscopy is the most valuable tool for the early diagnosis of SSc and related disorders. It allows classification of capillary abnormalities. Scoring capillaroscopic alterations, which change significantly during patient follow-up, should be systematically used in order to monitor microangiopathy. The effectiveness of the nailfold videocapillaroscopy in allowing an early diagnosis of SSc and monitoring the progression of the disease, and its predictive value of clinical complications make it a powerful tool for clinical evaluation and research.

Keywords

Systemic sclerosis; Nailfold videocapillaroscopy; Early diagnosis; Microangiopathy

1. Introduction

Although the structural vascular disease in scleroderma is patent, the nature of endothelial injury is still elusive, yet markers of endothelial activation and injury continue to be proposed. However, the assessment of microvascular function by laboratory methods is not specific or sensitive [1].

Despite a large prevalence in the general population [2], Raynaud's phenomenon remains a typical manifestation of vascular involvement in scleroderma. It is characterized by intense vasospasm of the digital arteries under cold exposure or emotional stress, which leads to characteristic color changes in the skin of the fingers, which is the expression of the imbalance between vasoconstrictor and vasodilator factors [3]. It may be primary or secondary to an underlying condition, especially immune-mediated diseases [4]. Physical examination, nailfold capillaroscopy and immunological tests can distinguish primary from secondary forms.

Capillaroscopy is an imaging technique, which is used in medicine since 1823, when Purkinje described skin capillaries by observing the nail-bed with a magnifying glass. One century later (1911), it was discovered that, using a drop of immersion oil, capillaries became visible for examination by microscope. More recently, Maricq and Le Roy described the specific capillaroscopic pattern in systemic sclerosis.

Nowadays, thanks to its greater magnification (from $50\times$ to $1000\times$), the digital videocapillaroscopy, which consists of a microscope assembled with a digital videocamera, represents the gold standard for assessing or measuring capillaroscopic parameters. Furthermore, nailfold capillaroscopy is a non-invasive, inexpensive, easy to repeat imaging technique, which is of considerable importance for the evaluation of microcirculation in vivo [5].

2. Capillaroscopic technique

In order to evaluate capillaries a drop of cedar oil has to be placed on the finger nailfold. A precise morphologic evaluation may be obtained by examining the fourth and the fifth finger of both hands

due to the high transparency of the skin in these areas [5] and [6]. However, all fingers from second to fifth should be examined, since early capillary alterations may be occasionally present in only a few digits. Each patient should stay inside the examination room, at a temperature of 23–25 °C, for 10–15 min before the nailfold is examined.

The images are generated by lens providing a magnification $\times 200$, and a charged-coupled device (CCD) camera giving high-resolution images (752×582 pixels). Only the capillaries in the distal row are observed. A 1 mm grid is used to quantify capillary density and width. Usually 4 fingers on each hand are examined, and at least 8 photo-micrographs are taken of each patient [7].

The following parameters are routinely evaluated: capillary distribution and width, presence of dilated and giant capillaries, loss of capillaries, presence of hemorrhages and signs of neoangiogenesis (meandering and ramified capillaries) [8], [9], [10], [11], [12], [13], [14], [15] and [16]. Generally speaking, a capillaroscopic feature is considered an abnormal finding if changes are observed in at least two fingers [5] and [6].

3. Clinical implications

Capillaroscopy is of crucial importance for the differentiation of primary and secondary RP in rheumatic diseases, and also in differentiation between different forms of connective tissue diseases as well as for their early diagnosis [17].

The detection of abnormal capillaroscopic patterns has high positive predictive value for the development of systemic rheumatic disease [18].

The most specific pattern is the so called “scleroderma pattern”, which is characterized by the presence of giant capillaries, hemorrhages, avascular areas and neoangiogenesis. It is found in more than 90% of patients with overt SSc. Similar changes, called “scleroderma-like patterns”, are found in patients with dermatomyositis, mixed connective tissue disease, undifferentiated connective tissue disease and overlap syndromes [6], [9], [10] and [16]. Absence of abnormal capillaroscopic findings can be regarded as a diagnostic criterion for primary RP.

3.1. Normal pattern

In normal conditions, the microvascular pattern is characterized by a regular array of microvessels with large intra/interindividual variability [19]. Usually, capillaries show a perpendicular disposition to the nailfold edge, with a capillary diameter lower than 20 μm , and at least 9 capillaries per linear millimeter are present.

3.2. Primary RP

The suggested criteria for primary RP include symmetric attacks, absence of tissue necrosis or ulceration or gangrene, absence of a secondary cause, negative tests for antinuclear antibodies and normal erythrocyte sedimentation rate. Nailfold capillaries are usually normal-shaped and no specific alterations are present [20].

A diagnosis of primary RP means that no underlying disease has yet been identified, but it is difficult to predict if and when it may become secondary RP [21], [22], [23] and [24]. Therefore, a follow-up nailfold capillaroscopic analysis is recommended to be performed every 6 months [9] and [10].

Women are 4–20 times more likely than men to develop primary RP. A presentation with symmetrical vasospastic attacks and a benign course without skin lesions is typical [25] and [26]. The onset of the disease is usually at puberty and is more frequent in certain families [5].

3.3. Secondary RP

Secondary RP includes a wide spectrum of diseases ranging from peripheral artery disorders and connective tissue diseases (CTDs) to paraneoplastic syndromes [27] and [28]. Onset age, which is older than primary RP, clinical signs of autoimmune disease, trophic alterations of the fingers [29] and [30], positive autoantibodies [5] and abnormal capillaroscopic findings are suggestive features of secondary RP.

As calculated by meta-analysis, a secondary disorder develops in 12.6% of patients with presumed primary RP. Other studies reported that 15–20% of patients initially diagnosed as affected by primary RP transitioned to secondary RP over a mean follow-up of 2 years [31] and [32].

Notably, RP is the first manifestation in about 90% of patients with SSc [24], [33], [34], [35] and [36].

The microvascular damage in SSc [37] is mainly characterized by increasing structural alterations of the capillaries with progressive decrease in their density [38]. Blood flow is also altered, with an average slowing of flow and increased periods of stasis [19]. Nagy et al. found specific abnormalities in 87.5% of patients with diffuse and in 61.6% with limited form of SSc [5] by evaluating advanced capillary changes. Conversely, by assessing both early and advanced capillary changes by videocapillaroscopy, more than 98% of SSc patients showed a scleroderma pattern of microangiopathy (early, active or late) [39].

Several studies have graded the morphological aspects of the vascular damage in patients with SSc, as assessed by nailfold capillaroscopy [19]. Maricq et al. [15] described two types of capillaroscopic changes in SSc. Extensive, confluent avascular areas and neovascularization with a variable capillaroscopic pattern have been thought to reflect activity and progression of disease (so called “active” capillaroscopic pattern). In contrast, the presence of giant capillary loops with minimal loss of capillaries was regarded as typical for the forms of the disease with a lower activity (so called “slow” capillaroscopic pattern) [5], [15] and [40]. These patterns are thought to represent two different stages of nailfold microangiopathy, even if the factors conditioning timing of transition are not known.

In a more recent study, microvascular alterations as detected in SSc by nailfold videocapillaroscopy have been re-classified in three pattern, namely “early”, “active” and “late” [41].

The “early” pattern refers to the presence of a few giant capillaries and hemorrhages along with normal-shaped capillaries and relatively well-preserved capillary distribution, without loss of capillaries (Fig. 1). The “active” pattern is mainly characterized by the detection of several giant capillaries along with mild loss of capillaries [19] (Fig. 2). The “late” pattern is characterized by loss of capillaries with extensive avascular areas, ramified capillaries and disorganization of the vascular array [5] (Fig. 3).

In order to quantify the microvascular changes, a semiquantitative rating scale was recently adopted to score each capillary abnormality (0, no changes; 1, < 33% of capillary alterations/reduction; 2, 33–66% of capillary alterations/reductions; and 3, > 66% of capillary alteration/reduction per linear millimeter) [42]. The mean score for each capillaroscopic parameter was calculated on four consecutive fields (each of 1 linear millimeter) in the middle of the nailfold in each digit and the

average score from the eight digits, added together, was divided by eight. The score for each capillaroscopic parameter was found to differ in the follow-up, even when a variation in the microangiopathy pattern was not obvious. Score for irregularly enlarged capillaries, capillaries loss, disorganization of the microvascular array and capillary ramifications were found to have increased, while scores for giant capillaries and hemorrhages decreased during follow-up. A 4% variability was found in the score assessment by the different evaluators [43], [44] and [45].

As regard to other CTD patients presenting with secondary RP, since more than 20% of UCTD patients have been reported to develop SSc [46], it has been suggested that using videocapillaroscopy might identify those patients who are candidates to develop SSc. In SLE, both enlarged capillaries [47] and capillary loss [48] may occasionally be present. SLE patients with capillary loss may also exhibit scleroderma-related symptoms including interstitial lung disease. Patients with MCTD, characterized by the simultaneous presence of symptoms characteristic of SLE, myositis and scleroderma, in conjunction with high titre of anti U1 RNP antibody can also present with scleroderma capillary pattern and bushy capillary loops [49]. In Sjogren's syndrome the "scleroderma pattern" can be detected especially in patients with RP and anticentromer antibodies. A number of morphological abnormalities have been also observed in mixed cryoglobulinemia. These alterations were reported to be often clustered in a characteristic pattern of abnormally oriented and short capillaries with neoangiogenetic phenomena, and were more frequently detected in patients with glomerular involvement [19] and [50].

Of note, in CTD patients, RP has been proposed to be the expression of a systemic disorder in which spasms were not restricted to peripheral arteries, but also involved the coronary vessels, arterioles of lung, brain, retina and gastrointestinal tract [5].

4. Concluding remarks

SSc is a rare multisystemic connective tissue disease characterized by microvascular damage [51], fibrosis of the skin [29] and internal organs [52], [53], [54] and [55], and specific immunologic abnormalities [56]. The clinical recognizable disease is classified on the basis of extent of skin and internal organ involvement [53]. The clinical expression and the course of the disease may be associated with severe morbidity and mortality. Moreover, to date, none of the treatments tested in randomized controlled trials have been able to halt the natural progression of the disease. Nail fold videocapillaroscopy is the most valuable tool for the early diagnosis of SSc and related disorders [57]. Scoring the capillaroscopic patterns, which changes significantly during the follow-up of these patients, should be systematically employed in order to quantify microangiopathy [44].

Take-home messages

- The Raynaud's phenomenon is a clinical sign of precocious abnormal microcirculation and can be considered a risk factor for the development of connective tissue disease, especially SSc.
- The nail fold videocapillaroscopy can be used for the early detection of microvascular abnormalities that characterize the secondary RP, and these abnormalities are quantifiable.
- The effectiveness of the nail fold videocapillaroscopy in the early diagnosis of SSc, its predictive value of clinical complications and its potential in monitoring the progression of the disease make it a critical non-invasive tool for clinicians and researchers.

References

- [1] M.B. Kahaleh Raynaud's phenomenon and vascular disease in scleroderma *Curr Opin Rheumatol*, 6 (6) (Nov 1994), pp. 621–627

- [2] H.R. Maricq, M.C. Weinrich, J.E. Keil, E.A. Smith, F.E. Harper, A.I. Nussbaum, et al. Prevalence of scleroderma spectrum disorders in the general population of South Carolina *Arthritis Rheum*, 32 (1989), pp. 998–1006
- [3] P. Cipriani, A. Marrelli, V. Liakouli, P. Di Benedetto, R. Giacomelli Cellular players in angiogenesis during the course of systemic sclerosis *Autoimmun Rev*, 10 (10) (Aug 2011), pp. 641–646
- [4] C. Defendenti, F. Atzeni, M.F. Spina, S. Grosso, A. Cereda, G. Guercilena, et al. Clinical and laboratory aspects of Ro/SSA-52 autoantibodies *Autoimmun Rev*, 10 (3) (Jan 2011), pp. 150–154
- [5] Sevdalina Nikolova Lambova, Ulf Müller-Ladner. The role of capillaroscopy in differentiation of primary and secondary Raynaud's phenomenon in rheumatic diseases: a review of the literature and two case reports *Rheumatol Int*, 29 (2009), pp. 1263–1271
- [6] R. Bergman, L. Sharony, D. Schapira, M.A. Nahir, A. Balbir-Gurman The handheld dermatoscope as a nail-foiled capillaroscopic instrument *Arch Dermatol*, 139 (2003), pp. 1027–1030
- [7] P. Formosa Nailfold capillaroscopy techniques *J Rheumatol*, 23 (2009), pp. 37–429
- [8] H.R. Maricq, E.C. LeRoy, W.A. D'Angelo, T.A. Medsger Jr., G.P. Rodnan, G.C. Sharp, et al. Diagnostic potential of in vivo capillary microscopy in scleroderma and related disorders *Arthritis Rheum*, 23 (2) (1980), pp. 183–189
- [9] M. Cutolo, W. Grassi, M. Matucci Cerinic Raynaud's phenomenon and the role of capillaroscopy *Arthritis Rheum*, 48 (11) (2003), pp. 3023–3030
- [10] M. Cutolo, C. Pizzorni, A. Sulli Capillaroscopy *Best Pract Res Clin Rheumatol*, 19 (3) (2005), pp. 437–452
- [11] M. Cutolo, A. Sulli, M.E. Secchi, M. Olivieri, C. Pizzorni The contribution of capillaroscopy to the differential diagnosis of connective autoimmune diseases. *Best Pract Res Clin Rheumatol*, 21 (6) (2007), pp. 1093–1108
- [12] Y. Kabasakal, D.M. Elvins, E.F. Ring, N.J. McHugh. Quantitative nailfold capillaroscopy findings in a population with connective tissue disease and in normal healthy controls *Ann Rheum Dis*, 55 (1996), pp. 507–512
- [13] P. Lee, F.Y. Leung, C. Alderdice, S.K. Armstrong. Nailfold capillary microscopy in the connective tissue diseases: a semiquantitative assessment *J Rheumatol*, 10 (6) (1983), pp. 930–938
- [14] F. LeVord, J.C.W. Edwards Nailfold capillary microscopy in connective tissue disease: a quantitative morphological analysis *Ann Rheum Dis*, 45 (1986), pp. 741–749
- [15] H.R. Maricq, F.E. Harper, M.M. Khan, E.M. Tan, E.C. LeRoy Microvascular abnormalities as possible predictors of disease subsets in Raynaud phenomenon and early connective tissue disease *Clin Exp Rheumatol*, 1 (3) (1983), pp. 195–205

- [16] H.R. Maricq. Comparison of quantitative and semiquantitative estimates of nailfold capillary abnormalities in scleroderma spectrum disorders *Microvasc Res*, 32 (2) (1986), pp. 271–276
- [17] M. Cutolo, C. Pizzorni, M. Meroni, G. Zampogna, C. Ferrone, E. Alessandri, et al. The role of nailfold videocapillaroscopy in Raynaud's phenomenon monitoring and early diagnosis of systemic sclerosis *Reumatismo*, 62 (4) (2010), pp. 237–247
- [18] G. Gitzemmann. Predictive value of nailfold capillaroscopy in patients with Raynaud phenomenon. *Clin Rheumatol*, 25 (2006), pp. 153–158
- [19] M. Cutolo, A. Sulli, M.E. Secchi, S. Paolino, C. Pizzorni. Nailfold capillaroscopy is useful for the diagnosis and follow-up of autoimmune rheumatic disease. A future tool for the analysis of microvascular heart involvement? *Rheumatology*, 45 (2006), pp. iv43–iv46
- [20] M. Cutolo, C. Pizzorni, A. Sulli. Nailfold video-capillaroscopy in systemic sclerosis *Rheumatology*, 63 (2004), pp. 457–462
- [21] M. Luggen, L. Belhorn, T. Evans, O. Fitzgerald, G. Spencer-Green. The evolution of Raynaud's phenomenon: a longterm prospective study *J Rheumatol*, 22 (1995), pp. 2226–2232
- [22] A.L. Herrick. The pathogenesis, diagnosis and treatment of Raynaud phenomenon *Nat Rev Rheumatol*, 8 (8) (Aug 2012), pp. 469–479
- [23] O. Fitzgerald, E.V. Hess, G.T. O'Connor, G. Spencer-Green. Prospective study of the evolution of Raynaud's phenomenon *Am J Med*, 84 (1988), pp. 718–726
- [24] F. Ingegnoli, P. Boracchi, R. Gualtierotti, C. Lubatti. Prognostic model based on nailfold capillaroscopy for identifying Raynaud's phenomenon patients at high risk for the development of a scleroderma spectrum disorder PRINCE (prognostic index for nailfold capillaroscopic examination) *Arthritis Rheum*, 58 (7) (July 2008), pp. 2174–2182
- [25] M. Ho, J.J.F. Belch. Raynaud's phenomenon: state of the art *Scand J Rheumatol*, 27 (1998), pp. 319–322
- [26] A.O. Steven. Raynaud's phenomenon. J.B. Sterling (Ed.), *Secrets of rheumatology*, Binom, Moscow (2001), pp. 614–619
- [27] E. Szekanecz, S. Szamosi, A. Horváth, A. Németh, B. Juhász, J. Szántó, et al. Malignancies associated with systemic sclerosis *Autoimmun Rev*, 11 (12) (Oct 2012), pp. 852–855
- [28] V. Racanelli, M. Prete, C. Minoia, E. Favoino, F. Perosa. Rheumatic disorders as paraneoplastic syndromes *Autoimmun Rev*, 7 (5) (May 2008), pp. 352–358
- [29] F. Galluccio, M. Matucci-Cerinic. Two faces of the same coin: Raynaud phenomenon and digital ulcers in systemic sclerosis *Autoimmun Rev*, 10 (5) (Mar 2011), pp. 241–243
- [30] L. Chung, D. Fiorentino. Digital ulcers in patients with systemic sclerosis *Autoimmun Rev*, 5 (2) (Feb 2006), pp. 125–128

- [31] M. Hirschl, K. Hirschl, M. Lenz, R. Katzenschlager, H.P. Hutter, M. Kundi Transition from primary Raynaud's phenomenon to secondary Raynaud's phenomenon identified by diagnosis of an associated disease: results of ten years of prospective surveillance *Arthritis Rheum*, 54 (6) (2006), pp. 1974–1981
- [32] M. Cutolo, C. Pizzorni, A. Sulli Identification of transition from primary Raynaud's phenomenon to secondary Raynaud's phenomenon by nailfold videocapillaroscopy: comment on the article by Hirschl et al *Arthritis Rheum*, 56 (6) (2007), pp. 2102–2103
- [33] G. Spencer-Green Outcomes in primary Raynaud phenomenon: a meta-analysis of the frequency, rates, and predictors of transition to secondary diseases *Arch Intern Med*, 158 (1998), pp. 595–600
- [34] M. Hudson, M.J. Fritzler, M. Baron Systemic sclerosis: establishing diagnostic criteria *Medicine (Baltimore)*, 89 (3) (May 2010), pp. 159–165
- [35] C.G. Kallenberg Early detection of connective tissue disease in patients with Raynaud's phenomenon *Rheum Dis Clin North Am*, 16 (1990), pp. 11–30
- [36] H.R. Maricq, P.H. Carpentier, M.C. Weinrich, J.E. Keil, Y. Palesch, C. Biro, et al. Geographic variation in the prevalence of Raynaud's phenomenon: a 5 region comparison *J Rheumatol*, 24 (1997), pp. 879–889
- [37] C. Chighizola, Y. Shoenfeld, P.L. Meroni Systemic sclerosis. Introduction *Autoimmun Rev*, 10 (5) (Mar 2011), pp. 239–240
- [38] P.H. Carpentier, H.R. Maricq Microvasculature in systemic sclerosis *Rheum Dis Clin North Am*, 16 (1990), pp. 75–91
- [39] M. Cutolo, A. Sulli, V. Smith Assessing microvascular changes in systemic sclerosis diagnosis and management *Nat Rev Rheumatol*, 6 (2010), pp. 578–587
- [40] M. Colaci, D. Giuggioli, M. Sebastiani, A. Manfredi, C. Vacchi, P. Spagnolo, et al. Lung cancer in scleroderma: results from an Italian Rheumatologic Centre and review of the literature *Autoimmun Rev* (Jun 25 2012)
- [41] M. Cutolo, C. Pizzorni, M. Tuccio, A. Burrioni, C. Craviotto, M. Basso, et al. Nailfold capillaroscopy patterns and serum autoantibodies in systemic sclerosis *Rheumatology*, 43 (2004), pp. 719–726
- [42] A. Sulli, M.E. Secchi, C. Pizzorni, M. Tutolo Scoring the nailfold microvascular changes during the capillaroscopic analysis in systemic sclerosis patients *Ann Rheum Dis*, 67 (6) (Jun 2008), pp. 885–887
- [43] M. Cutolo, C. Pizzorni, M.E. Secchi, A. Sulli Capillaroscopy *Best Pract Res Clin Rheumatol*, 22 (6) (2008), pp. 1093–1108
- [44] A. Sulli, M.E. Secchi, C. Pizzorni, M. Tutolo Scoring the nailfold microvascular changes during the capillaroscopic analysis in systemic sclerosis patients *Ann Rheum Dis*, 67 (2008), pp. 885–887

- [45] A. Sulli, C. Pizzorni, V. Smith, G. Zampogna, F. Ravera, M. Tutolo Timing of transition between capillaroscopic patterns in systemic sclerosis *Arthritis Rheum*, 64 (2012), pp. 821–825
- [46] P. Priollet, M. Vayssairat, E. Housset How to classify Raynaud's phenomenon. Long-term follow-up study of 73 cases *Am J Med*, 83 (3) (1987), pp. 494–498
- [47] V. Riccieri, A. Spadaro, F. Ceccarelli, R. Scrivo, V. Germano, G. Valesini Nailfold capillaroscopy changes in systemic lupus erythematosus: correlations with disease activity and autoantibody profile *Lupus*, 14 (7) (2005), pp. 521–525
- [48] M. Pallis, N. Hopkinson, R. Powell Nailfold capillary density as a possible indicator of pulmonary capillary loss in systemic lupus erythematosus but not in mixed connective tissue disease *Rheumatology*, 18 (10) (1991), pp. 1532–1536
- [49] F. Granier, M. Vayssairat, P. Priollet, E. Housset Nailfold capillary microscopy in mixed connective tissue disease. Comparison with systemic sclerosis and systemic lupus erythematosus *Arthritis Rheum*, 29 (2) (1986), pp. 189–195
- [50] D. Rossi, M. Mansouri, S. Baldovino, C. Naretto, M. Alpa, L.M. Sena, et al. Nail fold videocapillaroscopy in mixed cryoglobulinemia *Nephrol Dial Transplant*, 19 (2004), pp. 2245–2249
- [51] S. Guiducci, R. Giacomelli, M.M. Cerinic Vascular complications of scleroderma. *Autoimmun Rev*, 6 (8) (Sep 2007), pp. 520–523
- [52] G. Bussone, L. Mouthon Interstitial lung disease in systemic sclerosis *Autoimmun Rev*, 10 (5) (Mar 2011), pp. 248–255
- [53] I. Almeida, R. Faria, P. Vita, C. Vasconcelos Systemic sclerosis refractory disease: from the skin to the heart *Autoimmun Rev*, 10 (11) (Sep 2011), pp. 693–701
- [54] K.P. Tiev, J. Cabane Digestive tract involvement in systemic sclerosis *Autoimmun Rev*, 11 (1) (Nov 2011), pp. 68–73 [Epub 2010 Jun 22]
- [55] S. Lambova, U. Müller-Ladner Pulmonary arterial hypertension in systemic sclerosis *Autoimmun Rev*, 9 (11) (Sep 2010), pp. 761–770
- [56] P. Dieudé, C. Boileau, Y. Allanore Immunogenetics of systemic sclerosis *Autoimmun Rev*, 10 (5) (Mar 2011), pp. 282–290
- [57] W. Grassi, P. Del Medico, F. Izzo, C. Cervini Microvascular Involvement in systemic sclerosis: capillaroscopic findings *Semin Arthritis Rheum*, 30 (6) (June 2001), pp. 397–402

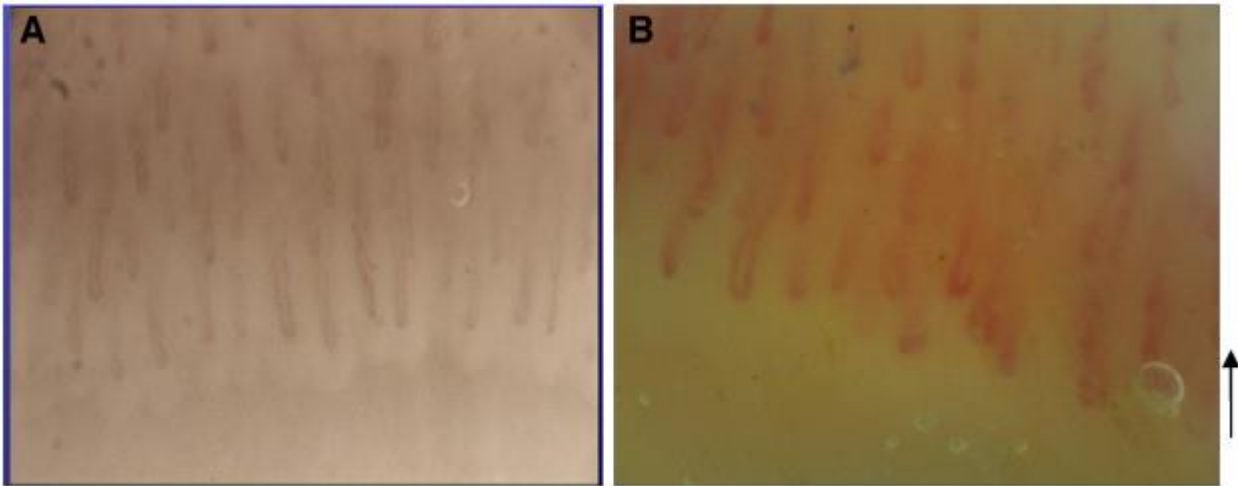


Fig. 1. A. Normal nailfold capillaroscopic pattern showing regular disposition of the capillary loops along the nail bed. B. Scleroderma pattern early. The arrow indicates a single giant capillary.

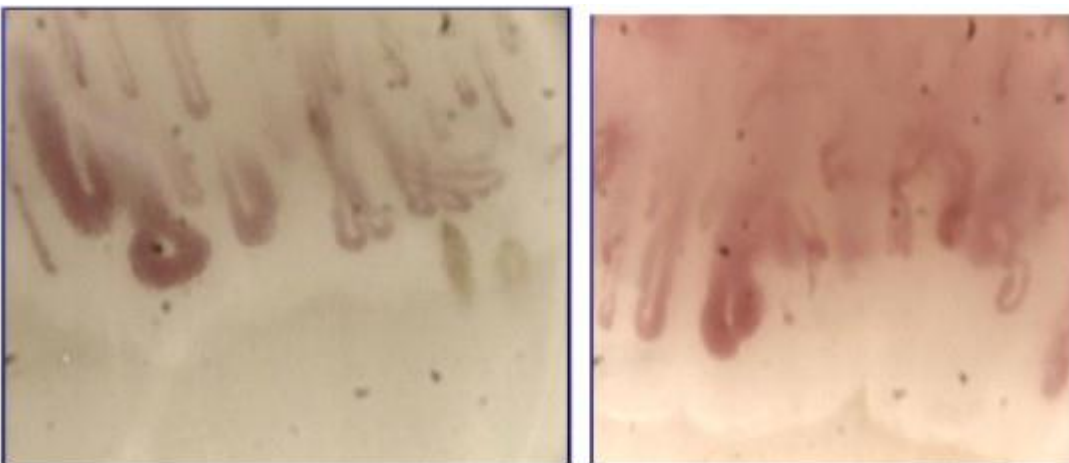


Fig. 2. Scleroderma pattern active. Typical giant capillary of the nailfold.

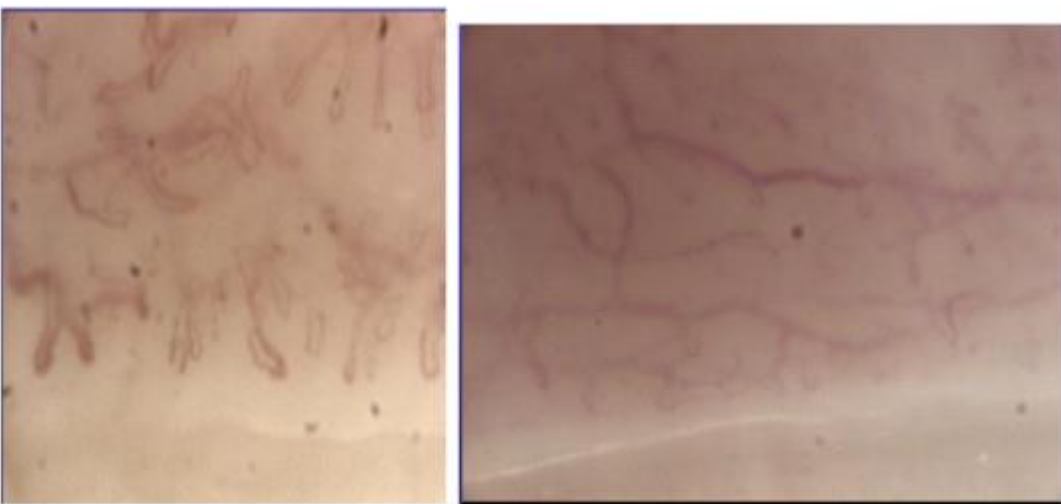

Fig. 3. Scleroderma pattern *late*. Capillary loss, fibrosis and intensive angiogenesis.