

AperTO - Archivio Istituzionale Open Access dell'Università di Torino

Transanal endoscopic microsurgery for giant circumferential rectal adenomas

This is the author's manuscript

Original Citation:

Availability:

This version is available <http://hdl.handle.net/2318/1600713> since 2016-10-11T15:20:32Z

Published version:

DOI:10.1111/codi.13279

Terms of use:

Open Access

Anyone can freely access the full text of works made available as "Open Access". Works made available under a Creative Commons license can be used according to the terms and conditions of said license. Use of all other works requires consent of the right holder (author or publisher) if not exempted from copyright protection by the applicable law.

(Article begins on next page)

This is the author's final version of the contribution published as:

Arezzo, Alberto; Arolfo, Simone; Allaix, Marco Ettore; Bullano, Alberto; Miegge, Alice; Marola, Silvia; Morino, Mario. Transanal endoscopic microsurgery for giant circumferential rectal adenomas. *COLORECTAL DISEASE*. 18 (9) pp: 897-902.
DOI: 10.1111/codi.13279

The publisher's version is available at:

<http://doi.wiley.com/10.1111/codi.13279>

When citing, please refer to the published version.

Link to this full text:

<http://hdl.handle.net/>

Transanal endoscopic microsurgery for giant circumferential rectal adenomas

Arezzo A¹, Arolfo S¹, Allaix ME¹, Bullano A¹, Miegge A¹, Marola S¹, Morino M¹.

¹Department of Surgical Sciences, University of Torino, Torino, Italy.

Abstract

Aim

Transanal endoscopic microsurgery (TEM) was originally invented by Buess *et al.* (*Chirurg*, 1984, **55**, 677–80) for the treatment of infraperitoneal rectal adenomas. Its indications have progressively expanded to include larger and more advanced lesions. The aim of the study was to report the results of TEM used for the treatment of circumferential rectal lesions.

Method

We retrospectively reviewed the medical records of 17 consecutive patients [median age 69 (32–89) years; nine men] who underwent TEM for a circumferential rectal lesion in our department between September 2010 and January 2015.

Results

The median distance from the anal verge was 4 (3–11) cm, the median longitudinal extent was 7 (3–10) cm and the median surface area was 75 (40–255) cm². An end-to-end anastomosis without proximal bowel mobilization was completed endoscopically in all cases. The median operating time was 120 (40–240) min. Persistent, endoscopically uncontrollable endoluminal bleeding in one patient was successfully treated with a second TEM procedure. One patient underwent preoperative radiotherapy for adenocarcinoma detected at the preoperative assessment. Surgical histology showed a pT3 cancer in one patient who refused further surgery, a pT2 cancer in two who subsequently underwent abdominoperineal resection, a pT1 cancer in four and a ypT0 in one patient. All are at present free of disease. No patients developed faecal incontinence or urinary or sexual dysfunction. Four patients required endoscopic balloon dilatation for stenosis.

Conclusion

Transanal endoscopic microsurgery is a feasible and safe technique for large circumferential lesions with a satisfactory outcome. Preoperative staging may be inaccurate.

What does this paper add to the literature?

This is the largest series on the specific and disputed indication of transanal endoscopic microsurgery for circumferential rectal adenomas. Transanal endoscopic microsurgery proved a relatively simple and safe technique, with a satisfactory postoperative outcome for these tumours. Preoperative identification of malignant invasion was inaccurate when compared.

Introduction

Originally conceived over 30 years ago for the treatment of large sessile extraperitoneal rectal adenomas, the indications for transanal endoscopic microsurgery (TEM) have since gradually expanded [1]. Initially, it proved curative for low-risk rectal cancers, often discovered postoperatively on histopathological examination of the resected specimen of a preoperatively assessed benign lesion [2] or later in the palliative treatment of advanced invasive cancers [3, 4]. More recently, TEM has been proposed as a complementary technique in combination with an abdominal approach for sphincter-sparing treatment of invasive low rectal cancer [5].

Transanal endoscopic microsurgery is still considered technically difficult because of the dexterity needed during resection and particularly for suturing the rectal wall defect, which requires consistent training before the technique can be mastered. Many centres perform TEM for a mucosectomy or a partial wall resection, avoiding the risk of perforation or abscess or leakage associated with full-thickness rectal wall excision.

Transanal excision of circumferential adenomas of the rectum is a technically complex procedure. In their description of the original technique, Buess *et al.* stressed the importance of maintaining downward orientation of the lesion to be resected with respect to the surgical field. Their novel method relied on the use of especially designed curved instruments to facilitate tissue grasping and manipulation. Moreover, it also required particular attention paid to positioning the patient, supine or prone or lateral depending on the preoperative assessment by rigid rectoscopy [2]. Owing to the surgical constraints imposed by circumferential lesions in the rectum, the patient is rotated during surgery on dissection of the rectal wall and the defect is sutured upwards along its circumference within the surgical field. In order to verify the feasibility and safety of the technique, we reviewed the medical records of patients who underwent TEM for circumferential lesions of the rectum. We also discuss factors that might influence the outcome.

Method

Preoperative assessment consisted of rigid rectoscopy with biopsy, complete colonoscopy, endoscopic ultrasound and MRI. The criteria for local excision were the same as those used for noncircumferential lesions [3, 4]. The Transanal Endoscopic Operation® system (TEO; Karl Storz, Tuttlingen, Germany) was used in all cases. The TEO instrumentarium includes a 7 or 15 cm rectal tube, 4 cm in diameter, with three working channels (10, 5 and 5 mm) for dedicated or conventional laparoscopic instruments, plus a 5 mm channel dedicated for a 30° two-dimensional optic. The rectoscope is anchored to the operating table with a retainer arm consisting of three joints and a single screw. The system is used in combination with a standard laparoscopic camera and instruments. Camera imaging is projected on a screen and insufflation is obtained with a conventional CO₂ thermo-insufflator connected to the rectoscope via a Luer-lock connector. The particular shape of the tip of the rectoscope allows tissue manipulation and suturing of the rectal wall on a 360° surface, minimizing the time needed to reposition the patient on the operating table. Neoplasms were defined as circumferential if more than three-quarters of the rectal circumference was involved, for which circumferential 360° proximal and distal incision of the rectal wall and an end-to-end anastomosis were planned. As a guide, an Indian ink tattoo was placed posteriorly by rigid rectoscopy about 1 cm above the proximal margin of the lesion.

Patients were instructed to follow a low-fibre diet the week before the operation; preoperative bowel preparation was performed 2 h before surgery; intravenous antibiotics (second-generation cephalosporin and metronidazole) were administered before introduction of the rectoscope and continued for 24 h at 12-h intervals. Deep venous thrombosis prophylaxis was administered. *En bloc* full-thickness rectal wall excision was performed, distally sparing the anal sphincters by dissecting in the submucosal layer, when necessary, or removing a complete cylindrical portion of the rectal wall to reveal the perirectal fat in all other cases. The cylinder was removed *en bloc*

(Video S1). First, the distal margin was dissected circumferentially (Fig. 1); then the perirectal fat was tunnelled until the proximal margin (Fig. 2), which had been tattooed with Indian ink preoperatively in order to recognize it from the extraluminal side. The rectal wall was then incised from the outside, while verifying its correct placement on the healthy mucosa, at least 5 mm from the upper margin of the adenoma (Fig. 3). Another 360° incision was placed with clear margins. Finally, the cylinder was dissected circumferentially within the perirectal fat layer.

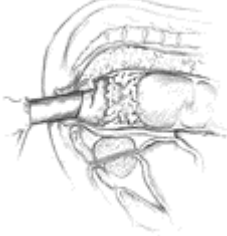

Figure 1. The distal margin is dissected circumferentially 360°.

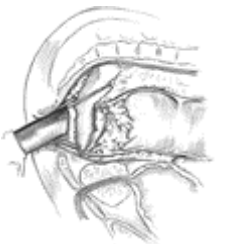


Figure 2. The perirectal fat is tunnelled to the proximal margin, which has been tattooed preoperatively with Indian ink in order to recognize it from the extraluminal side.

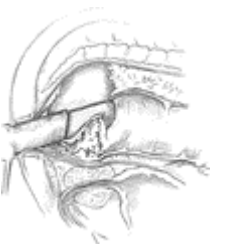

Figure 3 . The rectal wall is then incised from the outside, while verifying the incision on the healthy mucosa, at least 5 mm from the upper margin of the adenoma; a circumferential 360° incision with clear margins is placed here also.

The prone position was used in all cases to limit the complication of inadvertent opening of the peritoneum. With the patient positioned in this manner, insufflation of the proximal bowel is limited by body pressure that counterbalances bowel distension, the risk of the inflated small bowel protruding into the rectum through the peritoneal opening is minimized and suturing of the peritoneum is easier. On completion of the dissection, the specimen was retrieved either through the rectoscope or, if too large to pass through the tube, by removing the tube and using it as a dilator to retrieve the specimen through the anus. The pelvic cavity was then irrigated with 100 ml iodopovidone 10% solution. Three or four double-stay stitches with monofilament absorbable suture (Maxon 3/0; Covidien Ltd, Mansfield, Massachusetts, USA) were placed at 120° or 90° and secured with dedicated silver clips. To avoid excessive tension on the stay stitches, they were tied loosely and then put under tension or removed after completion of the anastomosis. If a 15-cm rectoscope was used, after placing the stay sutures, this was replaced with a 7-cm rectoscope to

allow better manoeuvrability. Full-thickness running sutures with Maxon 3/0 secured with silver clips (Richard Wolf, Knittlingen, Germany) were placed from one stay suture to the next, completing the end-to-end anastomosis.

Patients were mobilized the same day of surgery. A urinary catheter placed at the time of surgery was removed 48 h later in cases of anterior wall involvement. Postoperative analgesia was ensured by intravenous paracetamol for 24 h. Oral intake was allowed the day after the first passage of flatus opening of the peritoneum was opened. Discharge was allowed 24 h after stool passage, if no fever or pain was experienced in the last day.

Results

Between September 2010 and January 2015, 317 TEM procedures were performed for rectal lesions, 17 of which were circumferential. There were nine males and the median age of the whole group was 69 years [interquartile range 25th to 75th percentile (IQR) 45–78 years]. The patient characteristics are shown in Table 1. Preoperative evaluation identified low-grade dysplasia (LGD) in three patients, high-grade dysplasia (HGD) adenoma in 12 and squamous HGD in one patient. Preoperative ultrasonography showed a uT0 lesion in 13 patients and a uT1 lesion in the remaining three and these findings were confirmed by MRI. One patient with a preoperative diagnosis of adenocarcinoma and an endorectal ultrasound and MRI staging of uT1 and mT1 was included in a local ongoing trial (NCT02127645) and offered short-course radiotherapy, achieved a downstaging of the lesion and consequently underwent, according to the protocol, local excision of the persisting scar. The median distance from the anal verge was 4 cm (IQR 4–8 cm); the median longitudinal extent was 7 cm (IQR 4–8 cm) as measured by rigid rectoscopy. End-to-end anastomosis was completed endoscopically in all cases. The mean operating time was 129.1 ± 55.2 min. The peritoneum was opened in four cases and closed with a continuous, braided absorbable suture (Vicryl, Johnson and Johnson Medical Ltd, Cincinnati, Ohio, USA) secured by intracorporeal stitching. No proximal bowel mobilization or conversion to transabdominal surgery or stoma formation was required.

Table 1. Patient characteristics, preoperative and follow-up data

Patient no.	1	2	3	4	5	6	7	8	9	10	11	12	13	14	15	16	17	Mean
1.	APR, abdominoperineal resection; D, dilatation; EUS, endoscopic ultrasound; HGD, high-grade dysplasia; K, carcinoma; LE, local excision; LGD, low-grade dysplasia; RT, radiotherapy; S, stenosis; VAC, Endo-SPONGE therapy.																	
2.	^a																	
Patient 17 had a second rectal lesion 4 cm from the anal verge, which was also excised during the same surgery.																		
Sex	M	F	F	M	F	M	F	F	M	M	M	F	M	M	F	M	F	
Age (years)	69	46	33	82	59	32	78	70	76	68	89	79	40	80	77	45	38	62.4
Distance anal verge	7	4	8	4	3	3	4	3	7	3	4	8	4	5	11	8	10	5.6
Longitudinal extent (cm)	8	7	6	10	8	7	7	10	7	7	5	4	8	5	5	7	3	6.7
EUS	uT0	uT1	uT0	uT1	uT0	uT0	uT0	uT0	uT0	uT0	uT1	uT0	uT0	uT0	uT0	uT0	uT1	
Operating time (min)	100	230	125	105	120	240	150	210	120	100	90	40	90	80	120	110	165	129.1
Preoperative pathology	LGD	HGD	HGD	HGD	HGD	LGD	HGD	HGD	HGD	HGD	K	HGD	HGD	HGD	LGD	HGD	HGD	
Surface area	60	91	84	110	108	148	90	255	60	55	50	40	75	40	45	80	70	85.9
Postoperative pathology	HGD	pT2	HGD	pT3	pT1	HGD	HGD	HGD	HGD	pT2	ypT0	HGD	pT1	pT1	HGD	HGD	pT1	

Patient no.	1	2	3	4	5	6	7	8	9	10	11	12	13	14	15	16	17	Mean
Lymph nodes resected	3	0	0	2	0	0	1	0	0	0	1	0	0	0	0	0	0	
Early complications				Leak		Leak	Leak						Leak	Leak			Bleeding	
Treatment of complications				Fibre		Fibre	VAC						Fibre	Fibre			Re-ly	
Hospital stay (days)	10	5	4	6	4	17	7	5	5	4	7	4	5	4	6	7	18	6.9
Local recurrence		Yes		Yes		Yes				Yes								
Treatment of recurrence		APR		RT		LE				APR								
Late complications	S			S	S					S								
Treatment of complications	D			D	D					D								
Follow-up (months)	54	42	42	30	30	30	30	24	24	24	12	12	9	9	9	9	9	23.5

Partial leakage of the anastomotic suture was observed in five patients. This was treated conservatively with a high-fibre diet in four and by endo-VAC therapy (Endo-SPONGE®; Braun Melsungen AG, Melsungen, Germany) for seven 7 days in one. According to the Dindo–Clavien classification the four minor leaks were classified as grade I and grade IIIa in the case of the fifth [6]. The median duration of postoperative hospital stay was 5 (4–18, IQR 4–7) days. Histopathological examination showed a mean surface area of $85.9 \pm 53.7 \text{ cm}^2$. Definitive tumour histology and staging reported HGD adenoma in eight patients, ypT0 in one patient, pT1sm1 in four patients, pT1sm2 in one patient, pT2 carcinoma in two patients and pT3 carcinoma in one patient. The lateral and deep margins were disease-free in all cases. No infectious complications were recorded. There was no postoperative faecal incontinence or urinary or sexual dysfunction over a minimum follow-up period of 9 months (median 24, IQR 9–30). Endoscopic balloon dilatation for stenosis was performed in four patients, complicated in one by a urinary fistula which was treated conservatively. According to the Dindo–Clavien classification these four (23.5%) late complications were grade IIIa [6]. The two patients with a pT2 carcinoma were offered a completion radical surgery which they refused, and they underwent abdominoperineal resection for subsequent endoluminal local recurrence of disease. They are both free of disease at 42 and 24 months after surgery. In both cases the recurrence was endoluminal. The patient diagnosed with a pT3 cancer refused radical surgery because of the risks related to comorbidities and experienced local relapse 18 months after surgery. He died of liver metastases 30 months after surgery, at the age of 85 years. None of the patients with pT1 carcinomas showed local relapse. In one patient with an HGD adenoma, a small local recurrence of HGD on the dentate line was detected; it was initially treated by endoscopic mucosectomy and argon plasma coagulation and then transanal local excision and is free of disease 30 months after initial surgery.

Discussion

One of the major barriers to the wider use of TEM is the steep learning curve in mastering reconstruction of the rectal wall defect [7]. For this reason, many centres perform TEM as a partial wall resection to minimize the risk of leakage. While it is true that suturing in TEM demands extensive training, a distinct advantage of a TEM excision over flexible endoscopy techniques, such as endoscopic mucosal resection and endoscopic submucosal dissection, is that it allows full-thickness rectal wall excision [8]. In such cases, TEM may overcome the limitations of the accuracy

of preoperative staging and the risk of unexpected malignancy [9-11]. Our belief is that the incidence of missed cancers is so high that a full-thickness excision in all cases should be preferred because, while it is true that radical surgery afterwards would be more complicated compared to partial excision, on the other side the need of further radical surgery decreases considerably.

A transanal approach is also advantageous for the patient and should be preferred to abdominal surgery whenever it is oncologically safe. So, the relatively long hospital stay (median 7 days) reported should not be an issue, as more important is patient's comfort. We did not obtain a quality of life score but most of the patients had a lesion < 5 cm from the anal verge and would otherwise have required an anterior resection, possibly with a hand-sutured colo-anal anastomosis, which would require a temporary loop ileostomy. This would significantly impair quality of life which would be further diminished by the need for stoma closure. A further advantage of the transanal approach is that the peritoneum can be left intact or sutured, so that extraperitoneal anastomotic leakage is more likely to be successfully treated conservatively, as was observed in all five cases in our series who developed this complication [12].

Preoperative understaging of rectal cancer can result in the subsequent clinical presentation of invasive adenocarcinomas not fully cleared by the TEM procedure, as occurred in three of the cases in our series. In such cases with invasive malignancy, immediate salvage radical surgery should always be recommended unless contraindicated for other reasons [13]. Very large lesions such as the circumferential ones reported here are very likely to contain a focus of malignant invasion as was seen in almost half of our cases. Unfortunately malignancy was diagnosed preoperatively in only one of these. Despite the considerable experience in our unit in the diagnosis and treatment of rectal cancer, preoperative staging by endoscopic ultrasound or MRI was found not to be completely reliable in determining the presence of invasion of the muscularis propria of the rectal wall with this being underestimated in three of the 17 patients, showing a limitation of the techniques.

The indications for TEM have been expanded over the years and now include the removal of circumferential large rectal adenomas transanally. To our knowledge, this is the largest series reported to date on the use of TEM for the removal of such lesions, which would otherwise have required major abdominal rectal surgery. The technique requires surgical expertise but it is safe, with an acceptable complication rate and a good oncological outcome.

REFERENCE

- 1 Buess G, Hutterer F, Theiss J, Böbel M, Isselhard W, Pichlmaier H. A system for a transanal endoscopic rectum operation. *Chirurg* 1984; 55: 677–80.
- 2 Mentges B, Buess G, Effinger G, Manncke K, Becker HD. Local therapy of rectum carcinoma. a prospective follow-up study. *Chirurg* 1996; 67: 133–8.
- 3 Morino M, Arezzo A, Allaix ME. Transanal endoscopic microsurgery. *Tech Coloproctol* 2013; 17 (Suppl 1): S55–61.
- 4 Allaix ME, Arezzo A, Caldart M, Festa F, Morino M. Transanal endoscopic microsurgery for rectal neoplasms: experience of 300 consecutive cases. *Dis Colon Rectum* 2009; 52: 1831–6.
- 5 Heald RJ. A new solution to some old problems: transanal TME. *Tech Coloproctol* 2013; 17: 257–8.
- 6 Dindo D, Demartines N, Clavien PA. Classification of surgical complications: a new proposal with evaluation in a cohort of 6336 patients and results of a survey. *Ann Surg* 2004; 240: 205–13.

- 7Schäfer H, Baldus SE, Hölscher AH. Giant adenomas of the rectum: complete resection by transanal endoscopic microsurgery (TEM). *Int J Colorectal Dis* 2006; 21: 533–7.
- 8Arezzo A, Passera R, Saito Y et al. Systematic review and meta-analysis of endoscopic submucosal dissection versus transanal endoscopic microsurgery for large noninvasive rectal lesions. *Surg Endosc* 2014; 28: 427–38.
- 9Mondal D, Betts M, Cunningham C, Mortensen NJ, Lindsey I, Slater A. How useful is endorectal ultrasound in the management of early rectal carcinoma? *Int J Colorectal Dis* 2014; 29: 1101–4.
- 10Marusch F, Ptok H, Sahm M et al. Endorectal ultrasound in rectal carcinoma – do the literature results really correspond to the realities of routine clinical care? *Endoscopy* 2011; 43: 425–31.
- 11Baatrup G, Elbrønd H, Hesselfeldt P et al. Rectal adenocarcinoma and transanal endoscopic microsurgery. Diagnostic challenges, indications and short term results in 142 consecutive patients. *Int J Colorectal Dis* 2007; 22: 1347–52.
- 12Morino M, Allaix ME, Famiglietti F, Caldart M, Arezzo A. Does peritoneal perforation affect short- and long-term outcomes after transanal endoscopic microsurgery? *Surg Endosc* 2013; 27: 181–8.
- 13Ramirez JM, Aguilera V, Valencia J et al. Transanal endoscopic microsurgery for rectal cancer. Long-term oncologic results. *Int J Colorectal Dis* 2011; 26: 437–43.