Histopathological and immunophenotypical criteria for the diagnosis of Sézary syndrome in differentiation from other erythrodermic skin diseases: A European Organisation for Research and Treatment of Cancer (EORTC) Cutaneous Lymphoma Task Force Study of 97 cases

Histopathological and immunophenotypical criteria for the diagnosis of Sézary syndrome in differentiation from other erythrodermic skin diseases: a European Organisation for Research and Treatment of Cancer (EORTC) Cutaneous Lymphoma Task Force Study of 97 cases

Klemke CD, Booken N, Weiss C, Nicolay JP, Goerdt S, Felcht M, Géraud C, Kempf W, Assaf C, Ortonne N, Battistella M, Bagot M, Knobler R, Quaglino P, Arheiliger B, Santucci M, Jansen P, Vermeer MH, Willemze R.

Summary

Background

Patients with erythrodermic disease are a diagnostic challenge regarding the clinical and histological differential diagnosis.

Objectives

To evaluate histopathological and immunohistochemical diagnostic markers for Sézary syndrome.

Methods

Ninety-seven erythrodermic cases [Sézary syndrome (SS), *n* = 57; erythrodermic inflammatory dermatoses (EIDs), *n* = 40] were collected by the EORTC Cutaneous Lymphoma Task Force histopathology group. Evaluation criteria were (i) epidermal and dermal changes; (ii) morphology of the infiltrate; (iii) immunohistochemical analysis of marker loss (CD2, CD3, CD4, CD5 and CD7); (iv) bystander infiltrate by staining for CD8, FOXP3 and CD25; and (v) expression of Ki-67, CD30, PD-1 and MUM-1.

Results

The workshop panel made a correct diagnosis of SS in 51% of cases (cutaneous T-cell lymphoma 81%) and of EID in 80% without clinical or laboratory data. Histology revealed a significantly increased degree of epidermotropism ($P < 0{\cdot}001$) and more intraepidermal atypical lymphocytes ($P = 0{\cdot}0014$) in SS biopsies compared with EID. Pautrier microabscesses were seen only in SS (23%) and not in EID ($P = 0{\cdot}0012$). SS showed significantly more dermal cerebriform and blastic lymphocytes than EID. Immunohistochemistry revealed a significant loss of CD7 expression (< 50%) in 33 of 51 (65%) cases of SS compared with two of 35 (6%) EID ($P < 0{\cdot}001$). The lymphocytic infiltrate in SS skin samples was found significantly to express PD-1 ($P = 0{\cdot}0053$), MUM-1 ($P = 0{\cdot}0017$) and Ki-67 ($P < 0{\cdot}001$), and showed less infiltration of $CD8^+$ lymphocytes ($P < 0{\cdot}001$). A multivariate analysis identified CD7 loss, increased numbers of small cerebriform lymphocytes, low numbers of $CD8^+$ lymphocytes and increased proliferation (Ki-67^+ lymphocytes) as the strongest indicators for the diagnosis of SS.

Conclusions

A number of different histological and immunophenotypical criteria are required to differentiate between SS and EIDs.

Sézary syndrome (SS) is the leukaemic variant of cutaneous T-cell lymphoma (CTCL). It is characterized by erythroderma, generalized lymphadenopathy and a clonal T-cell proliferation involving skin, lymph nodes and peripheral blood.[1] The diagnosis is based on the clinical presentation; (immuno)histopathology of a skin biopsy; T-cell receptor (TCR) gene rearrangement studies of skin, lymph node and blood samples; demonstration of circulating Sézary cells in the peripheral blood; and staging procedures. The patient usually experiences erythrodermic skin and intense pruritus. The intensity of the erythroderma shows a wide variety from mild to intensive.[2] Besides SS, erythroderma can be caused by erythrodermic mycosis

fungoides (EMF), the classical CTCL, or by a number of erythrodermic inflammatory dermatoses (EIDs) such as psoriasis, atopic dermatitis, drug rash, pityriasis rubra pilaris, contact dermatitis and others. The clinical differential diagnosis between the various erythrodermic skin diseases is quite challenging due to the lack of clear diagnostic markers.

The histopathological diagnosis of erythrodermic skin samples is hampered by missing diagnostic markers for one or the other. A number of studies have tried to evaluate histopathological markers to differentiate between erythrodermic CTCL and EIDs. A recent study evaluated 47 skin biopsies from erythrodermic patients including 18 erythrodermic CTCL and 29 EID skin samples.[3] In that study erythrodermic CTCL was characterized by the presence of atypical lymphocytes, Pautrier microabscesses, a dense dermal infiltrate, a low CD8 : CD3 ratio, dermal $CD30^+$ cells and JunB expression in 17% of the cases. The samples from patients with EIDs showed single-lymphocyte epidermotropism, telangiectasias and a slight dermal infiltrate. However, based on these criteria the blinded evaluation of the slides provided the correct diagnosis in only 31% of the cases. A correct differentiation between erythrodermic CTCL and EIDs was achieved in 57% of the samples.

Another study identified a monotonous band-like or perivascular infiltrate in the papillary dermis and Pautrier microabscesses in SS skin biopsies.[4] The accuracy of histopathological diagnosis in erythroderma could be increased by multiple biopsies and a correlation with clinical data.[5] A correct diagnosis by histology alone was obtained in 66% of cases in the previous study by focusing on subtle criteria that are characteristic for the different conditions associated with erythroderma.[6] Kamarashev *et al*.[7] investigated the histopathology of SS in contrast to EMF. They found acanthosis in 12 of 13 SS and seven of 13 EMF samples, and Pautrier microabscesses in six of 13 SS and 11 of 13 EMF biopsies. Two other studies concluded that the histological features of SS and EMF are more subtle than the histopathology of patch- or plaque-stage MF.[8, 9]

The differential diagnosis of erythroderma is still challenging based on clinical and morphological criteria alone. A number of new markers have been introduced in the clinic in recent years. The Cutaneous Lymphoma Task Force (CLTF) of the European Organisation for Research and Treatment of Cancer (EORTC) has collected a large number of skin samples of erythrodermic patients in order to identify diagnostic characteristics to differentiate SS from EIDs. A second goal was the evaluation of prognostic markers in this large cohort of well-characterized patients with SS.

Materials and methods

Two workshops of the EORTC CLTF were held at the Mannheim Medical Center, University of Heidelberg, Mannheim, Germany on 12–13 May 2011 and at the Leiden University Medical Center, Leiden, the Netherlands on 3–4 November 2011. The participants came from seven European cutaneous lymphoma centres and are experienced dermatopathologists, haematopathologists and dermatologists. The participants provided skin biopsies from erythrodermic patients with a clear diagnosis and complete clinical, staging and follow-up data available. Completed data sheets with information on a large number of clinical, histological, laboratory, molecular biology and follow-up data were collected before the meeting.

Patients

Cases of SS were defined according to the criteria of the World Health Organization (WHO)–EORTC classification of cutaneous lymphomas.[1] All 57 patients with SS presented with erythroderma and had evidence of circulating Sézary cells in the peripheral blood by demonstration of either a Sézary cell count > 1000 cells mm^{-3} (36 of 52), a CD4 : CD8 ratio > 10 (41 of 57) or a monoclonal TCR-γ-chain gene rearrangement (53 of 53). Clonality data of the peripheral blood were not available in four patients with SS. These patients had CD4/CD8 ratios well above 10 and circulating Sézary cells > 1000 cells mm^{-3}

demonstrated by fluorescence-activated cell sorting analysis. Therefore, these four patients were diagnosed as having SS and included in the investigated cohort.

In all included patients with SS at least one of the three described criteria of circulating Sézary cells was SS defining. In four patients with CTCL a diagnosis of EMF was established because they did not fulfil the above-mentioned criteria for peripheral blood involvement. Due to the low number of patients with EMF these four patients were excluded from the study. Biopsies at the time point of establishing the diagnosis of SS were available from 36 patients with SS. Five of these were treated with topical steroids at the time point of the biopsy. In 31 patients with SS, untreated skin lesions were biopsied. In the remaining 21 patients biopsies obtained during follow-up were provided. In three follow-up cases the biopsy was taken from untreated skin, and the remaining patients received various therapies such as psoralen–ultraviolet A, extracorporeal photopheresis, bexarotene, chlorambucil, interferon-α, methotrexate or alemtuzumab.

The control group consisted of 40 well-defined patients with EIDs. All patients with EIDs presented with erythroderma and were diagnosed as having atopic dermatitis (*n* = 14), a drug eruption (*n* = 8), psoriasis (*n* = 6), erythroderma not otherwise specified (*n* = 4), pityriasis rubra pilaris (*n* = 3), contact dermatitis (*n* = 1), eczema (*n* = 1), Netherton syndrome (*n* = 1), papuloerythroderma Ofuji (*n* = 1) and paraneoplastic erythroderma (*n* = 1). These different patients with EIDs were evaluated as one group in order to identify diagnostic criteria for skin samples from patients with SS in contrast to other causes of erythroderma.

Histology and immunohistochemistry

Haematoxylin and eosin-stained sections, defined immunostainings and unstained sections or paraffin blocks were provided. Missing stainings were performed at the Department of Dermatology, Venereology and Allergy and Department of Pathology at the University Medical Center Mannheim, and at the Department of Pathology, Leiden University Medical Center prior to the meeting. The following immunostains were performed for the study: CD2, CD3, CD4, CD5, CD7, CD8, CD25, CD30, Ki-67, forkhead box protein (FOX)P3, mutated melanoma-associated antigen (MUM)-1 and programmed death (PD)-1. Expression of these markers was scored as follows: (i) antigen loss ≤ 50% of the whole epidermal and dermal lymphocytic infiltrate vs. positivity of ≥ 50% of the whole epidermal and dermal lymphocytic infiltrate (for CD2, CD3, CD4, CD5, CD7 and PD-1) and (ii) < 5%, 5–10%, 10–25%, 25–50% and > 50% of the whole epidermal and dermal lymphocytic infiltrate (for CD8, CD30, Ki-67, CD25, FOXP3 and MUM-1).

In total 101 biopsies from 101 patients were evaluated during the workshops. After excluding four cases of EMF, 97 erythrodermic patients with either SS or EIDs were suitable for evaluation and fulfilled the criteria of the study. During the two workshops haematoxylin and eosin stainings and immunostainings of all submitted cases were studied together behind a 14-headed (Mannheim) or 23-headed (Leiden) microscope. The goal was to define criteria for the histological and immunophenotypical diagnosis of SS. Well-defined cases of SS (*n* = 57) diagnosed according to the criteria of the WHO–EORTC classification of cutaneous lymphomas were mixed with well-defined cases of EID (*n* = 40) and studied in a blinded procedure.[1] For each case a consensus diagnosis based solely on histological and immunophenotypical criteria was obtained by the workshop panel. Consensus was reached after a discussion among the panel directly after looking at the slides of each case. Following the histopathological evaluation of each case the results were correlated with the provided clinical data, blood tests for circulating Sézary cells and results of TCR-γ-chain gene rearrangement analyses of skin and blood samples.

Statistical analysis

The study end point was 30 April 2011 or the last available follow-up prior to this date for survival or death of the patient. All statistical calculations, including estimated 5-year survival rates, were performed using SAS statistical software, release 9.3 (SAS Institute Inc., Cary, NC, U.S.A.). Quantitative, approximately normally distributed data are presented as the mean value with SD; time intervals (such as follow-up time)

and skewed data are given as the median with the corresponding range. Survival rates were assessed according to the Kaplan–Meier technique. The different parameters investigated in the two groups (SS and EID) were analysed with the chi-squared-test, Fisher's exact test, one-way anova or Cochran–Mantel–Haenszel test, as appropriate. For the comparisons of two groups, the chi-squared-test, Fisher's exact test, two-sample *t*-test or Cochran–Armitage trend test was used. Log-rank tests were performed to compare survival times of several diagnostic groups. Logistic regression was used as a multiple analysis in order to investigate prognostic factors differentiating SS from EIDs. A test result was considered significant with $P < 0{\cdot}05$.

Results

The clinical, molecular diagnostic, histopathological and immunohistochemical results of the 57 cases of SS and 40 cases of EID are summarized in Tables 1-3. The mean age was 67 years for patients with SS and 65 years for patients with EIDs (Table 1). The male-to-female ratios were 1·1 : 1 (SS) and 4·7 : 1 (EID) ($P = 0{\cdot}0024$). Analyses of peripheral blood parameters showed significant differences for SS and EID. The CD4/CD8 ratio was increased to a median of 27 (range 1–99) in patients with SS in contrast to 3 (range 1–6) in patients with EIDs ($P < 0{\cdot}001$). High numbers of Sézary cells were detected in patients with SS (3845 cells μL^{-1}, range 7–31 493) in comparison with EID (244 cells μL^{-1}, range 68–598) ($P < 0{\cdot}001$). Patients with SS showed a monoclonal TCR-γ-chain gene rearrangement in the skin in 49 of 50 cases and in the blood in 53 of 53 cases. In 33 of 53 (62%) patients with SS the blood clone was identical to that detected in the skin. In patients with EIDs a skin clone was found in two of 15 and a blood clone in one of 18 samples ($P < 0{\cdot}001$), which was not identical to the cutaneous clone. The median survival time for all patients with SS was 61 months (range 2–144). The overall survival was calculated with the Kaplan–Meier technique and revealed a 5-year survival rate of 51·4% for patients with SS and 64·6% for patients with EIDs.

Table 1. Clinical, diagnostic and follow-up data of patients with Sézary syndrome (SS) and erythrodermic inflammatory dermatoses (EIDs)

	SS	**EID**	**Test**	***P*-value**
Number of patients	57	40		
Age (years), mean ± SD (range)	66·8 ± 10·6 (43–91)	65·1 ± 15·4 (25–90)	*t*-test	0·79
Sex			χ^2	0·0024
Male, *n*	30	33		
Female, *n*	27	7		
Male-to-female ratio	1·1 : 1	4·7 : 1		
Time point of skin biopsy			χ^2	0·0016
First diagnosis	36/57 (63)	30/40 (75)		
Follow-up	21/57 (37)	10/40 (25)		
CD4/CD8 ratio in blood	27 (1–99)	3 (1–6)	*U*-test	< 0·001
CD4/CD8 ratio > 10	41/57 (72)	0/18 (0)	*U*-test	< 0·001
Sézary cells μL^{-1} blood	3845 (7–31 493)	244 (68–598)	*U*-test	< 0·001
Sézary cells μL^{-1} blood > 1000	36/52 (39)	0/20 (0)	*U*-test	< 0·001
Clonal TCR-γ in skin	49/50 (98)	2/15 (13)	Fisher	< 0·001
Clonal TCR-γ in blood	53/53 (100)	1/18 (6)	Fisher	< 0·001
Identical clone in skin and blood	33/53 (62)	0/18 (0)	χ^2	< 0·001
Status at last follow-up, *n*			Fisher	< 0·001
Complete remission	6	18		
Partial remission	18	5		
Stable disease	4	3		
Progressive disease	2	–		

1. Values are *n*/*N* (%) or median (range) unless stated otherwise. NC, not calculable; TCR, T-cell receptor.

	SS	EID	Test	*P*-value
Died of disease	13	–		
Died of other cause	13	4		
Not determined	1	10		
Survival time for all patients (months)	61 (2–144)	NC (2–69)		
5-Year overall survival	51·4%	64·6%		

Table 2. Histological data of patients with Sézary syndrome (SS) and erythrodermic inflammatory dermatoses (EIDs)

	SS	EID	Test	*P*-value
Number of patients	57	40		
Epidermal change	51/57 (89)	32/40 (80)	χ^2	0·19
Epidermotropism degree			Trend	< 0·001
None	7	11		
Single cells	3	11		
Focal	18	12		
Moderate	18	3		
Extensive	11	3		
Epidermotropism cell type (lymphocytes)			χ^2	0·0014
None	6	11		
Small	20	21		
Atypical	23	4		
Pautrier microabscesses	13/57 (23)	0/40 (0)	χ^2	0·0012
Location of dermal infiltrate				
Upper dermis	57/57 (100)	40/40 (100)		NC
Deeper dermis	5/57 (9)	0/40 (0)	Fisher	0·075
Subcutaneous tissue	0/57 (0)	0/40 (0)		NC
Pattern of dermal infiltrate				
Band-like	7/57 (12)	2/40 (5)	Fisher	0·19
Lichenoid	0/57 (0)	2/40 (5)	Fisher	0·17
Perivascular	45/57 (79)	37/40 (93)	χ^2	0·069
Diffuse	6/57 (11)	0/40 (0)	Fisher	0·041
Morphology of dermal lymphocytes				
Small cerebriform	39/57 (68)	12/40 (30)	χ^2	< 0·001
Large cerebriform	17/57 (30)	2/40 (5)	χ^2	0·0024
Small blasts	19/57 (33)	4/40 (10)	χ^2	0·0073
Large blasts	16/57 (28)	4/40 (10)	χ^2	0·030

1. Values are *n* or *n*/*N* (%). NC, not calculable.

Table 3. Immunohistochemical data of patients with Sézary syndrome (SS) and erythrodermic inflammatory dermatoses (EIDs). Antigen loss was diagnosed if < 50% of the whole epidermal and dermal lymphocytic infiltrate stained with the investigated antibody

	SS	EID	Test	*P*-value
Number of patients	57	40		
CD2 loss < 50%	4/47 (9)	0/39 (0)	Fisher	0·12
CD3 loss < 50%	2/57 (4)	0/40 (0)	Fisher	0·51
CD4 loss < 50%	1/51 (2)	0/40 (0)	Fisher	0·83

1. Values are *n* or *n*/*N* (%). FOXP3, forkhead box protein P3; MUM-1, mutated melanoma-associated antigen-1; PD-1, programmed death 1.

	SS	EID	Test	*P*-value
CD5 loss < 50%	1/50 (2)	0/37 (0)	Fisher	1·00
CD7 loss < 50%	33/51 (65)	2/35 (6)	χ^2	< 0·001
CD8			Trend	< 0·001
< 10%	37	9		
10–25%	15	13		
26–50%	–	6		
> 50%	–	11		
Not determined	5	1		
CD30			Trend	0·22
Negative	20	13		
< 5%	18	20		
5–10%	5	3		
11–25%	4	–		
26–50%	1	–		
> 50%	1	–		
Not determined	8	4		
Ki-67			Trend	< 0·001
Negative	–	1		
< 5%	6	13		
5–10%	17	11		
11–25%	9	6		
26–50%	4	–		
> 50%	4	–		
Not determined	17	9		
CD25			Trend	0·31
Negative	1	–		
< 5%	15	10		
5–10%	16	9		
11–25%	6	10		
26–50%	1	–		
> 50%	–	–		
Not determined	18	11		
FOXP3			Trend	0·20
Negative	2	1		
< 5%	33	12		
5–10%	9	11		
11–25%	3	3		
26–50%	1	–		
> 50%	–	–		
Not determined	9	13		
MUM-1			Trend	0·0017
Negative	6	5		
< 5%	12	18		
5–10%	15	14		
11–25%	10	–		
26–50%	5	–		
> 50%	5	1		
Not determined	4	2		
PD-1 expression > 50%	41/55 (75)	17/37 (46)	χ^2	0·0053

Sézary skin biopsies showed similar results obtained at first diagnosis and during follow-up

Skin biopsies were obtained at the time of establishing the diagnosis in the majority of cases (36 of 57 SS and 30 of 32 EID samples). However, in 21 of the 57 patients with SS, biopsies were available only during follow-up. In order to avoid any bias by looking at skin lesions that were possibly already treated we compared the results of two SS subgroups: patients with biopsies taken at the time point of first diagnosis (SS-1) and those obtained during follow-up (SS-2) (Tables S1–S3; see Supporting Information). All of the clinical data were obtained at the time point of diagnosis. A statistical comparison of all other parameters investigated did not show a significant difference between SS-1 and SS-2, except for a lower number of patients with an identical clone in the skin and blood in the SS-2 group ($P = 0{\cdot}044$, Tables S1–S3). Therefore, we evaluated all cases of SS as one group, despite different time points of available skin biopsies.

Diagnosis of the expert panel

All submitted cases were evaluated together by the faculty of the workshop in a blinded manner. After looking at all sections and immunostains the workshop faculty agreed on a diagnosis in each individual case based on epidermotropism, presence of Pautrier microabscesses, morphology of the lymphocytes (cerebriform, blasts) and the immunohistochemical profile of the lymphocytic infiltrate. The following diagnoses were obtained in the submitted SS biopsies ($n = 57$): SS ($n = 29$, 51%), CTCL ($n = 12$, 21%), suspicion CTCL ($n = 8$, 14%), mycosis fungoides (MF) ($n = 5$, 9%) and EID ($n = 3$, 5%). A correct dermatopathological diagnosis of SS without clinical correlation was obtained by the expert panel in 51% of the cases, and definite diagnosis of CTCL in 81%. However, a benign EID was diagnosed in only 5% of the cases.

Microscopy of the 40 EID skin samples revealed the following results: EID ($n = 32$, 80%), suspicion CTCL ($n = 3$, 8%), CTCL ($n = 2$, 5%), SS ($n = 2$, 5%) and one nondiagnostic sample (2%). This case had the clinical diagnosis of erythrodermic atopic dermatitis. In 80% of the evaluated EID skin samples a diagnosis of an inflammatory skin condition was obtained by histopathology alone. However, in 18% of the EID samples a diagnosis of CTCL or SS was made or at least suspected. All three cases with a histopathological diagnosis 'suspicion CTCL' had the clinical diagnosis of a drug eruption. The two samples diagnosed as CTCL were from a patient with erythrodermic atopic dermatitis and a patient with psoriasis. In one patient with an erythroderma not otherwise specified and one with papuloerythroderma Ofuji we concluded the histopathological diagnosis of SS. In order possibly to increase the correct histopathological diagnosis of SS we evaluated the above-mentioned diagnostic criteria for SS by comparing the morphological and immunohistochemical findings in SS samples with those found in control samples from patients with EIDs.

Epidermotropism is significantly increased in Sézary syndrome

Epidermal changes were recorded in the case of hyperplasia, spongiosis or atrophy (summarized in Table 2). Epidermal changes were seen in 51 of 57 (89%) SS specimens and 32 of 40 (80%) cases of EID. In SS, seven of 57 cases (12%) showed no epidermotropism, three (5%) showed single cells, and 18 (32%) focal, 18 (32%) moderate and 11 (19%) extensive epidermotropism. In EID skin samples epidermotropism was less pronounced: 11 of 40 (28%) showed none, 11 (28%) single cells, 12 (30%) focal, three (8%) moderate and three (8%) extensive epidermotropism. A statistical comparison between the two groups showed a significantly increased degree of epidermotropism in SS skin biopsies in contrast to EIDs ($P < 0{\cdot}001$). A clear distinction between SS skin samples and those from EID lesions could be made by the presence of Pautrier microabscesses, which were found only in SS (13 of 57, 23%) and not in any of the EID biopsies ($P = 0{\cdot}0012$).

Sézary syndrome is characterized by skin infiltration of atypical cerebriform and blastic lymphocytes

Epidermotropic atypical lymphocytes were found in 23 of 49 (47%) SS skin specimens and in four of 36 (11%) EID biopsies. The analysis of the morphology of the dermal lymphocytic infiltrate revealed significant differences between skin biopsies from SS vs. EID samples. The presence and percentage of small cerebriform lymphocytes ($P < 0{\cdot}001$), large cerebriform lymphocytes ($P = 0{\cdot}0024$) and small ($P = 0{\cdot}0073$) and large blasts ($P = 0{\cdot}030$) was increased in SS in comparison with EID (Table 2).

A dermal band-like infiltrate was seen in seven of 57 (12%) SS and in two of 40 (5%) EID biopsies. A perivascular distribution of the dermal infiltrate was observed in 45 of 57 (79%) SS and 37 of 40 (93%) EID sections. None of the 40 EID skin biopsies showed diffuse dermal infiltration, in contrast to six of 57 (11%) SS cases ($P = 0{\cdot}041$). Lichenoid dermal infiltration was seen in only two of 40 (5%) EID biopsies evaluated but in none of the cases of SS. The location and pattern of the dermal infiltrate did not differ significantly between the two study groups, except for the diffuse pattern, which was observed only in a minority of SS samples. Therefore, we evaluated the diagnostic value of various immunohistochemical markers in the differentiation of SS and EID.

Infiltrates of Sézary syndrome are characterized by loss of CD7 expression

One goal of this study was to evaluate the value of routine and newly established immunohistochemical markers in the differential diagnosis of erythrodermic skin diseases (Table 3). Antigen loss was diagnosed if < 50% of the whole epidermal and dermal lymphocytic infiltrate stained with the marker investigated. The loss of expression of classical T-cell markers such as CD2, CD3, CD4 and CD5 was seen only in single cases by comparing the expression of all four markers with each other. However, loss of CD7 expression occurred in 33 of 51 (65%) cases of SS investigated in contrast to two of 35 (6%) EID specimens (Fig. 1a). Loss of CD7 in comparison with other T-cell antigens studied was highly significant for Sézary skin biopsies ($P < 0{\cdot}001$, Fig. 2). Demonstration of CD7 loss by > 50% of the infiltrating T cells supports the histopathological diagnosis of SS.

Figure 1.

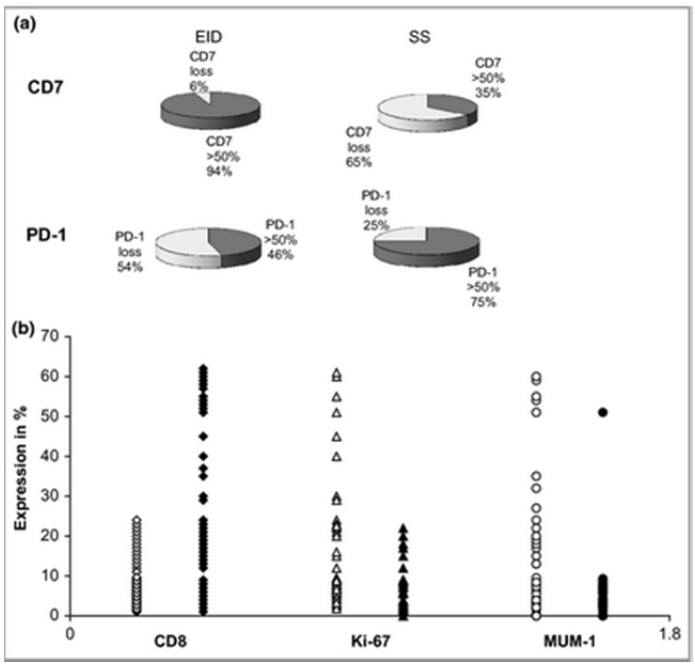

Immunohistochemical expression patterns differentiate Sézary syndrome (SS) skin samples from samples from patients with erythrodermic inflammatory dermatoses (EIDs). (a) Loss of CD7 expression in > 50% of the infiltrate was observed in 65% of SS samples in contrast to only 6% of EID samples. Programmed death (PD)-1 expression in > 50% of the lymphocytic infiltrate was seen in 75% of SS biopsies and in 46% of EID samples. (b) Expression of CD8, Ki-67 and mutated melanoma-associated antigen (MUM)-1 in SS and EID.

Figure 2.

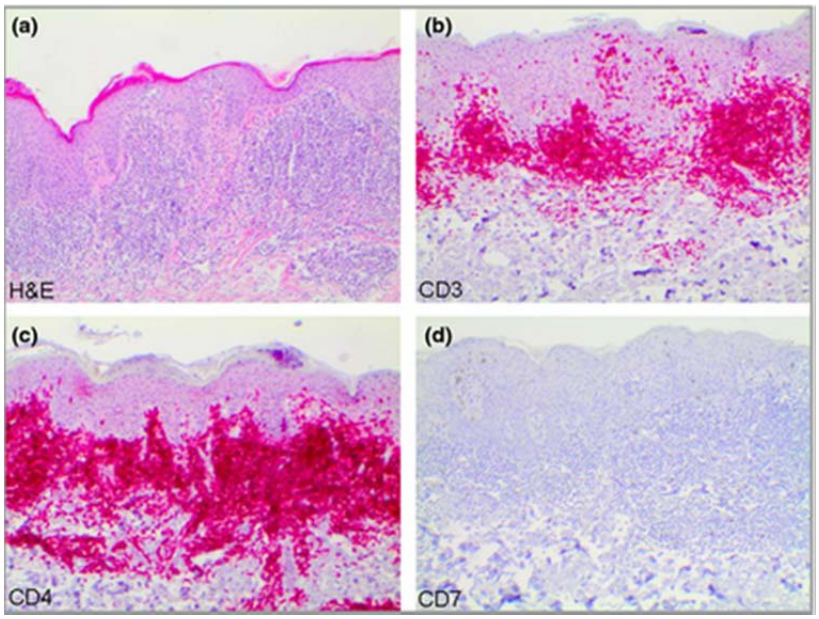

Pronounced loss of CD7 expression in a Sézary syndrome (SS) skin biopsy. (a) The haematoxylin and eosin (H&E) staining of a case of SS shows a dense dermal infiltrate of atypical small cerebriform lymphocytes with marked epidermotropism. (b) Most of the lymphocytes are $CD3^+$ T cells showing extensive epidermotropism with the beginning of Pautrier microabscess formation. (c) Most of the lymphocytes are also $CD4^+$. (d) Staining with an antibody against CD7 reveals loss of CD7 expression of most of the malignant T cells.

The majority of skin-infiltrating lymphocytes in Sézary syndrome are $CD30^-$ $FOXP3^-$ $CD25^-$

Expression of CD30 was usually seen in < 5% of the skin-infiltrating lymphocytes in SS and EIDs. Only single SS biopsies showed higher expressions rates of up to 50% of the infiltrate. However, there were no statistical differences found between the two groups. Similar results were obtained for stainings with CD25 and FOXP3. In the majority of samples the expression of CD25 and FOXP3 was < 5% of the infiltrate. We did not see a single case of SS with $FOXP3^+$ tumour cells.

Sézary syndrome shows increased proliferation and mutated melanoma-associated antigen-1 expression and reduced numbers of reactive $CD8^+$ lymphocytes

All skin samples were scored as follows: < 5%, 5–10%, 11–25%, 26–50% and > 50% of skin-infiltrating lymphocytes. The proliferation rate established by Ki-67 expression was significantly different between the two groups, with a higher rate in SS samples than in EID samples ($P < 0{\cdot}001$, Fig. 1b). The expression of MUM-1 was evaluated as described for Ki-67. The expressions levels of MUM-1 were significantly higher in SS than in EID ($P = 0{\cdot}0017$; Figs 1b and 3a, b). Infiltration of the skin by reactive $CD8^+$ lymphocytes was much more pronounced in EID specimens than in SS samples ($P < 0{\cdot}001$; Figs 1b and 3c, d). SS skin samples are characterized by higher proliferation rates (Ki-67^+ lymphocytes) and increased MUM-1 expression. The lymphocytic skin infiltrates in reactive erythroderma skin biopsies are predominated by $CD8^+$ lymphocytes.

Figure 3.

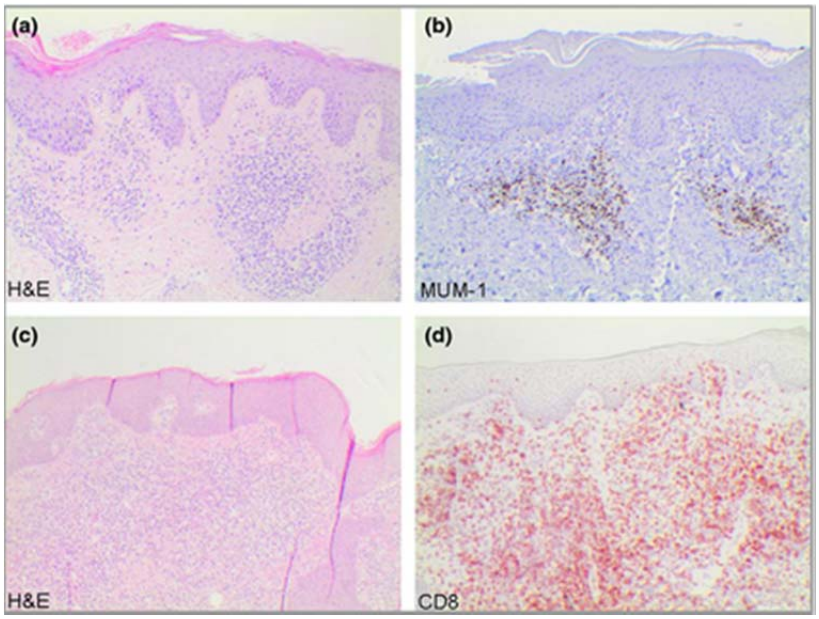

Sézary syndrome (SS) skin biopsies show strong mutated melanoma-associated antigen (MUM)-1 expression, and reactive erythrodermic skin infiltrates are dominated by $CD8^+$ cells. (a) The haematoxylin and eosin (H&E) staining of a case of SS shows a moderate infiltrate of atypical lymphocytes in the upper dermis without epidermotropism. (b) The majority of the dermal atypical lymphocytes express MUM-1. (c) The biopsy of a patient with erythrodermic psoriasis shows acanthosis and a dense infiltrate of lymphocytes in the upper dermis. (d) Most of the dermal cells are $CD8^+$ lymphocytes.

Programmed death-1 expression is significantly increased in Sézary syndrome

Skin samples were rated as PD-1 positive if > 50% of the skin infiltrate expressed PD-1. Cases with < 50% PD-1 expression were scored as PD-1 negative. Overall 75% (41 of 55) of SS skin biopsies were PD-1 positive and 14 (25%) were PD-1 negative (Fig. 1a). In EID 17 of 37 (46%) samples were PD-1 positive. Within the EID group PD-1 expression was found particularly in biopsies from patients with atopic dermatitis (n = 5) and drug eruptions (n = 6). The expression of PD-1 was significantly different between the two groups (P = 0·0053, Fig. 4). Therefore, PD-1 expression is an important feature of SS.

Figure 4.

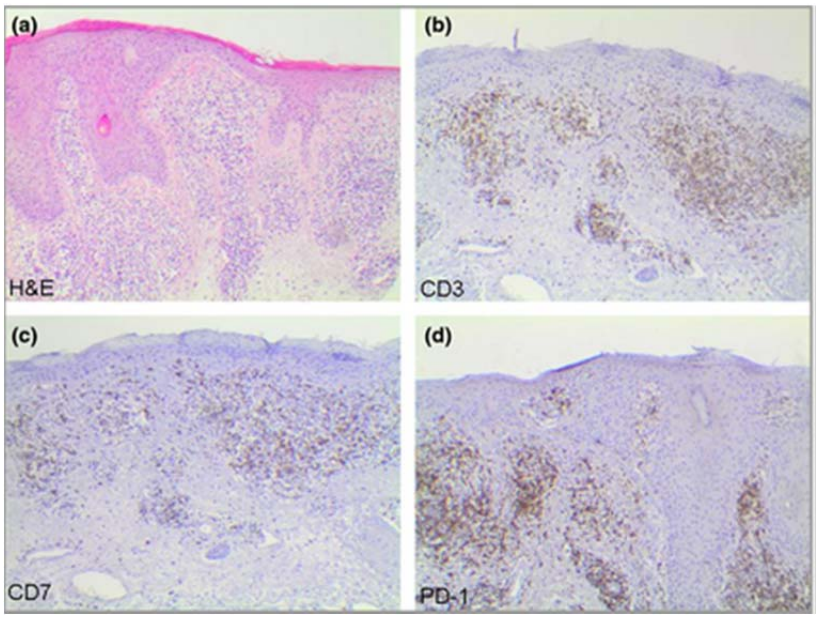

Skin infiltrates in patients with Sézary syndrome (SS) show strong programmed death (PD)-1 expression. (a) The haematoxylin and eosin (H&E) staining of a case of SS shows an upper-dermal infiltrate of atypical small and large cerebriform lymphocytes with a single-cell epidermotropism. (b) The majority of the lymphocytes express the T-cell antigen CD3. (c) Less than 50% of the $CD3^+$ lymphocytes express CD7, consistent with CD7 loss. (d) Most of the $CD3^+$ lymphocytes express PD-1.

Diagnostic criteria for Sézary syndrome skin samples

Diagnostic criteria obtained for SS samples were the presence of Pautrier microabscesses and a diffuse dermal lymphocytic infiltrate. However, these criteria were found in only 23% and 11%, respectively, of the cases investigated. Other characteristics of SS identified in this study were marked epidermotropism in contrast to EIDs. Lymphocytes in SS skin infiltrates showed atypical, cerebriform and blastic morphology compared with EID infiltrates. Immunohistochemically SS samples showed CD7 loss, increased MUM-1 and PD-1 expression and higher proliferation rates. The infiltrates of EID were predominated by $CD8^+$ lymphocytes, which were hardly seen in SS samples. We used multivariate analysis by a logistic regression model to identify the best diagnostic parameters for the differentiation of SS from EIDs. All of the morphological and immunophenotypical parameters shown in Tables 2 and 3 were included in this statistical model. This multivariate analysis revealed CD7 loss ($P = 0{\cdot}0081$), presence of small cerebriform lymphocytes in the dermis ($P = 0{\cdot}014$), CD8 expression ($P = 0{\cdot}018$) and proliferation established by Ki-67 ($P = 0{\cdot}049$) as the best markers for the differential diagnosis of SS and EIDs. All other markers were not able to differentiate between SS and EIDs in this multivariate analysis.

A diagnostic workflow for the evaluation of skin biopsies from erythrodermic skin was developed (Fig. 5). The most important morphological criteria for the diagnosis of SS were the presence of Pautrier microabscesses and a diffuse dermal infiltrate, which were both seen exclusively in SS samples. The most helpful immunohistochemical markers were CD7 loss in combination with CD8 expression < 25% of the infiltrate, which was not found in any of the EID samples. These four morphological and immunohistochemical parameters identified 37 of 57 (65%) SS samples. The addition of TCR-γ-chain gene rearrangement data of skin and blood samples allowed a correct diagnosis of SS in 95% of the cases.

Figure 5.

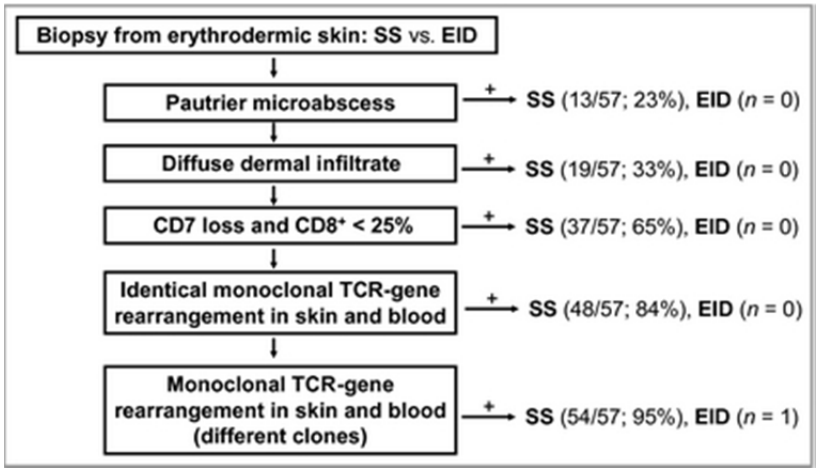

Diagnostic workflow for the evaluation of skin biopsies from erythrodermic skin to differentiate Sézary syndrome (SS) from erythrodermic inflammatory dermatoses (EIDs). TCR, T-cell receptor.

Prognostic markers identified in Sézary syndrome skin samples in correlation with follow-up data

Finally, we correlated the investigated histological and immunohistochemical markers with survival in all patients with SS (Table 4). There was a significant prognostic influence of the cell type of epidermotropism (P = 0·046), a deep (P = 0·018, Fig. 6a) and diffuse (P = 0·049, Fig. 6b) dermal infiltrate and CD25 expression (P = 0·0061) in patients with SS who died of SS.

Table 4. Prognostic value of the investigated histopathological and immunohistochemical parameters in skin biopsies of patients with Sézary syndrome

	Death	Death of disease
Epidermal change	0·43	0·76
Epidermotropism degree	0·27	0·17
Epidermotropism cell type	0·031	0·046
No vs. small	0·017	0·0045
No vs. atypical	0·046	0·21
Small vs. atypical	0·53	0·17
Pautrier microabscesses	0·66	0·64
Location of dermal infiltrate		
Upper dermis	NC	NC
Deeper dermis	0·27	0·018
Subcutaneous tissue	NC	NC
Pattern of dermal infiltrate		
Band-like	0·15	0·40
Lichenoid	NC	NC
Perivascular	0·29	0·38
Diffuse	0·46	0·049
Morphology of dermal lymphocytes		
Small cerebriform	0·69	0·74
Large cerebriform	0·35	0·85
Small blasts	0·68	0·52

1. NC, not calculable; FOXP3, forkhead box protein P3; MUM-1, mutated melanoma-associated antigen 1; PD-1, programmed death 1.

	Death	Death of disease
Large blasts	0·54	0·64
CD2 loss	0·63	0·89
CD3 loss	0·39	0·65
CD4 loss	NC	NC
CD5 loss	NC	NC
CD7 loss	0·18	0·088
CD8	0·31	0·098
CD30	0·23	0·49
Ki-67	0·17	0·11
CD25	0·052	0·0061
FOXP3	0·051	0·21
MUM-1	0·30	1·00
PD-1	0·51	0·18

Figure 6.

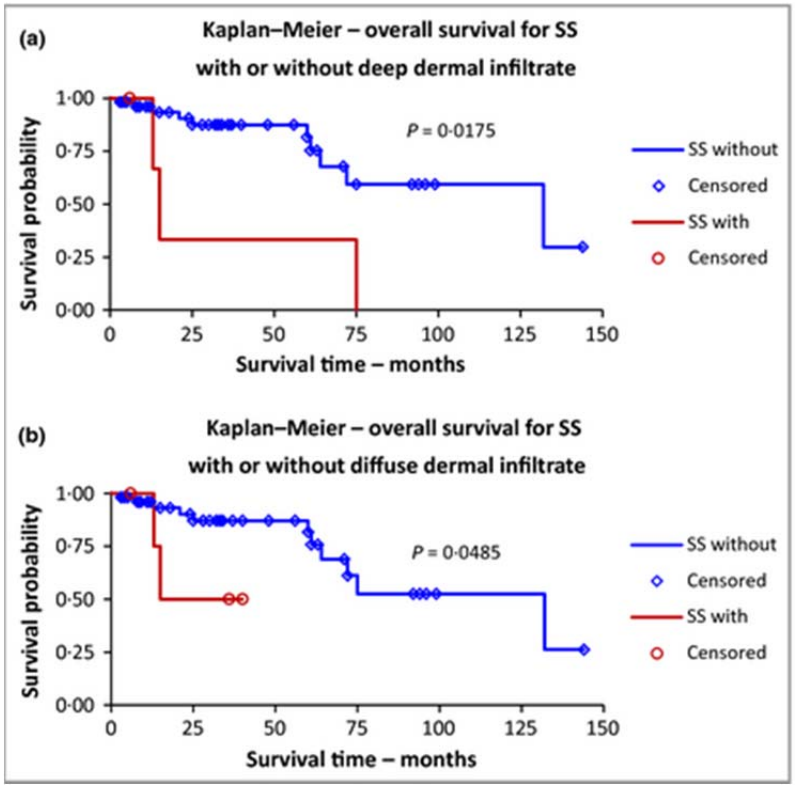

Patients with Sézary syndrome (SS) with a deep or diffuse dermal lymphocytic infiltrate have a worse prognosis. (a) Kaplan–Meier survival curves for patients with SS with or without a deep dermal infiltrate. (b) Kaplan–Meier survival curves for patients with SS with or without a diffuse dermal infiltrate.

Discussion

This study investigated diagnostic markers in 97 biopsies from erythrodermic skin obtained from patients with SS (*n* = 57) and EID (*n* = 40). The characteristics of our patients with SS were comparable with those in published studies, also reporting a male predominance.[10] The 5-year survival rate of 51·4% of our well-defined group of patients with SS is more favourable than previously reported (42·3%[10] and 24%).[1] A correct diagnosis was made by histopathology alone in 51% of the SS samples and in 80% of the EID specimens. A recent study of 47 erythrodermic cases revealed a correct diagnosis in 31% of cases, and a separation between CTCL and reactive erythroderma was possible in 57% of the cases.[3] That study and

our results presented here underline the necessity for better definition of diagnostic criteria for the histopathological diagnosis of SS. The identification of diagnostic histopathological criteria for SS was the main goal of this study. A second goal was the identification of prognostic markers obtained by histology in SS.

Epidermotropism of lymphocytes was more pronounced in SS skin biopsies than in EID samples ($P < 0{\cdot}001$). The majority of SS samples (51%) showed moderate or extensive epidermotropism, which was seen in only 16% of EID skin biopsies. However, 12% of the SS samples and 28% of EID lesions showed no epidermotropism at all. Diwan *et al*.[11] found significant epidermotropism of lymphocytes in 12 of 31 (39%) Sézary samples, which is slightly less than in our cohort. Another study observed moderate-to-extensive epidermotropism in six of 11 cases of SS.[4] These differences in epidermotropism might reflect the clinical heterogeneity of erythroderma in patients with SS, ranging from mild erythema to indurated erythroderma with scaling and exfoliation.[2]

A clear diagnostic marker for the distinction between SS and EIDs was the presence of Pautrier microabscesses, which we observed in 13 of 57 (23%) SS biopsies and in none of the EID biopsies ($P = 0{\cdot}0012$). This finding is in line with other studies showing Pautrier microabscesses in seven of 11[4] and six of 13 SS skin biopsies.[7] However, it has to be taken into account that Pautrier microabscesses are more common in EMF (11 of 13) than in SS (six of 13).[7] The presence of Pautrier microabscesses is highly diagnostic for CTCL in erythrodermic patients and excludes EIDs.

Morphological changes such as cerebriform nuclei or blasts can also occur during inflammatory processes, although to a lesser degree. In our series 23 of 49 (47%) SS samples showed epidermotropic atypical lymphocytes in contrast to four of 36 (11%) in EID samples. Another study measured the largest nuclear diameter of cerebriform mononuclear cells and found identical diameters in samples from SS, chronic dermatitis and drug eruptions.[4] Furthermore, the identification of atypical lymphocytes varies between different observers.[5] Therefore, the evaluation of lymphocyte morphology might be a possible pitfall in the histopathology of SS.[12]

The dermal infiltrate showed a perivascular pattern in the majority of SS (45 of 57, 79%) and EID (37 of 40, 93%) samples. These findings were similar to those from two other studies.[4, 7] A minority of patients with SS showed infiltration of the deeper dermis (five of 57) or a diffuse dermal infiltrate (six of 57), neither of which was seen in any of the cases of EID. The presence of a diffuse dermal infiltrate and infiltration of the deeper dermis were associated with a worse prognosis in those patients who died due to their SS. These observations could reflect a higher cutaneous tumour cell load leading to a worse outcome. A lichenoid infiltrate was seen in none of our cases of SS, which is in contrast to 42% lichenoid infiltrates in a study of 31 SS samples.[11]

A current problem in the diagnosis of SS is the lack of a tumour cell marker that is able to separate malignant tumour 'Sézary' cells from reactive lymphocytes. A number of new markers and techniques have identified possible new markers for SS in a variety of small studies. The EORTC CLTF has initiated a translational multinational study for the identification of diagnostic markers in the peripheral blood in a large cohort of patients with SS. In parallel the group wanted to investigate suitable markers for histopathology in a large cohort of Sézary skin samples.

Many studies have found changes of the expression of classical T-cell surface markers and identified new markers on peripheral blood lymphocytes of patients with SS by flow cytometry immunophenotyping.[13-15] One study compared the tumour cell immunophenotype in the skin and blood of the same patient and demonstrated identical immunophenotypes in nine of 20 patients.[16] However, these markers have not been investigated systematically in the skin. Classical T-cell markers such as CD2, CD3, CD4 and CD5 were lost in only a few single cases in our study.

CD7 is a transmembrane protein belonging to the immunoglobulin superfamily. The majority (33 of 51, 65%) of SS samples showed CD7 loss, in contrast to two of 35 (6%) in EID biopsies. A significant loss of CD7 expression in cutaneous lymphocytes has been reported only in single cases[17] or small cohorts of patients with SS.[11] Observation of CD7 loss in an erythrodermic skin biopsy clearly supports the diagnosis of SS.

The frequency of $CD30^+$ cells was low in all skin samples investigated. We did not observe a difference between SS and EIDs regarding CD30 expression, similarly to other studies.[3] Two cases with SS had > 25% of lymphocytes expressing CD30. This finding is supported by single cases of SS with increased CD30 expression of the lymphocytes.[18]

Talpur *et al*.[19] identified CD25 expression levels > 20% of the cutaneous infiltrate in 24 of 113 (21%) CTCL skin biopsies (100 MF and 13 SS). The majority of our skin samples showed CD25 expression up to 10% of the infiltrate. The expression rates did not differ between SS and EIDs. Interestingly, the multiple Cox analysis revealed that an increase of CD25 expression was associated with a 50% reduction of the death rate in patients with SS ($P = 0{\cdot}052$). This was also true for patients with SS who died of the disease ($P = 0{\cdot}0061$, hazard ratio 0·17). Thus, an increase in CD25 expression reduced the death rate to one in six. This is in contrast to *de novo* CD25 expression in follicular lymphoma, which was shown to be associated with a worse outcome.[20] However, another study showed that increased serum levels of soluble interleukin-2 receptor-α were associated with better responses to treatment in patients with extranodal natural killer/T-cell lymphoma.[21] Our study result regarding the prognostic value of CD25 expression in SS needs to be confirmed in another cohort of patients with SS.

Earlier studies described $FOXP3^+$ tumour cells in the skin and blood in a small number of patients with SS.[22, 23] Furthermore, the reactive cutaneous lymphocytic infiltrate in SS showed a significant decrease of $FOXP3^+$ cells in contrast to MF and inflammatory skin diseases.[24] The majority of the skin samples investigated in this study showed FOXP3 expression in up to 10% of the infiltrate. We could not confirm a difference between SS and EIDs and we did not see any cases with $FOXP3^+$ tumour cells. Therefore, FOXP3 is not a good marker to identify Sézary cells.

Proliferation of cutaneous lymphocytes established by staining with Ki-67 was significantly increased in SS in contrast to EIDs ($P < 0{\cdot}001$). None of the EID samples had proliferation rates > 25% of the infiltrate. None of the other studies on the histopathology of SS reported data on proliferation. The increased proliferation might reflect the more aggressive clinical behaviour of SS in contrast to MF.

The multiple myeloma oncogene MUM-1 is a nuclear transcription factor that is essential for the development and activation of B lymphocytes. Nuclear expression is also seen in activated T cells and is found in a variety of T-cell neoplasms. We demonstrated significantly increased expression levels of MUM-1 in SS in contrast to EID ($P = 0{\cdot}0017$). Expression levels > 10% of the infiltrate were seen exclusively in SS samples. Therefore, high expression levels of MUM-1 > 10% of the infiltrate might be a helpful diagnostic marker for the histopathological diagnosis of SS in erythrodermic skin biopsies.

The tumour cells in SS are typically $CD4^+$ lymphocytes. Reactive $CD8^+$ cells decrease with an increased tumour cell load (reviewed by Krejsgaard *et al*.).[25] The presence of high numbers of $CD8^+$ cells in skin lesions of MF and SS was shown to be associated with improved survival.[26] We found a much more prominent infiltration of the skin in EID samples in contrast to SS. The percentage of $CD8^+$ cells was < 10% of the infiltrate in the majority of SS samples (37 of 57). $CD8^+$ cells > 25% of the infiltrate were found only in EID. The study by Ram-Wolff *et al*.[3] also demonstrated increased CD8/CD3 ratios in skin samples from patients with EID.

PD-1 is an inhibitory receptor for B7-H1 and B7-DC, two members of the B7 family of costimulatory–coinhibitory molecules that have an important role in the inhibition of T cells. PD-1 is expressed by germinal

centre-associated T cells in normal or reactive lymphoid tissue and by some activated T cells. It has also been detected in several types of lymphomas of T-cell origin.[27] PD-1 expression was shown on peripheral blood lymphocytes from patients with SS by flow cytometry immunophenotyping[28] and in the skin by immunohistochemistry.[29] Cetinözman *et al*.[30] demonstrated PD-1 expression by > 50% of the neoplastic cells in 24 of 27 (89%) patients with SS and in only eight of 60 (13%) patients with MF. We confirm the results of this study by demonstrating PD-1 expression in 41 of 55 (75%) SS samples. In the EID control group 17 of 37 samples (46%) were PD-1^+ (P = 0·0053).

In conclusion, important histopathological criteria for the distinction between SS and EIDs are the presence of Pautrier microabscesses and a diffuse and deep pattern of the dermal infiltrate, which were both seen exclusively in SS samples. Another important morphological feature of SS is increased epidermotropism. The presence of atypical cerebriform or blastic lymphocytes is more common in SS than in EID. Immunohistochemistry of SS revealed a significant loss of CD7 expression, less infiltration by $CD8^+$ cells, increased proliferation (Ki-67^+) and MUM-1 and PD-1 expression. Therefore, histopathological and immunohistochemical investigations of one or even multiple skin biopsies are an important diagnostic tool in establishing the diagnosis of SS. However, clinicopathological correlation is still essential for the final diagnosis of SS in differentiation from its simulators.[31]

References

1 Willemze R, Jaffe ES, Burg G et al. WHO-EORTC classification for cutaneous lymphomas. Blood 2005; 105:3768–85.

2 Booken N, Nicolay JP, Weiss C, Klemke CD. Cutaneous tumor cell load correlates with survival in patients with Sézary syndrome. J Dtsch Dermatol Ges 2013; 11:67–79.

3Ram-Wolff C, Martin-Garcia N, Bensussan A et al. Histopathologic diagnosis of lymphomatous versus inflammatory erythroderma: a morphologic and phenotypic study on 47 skin biopsies. Am J Dermatopathol 2010; 32:755–63.

4 Sentis HJ, Willemze R, Scheffer E. Histopathologic studies in Sézary syndrome and erythrodermic mycosis fungoides: a comparison with benign forms of erythroderma. J Am Acad Dermatol 1986; 15:1217–26.

5 Walsh NM, Prokopetz R, Tron VA et al. Histopathology in erythroderma: review of a series of cases by multiple observers. J Cutan Pathol 1994; 21:419–23.

6 Zip C, Murray S, Walsh NM. The specificity of histopathology in erythroderma. J Cutan Pathol 1993; 20:393–8.

7 Kamarashev J, Burg G, Kempf W et al. Comparative analysis of histological and immunohistological features in mycosis fungoides and Sézary syndrome. J Cutan Pathol 1998; 25:407–12.

8 Kohler S, Kim YH, Smoller BR. Histologic criteria for the diagnosis of erythrodermic mycosis fungoides and Sézary syndrome: a critical reappraisal. J Cutan Pathol 1997; 24:292–7.

9 Trotter MJ, Whittaker SJ, Orchard GE, Smith NP. Cutaneous histopathology of Sézary syndrome: a study of 41 cases with a proven circulating T-cell clone. J Cutan Pathol 1997; 24:286–91.

10 Kubica AW, Davis MD, Weaver AL et al. Sézary syndrome: a study of 176 patients at Mayo Clinic. J Am Acad Dermatol 2012; 67:1189–99.

11 Diwan AH, Prieto VG, Herling M et al. Primary Sézary syndrome commonly shows low-grade cytologic atypia and an absence of epidermotropism. Am J Clin Pathol 2005; 123:510–15.

12 Batrani M, Bhawan J. Pitfalls in the diagnosis of cutaneous lymphoma. Am J Dermatopathol 2014; 36:90–100.

13 Horna P, Deaver DM, Qin D et al. Quantitative flow cytometric identification of aberrant T cell clusters in erythrodermic cutaneous T cell lymphoma. Implications for staging and prognosis. J Clin Pathol 2014; 67:431–6.

14 Bouaziz JD, Remtoula N, Bensussan A et al. Absolute CD3+ CD158k+ lymphocyte count is reliable and more sensitive than cytomorphology to evaluate blood tumour burden in Sézary syndrome. Br J Dermatol 2010; 162:123–8.

15 Klemke CD, Brade J, Weckesser S et al. The diagnosis of Sézary syndrome on peripheral blood by flow cytometry requires the use of multiple markers. Br J Dermatol 2008; 159:871–80.

16 Kelemen K, White CR, Gatter K et al. Immunophenotypic correlation between skin biopsy and peripheral blood findings in mycosis fungoides. Am J Clin Pathol 2010; 134:739–48.

17 Song SX, Willemze R, Swerdlow SH et al. Mycosis fungoides: report of the 2011 Society for Hematopathology/European Association for Haematopathology workshop. Am J Clin Pathol 2013; 139:466–90.

18 Jang MS, Kang DY, Han SH et al. CD25+ folliculotropic Sézary syndrome with CD30+ large cell transformation. Australas J Dermatol 2014; 55:e4–8.

19 Talpur R, Jones DM, Alencar AJ et al. CD25 expression is correlated with histological grade and response to denileukin diftitox in cutaneous T-cell lymphoma. J Invest Dermatol 2006; 126:575–83.

20 Fujiwara S, Muroi K, Tatara R et al. Clinical features of de novo CD25-positive follicular lymphoma. Leuk Lymphoma 2014; 55:307–13.

21 Wang L, Liao DZ, Zhang J et al. Clinical significance of serum soluble interleukin-2 receptor-α in extranodal natural killer/T-cell lymphoma (ENKTL): a predictive biomarker for treatment efficacy and valuable prognostic factor. Med Oncol 2013; 30:723.

22 Krejsgaard T, Gjerdrum LM, Ralfkiaer E et al. Malignant Tregs express low molecular splice forms of FOXP3 in Sézary syndrome. Leukemia 2008; 22:2230–9.

23 Heid JB, Schmidt A, Oberle N et al. FOXP3+CD25− tumor cells with regulatory function in Sézary syndrome. J Invest Dermatol 2009; 129:2875–85.

24 Klemke CD, Fritzsching B, Franz B et al. Paucity of FOXP3+ cells in skin and peripheral blood distinguishes Sézary syndrome from other cutaneous T-cell lymphomas. Leukemia 2006; 20:1123–9.

25 Krejsgaard T, Odum N, Geisler C et al. Regulatory T cells and immunodeficiency in mycosis fungoides and Sézary syndrome. Leukemia 2012; 26:424–32.

26 Hoppe RT, Medeiros LJ, Warnke RA, Wood GS. CD8-positive tumor-infiltrating lymphocytes influence the long-term survival of patients with mycosis fungoides. J Am Acad Dermatol 1995; 32:448–53.

27 Keir ME, Butte MJ, Freeman GJ, Sharpe AH. PD-1 and its ligands in tolerance and immunity. Annu Rev Im munol 2008; 26:677–704.

28Samimi S, Benoit B, Evans K et al. Increased programmed death-1 expression on CD4+ T cells in cutaneous T-cell lymphoma: implications for immune suppression. Arch Dermatol 2010; 146:1382–8.

29 Wada DA, Wilcox RA, Harrington SM et al. Programmed death 1 is expressed in cutaneous infiltrates of mycosis fungoides and Sézary syndrome. Am J Hematol 2011; 86:325–7.

30 Cetinözman F, Jansen PM, Willemze R. Expression of programmed death-1 in primary cutaneous CD4-positive small/medium-sized pleomorphic T-cell lymphoma, cutaneous pseudo-T-cell lymphoma, and other types of cutaneous T-cell lymphoma. Am J Surg Pathol 2012; 36:109–16.

31 LeBoit PE. Simulators of cutaneous lymphoma: where should our efforts go? Am J Clin Pathol 2013; 139:414–17.