

AperTO - Archivio Istituzionale Open Access dell'Università di Torino

Long-term effects of rituximab added to cyclophosphamide in refractory patients with vasculitis.

This is the author's manuscript

Original Citation:

Availability:

This version is available <http://hdl.handle.net/2318/94749> since 2016-10-20T16:46:04Z

Published version:

DOI:10.1159/000329535

Terms of use:

Open Access

Anyone can freely access the full text of works made available as "Open Access". Works made available under a Creative Commons license can be used according to the terms and conditions of said license. Use of all other works requires consent of the right holder (author or publisher) if not exempted from copyright protection by the applicable law.

(Article begins on next page)

This is the author's final version of the contribution published as:

Roccatello D; Sciascia S; Rossi D; Alpa M; Naretto C; Russo A; Menegatti E; Baldovino S.. Long-term effects of rituximab added to cyclophosphamide in refractory patients with vasculitis.. AMERICAN JOURNAL OF NEPHROLOGY. 34 (2) pp: 175-180.
DOI: 10.1159/000329535

The publisher's version is available at:

<http://www.karger.com/doi/10.1159/000329535>

When citing, please refer to the published version.

Link to this full text:

<http://hdl.handle.net/2318/94749>

Long-Term Effects of Rituximab Added to Cyclophosphamide in Refractory Patients with Vasculitis

Dario Roccatello, Savino Sciascia, Daniela Rossi, Mirella Alpa, Carla Naretto, Alessandra Russo, Elisa Menegatti, Simone Baldovino.

Dipartimento di Malattie Rare, Immunologiche, Ematologiche ed Immunoematologiche, Centro di Ricerche di Immunopatologia e Documentazione su Malattie Rare (CMID), Struttura Complessa a Direzione Universitaria di Immunologia Clinica, Ospedale Torino Nord Emergenza San G. Bosco ed Università di Torino, Torino, Italia.

Key Words : Rituximab, Systemic vasculitis, Wegener's granulomatosis, Churg-Strauss syndrome, Idiopathic systemic microscopic polyangiitis .

Disclosure Statement The authors have no conflicts of interest to declare.

Abstract

Background: Current therapies have changed systemic vasculitis from a disease with a high rate of mortality to a chronic curable condition. A limited percentage of patients either remains refractory to conventional treatment or experiences dose-limiting side effects.

Methods: 11 patients (4 affected by idiopathic systemic microscopic polyangiitis, 5 by Wegener's granulomatosis, and 2 by Churg-Strauss syndrome) intolerant or refractory to conventional therapies including cyclophosphamide were enrolled. All patients received rituximab as a rescue therapy and were followed for 30–54 months. Following rituximab administration, immunosuppressive drugs were rapidly tapered and no immunosuppressive maintenance therapy was given.

Results: Significant decreases in levels of serum creatinine, proteinuria, erythrocyte sedimentation rate, C-reactive protein, and ANCA titers were observed during the follow-up (at least 30 months after rituximab administration). Arthralgia and weakness rapidly disappeared in all patients. Out of 7 patients, 5 reported a decrease in the degree of paresthesia and in the electrophysiologic parameters. Six months after rituximab administration the mean dose of prednisone was 5.5 mg/day.

Conclusion: In this sample of patients with systemic vasculitis who were refractory or intolerant to more conventional treatment, rituximab proved to be safe and effective in a long-term follow-up, and showed steroid- and immunosuppressive-sparing effects allowing the persistence of long-lasting remissions without maintenance therapy.

Introduction

A considerable minority (about 10%) of patients with anti-neutrophil cytoplasmic antibody-associated small-vessel vasculitis are refractory to conventional therapy or experience dose-limiting side effects. Moreover, despite effective remission of vasculitic disease, a patient's quality of life often remains compromised due to the devastating effects of the current therapies. Novel therapeutic approaches include rituximab, a genetically engineered chimeric murine-human monoclonal antibody that binds to CD20, which is expressed on human B cells and at a low level on a small subset of T cells [1]. Mechanisms of depletion include antibody- and complement-mediated cytotoxicity [2], the latter being probably involved in infusion reactions [3]. Some non-circulating tissue cells seem to bind rituximab but are non-depleted [4]. The role of tissue-restricted depletion-refractory B cells and the CD20-expressing T-cell subset in conditioning rituximab responsiveness is under investigation. Rituximab has been investigated as an optional therapy in small-size-vessel idiopathic systemic angiitis due to the potentially serious toxicities of conventional immunosuppressive agents and because of the need of efficacious therapies for cases who are refractory or intolerant to standard therapy. Two randomized controlled studies have recently supported the efficacy of rituximab in severe cases of ANCA-associated systemic vasculitis [5, 6]. The only limit of these important reports was the relative short time of follow-up. The present open study focused on a small cohort of difficult patients who could not be recruited in controlled studies and represent about 5% of the cases of micropolyangiitis with or without granulomatous phenotype censored by the Piedmont Registry of Rare Diseases between January 2006 and August 2009 [197 patients including 77 cases of systemic microscopic polyangiitis (MPA), 83 Wegener's granulomatoses (WG) and 37 Churg-Strauss syndromes (CS)]. This small percentage came to our tertiary-level center after previous unsuccessful

approaches with a conventional treatment. Our interest focused on the long-term effects of rituximab given prospectively to this selected cohort of patients, following a 4 + 2 infusion protocol we successfully used in other immune-mediated diseases [7–10] . Another novelty of this study was that this intensive treatment was associated with long-lasting remissions despite the absence of maintenance immunosuppressive therapy and a small maintenance dose of prednisone.

Methods

Eleven patients with ANCA-associated vasculitis, 5 women and 6 men, 5 with WG, 4 with MPA, and 2 with CS, mean age 57.5 years (range 35–71), mean disease duration 21.8 months (range 6–80), were deemed eligible for rituximab therapy. Table 1 summarizes the main clinical features of the patients.

Seven patients presented with renal involvement: 6 had a biopsy-proven necrotizing extracapillary paucimmune glomerulonephritis, while 1 case did not undergo renal biopsy because of concomitant anticoagulation

therapy due to the presence of antiphospholipid antibodies. Sinus involvement (with granulomatous lesion in 1 case) and lung nodules were detected in 5 cases, retroorbital granulomata in 2 patients. Biopsy-proven leukocytoclastic vasculitis and large necrotizing skin ulcers were present in 2 cases. Polyneuropathy was observed in 7 patients, while arthralgia and weakness were found in all 9 cases, and fever in 6. Six patients (3 WG: patients No. 5, No. 9, No. 11; 2 MPA: No. 3, No. 4, and 1 CS: No. 7) were found to be resistant to CYC. One more WG patient (No. 10) was in a relapsing phase albeit an elevated cumulative dose of CYC. Another WG patient (No. 6) had a history of severe CYC-induced leukopenia when addressed to our center from another hospital because of a life-threatening disease. A MPA patient (No. 2) could not be treated with CYC because of a sudden pancytopenia after 1 week of oral treatment at the conventional dose (2 mg/kg). One MPA patient (No. 1) and 1 CS CYC-naïve patient (No. 8) refused to accept the risks of infertility related to CYC treatment. Rituximab was administered intravenously at a dose of 375 mg/m² on days 1, 8, 15 and 22. Two more doses were administered 1 and 2 months after the last administration. This scheme was associated with a delayed occurrence of relapses in our own experience in other immune-mediated diseases [7–10] . Premedication included oral anti-histamines, acetaminophen (500 mg) and deflazacort (60 mg unique administration at the first infusion). Response was evaluated by assessing the changes in clinical signs and symptoms and laboratory parameters for at least 12 months. The Birmingham Vasculitis Activity Score (BVAS; at study entry and at 12 months) [11] and the Vasculitis Damage Index (VDI; at study entry) were also measured [12] . Human anti-chimeric antibodies directed against rituximab were quantified using validated antigen-binding tests (RIA), while levels of therapeutic antibodies were assessed using validated ELISA, both performed at Sanquin Diagnostic Services (Amsterdam, The Netherlands) on a routine base. Serum samples were collected 8 weeks after the last drug administration. Due to the low number of patients, mainly descriptive statistical analyses were performed. Differences among study groups were analyzed by multifactorial ANOVA. Differences were considered statistically significant when two-sided p values were < 0.05. Statistical analyses were carried out using StatView 5.0.1 for Macintosh (SAS Institute Inc., Cary, N.C., USA).

Results

Treatment with rituximab resulted in complete depletion of B cells in peripheral blood, as shown by the percentage of CD20-positive cells, diminishing from the pretreatment mean value of 16 to 0.05% 7 days after the first infusion. Rituximab blood levels, measured 8 weeks after the last administration, were undetectable (8 cases) or present in trace amounts (3 patients). Anti-rituximab antibodies were undetectable (< 12 AU/ml) in every case. Significant decreases in erythrocyte sedimentation rate and C-reactive

protein were observed. IgM values also significantly decreased, while IgG declined, after the 6th month (fig. 1). Significant declines were also detected for levels of serum creatinine and proteinuria, while ANCA titers and visual analogue score already decreased at the first month (fig. 1). Constitutional symptoms disappeared or improved, including arthralgia and weakness in all 9 cases and fever in 6 out of 6. Paresthesia has been reported to be improved in 5/7 cases 6 months after rituximab infusions. Of note, the electrophysiologic parameters, checked at the 6th month in 5 cases, improved considerably in 4 of them. Skin ulcers disappeared. Lung nodules improved and completely resolved in 2 cases. Sinus inflammation ameliorated in every case, including the patient with granulomatous lesion. Significant improvement was observed in the Birmingham Vasculitis Activity Score (table 2). Notably, 6 months after rituximab

administration the mean dose of prednisone was 5.5 mg/day, and only 1 patient was assuming immunosuppressive therapy (No. 2, mycophenolate mofetil 500 mg/day, withdrawn at the 7th month). At 1 year of follow-up the mean dose of prednisone was 5 mg/day. No relapses were observed in 9 out of 11 cases during the follow-up (1–30 months). Two patients relapsed. Patient No. 6 presented 18 months after rituximab with malaise, persistent cough, rhinosinusitis and fever associated with high titer of ANCA. Patient No. 8 presented 15 months after rituximab with fever and lung involvement confirmed at CT scan associated with increased levels of ESR and CRP. Because of the good previously obtained results, retreatment with rituximab (infusion on days 1 and 8, with two more doses administered 1 and 2 months after the last administration) was decided in both cases. Both patients showed a complete clinical response again.

Discussion

General experience and results of quoted randomized controlled trials [13–15] indicate that 10% of patients with ANCA-associated vasculitis are cyclophosphamide-resistant. Refractory disease is defined as a persistently active illness despite maximally tolerated cyclophosphamide. However, a number of confounding factors (e.g. features of permanent damage or associated morbidity) are implicated in this definition. Patients undergoing standard immunosuppressive therapy are susceptible to cumulative toxicity derived from both iatrogenic effects – especially in the large proportion of the relapsing course of ANCA-associated

vasculitis – and damage related to the disease itself. Moreover, despite effective remission induction as measured by validated indices of disease activity, due to the devastating effects of current therapies, a patient's perspective of the impact of the disease on her/his life, as scored by specific questionnaire, remains depressed [16]. Infertility and malignancies (especially in the long-term treatment) in the young patient, leukopenia and infections in the elderly make standard immunosuppressive treatment unappealing and the advent of effective and safer forms of management of ANCA-associated vasculitis more than welcome. A major strength of the present study is that it was specifically addressed to the rituximab cost-benefit profile with regard to indicators not only of disease activity, but also of extent of vasculitis damage, in patients with ANCA-associated vasculitis and frequent renal involvement with poorly controlled disease, history of multiple relapses, and treatment with various immunosuppressive agents before rituximab therapy. Our study substantially confirms a number of reports which documented clinical benefits of rituximab given in addition to oral prednisone [17], or immunosuppressive drugs including cyclophosphamide, methotrexate, azathioprine and mycophenolate mofetil [18–21]. In general, rituximab was found to lead to clinical remission by 6 months in over 80% of cases [22]. Non-responders exhibited mostly granulomatous, especially retroorbital, manifestations [21]. This was not the case in our patients, even though the response appeared to be delayed compared to other involved sites. This favorable profile has been recently reported in a retrospective data collection performed from 65 patients receiving rituximab for refractory ANCA-associated vasculitis at four centers in the UK. Patients had at least 6 months of follow-up. Complete remission occurred in 49 of the 65 patients (75%) while 15 patients experienced partial remission. Remission was accompanied by a decrease of prednisone dosage. 38 patients received a second course of rituximab. Of these, 84% experienced a second complete remission. No clear relationship between B-cell repopulation and relapse could be observed [22]. Based on results of open studies, two separated randomized studies were designed to test the efficacy of rituximab as induction therapy compared to standard treatment with cyclophosphamide [5, 6]. There were no differences in sustained remission or adverse events in a relatively short-term follow-up. A 4 + 2 protocol of rituximab administration was used in the present study. This scheme was associated with a delayed occurrence of relapses in our own experience in secondary vasculitis [7–10] where a complete discontinuation of steroids and immunosuppressive drugs was often permitted. This explains the substantial steroid- and immunosuppressive-sparing effects observed in our patients, who remained in remission for at least 30 months in 9 of 11 cases, despite the absence of maintenance immunosuppressive therapy. In 2 patients (Nos. 6 and 8) a second cycle of infusion of rituximab alone (on days 1 and 8, with two more doses 1 and 2 months after the last administration) was given because of worsening of clinical settings. Both the patients showed a complete clinical response after the second cycle with normalization of the clinical and serologic profile. It is still debated if the key mechanism of action of rituximab in vasculitis consists in removing the cellular source of the putative pathogenic autoantibodies. This should presuppose that ANCA are produced

by shortand not long-lived plasma cells [6] . Actually, it seems more likely that rituximab blocks B-celldependent autoimmune arms unrelated to antibody production such as cytokine production, antigen presentation and interactions with T cells and other antigen-presenting cells [23] . Besides, B cells are activated in systemic vasculitis and an expansion of the B-cell compartment, which multiplies the number of antigen-presenting cells and increases the production of a variety of cytokines, has been observed in vasculitis patients [24] . This might explain the longterm effects of rituximab, which often persists beyond the B-cell depletion phase. In a long-term observation period (30–54 months), sustained clinical remission without immunosuppressive maintenance therapy (and a negligible dose of prednisone since the 6th month) was obtained by a 4 + 2 infusion protocol of rituximab in a selected sample of patients with ANCA associated vasculitis intolerant or refractory to conventional therapy.

References

1. Eisenberg R, Looney RJ: The therapeutic potential of anti-CD20 ‘what do B-cells do?’ Clin Immunol 2005;117:207–213.
2. Di Gaetano N, Cittera E, Nota R, Vecchi A, Grieco V, Scanziani E, Botto M, Introna M, Golay J: Complement activation determines the therapeutic activity of rituximab in vivo. J Immunol 2003;171:1581–1587.
3. Cheifetz A, Mayer L: Monoclonal antibodies, immunogenicity, and associated infusion reactions. Mt Sinai J Med 2005;72:250–256.
4. Martin F, Chan AC: B cell immunobiology in disease: evolving concepts from the clinic. Annu Rev Immunol 2006;24:467–496.
5. Jones RB, Tervaert JW, Hauser T, Luqmani R, Morgan MD, Peh CA, Savage CO, Segelmark M, Tesar V, van Paassen P, Walsh D, Walsh M, Westman K, Jayne DR: rituximab versus cyclophosphamide in ANCA associated renal vasculitis. N Engl J Med 2010;363:211– 220.
6. Stone JH, Merkel PA, Spiera R, Seo P, Langford CA, Hoffman GS, Kallenberg CG, St Clair EW, Turkiewicz A, Tchao NK, Webber L, Ding L, Sejismundo LP, Mieras K, Weitzenkamp D, Ikle D, Seyfert-Margolis V, Mueller M, Brunetta P, Allen NB, Fervenza FC, Geetha D, Keogh KA, Kissin EY, Monach PA, Peikert T, Stegeman C, Ytterberg SR, Specks U: Rituximab versus cyclophosphamide for ANCA-associated vasculitis. N Engl J Med 2010;363:221–232.
7. Roccatello D, Baldovino S, Rossi D, Mansouri M, Naretto C, Gennaro M, Cavallo R, Alpa M, Costanzo P, Giachino O, Mazzucco G, Sena LM: Long-term effects of anti-CD20 monoclonal antibody treatment of cryoglobulinaemic glomerulonephritis. Nephrol Dial Transplant 2004;19:3054–3061.
8. Roccatello D, Baldovino S, Rossi D, Giachino O, Mansouri M, Naretto C, Di Simone D, Francica S, Cavallo R, Alpa M, Napoli F, Sena LM: Rituximab as a therapeutic tool in severe mixed cryoglobulinemia. Clin Rev Allergy Immunol 2008;34:111–117.
9. Roccatello D, Sciascia S, Rossi D, Alpa M, Naretto C, Baldovino S, Menegatti E, La Grotta R, Modena V: Intensive short-term treatment with rituximab, cyclophosphamide and methylprednisolone pulses induces remission in severe cases of SLE with nephritis and avoids further immunosuppressive maintenance therapy. Nephrol Dial Transplant 2011 (Epub ahead of print).
10. Cavallo R, Roccatello D, Menegatti E, Naretto C, Napoli F, Baldovino S: Rituximab in cryoglobulinemic peripheral neuropathy. J Neurol 2009;256:1076–1082.
11. Mukhtyar C, Lee R, Brown D, Carruthers D, Dasgupta B, Dubey S, Flossmann O, Hall C, Hollywood J, Jayne D, Jones R, Lanyon P, Muir A, Scott D, Young L, Luqmani RA: Modification and validation of the Birmingham Vasculitis Activity Score (version 3). Ann Rheum Dis 2009;68:1827–1832.
12. Mohammad AJ, Bakoush O, Sturfelt G, Segelmark M: The extent and pattern of organ damage in small vessel vasculitis measured by the Vasculitis Damage Index. Scand J Rheumatol 2009;38:268–275.
13. Jayne D, Rasmussen N, Andrassy K, Bacon P, Tervaert JW, Dadoniené J, Ekstrand A, Gaskin G, Gregorini G, de Groot K, Gross W, Hagen EC, Mirapeix E, Pettersson E, Siegert C, Sinico A, Tesar V, Westman K, Pusey C: A randomized trial of maintenance therapy for vasculitis associated with antineutrophil cytoplasmic autoantibodies. N Engl J Med 2003;349:36–44.
14. Wegener’s Granulomatosis Etanercept Trial (WGET) Research Group: Etanercept plus standard therapy for Wegener’s granulomatosis. N Engl J Med 2005;352:351–361.

15. De Groot K, Rasmussen N, Bacon PA, Tervaert JW, Feighery C, Gregorini G, Gross WL, Luqmani R, Jayne DR: Randomized trial of cyclophosphamide versus methotrexate for induction of remission in early systemic antineutrophil cytoplasmic antibody-associated vasculitis. *Arthritis Rheum* 2005;52: 2461–2469.
16. Carruthers D, Bacon P: Activity, damage and outcome in systemic vasculitis. *Best Pract Res Clin Rheumatol* 2001;15:225–238 .
17. Keogh KA, Ytterberg SR, Fervenza FC, Carlon KA, Schroeder DR, Specks U: rituximab for refractory Wegener's granulomatosis: report of a prospective, open-label pilot trial. *Am J Respir Crit Care Med* 2006;173:180– 187.
18. Eriksson P: Nine patients with anti-neutrophil cytoplasmic antibody-positive vasculitis successfully treated with rituximab. *J Intern Med* 2005;257:540–548.
19. Gottenberg JE, Guillevin L, Lambotte O, Combe B, Allanore Y, Cantagrel A, Larroche C, Soubrier M, Bouillet L, Dougados M, Fain O, Farge D, Kyndt X, Lortholary O, Masson C, Moura B, Remy P, Thomas T, Wendling D, Anaya JM, Sibilia J, Mariette X: Tolerance and short-term efficacy of rituximab in 43 patients with systemic autoimmune diseases. *Ann Rheum Dis* 2005;64:913–920.
20. Omdal R, Wildhagen K, Hansen T, Gunnarsson R, Kristoffersen G: Anti-CD20 therapy of treatmentresistant Wegener's granulomatosis: favourable but temporary response. *Scand J Rheumatol* 2005;34:229–232.
21. Aries PM, Hellmich B, Voswinkel J, Both M, Nölle B, Holl-Ulrich K, Lamprecht P, Gross WL: Lack of efficacy of rituximab in Wegener's granulomatosis with refractory granulomatous manifestations. *Ann Rheum Dis* 2006;65:853–858.
22. Bosch X, Guilabert A, Espinosa G, Mirapeix E: Immunotherapy for antineutrophil cytoplasmic antibodyassociated vasculitis: challenging the therapeutic status quo? *Trends Immunol* 2008;29:280–289.
23. Mitchison NA: T-cell–B-cell cooperation. *Nat Rev Immunol* 2004;4:308–312.
24. Lamprecht P, Till A, Steinmann J, Aries PM, Gross WL: Current state of biologicals in the management of systemic vasculitis. *Ann N Y Acad Sci* 2007;1110:261–270.

Table 1. Demographic and clinical characteristics of patients at baseline

Pa-tient	Age years	Gen-der	Disease du-ration be-fore RTX months	Diag-nosis	Previous treatment	Cumulative dose of CYC/ methylprednisolone/ prednisone, mg	Active organ involvement at entry	VDI	BVAS at entry
1	43	M	6	MPA	MMP, MTX, SP, IVIG, PE	–/4,000/3,750	K, PNS, J, F, S, W	18	29
2 ^a	71	F	6	MPA	MMP, SP, CYC	830/3,000/3,250	K, F, W	9	20
3 ^b	67	M	18	MPA	Oral CYC, SP	15,000/3,000/6,400	K, J, W	7	15
4 ^b	75	F	24	MPA	Oral CYC, SP	20,000/4,000/7,250	PNS, J, F	6	15
5 ^b	73	M	32	WG	MMP, SP, CYC	4,500/4,000/7,250	K, PNS, J, F, W	6	11
6 ^b	66	F	10	WG	MMP, SP, IVIG, CYC	4,300/4,000/4,750	K, L, F, W, PNS, J, Mu, UA	8	12
7 ^b	64	M	12	CS	CYC, SP, IVIG	4,500/3,000/6,150	PNS, S, J, H, W	13	28
8	35	M	10	CS	Steroid	–/6,000/5,500	L, F, W, J	8	26
							UA	9	25
9 ^b	50	M	32	WG	CYC, steroid, MTX, anti-TNF	4,000/3,000/9,600	PNS, W, J, UA	7	18
10 ^b	49	F	80	WG	SP, CYC, AZA, CyA	6,500/6,000/22,000	K, W, J, PNS, UA	8	27
11 ^b	68	F	10	WG	SP, oral CYC, IVIG, PE	10,000/3,000/2,850	K, UA, CNS, L	9	20

RTX = Rituximab; MMP = mycophenolate mofetil; MTX = methotrexate; IVIG = intravenous immunoglobulin; AZA = azathioprine; CYC = cyclophosphamide (oral or intravenous); PE = plasma exchange; SP = steroid pulses, methylprednisolone 15 mg/kg/day for 3 consecutive days; CyA = cyclosporin A; K = kidney; PNS = peripheral nervous system; CNS = central nervous system; J = joints; F = fever; S = skin; W = weakness; UA = upper airways (ears, nose, throat); Mu = muscle; H = heart; L = lung; MPA = microscopic polyangiitis; WG = Wegener's granulomatosis; CS = Churg-Strauss syndrome. ^a CYC-intolerant; ^b CYC-resistant.

Fig. 1. Biochemical profiles of 11 patients with ANCA-associated idiopathic vasculitis with multiorgan involvement who had undergone a 4 + 2 infusion protocol of rituximab (375 mg/m²). ESR = Erythrocyte

sedimentation rate; CRP = C-reactive protein; IgM = immunoglobulin M; IgG = immunoglobulin G; sCr = serum creatinine; ANCA = anti-neutrophil cytoplasm antibody; VAS = visual analogue score. * $p < 0.05$, ** $p < 0.01$, and *** $p < 0.001$ as calculated with the one-way ANOVA test and Dunnett's multiple-comparison post test.

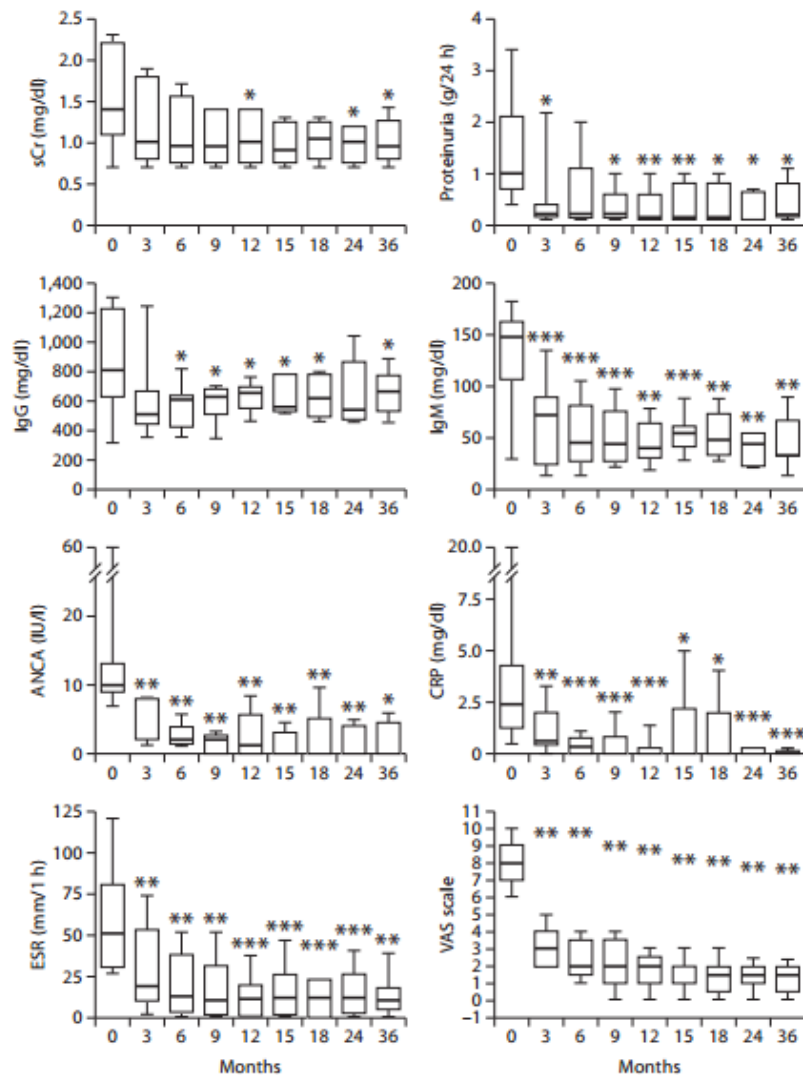


Table 2. Clinical characteristics of patients treated with rituximab in follow-up after treatment

Patient	Follow-up after rituximab administration, months	Therapy still administered at 6 months following rituximab, mg	BVAS after 12 months
1	44	PRE 5	3
2	54	PRE 5, MMP 500 ^a	3
3	36	PRE 5	2
4	30	PRE 5	6
5	52	PRE 5	2
6	18 (1st cycle)	PRE 5	2
	55 (2nd cycle)	PRE 5	
7	35	PRE 10	6
8	15 (1st cycle)	PRE 5	3
	36 (2nd cycle)	PRE 5	3
9	30	PRE 5	3
10	40	PRE 5	3
11	36	PRE 5	3