IRIS AperTO

UNIVERSITÀ DEGLI STUDI DI TORINO

AperTO - Archivio Istituzionale Open Access dell'Università di Torino

Regulatory T cells as well as IL-10 are reduced in the skin of patients with dermatitis herpetiformis

This is the author's manuscript

Original Citation:

Availability:

This version is available http://hdl.handle.net/2318/1569513 since 2016-06-21T13:16:33Z

Published version:

DOI:10.1016/j.jdermsci.2014.11.003

Terms of use:

Open Access

Anyone can freely access the full text of works made available as "Open Access". Works made available under a Creative Commons license can be used according to the terms and conditions of said license. Use of all other works requires consent of the right holder (author or publisher) if not exempted from copyright protection by the applicable law.

(Article begins on next page)

12 October 2024

This Accepted Author Manuscript (AAM) is copyrighted and published by Elsevier. It is posted here by agreement between Elsevier and the University of Turin. Changes resulting from the publishing process - such as editing, corrections, structural formatting, and other quality control mechanisms - may not be reflected in this version of the text. The definitive version of the text was subsequently published in JOURNAL OF DERMATOLOGICAL SCIENCE, 77 (1), 2015, 10.1016/j.jdermsci.2014.11.003.

You may download, copy and otherwise use the AAM for non-commercial purposes provided that your license is limited by the following restrictions:

(1) You may use this AAM for non-commercial purposes only under the terms of the CC-BY-NC-ND license.

(2) The integrity of the work and identification of the author, copyright owner, and publisher must be preserved in any copy.

(3) You must attribute this AAM in the following format: Creative Commons BY-NC-ND license (http://creativecommons.org/licenses/by-nc-nd/4.0/deed.en), 10.1016/j.jdermsci.2014.11.003

The publisher's version is available at:
http://linkinghub.elsevier.com/retrieve/pii/S0923181114002564

When citing, please refer to the published version.

Link to this full text:
http://hdl.handle.net/2318/1569513

This full text was downloaded from iris - AperTO: https://iris.unito.it/

iris - AperTO

University of Turin's Institutional Research Information System and Open Access Institutional Repository

Regulatory T cells as well as IL-10 are reduced in the skin of patients with dermatitis herpetiformis

Emiliano Antiga, Pietro Quaglino, Ilaria Pierini, Walter Volpi, Gabriele Lami, Beatrice Bianchi, Elena Del Bianco, Daniela Renzi, Gianna Baroni, Mauro Novelli, Renata Ponti, Manuela Papini, Simonetta Di Lollo, Antonino Salvatore Calabrò, Paolo Fabbri, Marzia Caproni

Abstract

Background

Dermatitis herpetiformis (DH) and celiac disease (CD) are considered as autoimmune diseases that share a defined trigger (gluten) and a common genetic background (HLA-DQ2/DQ8). However, the pathogenesis of DH is not fully understood and no data are available about the immune regulation in such a disease.

Objective

The aim of this study was to assess if alterations in the pattern of the immune response and, in particular, impairments of regulatory T (Tregs) cells may contribute to the phenotypic differences between DH and CD.

Methods

We investigated the presence of Tregs cell markers, in the skin, the duodenum and the blood of patients with DH by immunohistochemistry, confocal microscopy and flow cytometry. As controls, we included patients with bullous pemphigoid, patients with CD without skin lesions, as well as healthy subjects (HS).

Results

In the skin of DH patient, we found a significantly lower proportion of $FOXP3^+$ Tregs and $IL\text{-}10^+$ cells than in HS ($p < 0.001$ for both cell populations). In duodenal samples, no differences where found in the proportion of Tregs between patients with DH and patients with CD without skin manifestations. Finally, the frequency of $CD25^{bright}FOXP3^+$ cells within the $CD4^+$ subset was significantly reduced in CD patients either with or without DH with respect to HS ($p = 0.029$ and $p = 0.017$, respectively).

Conclusions

Our findings suggested that a reduction of Tregs may play a major role in the skin, leading to a defective suppressive function and thus to the development of the lesions. By contrast, no differences could be detected about Tregs between patients with DH and patients with CD in the duodenum, suggesting that the mechanisms of the intestinal damage are similar in both diseases.

Abbreviations

- BP, bullous pemphigoid;
- CD, celiac disease;
- DH, dermatitis herpetiformis;
- FOXP3, forkhead box P3;
- HS, healthy subjects;
- TG3, epidermal transglutaminase;
- Tregs, regulatory T cells

1. Introduction

Dermatitis herpetiformis (DH) is the specific cutaneous manifestation of celiac disease (CD) [1] and [2]. Both diseases are characterized by a defined trigger (gluten), the presence of HLA-DQ2/DQ8, and the generation of circulating autoantibodies to tissue transglutaminase (TG2). TG2 deamidates certain gluten peptides, increasing their affinity to HLA-DQ2 or -DQ8 [1]. This generates a more vigorous $CD4^+$ T-cell activation, which can result in intestinal mucosal inflammation, malabsorption, and numerous extraintestinal symptoms as well as autoimmune diseases [3].

A possible clue to the pathogenesis of DH could be represented by epidermal transglutaminase (TG3) [4] and [5]. In particular, a study by Sardy et al. [6] suggested that TG3 might be considered the autoantigen of DH, since it has been shown to colocalize with IgA deposits in the skin and circulating anti-TG3 antibodies have been found in the blood of patients with DH. Moreover, DH lesions seem to show a prominent T helper 2 cell polarization, that contributes to the recruitment of other proinflammatory cells such as neutrophils and, thus, to the development of skin damage [7]. However, the differences in the T cell response and in its regulation between DH and CD are yet to be elucidated.

In the field of autoimmune skin diseases, growing attention is currently paid to the role of regulatory T cells (Tregs) [8]. Tregs are characterized by the expression of FOXP3, that is still considered the most specific marker of such cell population [9]. Moreover, they are able to produce regulatory cytokines such as TGF-β and IL-10 [10]. Depletion of Tregs contributes to the induction of severe autoimmune disease in animal models, and several studies have demonstrated a deficiency in the number of Tregs and/or function in various human autoimmune disorders, including an autoimmune blistering disease such as bullous pemphigoid (BP) [11], [12] and [13].

To date, no data are present in the literature about Tregs in patients with DH, while several studies have investigated such cells in CD, with contrasting results. In fact, although some Authors found augmented percentages of duodenal Tregs in CD [14], other papers showed no differences in the blood if compared to healthy subjects (HS) [15] and [16]. In the duodenum of celiac patients, the absolute number of Tregs is higher than that found in HS [17] and [18]. Despite their number, some studies showed that Tregs have a defective suppressive activity in celiac patients [16] and [19].

In order to assess whether similar alterations of the immune regulation to those operating in CD can be responsible for the development of celiac-specific skin lesions, in the present study we investigated the proportions of Tregs in the skin, the duodenum and the blood of patients with DH.

2. Materials and methods

2.1. Patients

Twenty-four patients with DH (11 males and 13 females, age range 17–54 years) were included in the study. All of them had typical clinical and histological features of DH; the diagnosis was confirmed by direct immunofluorescence of uninvolved skin, which demonstrated granular deposits of IgA at the dermal papillae. None of the patients were on a gluten free diet.

A 4-mm punch biopsy from lesional skin was taken from 10 patients and a duodenal biopsy from 6 patients. Blood samples were collected from all the patients.

As control, samples from 10 patients with BP (5 males and 5 females, age range 37–68 years), 1 patients with CD without skin involvement (5 males and 7 females, age range 24–47 years) and 30 HS (14 males and 16 females, age range 21–67 years) were collected. All the controls were neither on therapy nor on gluten free diet.

Skin samples from HS were collected during nevi excision. Duodenal samples were taken from HS underwent gastro-duodenal endoscopy for diagnostic purposes and showing normal histopathological findings.

The patients and controls were recruited from Dermatology Departments belonging to the Italian Group for Cutaneous Immunopathology between May 2010 and April 2012. The study was approved by the Ethic Committee of Azienda Sanitaria Firenze, Florence, Italy and by local committees of all the centres involved in the study. All the patients provided written informed consent.

2.2. Reagents for immunohistochemical stainings and confocal microscopy

The monoclonal antibodies used for immunohistochemistry included: anti-CD4 (1:20; DAKO, Carpinteria, CA, USA); anti-CD25 (1:25; Histo-Line Laboratories, Milan, Italy); anti-FOXP3 (1:80; Abcam, Cambridge, UK); anti-IL10 (1:300; DAKO); anti-TGFβ1 (1:2000; Abcam).

2.3. Immunohistochemical analysis of the skin specimens

The expression of different Tregs markers was analyzed in serial sections of lesional skin biopsy specimens of 10 DH and 10 BP patients, as well as in healthy skin of 6 HS using single immunohistochemical staining as described previously [20].

Briefly, skin specimens were immediately frozen and stored at −80 °C until used. Sequential cryostat sections (5 µm) were air dried and fixed in 100% acetone. We used the system EnVision + System-HRP (DAKO). According to the protocols, sections were washed in Tris-buffered saline, coated with peroxidase block for 5 min, rinsed gently and then incubated with primary antibodies for 30 min. After washing, sections were incubated with peroxidase labelled polymer for 30 min, rinsed and then processed with substrate-chromogen. Sections were then counterstained with Mayer's haematoxylin, cleared and mounted. Negative controls were subjected to the same treatment but the passage with the primary antibody has been omitted.

Two independent “blind” observers evaluated the slides. For quantitative analysis, the stained cells were counted in three consecutive microscopic fields (400×). Furthermore, for each patient, $FOXP3^+/CD4^+$, TGF-$\beta^+/CD4^+$ and $IL\text{-}10^+/CD4^+$ cell ratios were calculated by counting the absolute number of positively stained cells in serial sections from the same skin biopsy specimen.

2.4. Immunohistochemistry of the duodenal specimens

Biopsy specimens from the duodenum taken from 6 patients with DH, 7 with CD without skin involvement, and 3 HS were fixed in formalin. Immunohistochemical staining was performed on 3-µm thick serial sections cut from paraffin-embedded tissues.

Tissue sections were deparaffined in Bio-Clear (Bio-Optica, Milan, Italy), hydrated with an ethanol concentration gradient followed by distilled water and placed in 3% hydrogen peroxide/H_2O_2 for blocking endogenous peroxidase. Antigen retrieval was performed by calibrated water bath capable of maintaining the Epitope Retrieval Solution (EDTA pH 9) at 98 °C for 30 min and was followed by incubation with mouse monoclonal antibodies (anti-FOXP3, anti-IL-10, and anti-TGFb1). Antibody binding was visualized using EnVision™ Detection System Peroxidase (DAKO) with DAB as chromogen. Additional sections from the same patients were placed on the Ventana automated stainer BenchMark XT™ ICH system, deparaffined, rehydrated and processed for blocking endogenous peroxidase and epitope retrieval. Primary anti-CD4 and anti-CD25 mAb were placed on tissue sections and incubated for 32 min at 37 °C using ultraView Universal DAB Detection Kit as revelation system. A negative control was included with each run by omitting the

primary antibody with non-immune serum at the same concentration. Tissue sections were counterstained with Mayer's haematoxylin, dehydrated and mounted with Permount.

Two independent "blind" observers evaluated the slides. For quantitative analysis, the stained cells were counted in three consecutive microscopic fields (400×). Furthermore, for each patient, $FOXP3^+/CD4^+$, TGF-$\beta^+/CD4^+$ and $IL\text{-}10^+/CD4^+$ cell ratios were calculated by counting the absolute number of positively stained cells in serial sections from the same skin biopsy specimen.

2.5. Confocal microscopy

About 10-µm serial sections of fresh frozen skin biopsies from 6 patients with DH, 5 patients with PB, and 5 HS were investigated for CD4, FOXP3, and IL-10 as previously described [21]. As positive controls, the skin specimens of 3 patients with psoriasis were stained. Frozen sections were fixed with ice cold acetone then blocked with 0.25% casein in Tris-buffered saline (TBS; 0.88% NaCl, ThermoFisher, 0.24% tris(hydroxymethyl) aminomethane, and distilled water). Primary antibodies against human CD4, FOXP3, and IL-10 were prepared in TBS containing 1% FCS and incubated on sections for 1 h at room temperature. Secondary antibodies against mouse isotypes IgG2a DyLight 488 (poly24092, BioLegend, San Diego, CA, USA) and IgG2b AlexaFluor 555 (Molecular Probes, Eugene, OR, USA) at 1:200 each were prepared and incubated on sections for 1 h. Sections were visualized with Nikon C2 confocal microscope.

2.6. Flow cytometry

Peripheral blood lymphocytes from 24 patients with DH, 12 patients with CD without skin involvement, and 30 HS were evaluated according to their immunofluorescence reactivity using FACSCalibur/FACSCanto™ II cytometers and analyzed with CellQuest/FACSDiva (Becton-Dickinson, San Josè, CA, USA). Surface markers were performed by four- or six-colour immunofluorescence analyses, using simultaneously antibodies conjugated to FITC, PE, PerCP or PerCP Cy5.5, Pe-Cy7, APC and APC-H7. At least 10,000 lymphocytes were collected for each antibody combination. Lymphocyte purity was verified by standard forward and sideways scattering parameters, using a CD45 gating analysis. The following MoAbs were analyzed: CD3 FITC, PerCP Cy5.5 or APC-H7 (SK7, mouse IgG1), CD4 PerCP or V450 (SK3, mouse IgG1) CD8 APC-H7 (SK1, mouse IgG1), CD25 PE or APC (M-A251, mouse IgG1), all purchased from BD Biosciences (San Diego, CA, USA).

The $CD4^+CD25^+$ population can be divided into two different levels of expression, i.e. low CD25 level (defined $CD4^+CD25^{low}$) and high CD25 level (defined $CD4^+CD25^{bright}$) that appear to have a tail to the right of the major population containing both $CD4^+CD25^{low}$ and $CD4^+CD25^-$cells. FOXP3 expression was analyzed using mononuclear cells purified from peripheral blood using Lymphoprep (1.077 g mL; Axis-Shield, Oslo, Norway) density gradient centrifugation. The cells were incubated with surface antibodies, anti-CD4 PerCP or PE-Cy7 and anti-CD25 APC for 10 min at room temperature, then stained with anti-FOXP3 PE (clone PCH101, rat IgG2a; eBiosciences, San Diego, CA, USA), using fixation and permeabilization buffers from the same provider. Tregs values were determined as the percentage of $CD25^{bright}FOXP3^+$ within the $CD3^+CD4^+$ compartment.

2.7. Statistical analysis

The results are presented as medians [25th–75th percentile]. Both the Mann–Whitney *U* test and the Kruskal–Wallis with Dunn post hoc test was used to compare the number of Tregs in peripheral blood of patients and HS and the results of the immunohistochemical and confocal microscopy analysis, giving similar results. Results were considered significant with a p value < 0.05.

3. Results

3.1. Immunohistochemical analysis of the skin specimens (Table 1)

$CD4^+$ and $CD25^+$ cells were located in the superficial dermis in patients with DH (Fig. 1), while in BP such cells were detected also in the medium/deep dermis; moreover, in HS, only few $CD4^+$ cells could be found and $CD25^+$ cells were virtually absent. The number of both $CD4^+$ and $CD25^+$ cells in DH was significantly lower than that found in BP ($p = 0.001$ and $p = 0.002$, respectively) and higher than in HS ($p < 0.001$ and $p < 0.001$, respectively)(Fig. 2).

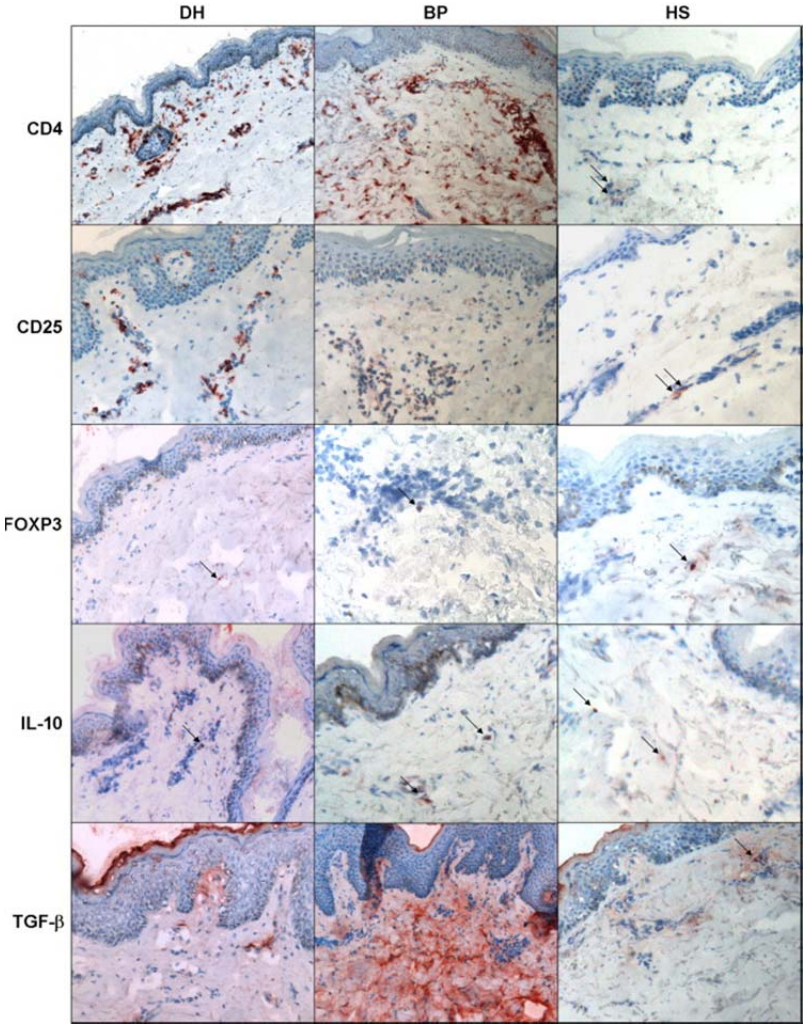

Fig. 1.

Immunohistochemistry in the skin. Immunohistochemical staining for Tregs markers in skin biopsy specimens from patients with dermatitis herpetiformis (DH), bullous pemphigoid (BP), as well as from healthy subjects (HS). Positive cells are mainly distributed within the superficial dermis.

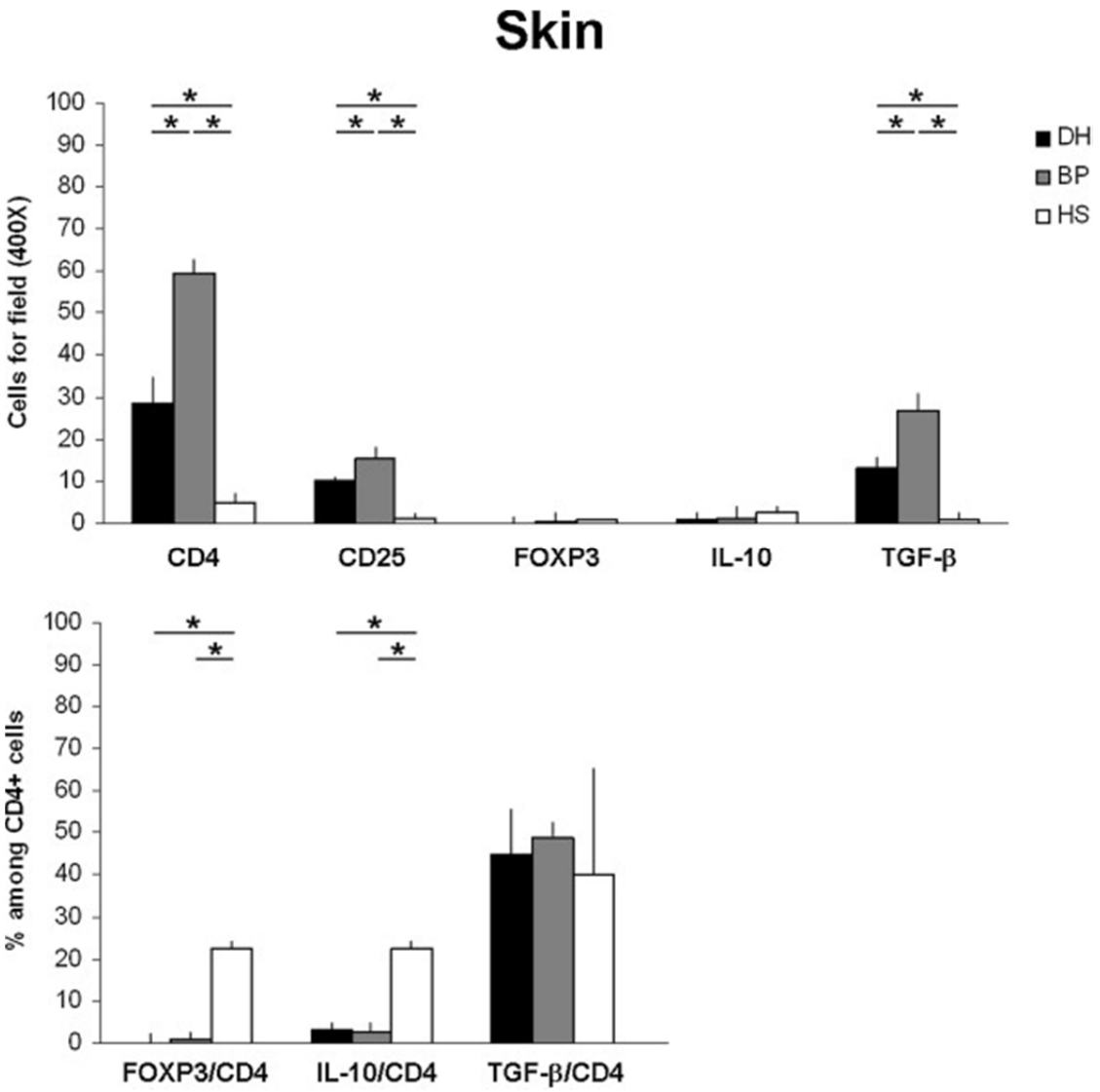

Fig. 2.

Cell counts as well as cell ratios in the skin specimens. Numbers of $CD4^+$, $CD25^+$, $FOXP3^+$, $IL\text{-}10^+$, and TGF-β^+ cells expressed as medians, as well as FOXP3/CD4, IL-10/CD4, and TGF-β/CD4 cell ratios expressed as % of $CD4^+$ cells in the inflammatory infiltrate of skin biopsy specimens from patients with dermatitis herpetiformis (DH), bullous pemphigoid (BP) and healthy subjects (HS). *$p < 0.05$.

Table 1. Quantitative analysis on the numbers of positive cells for field (400×) in skin lesions of dermatitis herpetiformis patients and controls as assessed by immunohistochemistry.

	DH	BP	HS
CD4	28.5 [23.5–35.7]	59.5 [53.2–63.5]	5 [4.2–7.2]
CD25	10 [6.2–11]	15.5 [13.2–18.5]	1.5 [1,2]
FOXP3	0 [0–1]	0.5 [0–1.7]	1 [1]
TGF-β	13 [11.2–16.2]	27 [20–31.5]	2.5 [2,3]
IL-10	1 [0–1.7]	1.5 [0.2–3]	1 [1]
% FOXP3/CD4	0 [0–2.7]	0.9 [0–2.8]	22.5 [20–25]
% TGF-β/CD4	45 [37.7–56]	49 [36.4–53.4]	40 [38.1–66.2]
% IL-10/CD4	3 [0–4.9]	2.8 [0.4–4.7]	22.5 [14.4–25]

Positive-cell counts are expressed as medians [25th–75th percentile]. DH, dermatitis herpetiformis; BP, bullous pemphigoid; HS, healthy subjects.

Very few FOXP3$^+$ cells were detected within the superficial dermis of patients with DH, BP, and HS (Fig. 1), without significant difference in their absolute number. By contrast, the FOXP3$^+$/CD4$^+$ cell ratio, that represents the frequency of FOXP3$^+$ cells expressed as the percentage of CD4$^+$ cells, was significantly lower in DH and BP specimens compared to HS ($p < 0.001$ and $p < 0.001$, respectively) (Fig. 2).

Finally, in order to increase the specificity of the detection of Tregs, double stained CD4$^+$FOXP3$^+$ cells were investigated by confocal microscopy. According to the immunohistochemical study, very few double positive CD4$^+$FOXP3$^+$ could be detected in DH lesions (Fig. 3).

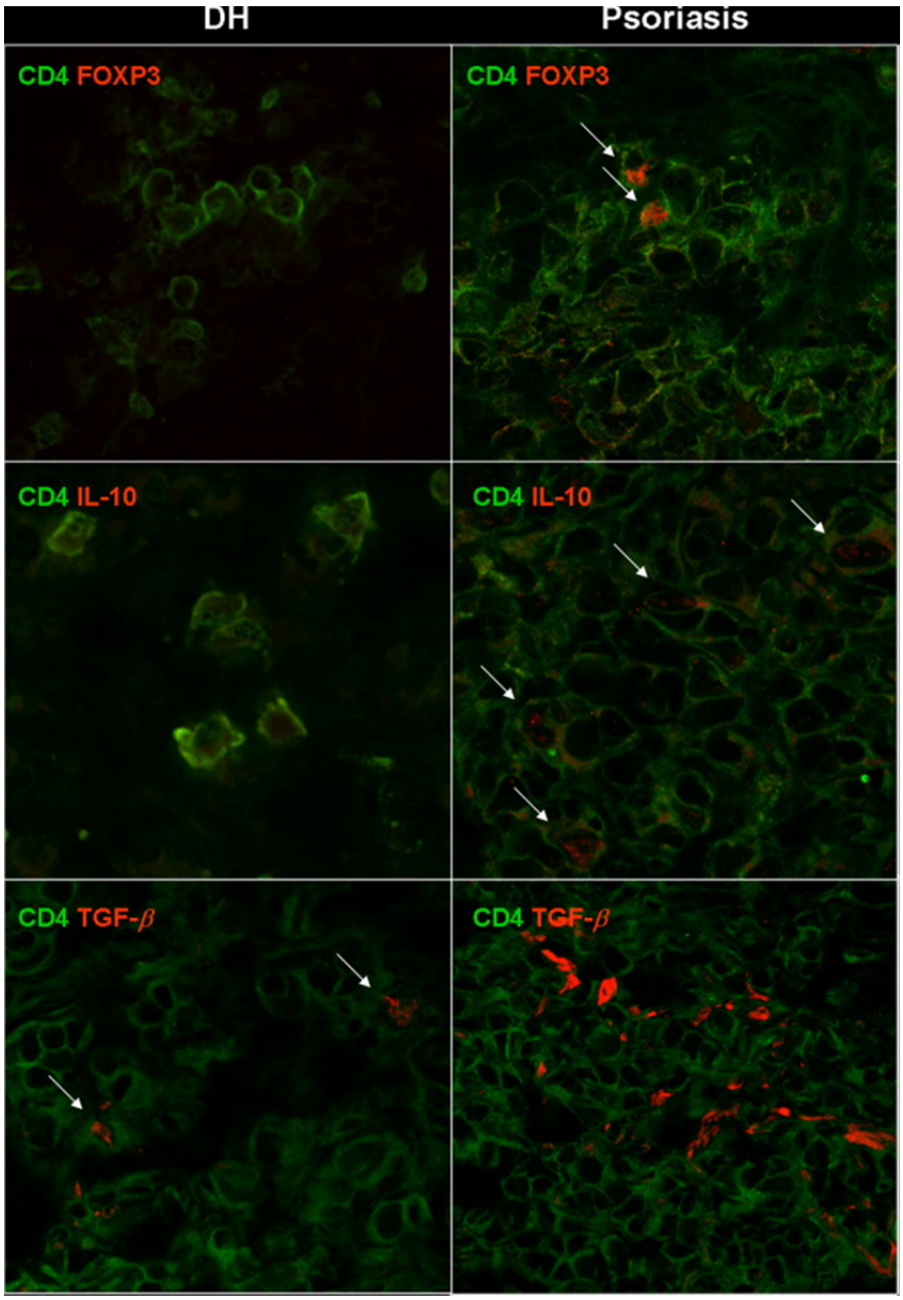

Fig. 3.

Confocal microscopy of the skin specimens. Confocal microscopy was used to detect double positive CD4$^+$FOXP3$^+$, CD4$^+$IL-10$^+$ and CD4$^+$TGF-β$^+$ cells in patients with dermatitis herpetiformis (DH); skin specimens from patients with psoriasis where used as positive control. In the pictures, no CD4$^+$FOXP3$^+$ cells are present, while a double positive CD4$^+$IL-10$^+$ cell and some CD4$^+$TGF-β$^+$ cells can be seen within the superficial dermis in patients with DH. More double stained cells can be observed in psoriasis skin.

TGF-β^+ cells were located in the superficial dermis of DH skin (Fig. 1). Their number was significantly lower compared to that found in BP lesions ($p < 0.001$) but significantly higher than in HS ($p < 0.001$). However the TGF-β^+/CD4$^+$ cell ratio did not show significant differences between the three groups (Fig. 2). Some CD4$^+$ TGF-β^+ cells were detected in DH lesions at confocal microscopy analysis (Fig. 3).

Very few IL-10$^+$ cells were found in the superficial dermis of DH (Fig. 1), without differences if compared with the other groups. By contrast, the IL-10/CD4$^+$ cell ratio in DH and BP skin was significantly lower than that found in HS ($p < 0.001$) (Fig. 2).

Finally, very few double positive CD4$^+$IL-10$^+$ cells could be detected by confocal microscopy in DH skin (Fig. 3).

3.2. Immunohistochemical analysis of the duodenal specimens (Table 2)

As for the skin, Tregs markers were investigated also in the duodenal samples of patients with DH (Fig. 4), and the results were compared to those found in patients with CD without skin involvement, and in HS (Fig. 5).

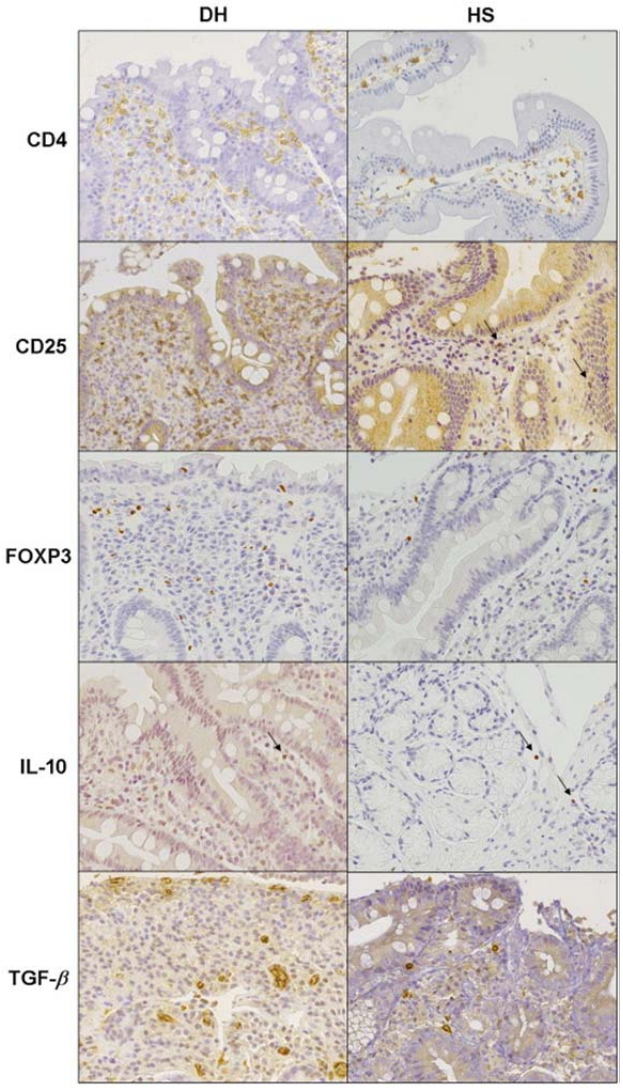

Fig. 4.

Immunohistochemistry in the duodenum. Immunohistochemical staining for Tregs markers in duodenum specimens from patients with dermatitis herpetiformis (DH) as well as from healthy subjects (HS). Positive cells are mainly located in the lamina propria.

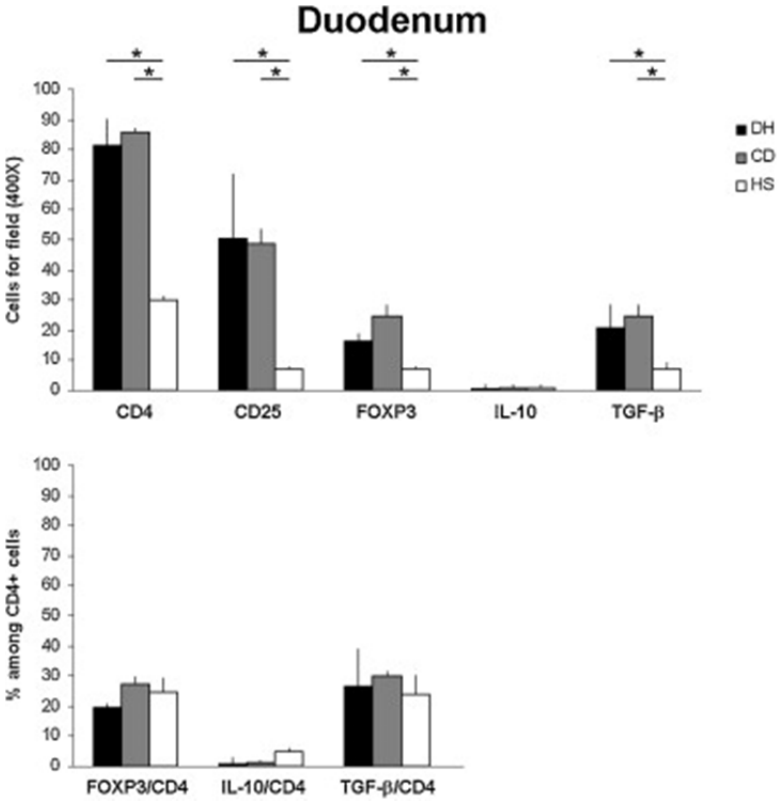

Fig. 5.

Cell counts as well as cell ratios in the duodenal specimens. Numbers of $CD4^+$, $CD25^+$, $FOXP3^+$, IL-10^+, and TGF-β^+cells expressed as medians, as well as FOXP3/CD4, IL-10/CD4, and TGF-β/CD4 cell ratios expressed as % of $CD4^+$ cells in the inflammatory infiltrate of duodenal specimens from patients with dermatitis herpetiformis (DH), celiac disease without skin lesions (CD), and healthy subjects (HS). *$p < 0.05$.

Table 2. Quantitative analysis on the numbers of positive cells for field (400×) in duodenal lesions of dermatitis herpetiformis patients and controls as assessed by immunohistochemistry.

	DH	CD	HS
CD4	81.5 [71–90.5]	86 [84.8–86.3]	30 [25.5–31]
CD25	50.5 [39.8–72.5]	48.5 [44.3–54]	7 [7–7.5]
FOXP3	16.5 [13.8–19.3]	25 [21.3–28]	7 [6.5–7.5]
TGF-β	21 [20.3–27.8]	25 [21.8–28]	7 [6–9]
IL-10	0.5 [0–2.5]	1 [0.8–1.3]	1 [1–1.5]
% FOXP3/CD4	19.3 [18.1–21.2]	27.6 [24.7–30.2]	25 [22.5–29]
% TGF-β/CD4	26.7 [23.9–31.5]	29.9 [26.5–32.5]	23.8 [22.9–30.3]
% IL-10/CD4	0.7 [0–3.3]	1.2 [0.8–1.5]	4.8 [4–5.8]

Positive-cell counts are expressed as medians [25th–75th percentile]. DH, dermatitis herpetiformis; CD, celiac disease; HS, healthy subjects.

Several $CD4^+$ cells were detected in the lamina propria of duodenal specimens of patients with DH (Fig. 4). Their number was similar to that found in patients with CD, but significantly higher than in HS ($p < 0.001$) (Fig. 5).

Similar results were found about CD25 staining. In particular, $CD25^+$ cells were highly represented within the duodenal specimens of DH patients (Fig. 4) and their number overlapped that of patients with CD (Fig. 4). Moreover, as for CD4, HS showed a lower number of $CD25^+$ cells than patients with DH ($p < 0.001$) (Fig. 5).

Finally, $FOXP3^+$ cells were scattered in the lamina propria of both patients with DH and controls (Fig. 4). Interestingly, their number was higher in DH and CD than in HS (DH vs HS: $p = 0.008$; CD vs HS: $p = 0.006$) (Fig. 5). By contrast, the $FOXP3^+/CD4^+$ cell ratio was similar in the two groups of patients as well as in HS (Fig. 5).

Regarding the expression of the regulatory cytokines TGF-β and IL-10, few differences could be detected between patients with DH and controls. In particular, although the absolute number of $TGF\text{-}\beta^+$ cells was higher in patients with DH and patients with CD than in HS (DH vs HS: $p = 0.006$; CD vs HS: $p = 0.005$), the $TGF\text{-}\beta^+/CD4^+$ cell ratio was similar in all the groups (Fig. 5).

Similarly, no differences in both $IL\text{-}10^+$ cell number as well as in $IL\text{-}10^+/CD4^+$ cell ratio were found in both patients and controls (Fig. 5).

3.3. Flow cytometry (Table 3)

No differences in the values of circulating $CD3^+CD4^+$, $CD3^+CD8^+$ subsets were found between CD patients with or without DH, and HS. Similarly, the $CD3^+CD4^+/CD3^+CD8^+$ ratio did not differ significantly between the three groups.

Table 3. Flow-cytometry values of the T cell subsets studied in the peripheral blood.

	DH	CD without DH	HS
$CD3^+CD4^+$	44.5 [40–52]	44.4 [38.6–45.2]	41 [36–44]
$CD3^+CD8^+$	28.5 [23.3–35.9]	28.3 [26.6–33.7]	25 [20.5–28]
$CD3^+CD4^+/CD3^+CD8^+$	1.3 [0.9–1.8]	1.5 [1.1–1.7]	1.5 [1.3–1.8]
$CD25^{bright}FOXP3^+$ % of $CD4^+$	1.9 [1.5–2.9]	2 [1.2–3.9]	3.9 [3.4–4.3]

Data are expressed as % medians [25th–75th percentile]. DH, dermatitis herpetiformis; CD, celiac disease; HS, healthy subjects.

On the other hand, the frequency of $CD25^{bright}FOXP3^+$ cells within the $CD4^+$ subset was significantly reduced in CD patients either with or without DH with respect to HS ($p = 0.029$ and $p = 0.017$, respectively) (Fig. 6). Finally, no differences were found between patients with DH and those with CD, in the distribution of all the cell subsets studied.

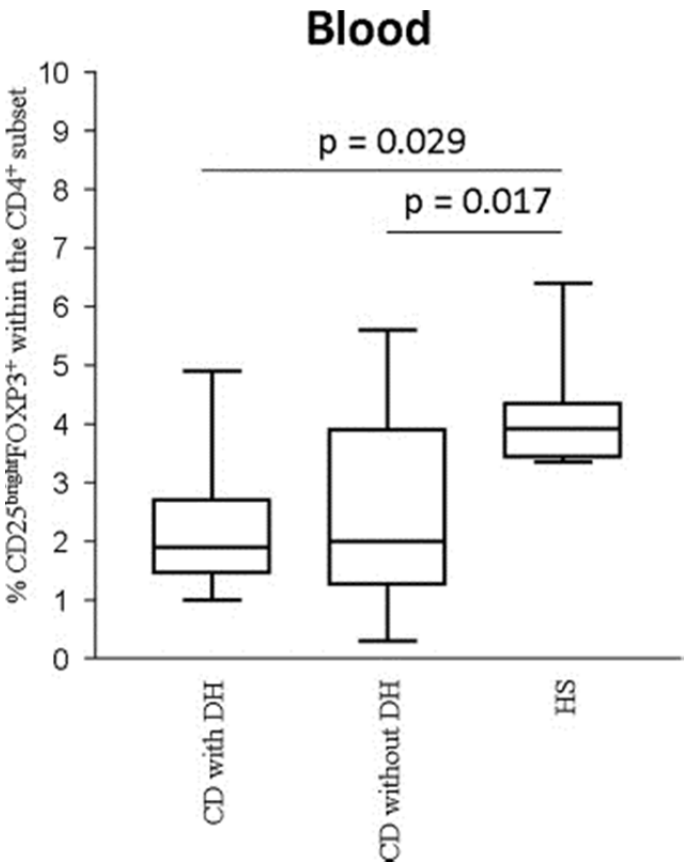

Fig. 6.

Regulatory T cells in the blood. Percentages of the $CD25^{bright}FOXP3^{+}$ subpopulations within the $CD4^{+}$ cell subset in patients with dermatitis herpetiformis (DH) compared with patients with celiac disease (CD) without DH and healthy subjects (HS).

Figure options

4. Discussion

To date, both DH and CD are considered autoimmune diseases in which predisposing genetic factors together with a well known triggering agent, i.e. gluten, lead to an autoimmune response directed to different organs, including the skin and duodenum.

Recently, growing evidence suggested that Tregs play a very important role in the development of autoimmunity [21]. However, no data are present in the literature about such T cell population in the various compartments involved in patients with DH. Moreover, the immunological differences between celiac patients with or without DH are still to be elucidated. Accordingly, the present study was designed to characterize the expression of Tregs in skin, duodenum and blood samples from patients with DH and to compare the findings with those found in celiac patients without DH, in order to evaluate their potential role in the pathogenesis of the disease and to assess whether a different pattern of the immune response could lead to a different disease phenotype.

Regarding the first aim of our study, that was intended to investigate the variations in the immune response among the different involved organs in patients with DH, our main finding was the demonstration of a significant reduction of Tregs in the skin lesions of patients with DH compared with HS. In fact, while the percentage of FOXP3-expressing $CD4^{+}$ cells in normal human skin is about 20%, as recently demonstrated by Sanchez Rodriguez [22] according to our results in HS, in both DH and BP lesions such a percentage was close to 0. Interestingly, our data showed that the decreased frequency of $FOXP3^{+}$ Tregs

was present even in the peripheral blood, but not in the intestinal lesions, suggesting that Tregs reduction could be considered as organ-specific.

The lack or the reduction of Tregs is a common finding in the cutaneous lesions of patients with autoimmune skin diseases, and was previously demonstrated in BP, in scleroderma, in dermatomyositis and in cutaneous lupus erythematosus [13], [23], [24], [25], [26], [27] and [28]. In DH skin, the reduction of Tregs may be responsible for an impairment of the suppressive activity that would not be able to control the inflammatory response, leading to the development of the lesions. Accordingly, we also found that the percentages of IL-10$^+$ cells among CD4$^+$ cells were significantly lower in DH skin than in HS, as demonstrated in a previous study also for BP; [13] since IL-10 is a regulatory cytokine involved in Tregs suppressive function and is predominantly expressed by adaptive Tregs, its local deficiency may contribute to the impairment of the regulatory activity found in DH lesions [29]. By contrast, we did not find any differences in TGF-β$^+$ cells with respect to HS. This is probably dependent on the low specificity of TGF-β for Tregs. In fact, TGF-β is not only a regulatory cytokine, but it has also other functions and is produced also by cell types different from Tregs, including fibroblasts [30]. Accordingly, our findings suggest that such a cytokine is probably not important in the pathogenesis of the DH.

Differently from the skin, we did not find a reduction of Tregs in duodenal lesions of patients with DH, since FOXP3$^+$ cell absolute number was higher than in HS, and their proportion among the CD4$^+$ cells was similar to that of the control group.

A possible explanation for the differences in Tregs distribution between the skin and the duodenal lesions might be related to the absence of skin homing markers and the presence of intestinal ones on Tregs in DH patients. Another possibility is the lack of Tregs specific for skin antigens involved in the pathogenesis of the lesions (i.e. TG3-specific Tregs) in patients with DH while, by contrast, gliadin specific Tregs have been documented in the duodenal mucosa at least in treated celiac patients [31].

The second aim of our study was to compare the phenotype of the duodenal immune response in celiac patients with or without DH. Similar results were found for Tregs, that were augmented in the duodenal lesions of all the investigated groups if compared to HS; such a result is in agreement with previous studies, suggesting that, although increased, Tregs are insufficient to reduce the duodenal inflammatory damage probably due to a functional impairment [16].

Our study has some limitations, including the fact that FOXP3, although still considered the most specific marker for Tregs, can be transiently expressed on activated T cells [32]. However, the finding of lack of Tregs in the skin is not affected by this potential bias, and therefore it can be considered specific. Moreover, functional studies investigating the suppressive activity of Tregs in patients with DH may be useful to further address the role of such cells in the development of the disease.

In conclusion, despite such limitations, our findings suggested that different patterns of the immune response are involved in the different organs targeted in DH. In particular, a reduction of Tregs may play a major role in the skin, leading to a defective suppressive function that is not able to downregulate the inflammation caused by the deposition in the skin of IgA anti-TG3 antibodies, that are currently thought to be the main effectors of DH lesions [4].

By contrast, no differences could be detected about Tregs between patients with DH and patients with CD in the duodenum, suggesting that the mechanisms of the intestinal damage are similar in both diseases.

References

[1]

M. Caproni, E. Antiga, L. Melani, P. Fabbri

Guidelines for the diagnosis and treatment of dermatitis herpetiformis

J Eur Acad Dermatol Venereol, 23 (2009), pp. 633–638

[2]

S. Kárpáti

Dermatitis herpetiformis: close to unravelling a disease

J Dermatol Sci, 34 (2004), pp. 83–90

[3]

D. Bonciani, A. Verdelli, V. Bonciolini, A. D'Errico, E. Antiga, P. Fabbri, et al.

Dermatitis herpetiformis: from the genetics to the development of skin lesions

Clin Dev Immunol, 2012 (2012), p. 239691

[4]

J.J. Zone, L.A. Schmidt, T.B. Taylor, C.M. Hull, M.C. Sotiriou, T.D. Jaskowski, et al.

Dermatitis herpetiformis sera or goat anti-transglutaminase-3 transferred to human skin-grafted mice mimics dermatitis herpetiformis immunopathology

J Immunol, 186 (2011), pp. 4474–4480

[5]

E. Antiga, M. Caproni, P. Fabbri

Comment on Dermatitis herpetiformis sera or goat anti-transglutaminase-3 transferred to human skin-grafted mice mimics dermatitis herpetiformis immunopathology

J Immunol, 187 (2011), p. 595

[6]

M. Sárdy, S. Kárpáti, B. Merkl, M. Paulsson, N. Smyth

Epidermal transglutaminase (TGase 3) is the autoantigen of dermatitis herpetiformis

J Exp Med, 195 (2002), pp. 747–757

[7]

M. Caproni, C. Feliciani, A. Fuligni, E. Salvatore, L. Atani, B. Bianchi, et al.

Th2-like cytokine activity in dermatitis herpetiformis

Br J Dermatol, 138 (1998), pp. 242–247

[8]

T. Honda, Y. Miyachi, K. Kabashima

Regulatory T cells in cutaneous immune responses

J Dermatol Sci, 63 (2011), pp. 75–82

[9]

S. Sakaguchi

Regulatory T cells: history and perspective

Methods Mol Biol, 707 (2011), pp. 3–17

[10]

E. Antiga, E. Del Bianco, E. Difonzo, P. Fabbri, M. Caproni

Serum levels of the regulatory cytokines transforming growth factor-β and interleukin-10 are reduced in patients with discoid lupus erythematosus

Lupus, 20 (2011), pp. 556–560

[11]

T.R. Torgerson

Regulatory T cells in human autoimmune diseases

Springer Semin Immunopathol, 28 (2006), pp. 63–76

[12]

M. Caproni, E. Antiga, D. Torchia, W. Volpi, E. Barletta, G. Gitti, et al.

FoxP3-expressing T regulatory cells in atopic dermatitis lesions

Allergy Asthma Proc, 28 (2007), pp. 525–528

[13]

E. Antiga, P. Quaglino, W. Volpi, I. Pierini, E. Del Bianco, B. Bianchi, et al.

Regulatory T cells in skin lesions and blood of patients with bullous pemphigoid

J Eur Acad Dermatol Venereol, 28 (2014), pp. 222–230

[14]

R. Cianci, G. Cammarota, G. Frisullo, D. Pagliari, G. Ianiro, M. Martini, et al.

Tissue-infiltrating lymphocytes analysis reveals large modifications of the duodenal immunological niche in coeliac disease after gluten-free diet

Clin Transl Gastroenterol, 3 (2012), p. e28

[15]

G. Frisullo, V. Nociti, R. Iorio, D. Plantone, A.K. Patanella, P.A. Tonali, et al.

Increased CD4 + CD25 + Foxp3+ T cells in peripheral blood of celiac disease patients: correlation with dietary treatment

Hum Immunol, 70 (2009), pp. 430–435

[16]

M. Granzotto, S. dal Bo, S. Quaglia, A. Tommasini, E. Piscianz, E. Valencic, et al.

Regulatory T-cell function is impaired in celiac disease

Dig Dis Sci, 54 (2009), pp. 1513–1519

[17]

M. Westerholm-Ormio, O. Vaarala, M. Tiittanen, E. Savilahti

Infiltration of Foxp3- and Toll-like receptor-4-positive cells in the intestines of children with food allergy

J Pediatr Gastroenterol Nutr, 50 (2010), pp. 367–376

[18]

M. Tiittanen, M. Westerholm-Ormio, M. Verkasalo, E. Savilahti, O. Vaarala

Infiltration of forkhead box P3-expressing cells in small intestinal mucosa in coeliac disease but not in type 1 diabetes

Clin Exp Immunol, 152 (2008), pp. 498–507

[19]

N.B. Hmida, M. Ben Ahmed, A. Moussa, M.B. Rejeb, Y. Said, N. Kourda, et al.

Impaired control of effector T cells by regulatory T cells: a clue to loss of oral tolerance and autoimmunity in celiac disease?

Am J Gastroenterol, 107 (2012), pp. 604–611

[20]

M. Caproni, D. Torchia, E. Antiga, W. Volpi, E. Del Bianco, A. D'Agata, et al.

The comparative effects of tacrolimus and hydrocortisone in adult atopic dermatitis: an immunoistochemical study

Br J Dermatol, 156 (2007), pp. 312–319

[21]

P. Wang, S.G. Zheng

Regulatory T cells and B cells: implication on autoimmune diseases

Int J Clin Exp Pathol, 6 (2013), pp. 2668–2674

[22]

R. Sanchez Rodriguez, M.L. Pauli, I.M. Neuhaus, S.S. Yu, S.T. Arron, H.W. Harris, et al.

Memory regulatory T cells reside in human skin

J Clin Invest, 124 (2014), pp. 1027–1036

[23]

M. Arakawa, T. Dainichi, N. Ishii, T. Hamada, T. Karashima, T. Nakama, et al.

Lesional Th17 cells and regulatory T cells in bullous pemphigoid

Exp Dermatol, 20 (2011), pp. 1022–1024

[24]

P. Quaglino, E. Antiga, A. Comessatti, M. Caproni, T. Nardò, R. Ponti, et al.

Circulating CD4+ CD25brightFOXP3+ regulatory T-cells are significantly reduced in bullous pemphigoid patients

Arch Dermatol Res, 304 (2012), pp. 639–645

[25]

E. Antiga, C.C. Kretz, R. Klembt, D. Massi, V. Ruland, C. Stumpf, et al.

Characterization of regulatory T cells in patients with dermatomyositis

J Autoimmun, 35 (2010), pp. 342–350

[26]

E. Antiga, P. Quaglino, S. Bellandi, W. Volpi, E. Del Bianco, A. Comessatti, et al.

Regulatory T cells in the skin lesions and blood of patients with systemic sclerosis and morphoea

Br J Dermatol, 162 (2010), pp. 1056–1063

[27]

P. Quaglino, R. Ponti, M. Novelli, P. Savoia, P. Fava, M. Papini, et al.

Flow cytometric analyses of circulating regulatory T cells in patients with dermatitis herpetiformis and other immune mediated dermatoses

G Ital Dermatol Venereol, 148 (2013), pp. 197–201

[28]

B. Franz, B. Fritzsching, A. Riehl, N. Oberle, C.D. Klemke, J. Sykora, et al.

Low number of regulatory T cells in skin lesions of patients with cutaneous lupus erythematosus

Arthritis Rheum, 56 (2007), pp. 1910–1920

[29]

C.C. Chu, N. Ali, P. Karagiannis, P. Di Meglio, A. Skowera, L. Napolitano, et al.

Resident CD141 (BDCA3)+ dendritic cells in human skin produce IL-10 and induce regulatory T cells that suppress skin inflammation

J Exp Med, 209 (2012), pp. 935–945

[30]

A.S. Patil, R.B. Sable, R.M. Kothari

An update on transforming growth factor-β (TGF-β): sources, types, functions and clinical applicability for cartilage/bone healing

J Cell Physiol, 226 (2011), pp. 3094–3103

[31]

C. Gianfrani, M.K. Levings, C. Sartirana, G. Mazzarella, G. Barba, D. Zanzi, et al.

Gliadin-specific type 1 regulatory T cells from the intestinal mucosa of treated celiac patients inhibit pathogenic T cells

J Immunol, 177 (2006), pp. 4178–4186

[32]

J. Wang, A. Ioan-Facsinay, E.I. van der Voort, T.W. Huizinga, R.E. Toes

Transient expression of FOXP3 in human activated nonregulatory CD4+ T cells

Eur J Immunol, 37 (2007), pp. 129–138