

جامعة نايف العربية للعلوم الأمنية
Naif Arab University for Security Sciences

Naif Arab University for Security Sciences
Arab Journal of Forensic Sciences and Forensic Medicine

www.nauss.edu.sa
http://ajfsfm.nauss.edu.sa



الجمعية العربية للعلوم الألة الجنائية والطب الشرعي
Arab Society for Forensic Sciences and Forensic Medicine

Suicide with One Cranial Gunshot by a .320 Caliber Pocket Revolver

Lucia Tattoli^{1*}, Saskia Sabrina Etzold², Michael Tsokos²,

Lars Oesterhelweg², Sven Hartwig²

Open Access



¹ Section of Legal Medicine, Department of Public Health and Pediatrics, University of Turin, Corso Galileo Galilei 22, 10126, Torino, Italy

² Institute of Legal Medicine and Forensic Sciences, University Medical Centre Charité, University of Berlin, Turmstr. 21, Building N, 10559, Berlin, Germany

Abstract

Suicide using a firearm is the most commonly used method of committing suicide for men and women. In this paper, we present and discuss a suicide case in which an 86-year-old man shot himself using a .320 caliber pocket revolver. Proper crime scene investigation, recovery of the weapon used, and precise interpretation of autopsy findings play a fundamental role in determining the exact cause and manner of death. Accurate analysis of the injuries and a thorough knowledge of weapons and ballistics are essential for an adequate investigation in these unusual cases. To the best of our knowledge, this is the first report of a cranial gunshot inflicted by a .320 caliber pocket revolver.

Key words: Suicide, Cranial gunshot, .320 caliber pocket revolver

* Corresponding Author: Lucia Tattoli MD, PhD

Email: luciatattoli@libero.it

1658-6794© 2015 Naif Arab University for Security Sciences. All Rights Reserved. Peer review under the responsibility of NAUSS / doi: 10.12816/0011257

حالة انتحار ناجمة عن طلقة نارية واحدة في قحف الجمجمة من مسدس جيب عيار (.320).

يعتبر الانتحار باستخدام السلاح الناري من الأساليب الأكثر شيوعاً في الانتحار بين كل من الرجال والنساء. في هذه الورقة، نقدم ونناقش قضية انتحار، تتمثل في رجل يبلغ من العمر 86 عاماً، أطلق النار على نفسه باستخدام مسدس جيب عيار (.320)، في هذا النوع من القضايا، من أجل تحديد السبب الحقيقي والطريقة الدقيقة التي حدثت بها الوفاة، فإننا نحتاج إلى تحقيق سليم في موقع الجريمة، ورفع صحيح للسلاح المستخدم، بالإضافة إلى تفسير دقيق لنتائج تشريح الجثة. حيث أن كل هذه الأمور تلعب دوراً أساسياً في تحديد السبب الحقيقي، والطريقة الدقيقة لحدوث الوفاة. كما أن التحليل الدقيق للإصابات والمعرفة الوافية للأسلحة والمقذوفات المستخدمة من الركاثر الضرورية لإجراء تحقيق يناسب هذه الحالات غير العادية. على حد علمنا، هذا هو التقرير الأول لقضية تطلق ناري في قحف الجمجمة وقع بواسطة مسدس جيب عيار (.320).

Introduction

Suicide is a tragic and potentially preventable public health problem. A considerable number of people – regardless of age, sex, race, social and economic status – put an end to their lives on purpose, thereby causing irreparable damage to society in general and to their respective families, in particular. The World Health Organization (WHO)



Production and hosting by NAUSS

estimates that each year approximately one million people die from suicide, which represents a global mortality rate of 16 people per 100,000 or one death every 40 seconds. It is predicted that by 2020 the rate of death from suicide will increase to one every 20 seconds [1].

Suicide using a firearm is the most commonly used method of committing suicide for men and women. According to the United States Suicide Statistics (2004), firearms were used in 51.6% of the total suicides committed in 2004, followed by hanging, strangulation and suffocation (22.6%), poisoning (17.9%) and other means of suicide (7.9%) [2]. Proper crime scene investigation, recovery of the weapon used, and precise interpretation of autopsy findings play a fundamental role in determining the exact cause and manner of death.

In this paper, we present and discuss a suicide case involving a .320 caliber pocket revolver.

Case Report

An 86-year-old man was found by his neighbour in the shower tray in the bathroom of his apartment, still gasping and bleeding from his head. He was taken to the hospital where he died approximately 20 hrs later despite neurosurgery and intensive care. At the death scene, blood stains and spatters were found in the shower tray, with downward cast-off stains on the shower walls at 1.0 meter from the ground.



Figure 1- The .320 caliber pocket revolver found at the death scene

A .320 caliber pocket revolver (Fig. 1) was lying on the bath mat. The revolver cylinder contained four spent (7.65 caliber, full metal jacket) cartridges and one fired round. The projectile was not found but there was a gunshot hole in the shower's ceiling. Police also found a scar-gun and

two 7.65 caliber cartridges in the apartment. The man's previous medical history was unknown but his neighbour reported that the deceased had suffered from a depressive disorder. External examination revealed a 5.0 cm suture in the right temporal region and a 4.0 cm suture near to the top of the head, to the left of the midline. A Right orbital hematoma and a sutured contused-lacerated wound of the left cheekbone were also observed. There was no evidence of other external injury.

Autopsy Findings

Autopsy showed an oval penetrating wound in the left parietal bone (close to the midline) measuring 1.0 cm in diameter and exhibiting external bevelling and a small fracture line (entrance wound) (Figures 2 a, b).

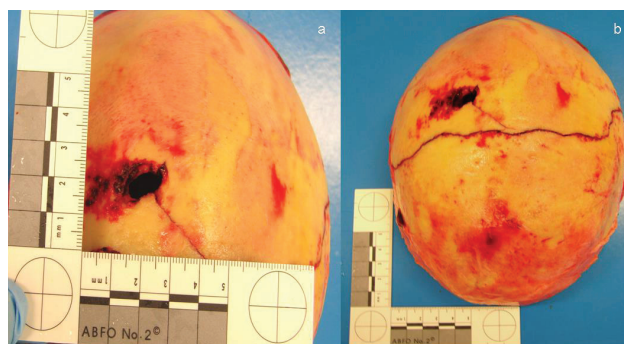


Figure 2- Entrance wound: gross appearance of the left parietal bone. a) Defect of the outer table. b) Short fracture line

A rounded penetrating cranial defect of the outer table of the right temporal bone measuring 0.9 cm in diameter was observed, with external bevelling of the inner table (exit wound) (Figures 3 a, b).

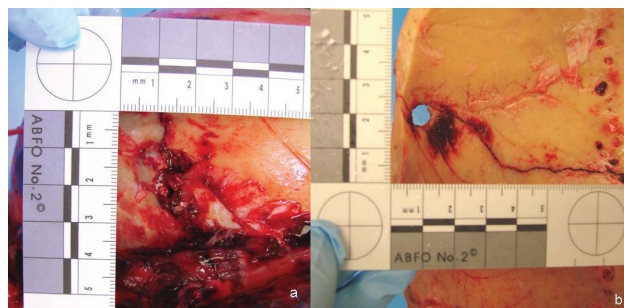


Figure 3- Exit wound: gross appearance of the right temporal bone a) Defect of the outer table with external bevelling b) Defect of the inner table

A fracture line started from the defect, crossing the midline and ending in the temporo-parietal left region not intersecting the previous one (Figure 4).

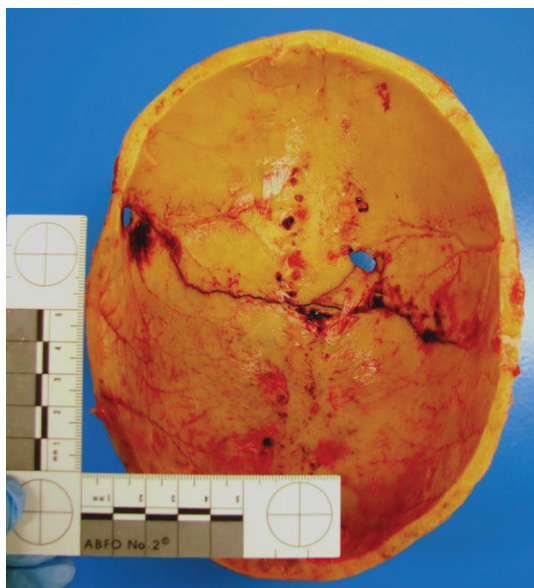


Figure 4- Fracture line starting from the right temporal wound. Note the entrance wound close to the midline

The brain showed a 3x3 cm defect of the left parietal lobe with the wound track passing intracranially and crossing the midline through both lateral ventricles and the corpus callosum where intraventricular haemorrhage was observed. The shot canal continued through the right temporal lobe ending in a rounded 0.9 cm tissue defect. The brain showed epidural and subdural haematomas with the dura mater injured; there was a widespread subarachnoid haemorrhage of both hemispheres. The brainstem was not involved. The right orbital roof plate was fractured. Cardiomegaly (heart weight 590 g) and a pacemaker, signs of chronic left and right heart failure (cardiac cirrhosis) and atherosclerosis were also observed. Toxicological analysis revealed morphine (in blood and urine), lidocaine (in blood), omeprazole (in gastric content) and amitriptyline (in blood and gastric content) in therapeutic concentrations. In particular, morphine and lidocaine (anesthetics) were administered in hospital; amitriptyline (a tricyclic antidepressant) was probably self-administered but it had not affected the deceased's capability to act. Ethanol was not detected. The cause of death was a penetrating cranial gunshot; the manner of death was ruled as a suicide.

Discussion

In the United States, the most common method of suicide in the mid-1800s was hanging, and then poisoning in the 1900s. From then onward, firearms fatalities started to rise for both men and women [3]. Handguns are the most frequently used weapons in suicides, mainly by contact shot to the head (81%), the chest (17%), and the abdomen (2%); the most common location is the right temple region [4, 5]. The mortality of the related cranial injury is very high, ranging from 20% to 90%, with a poor outcome in bilobar lesions [6].

The weapon used in the above case was a double action .320 caliber revolver with a five-round cylinder, loaded with 7.65 caliber cartridges. This firearm is a smaller version of the 'British Bull-Dog' revolver introduced by Philip Webley & Son of Birmingham in 1872, featuring a 64 mm barrel and chambered for five .44 Short Rimfire, .442 Webley, or .450 Adams cartridges. These pocket revolvers are small and have no sharp edges because they were designed to be carried in a coat pocket or kept at home; they were optimal for self-defence and ideal for plainclothes police officers and detectives in the British Empire in the late 19th century [7-9]. Some of these revolvers are still available in quite good condition, and so their use in gunshot injuries has to be taken into consideration along with other unusual pocket revolvers.

To the best of our knowledge this is the first report of cranial gunshot inflicted by a .320 caliber pocket revolver. In the literature, there is only one report concerning a suicide committed using a 'Velo-Dog' (.25 caliber) pocket revolver, by Hayashi et al. [10], which showed that these unusual firearms can be lethal weapons if used to shoot at close range into the head. Often wounds caused by such special guns are described as atypical wounds that differ from those inflicted by conventional and modern revolvers.

Conclusion

So many different versions of this type of gun can still be acquired nowadays. Therefore, an accurate analysis of the injuries and a thorough knowledge of weapons and ballistics are essential for an adequate investigation in these unusual cases [10-11].

References

1. First WHO World Suicide Report. http://www.who.int/mental_health/suicide-prevention/en/ Accessed April, 2015.
2. U.S. Suicide Statistics (2004): Suicide Methods. <http://www.suicide.org/suicide-statistics.html#2005> Accessed April, 2015.
3. Shields LBE, Hunsaker DM, Hunsaker III JC. Trends of Suicide in the United States During the 20th Century. In: Tsokos M, editor. Forensic pathology reviews. Vol. 3. Totowa: Humana Press; 2005. pp.305-322.
4. Di Maio VJM. Gunshot wounds: Practical Aspects of Firearms, Ballistics, and Forensic Techniques. 2nd ed. Boca Raton: CRC Press LLC; 1999.
5. Solarino B, Nicoletti EM, Di Vella G. Fatal firearm wounds: a retrospective study in Bari (Italy) between 1988 and 2003. *Forensic Sci Int* 2007;168:95-101.
6. Petridis AK, Doukas A, Barth H, Mehdorn M. Outcome of craniocerebral gunshot injuries in the civilian population. Prognostic factors and treatment options. *Cent Eur Neurosurg* 2011; 72:5-14.
7. Black J, Ficken H, Michaels F. Webley solid-frame Revolvers: Nos. 1, 1 1/2, 2, Bull Dogs, and Pugs. Atglen: Schiffer Publishing, Ltd; 2008.
8. Barnes FC, Skinner S. Cartridges of the world. 10th ed. Northbrook: DBI Books; 2003.
9. Dowell WC. The Webley Story. Kirkland: Commonwealth Heritage Foundation; 1987.
10. Hayashi T, Gapert R, Tsokos M, Hartwig S. Suicide with two shots to the head using a rare 'Velo-Dog' pocket revolver. *Forensic Sci Med Pathol* 2013; 9:265-9.
11. Tsokos M, Voigt Z, Ehrlich E. Atypical gunshot entry wound. *Forensic Sci Med Pathol* 2012; 8:460-2.

