

AperTO - Archivio Istituzionale Open Access dell'Università di Torino

Oval and round window vibroplasty: a comparison of hearing results, risks and failures.

This is the author's manuscript

Original Citation:

Availability:

This version is available <http://hdl.handle.net/2318/141768> since

Published version:

DOI:10.1007/s00405-013-2752-1

Terms of use:

Open Access

Anyone can freely access the full text of works made available as "Open Access". Works made available under a Creative Commons license can be used according to the terms and conditions of said license. Use of all other works requires consent of the right holder (author or publisher) if not exempted from copyright protection by the applicable law.

(Article begins on next page)

This is the author's final version of the contribution published as:

Canale A; Dagna F; Cassandro C; Giordano P; Caranzano F; Lacilla M; Albera R. Oval and round window vibroplasty: a comparison of hearing results, risks and failures.. EUROPEAN ARCHIVES OF OTO-RHINO-LARYNGOLOGY. 271 (10) pp: 2637-2640.
DOI: 10.1007/s00405-013-2752-1

The publisher's version is available at:

<http://link.springer.com/content/pdf/10.1007/s00405-013-2752-1>

When citing, please refer to the published version.

Link to this full text:

<http://hdl.handle.net/2318/141768>

Oval and round window vibroplasty: a comparison of hearing results, risks and failures

Andrea Canale¹, Federico Dagna¹, Claudia Cassandro¹, Pamela Giordano¹, Federico Caranzano¹, Michelangelo Lacilla¹ and Roberto Albera¹

(1)ENT Department, San Giovanni Battista Hospital, University of Torino, Via Genova, 3, 10100 Turin, Italy

Corresponding author: Federico Dagna Email: federico.dagna@gmail.com

Abstract

The aim of this study was to compare oval and round window vibroplasty. Eighteen (18) patients implanted with Vibrant Soundbridge (VSB) were enrolled. Two groups were formed depending on FMT placement: on round window in ten cases (RW group) and on oval window in eight (OW group). Pre and postoperative audiological tests were performed both under headphones and free-field settings, VSB on and off. One (1) RW patient experienced sudden hearing loss at the operated side after 4 months from surgery and was excluded from the analysis. Both groups showed good hearing results. Significant differences were measured at free-field pure-tone test with VSB on at 0.5 kHz (RW better than OW, $p = 0.026$) and 4 kHz (OW better than RW, $p = 0.043$). Both techniques share similar good results and are considered safe. However, we had one failure with deep and sudden hearing threshold worsening after some months of good results. From a surgical point of view OW vibroplasty is easier and safer to perform, when the stapes suprastructure is absent, as it does not require any drilling and should be preferred in such cases. More reports are needed to explain if RW vibroplasty is risky in a mid to long term.

Keywords: Vibrant Soundbridge Hearing impairment Oval window Round window

Introduction

The Vibrant Soundbridge (MedEl, Innsbruck, Austria) is a middle-ear implantable device that has been used since 1996.

The indications from its early introduction have been spreading from pure sensorineural to mixed-type hearing losses, reflecting several changes in the surgical technique. In the beginning the FMT (Floating Mass Transducer), the real effector of the device, was supposed to be attached to the ossicular chain, namely to the long process of the incus, through a wide posterior tympanotomy (chain vibroplasty). Later on Colletti [1] suggested to place the FMT on the round window (RW vibroplasty) obtaining good hearing results and extending the use of the Vibrant Soundbridge to many patients affected by mixed-type hearing loss who could not benefit from conventional hearing aids usually because of previous surgery. More recently OW vibroplasty, in which the FMT is placed on the oval window, has been introduced with good results [2, 3].

From a surgical point of view the main difference between RW and OW vibroplasty is that the former needs the round window niche to be drilled to expose its membrane while the latter requires the absence of the stapes suprastructure, although the recent development of specific couplers has partially overcome this problem [4, 5].

There are several reports in the literature showing the good hearing results of both these techniques, however to the authors' knowledge there is just one paper which compared the results in patients operated on by the same surgeons [6].

The aim of this study was to compare the hearing results of OW and RW vibroplasty and highlight the advantages of each technique.

Materials and methods

The study group consisted of a series of 18 patients consecutively operated on between January 2009 and June 2012; there were 3 males (17 %) and 15 females (83 %) and their age ranged from 26 to 74 years (mean 52, SD 14.7).

All the patients had undergone previous surgeries and were submitted to Vibrant Soundbridge implantation due to poor hearing results and after trying and then abandoning traditional hearing aids. In particular 15 patients (83 %) had previous tympanoplasty, 1 (5.6 %) stapedotomy, 1 (5.6 %) myringoplasty and 1 (5.6 %) patient was affected by atresia auris. Among the patients who had undergone tympanoplasty there were ten canal wall down and five canal wall up cases.

Each patient underwent a complete preoperative assessment including otoscopy and micro-otoscopy, temporal bone HRCT scan, pure-tone audiometry, speech audiometry both under headphones and free-field setting.

The Vibrant Soundbridge was implanted in the left ear in ten cases (56 %) and in the right ear in eight cases (44 %) and the FMT was positioned on the oval window in eight patients (44 %) and on the round window in 10 (56 %).

The sample was divided into group O and group R depending on the placement of the FMT on oval or round window, respectively. The choice between the techniques was guided by the preoperative diagnostic workup, in particular former surgical records, when available, and HRCT scans were carefully examined looking for anatomical abnormalities which would have forced our decision. From this point of view we carefully looked for overhanging facial nerve, ossicular chain discontinuity, high jugular bulb, presence of scars in the middle ear. However, the final decision was taken during surgery depending on intraoperative findings, namely presence/absence of stapes remnants, footplate mobility/fixation.

Mean preoperative hearing threshold in the frequency range 0.5–4 kHz is reported in Table 1.

Table 1
Pure-tone audiometry thresholds

		0.5 kHz	1 kHz	2 kHz	3 kHz	4 kHz
OW n = 8	AC	71 (15)	74 (18)	74 (21)	75 (20)	77 (18)
	BC	30 (11)	32 (13)	44 (17)	47 (19)	51 (24)
RW n = 10	AC	76 (14)	72 (13)	69 (16)	73 (17)	75 (20)
	BC	27 (8)	33 (10)	42 (14)	45 (15)	47 (14)

All values are in dB HL. Standard deviation in brackets

OW oval window, RW round window, AC air conduction, BC bone conduction

Free-field pure-tone and speech recognition test (SRT) mean thresholds were, respectively, 75.7 and 74.2 dB. The Vibrant Soundbridge was activated 1 month after surgery and the audiological data used for this study were collected 6 months later. However, each patient has been monitored since the time of surgery and mean follow-up time is 23 months (min 7, max 40).

Each patient underwent the same preoperative tests with VBS on and off. All the free-field tests were performed with the contralateral ear occluded by specific acrylic mould. To verify FMT

correct placement each patient underwent audiometry using the FMT as output (vibrogram). To do so pure tones were sent through MedEl specific adaptor and software directly to the implanted vibrant ossicular prosthesis (VORP). Well-performed surgery should aim at minimum gap between bone conduction threshold and vibrogram from 1 kHz onward.

Results

There were no significant differences between the groups as regards preoperative hearing thresholds ($p > 0.05$).

One (1) Group R patient (5.6 %) was excluded from the analysis because of the sudden and quick worsening of the hearing threshold at the implanted side after 4 months of good results. The surgery video recording was evaluated without getting any explanations.

No significant differences both between groups and before/after surgery ($p > 0.05$) were found.

The vibrogram showed similar results ($p > 0.05$) in both groups as reported in Fig. 1. Coherence between vibrogram and BC thresholds was higher from 1 kHz onward due to intrinsic amplification limits of the VSB.

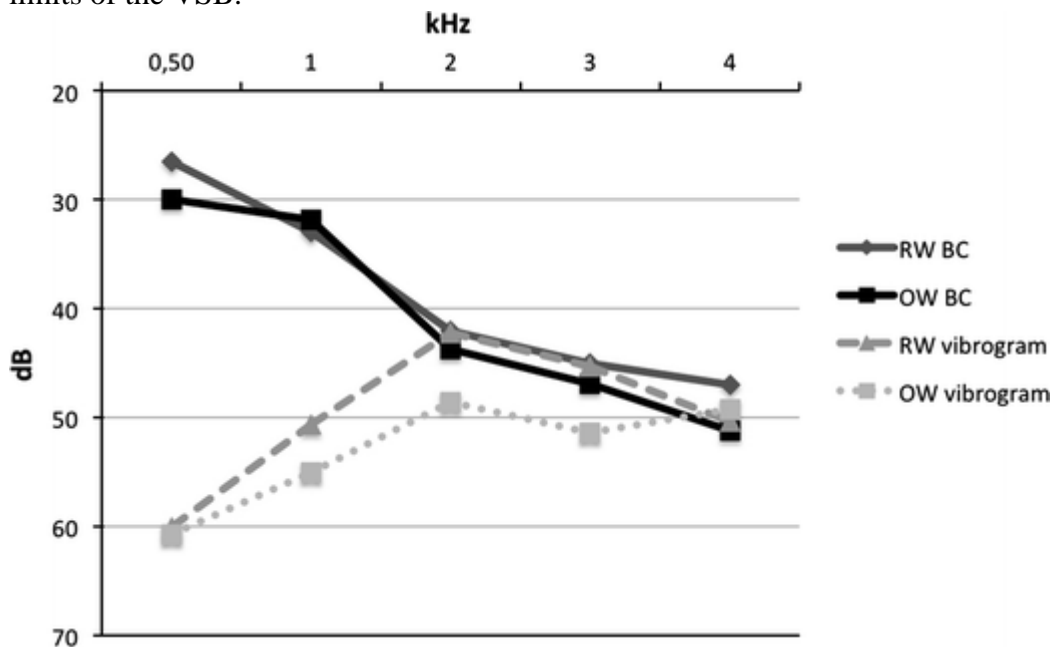


Fig. 1

Mean bone conduction (BC) threshold and vibrogram in both groups. OW oval window, RW round window

Free-field pure-tone and speech audiometry results are reported in Fig. 2 and Table 2. Student's t test showed significant differences between groups with VSB on at 0.5 kHz ($p = 0.026$) and 4 kHz ($p = 0.043$). No between-group differences were found to be significant with VSB off.

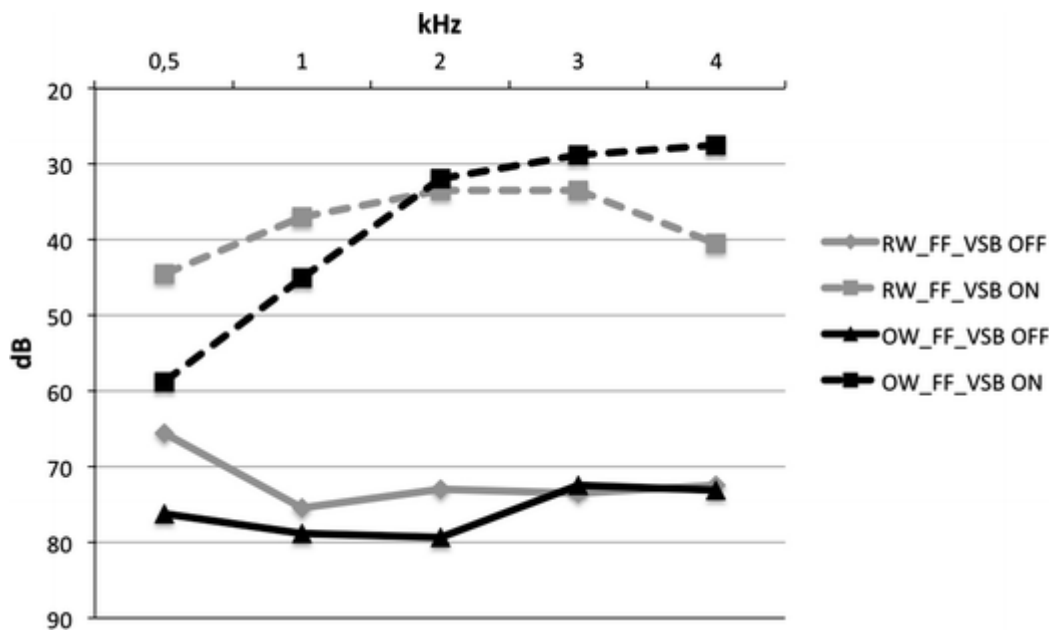


Fig. 2

Mean free-field pure-tone audiometry threshold in both groups with and without Vibrant Soundbridge (VSB) on. OW oval window, RW round window. Differences between groups with VSB on are significant at 0.5 and 4 kHz

Table 2

Free-field speech reception test

Free-field	SRT VSB off	SRT VSB on
OW	77.5 (18)	43.1 (8)
RW	71.5 (11)	40.5 (10)
p	0.43	0.53

Standard deviation in brackets. Differences were not significant at student's t test

OW oval window, RW round window, SRT speech reception test, VSB Vibrant Soundbridge

Discussion

The VSB is a middle-ear implantable device, which may be effectively used in several patients affected by hearing loss, who cannot benefit from traditional hearing aids. Since its early introduction many modifications of the surgical technique have been suggested and used with good hearing results. In particular RW vibroplasty and, later, OW vibroplasty greatly extended the VSB indications of use. Round window approach is the first choice for many authors, who perform OW vibroplasty when RW vibroplasty is contraindicated (e.g. high jugular bulb or scar formation in front of the round window membrane) [4]. Several studies have showed the hearing results of both techniques separately [7, 8], however there is just one paper comparing the results in a group of patients operated on by the same surgeon at the same hospital [6].

As pointed out by other studies both OW and RW vibroplasties show good hearing results. However, significant differences between groups were found at 0.5 and 4 kHz. In particular group R showed better hearing results at 0.5 kHz ($p < 0.05$), whereas group O had better improvements at 4 kHz ($p < 0.05$). The differences at lower frequencies were expected as already pointed out [6],

while those at 4 kHz had never been demonstrated before. However, these differences are consistent with middle ear physiology: the presence of the footplate increases system stiffness thus enhancing high frequencies and limiting low-frequency transmission. By performing the vibrogram we could demonstrate that the FMT was well positioned in all the cases.

Being the sample heterogeneous in terms of hearing loss etiology, we decided to perform the same statistical analysis focusing just on the patients who had undergone tympanoplasty, seven of which received RW-vibroplasty and eight OW-vibroplasty. The results did not change as regards aided hearing results, which were good in both groups, and a significant difference remained at 0.5 and 4 kHz (Table 3).

Table 3
Subset of patients who had tympanoplasty previously

Sample	PTA pre	Postoperative PTA in free-field setting			
		VSB off	VSB on	VSB on, 0.5 kHz	VSB on, 4 kHz
RW n = 7	76 (18)	73 (16)	39 (11)	46 (11)	41 (17)
OW n = 8	74 (19)	76 (17)	38 (12)	59 (16)	28 (12)
p	> 0.05	> 0.05	> 0.05	= 0.05*	= 0.05*

All values are expressed in dB HL. Standard deviation values are in brackets
OW oval window, RW round window, VSB vibrant Soundbridge

Although the FMT window application seems a safe procedure [7–10] we had one failure with deep and sudden worsening of the hearing threshold. The inner ear loss of function occurred after some months of good hearing results. This patient was implanted using a RW vibroplasty and a careful evaluation of the recordings of the operation could not explain the reasons for which this happened. Drilling of the RW niche was careful and did not damage the inner ear, as postoperative audiograms showed, and fascia was interposed between the FMT and the secondary membrane of the RW. CT scan did not show FMT displacement. A hypothesis might be that the FMT may have altered the secondary membrane of the round window determining a fistula after some months of use although sudden idiopathic hearing loss cannot be excluded. However, there are some similar reports in the literature and attention on this topic is needed [7].

From a surgical point of view OW vibroplasty is easier to perform when the stapes suprastructure is absent and there are no anatomical issues (e.g. narrow window, overhanging facial nerve) as it does not require any drilling. Drilling the superior lip of the RW niche, in fact, increases the risks of inner ear damage.

In conclusion, although both OW and RW vibroplasty share similar results, we suggest using the former technique whenever possible due to minor risks of hearing deterioration.

However, one case in a series of 18 patients is not conclusive on the topic and other reports will be needed to explain if RW vibroplasty is risky in a mid to long term.

References

1. Colletti V, Soli SD, Carner M, Colletti L (2006) Treatment of mixed hearing losses via implantation of a vibratory transducer on the round window. *Int J Audiol* 45:600Y5
2. Zehlicke T, Dahl R, Just T, Pau HW (2010) Vibroplasty involving direct coupling of the floating mass transducer to the oval windowniche. *J Laryngol Otol* 124:716–719
3. Huttenbrink KB, Beutner D, Zahnert T (2010) Clinical results with an active middle ear impant in the oval window. *Adv Otorhinolaryngol* 69:27–31
4. Mlynski R, Mueller J, Hagen R (2010) Surgical approaches to position the Vibrant Soundbridge in conductive and mixed hearing loss. *Oper Tech Otolaryngol* 21:272–277
5. Beleites T, Neudert M, Beutner D, Hüttenbrink KB, Zahnert T (2011) Experience with vibroplasty couplers at the stapes head and footplate. *Otol Neurotol* 32(9):1468–1472
6. Gunduz B, Atas A, Bayazıt YA, Goksu N, Gokdogan C, Tutar H (2012) Functional outcomes of Vibrant Soundbridge applied on the middle ear windows in comparison with conventional hearing aids. *Acta Otolaryngol* 132(12):1306–1310 Epub 2012 Oct 7
7. Böheim K, Mlynski R, Lenarz T, Schlögel M, Hagen R (2012) Round window vibroplasty: long-term results. *Acta Otolaryngol* 132(10):1042–1048 Epub 2012 Jul 10
8. Baumgartner WD, Boheim K, Hagen R, Muller J, Lenarz T, Reiss S et al (2010) The Vibrant Soundbridge for conductive and mixed hearing losses: European multicenter study results. *Adv Otorhinolaryngol* 69:38–50
9. Beltrame AM, Martini A, Prosser S, Giarbini N, Streitberger C (2009) Coupling the Vibrant Soundbridge to cochlea round window: auditory results in patients with mixed hearing loss. *Otol Neurotol* 30(2):194–201
10. Skarzynski H, Olszewski L, Skarzynski PH, Lorens A, Piotrowska A, Porowski M, Mrowka M, Pilka A (2013) Direct round window stimulation with the Med-El Vibrant Soundbridge: 5 years of experience using a technique without interposed fascia. *Eur Arch Otorhinolaryngol*. [Epub ahead of print]