

## Ultrasound imaging for the rheumatologist XXXVI. Sonographic assessment of the foot in gout patients

E. Filippucci<sup>1</sup>, G. Meenagh<sup>2</sup>, A. Delle Sedie<sup>3</sup>, G. Sakellariou<sup>4</sup>, A. Iagnocco<sup>5</sup>, L. Riente<sup>3</sup>,  
M. Gutierrez<sup>1</sup>, S. Bombardieri<sup>3</sup>, G. Valesini<sup>5</sup>, C. Montecucco<sup>4</sup>, W. Grassi<sup>1</sup>

<sup>1</sup>Clinica Reumatologica, Università Politecnica delle Marche, Ancona, Italy;

<sup>2</sup>Department of Rheumatology, Antrim Hospital, Antrim, United Kingdom;

<sup>3</sup>Unità Operativa di Reumatologia, Università di Pisa, Pisa, Italy;

<sup>4</sup>Cattedra di Reumatologia, IRCCS Policlinico San Matteo, Università di Pavia, Pavia, Italy;

<sup>5</sup>Rheumatology Unit, Dipartimento di Medicina Interna e Specialità Mediche, Sapienza Università di Roma, Rome, Italy.

Emilio Filippucci, MD

Gary Meenagh, MD

Andrea Delle Sedie, MD

Garifallia Sakellariou, MD

Annamaria Iagnocco, MD

Lucrezia Riente, MD

Marwin Gutierrez, MD

Stefano Bombardieri, MD, Professor of Rheumatology

Guido Valesini, MD, Professor of Rheumatology

Carlomaurizio Montecucco, MD,

Professor of Rheumatology

Walter Grassi, MD, Professor of Rheumatology

Please address correspondence to:

Dr Emilio Filippucci,

Clinica Reumatologica,

Università Politecnica delle Marche,

Ospedale "C. Urbani",

Via dei Colli 52,

60035 Jesi (Ancona), Italy.

E-mail: emilio\_filippucci@yahoo.it

Received and accepted on December 14, 2011.

Clin Exp Rheumatol 2011; 29: 901-905.

© Copyright CLINICAL AND

EXPERIMENTAL RHEUMATOLOGY 2011.

Competing interests: none declared.

### ABSTRACT

**Objective.** This study aims to investigate the relationship between clinical and US findings together with the prevalence and distribution of US findings indicative of monosodium urate (MSU) crystal deposition within the foot in patients with gout.

**Methods.** A total of 50 patients with gout attending the in-patient and the out-patient clinics of the Rheumatology Departments were prospectively enrolled in this multi-centre study. Multi-planar examination of the following 15 joints was performed: talo-navicular, navicular-cuneiform (medial, intermediate and lateral), calcaneo-cuboid, medial, intermediate and lateral cuneiform-metatarsal, cuboid-4th metatarsal, cuboid-5th metatarsal and all five metatarsophalangeal (MTP) joints.

**Results.** The following US findings were indicative of gout: enhancement of the superficial margin of the hyaline cartilage, intra-articular tophus, and extra-articular tophus. In 46 patients, a total of 1380 foot joints were investigated. In 1309 joints that were not clinically involved, US detected signs indicative of joint inflammation in 9% (121/1309). Talo-navicular joint and the first MTP joint were the joints in which the highest number of US findings were found at mid-foot and fore-foot, respectively. At MTP joint level, dorsal scans allowed the detection of a higher number of US findings indicative of joint inflammation, and MSU crystal deposits rather than on the volar plane.

**Conclusion.** This study demonstrated that US detected a higher number of inflamed foot joints than clinical examination, and that the first MTP and the talo-navicular joints were the anatomic sites with the highest prevalence of US signs of MSU crystal aggregates.

### Introduction

In recent times several studies have investigated the role of ultrasound (US) in the rheumatological assessment of patients with gout (1-15). Highly specific findings have been already been described by our group and other investigators.

Current evidence suggests that US is an accurate imaging tool for detecting signs of monosodium urate (MSU) crystal deposition. Some aspects of using US in gout require further clarification, however including the relationship between clinical and US findings and the impact of these findings in the management of patients with gout.

The present study was aimed at investigating the relationship between clinical and US findings, together with the prevalence and distribution of US findings indicative of MSU crystal deposition within the foot in patients with gout.

### Methods

#### Patients

A total of 50 consecutive patients with a definite diagnosis of gout (16) attending the in-patient and out-patient clinics of the Rheumatology Departments were prospectively enrolled in this multi-centre study. Patients with previous joint surgery and/or history of severe trauma to the foot were excluded. Each centre was expected to recruit at least 10 patients. Four patients were not included because of the following reasons: two patients had undergone a surgical intervention, one had multiple metatarsal bony fractures and the last did not agree to participate in the study.

Before the beginning of the study, the sonographers reached an agreement on the scanning protocol to adopt and on

the definition of the pathological US signs to be commented upon.

The study was conducted according to the local regulations and the Declaration of Helsinki. Informed consent was obtained before their patients were included in the study.

#### US scanning technique

Prior to US examination, each patient was examined clinically by an expert rheumatologist following the same method adopted in the previous studies (18-22).

All US examinations were performed using two US systems a Logiq 9 (General Electrics Medical Systems, Milwaukee, WI) and a My Lab70 XVG (Esaote SpA, Genoa, Italy). Both of them equipped with a multi-frequency linear probe operating at a frequency higher than 13 MHz.

To obtain the US data, the scanning technique described in detail by Delle Sedie *et al.* (17) was adopted and the EULAR guidelines were followed (23). To obtain maximal access of the metatarsal head hyaline cartilage, MTP joints were examined in maximal flexion.

Multi-planar examination of the following 15 joints per foot was performed: talo-navicular, medial, intermediate and lateral navicular-cuneiform medial, calcaneo-cuboid, medial, intermediate and lateral cuneiform-metatarsal, cuboid-4th metatarsal, cuboid-5th meta-tarsal, all five metatarsophalangeal (MTP) joints.

#### US image interpretation

For the detection of non-specific findings indicative of joint inflammation and bone erosions, the OMERACT preliminary definitions were used (24). To detect the presence of MSU crystal deposits, the following US findings were used: enhancement of the superficial margin of the hyaline cartilage (double contour), intra-articular tophus, and extra-articular tophus (1-3, 7, 10, 15).

#### Results

Forty-six consecutive patients (43 males and 3 females) with gout were included in the present study and a total of 1380 joints (15 per each foot) were

**Table I.** Patients' demographic and clinical data.

Number of patients	46
Gender (female/male)	3/43
Age in years (median; 95% CI for the median; SD; range)	58.5; 54-64; 12; 41-91
Disease duration in months (median; 95% CI for the median; SD; range)	53.5; 36.4-54; 27; 12-156.
Number of patients on urate lowering therapy (%)	37 (80%)
Number of patients on colchicine treatment (%)	33 (71.7%)
Number of patients on steroid therapy (%)	25 (54.3%)
Number of patients on NSAIDs (%)	17 (37%)

CI: confidence interval; SD: standard deviation; NSAIDs: non-steroidal anti-inflammatory drugs.

**Table II.** Correlation between sonographic and clinical findings indicative of midtarsal and MTP joint inflammation. The presence of at least one finding indicative of joint inflammation was used to compile the table.

A. Midtarsal joints		Clinical findings		Total
		Presence	Absence	
Sonographic findings	Presence	25	45	70
	Absence	2	848	850
	Total	27	893	920

B. MTP joints		Clinical findings		Total
		Presence	Absence	
Sonographic findings	Presence	41	76	117
	Absence	3	340	343
	Total	44	416	460

**Table III.** Distribution of sonographic findings at different anatomical sites within the foot.

Joint	US finding	Number
Talo-navicular joint	Joint effusion	9
	Synovial hypertrophy	13
	Intra-articular PD signal	13
	Bone erosions	13
	Intra-articular tophus	7
	Extra-articular tophus	0
Navicular-cuneiform medial joint	Joint effusion	9
	Synovial hypertrophy	11
	Intra-articular PD signal	12
	Bone erosions	7
	Intra-articular tophus	4
	Extra-articular tophus	0
Navicular-cuneiform intermediate joint	Joint effusion	4
	Synovial hypertrophy	5
	Intra-articular PD signal	3
	Bone erosions	1
	Intra-articular tophus	0
	Extra-articular tophus	0
Navicular-cuneiform lateral joint	Joint effusion	1
	Synovial hypertrophy	3
	Intra-articular PD signal	1
	Bone erosions	0
	Intra-articular tophus	1
	Extra-articular tophus	0
Calcaneous-cuboid joint	Joint effusion	3
	Synovial hypertrophy	2
	Intra-articular PD signal	2
	Bone erosions	0
	Intra-articular tophus	0
	Extra-articular tophus	0

Joint	US finding	Number
Medial cuneiform-metatarsal joint	Joint effusion	2
	Synovial hypertrophy	2
	Intra-articular PD signal	2
	Bone erosions	0
	Intra-articular tophus	1
	Extra-articular tophus	0
Intermediate cuneiform-metatarsal joint	Joint effusion	2
	Synovial hypertrophy	3
	Intra-articular PD signal	1
	Bone erosions	0
	Intra-articular tophus	0
	Extra-articular tophus	0
Lateral cuneiform-metatarsal joint	Joint effusion	4
	Synovial hypertrophy	3
	Intra-articular PD signal	5
	Bone erosions	2
	Intra-articular tophus	1
	Extra-articular tophus	0
Cuboid-4th metatarsal joint	Joint effusion	0
	Synovial hypertrophy	1
	Intra-articular PD signal	1
	Bone erosions	0
	Intra-articular tophus	0
	Extra-articular tophus	0
Cuboid-5th metatarsal joint	Joint effusion	0
	Synovial hypertrophy	1
	Intra-articular PD signal	0
	Bone erosions	0
	Intra-articular tophus	0
	Extra-articular tophus	0
1 <sup>st</sup> MTP joint	Joint effusion	33 (dorsal) 6 (volar)
	Synovial hypertrophy	33 (dorsal) 2 (volar)
	Intra-articular PD signal	33 (dorsal) 0 (volar)
	Bone erosions	29 (dorsal) 1 (volar) 29 (medial)
	Double contour	33 (dorsal) 1 (volar)
	Intra-articular tophus	8 (dorsal) 0 (volar) 34 (medial)
	Extra-articular tophus	2 (dorsal) 0 (volar) 0 (medial)
2 <sup>nd</sup> MTP joint	Joint effusion	26 (dorsal) 1 (volar)
	Synovial hypertrophy	20 (dorsal) 0 (volar)
	Intra-articular PD signal	20 (dorsal) 0 (volar)
	Bone erosions	2 (dorsal) 0 (volar)
	Double contour	5 (dorsal) 1 (volar)
	Intra-articular tophus	2 (dorsal) 0 (volar)
	Extra-articular tophus	0 (dorsal) 0 (volar)
3 <sup>rd</sup> MTP joint	Joint effusion	12 (dorsal) 0 (volar)
	Synovial hypertrophy	11 (dorsal) 0 (volar)
	Intra-articular PD signal	8 (dorsal) 0 (volar)
	Bone erosions	2 (dorsal) 0 (volar)
	Double contour	4 (dorsal) 1 (volar)
	Intra-articular tophus	0 (dorsal) 0 (volar)
	Extra-articular tophus	0 (dorsal) 0 (volar)
4 <sup>th</sup> MTP joint	Joint effusion	4 (dorsal) 0 (volar)
	Synovial hypertrophy	1 (dorsal) 0 (volar)
	Intra-articular PD signal	0 (dorsal) 0 (volar)
	Bone erosions	0 (dorsal) 0 (volar)
	Double contour	0 (dorsal) 0 (volar)
	Intra-articular tophus	0 (dorsal) 0 (volar)
	Extra-articular tophus	2 (dorsal) 0 (volar)
5 <sup>th</sup> MTP joint	Joint effusion	8 (dorsal) 3 (volar)
	Synovial hypertrophy	8 (dorsal) 5 (volar)
	Intra-articular PD signal	5 (dorsal) 4 (volar)
	Bone erosions	7 (dorsal) 4 (volar)
	Double contour	0 (dorsal) 1 (volar)
	Intra-articular tophus	0 (dorsal) 0 (volar)
	Extra-articular tophus	0 (dorsal) 0 (volar)

investigated. Table I reports patient demographic and clinical data.

Clinically, 60 (4.35%) out of 1380 foot joints were considered to be inflamed, whilst at least one US finding consistent with joint inflammation was acquired in 190 (13.8%) joints. Table II shows the relationship between clinical and US findings indicative of foot joint inflammation.

The most frequent US finding indicative of joint inflammation was synovial effusion, detected in 117 (8.5%) out of 1380 joints, followed by synovial hypertrophy with or without intra-articular power Doppler signal, detected in 109 (7.9%) out of 1380 joints.

Table III illustrates the distribution of US pathological findings within the different joints of the foot.

In the 460 MTP joints, the dorsal scans allowed the detection of US findings indicative of joint inflammation in 117 joints, compared with 12 detectable using the volar views.

When the dorsal aspect of the MTP joint was compared with the volar one, 42 *versus* 4 double contour signs at the hyaline cartilage of the metatarsal head were observed.

In 34 (37%) out of 92 first MTP joints, the medial aspect of this joint was found positive for intra-articular tophaceous deposits, and MSU deposits were located in-between the collateral ligament and the first metatarsal head.

When the medial aspect of the first MTP joint was compared with the dorsal, and volar one, 29 medial, 4 dorsal, and 1 volar erosions were found.

### Discussion

The foot is frequently involved in patients with different rheumatic diseases and pain referred to the foot can be related to several underlying pathological conditions (25).

US imaging permits detection of small joint inflammation, bone erosion and tendon involvement at foot level in patients with chronic arthritis (17-22, 26-29).

Previous studies have been conducted in patients with gout predominantly looking at changes seen at the first MTP joint.

This is the first study aiming to describe the prevalence and distribution of US findings indicative of MSU crystal deposits at foot level and investigate how such findings relate to clinical examination.

We believe that the results of the present study may help in refining the US scanning protocol at foot level in patients with gout.

At the MTP joint level, the dorsal views allowed the detection of a higher number of US findings indicative of both joint inflammation and MSU crystal deposits.

Among US findings indicative of MSU crystal deposits, the most frequently found was the presence of intra-articular tophaceous deposits and the medial aspect of the first MTP joint was the site where they were most frequently observed.

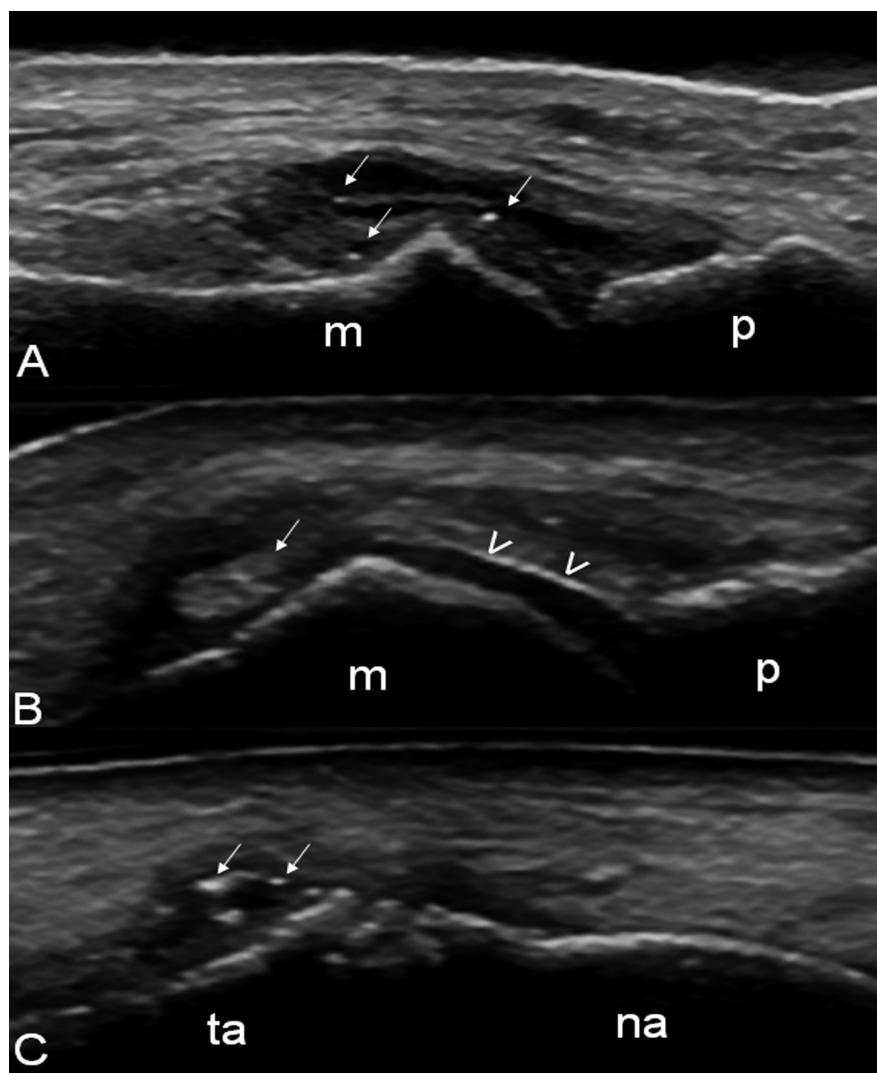
The relatively lower prevalence of the US findings indicative of extra-articular tophaceous deposits can be explained by the scanning protocol that limited the examination to the peri-articular soft-tissues not including tendons and other anatomic tissues and sites not adjacent to the foot joints that can be target areas for MSU deposits.

Moreover, the prevalence of US findings indicative of MSU crystal deposits must be interpreted in the light of the fact that 80% of the gouty patients were receiving urate lowering therapy. In fact, such a therapy was shown to induce changes in US features indicative of MSU crystal deposits (9, 12).

Our study does have some limitations. Firstly, while patients were asked not to talk with the sonographers about their clinical condition, in severe cases the presence of tophaceous deposits and/or the presence of clear clinical signs of an acute attack of gout could have undermined the blinding of the sonographers.

Secondly, disease duration and prior treatment for gout in the months before the study could have influenced the prevalence of US findings indicative of MSU crystal deposits (9, 15).

Thirdly, the study was conducted using two different US systems. Although both systems are of high quality there could have been subtle differences in



**Fig. 1.** Foot. **A-B.** First metatarsophalangeal joint in longitudinal dorsal scan, with joint in neutral position (**A**) and maximal flexion (**B**), showing intra-articular tophaceous deposits (arrows) and enhancement of the superficial margin of the hyaline cartilage (double contour) of the metatarsal head hyaline cartilage (arrowheads) (**B**). **C.** Talo-navicular joint in longitudinal dorsal scan. The arrows indicate intra-articular tophaceous deposits. m=metatarsal bone; p=proximal phalanx; ta=talar bone; na=navicular bone.

the sensitivity of Doppler assessments. A further limitation was that no assessments were made of tendon pathology and the study concentrated solely on joint findings. The full extent of US pathology may not have been documented therefore.

Finally, the US findings were evaluated only in terms of presence/absence and no quantitative assessment was performed.

Further investigation is warranted to confirm the results of the present studies and to evaluate the impact of US findings in patients with a clinical suspicion of gout.

In conclusion, US findings indica-

tive of foot joint inflammation were found to be more sensitive than clinical findings, and the first MTP and the talo-navicular joints were the anatomic sites with the highest prevalence of US signs of MSU crystal aggregates.

## References

1. GRASSI W, MEENAGH G, PASCUAL E, FILIPPUCCI E: "Crystal clear"-sonographic assessment of gout and calcium pyrophosphate deposition disease. *Semin Arthritis Rheum* 2006; 36: 197-202.
2. THIELE RG: Role of ultrasound and other advanced imaging in the diagnosis and management of gout. *Curr Rheumatol Rep* 2011; 13: 146-53.
3. DELLE SEDIE A, RIENTE L, IAGNOCCO A *et al.*: Ultrasound imaging for the rheumatolo-



- gist X. Ultrasound imaging in crystal-related arthropathies. *Clin Exp Rheumatol* 2007; 25: 513-7.
4. OTTAVIANI S, ALLARD A, BARDIN T, RICHELLE P: An exploratory ultrasound study of early gout. *Clin Exp Rheumatol* 2011; 29: 816-21.
  5. DE ÁVILA FERNANDES E, KUBOTA ES, SANDIM GB, MITRAUD SA, FERRARI AJ, FERNANDES AR: Ultrasound features of tophi in chronic tophaceous gout. *Skeletal Radiol* 2011; 40: 309-15.
  6. SCONFENZA LM, SILVESTRI E, BARTOLINI B, GARLASCHI G, CIMMINO MA: Sonoelastography may help in the differential diagnosis between rheumatoid nodules and tophi. *Clin Exp Rheumatol* 2010; 28: 144-5.
  7. FILIPPUCCI E, SCIRÈ CA, DELLE SEDIE A *et al.*: Ultrasound imaging for the rheumatologist. XXV. Sonographic assessment of the knee in patients with gout and calcium pyrophosphate deposition disease. *Clin Exp Rheumatol* 2010; 28: 2-5.
  8. CARTER JD, KEDAR RP, ANDERSON SR *et al.*: An analysis of MRI and ultrasound imaging in patients with gout who have normal plain radiographs. *Rheumatology* (Oxford) 2009; 48: 1442-6.
  9. THIELE RG, SCHLESINGER N: Ultrasonography shows disappearance of monosodium urate crystal deposition on hyaline cartilage after sustained normouricemia is achieved. *Rheumatol Int* 2010; 30: 495-503.
  10. FILIPPUCCI E, RIVEROS MG, GEORGESCU D, SALAFFI F, GRASSI W: Hyaline cartilage involvement in patients with gout and calcium pyrophosphate deposition disease. An ultrasound study. *Osteoarthritis Cartilage* 2009; 17: 178-81.
  11. RETTENBACHER T, ENNEMOSER S, WEIRICH H *et al.*: Diagnostic imaging of gout: comparison of high-resolution US versus conventional X-ray. *Eur Radiol* 2008; 18: 621-30.
  12. PEREZ-RUIZ F, MARTIN I, CANTELI B: Ultrasonographic measurement of tophi as an outcome measure for chronic gout. *J Rheumatol* 2007; 34: 1888-93.
  13. PEREZ-RUIZ F, NAREDO E: Imaging modalities and monitoring measures of gout. *Curr Opin Rheumatol* 2007; 19: 128-33.
  14. SCHUELLER-WEIDEKAMM C, SCHUELLER G, ARINGER M, WEBER M, KAINBERGER F: Impact of sonography in gouty arthritis: comparison with conventional radiography, clinical examination, and laboratory findings. *Eur J Radiol* 2007; 62: 437-43.
  15. WRIGHT SA, FILIPPUCCI E, MCVEIGH C *et al.*: High-resolution ultrasonography of the first metatarsal phalangeal joint in gout: a controlled study. *Ann Rheum Dis* 2007; 66: 859-64.
  16. WALLACE SL, ROBINSON H, MASI AT, DECKER JL, MCCARTY DJ, YU TF: Preliminary criteria for the classification of the acute arthritis of primary gout. *Arthritis Rheum* 1977; 20: 895-900.
  17. RIENTE L, DELLE SEDIE A, IAGNOCCO A *et al.*: Ultrasound imaging for the rheumatologist V. Ultrasonography of the ankle and foot. *Clin Exp Rheumatol* 2006; 24: 493-8.
  18. DELLE SEDIE A, RIENTE L, FILIPPUCCI E *et al.*: Ultrasound imaging for the rheumatologist. XXXII. Sonographic assessment of the foot in patients with psoriatic arthritis. *Clin Exp Rheumatol* 2011; 29: 217-22.
  19. IAGNOCCO A, FILIPPUCCI E, RIENTE L *et al.*: Ultrasound imaging for the rheumatologist XXXV. Sonographic assessment of the foot in patients with osteoarthritis. *Clin Exp Rheumatol* 2011; 29: 757-62.
  20. MEENAGH G, SAKELLARIOU G, IAGNOCCO A *et al.*: Ultrasound imaging for the rheumatologist XXXIV. Sonographic assessment of the painful foot. *Clin Exp Rheumatol* 2011; 29: 601-3.
  21. SCIRÈ CA, IAGNOCCO A, MEENAGH G *et al.*: Ultrasound imaging for the rheumatologist XXXIII. Sonographic assessment of the foot in early arthritis patients. *Clin Exp Rheumatol* 2011; 29: 465-9.
  22. RIENTE L, DELLE SEDIE A, SCIRÈ CA *et al.*: Ultrasound imaging for the rheumatologist. XXXI. Sonographic assessment of the foot in patients with rheumatoid arthritis. *Clin Exp Rheumatol* 2011; 29: 1-5.
  23. BACKHAUS M, BURMESTER GR, GERBER T, GRASSI W, MACHOLD KP, SWEN WA: Working Group for Musculoskeletal Ultrasound in the EULAR Standing Committee on International Clinical Studies including Therapeutic Trials. Guidelines for musculoskeletal ultrasound in rheumatology. *Ann Rheum Dis* 2001; 60: 641-9.
  24. WAKEFIELD RJ, BALINT PV, SZKUDLAREK M *et al.*: Musculoskeletal ultrasound including definitions for ultrasonographic pathology. *J Rheumatol* 2005; 32: 2485-7.
  25. FAM AG: Axial and peripheral joints: the ankle and the foot. In: KLIPPEL JH, DIEPPE PA (Eds.) *Rheumatology*, 2nd ed. London, Mosby, 1998, pp 12.12.1-12.12.12.
  26. WEINER SM, JURENZ S, UHL M *et al.*: Ultrasonography in the assessment of peripheral joint involvement in psoriatic arthritis: a comparison with radiography, MRI and scintigraphy. *Clin Rheumatol* 2008; 27: 983-9.
  27. WIELL C, SZKUDLAREK M, HASSELQUIST M *et al.*: Ultrasonography, magnetic resonance imaging, radiography, and clinical assessment of inflammatory and destructive changes in fingers and toes of patients with psoriatic arthritis. *Arthritis Res Ther* 2007; 9: R119.
  28. SZKUDLAREK M, NARVESTAD E, KLARLUND M, COURT-PAYEN M, THOMSEN HS, ØSTERGAARD M: Ultrasonography of the metatarsophalangeal joints in rheumatoid arthritis: comparison with magnetic resonance imaging, conventional radiography, and clinical examination. *Arthritis Rheum* 2004; 50: 2103-12.
  29. GRASSI W, FILIPPUCCI E, FARINAA, SALAFFI F, CERVINI C: Ultrasonography in the evaluation of bone erosions. *Ann Rheum Dis* 2001; 60: 98-103.