

Ultrasound in the assessment of musculoskeletal involvement in Systemic sclerosis

Annamaria Iagnocco, Fulvia Ceccarelli, Caterina Vavala, Angelica Gattamelata, Chiara Scirocco, Iolanda Maria Rutigliano, Guido Valesini

Dipartimento di Medicina Interna e Specialità Mediche: Reumatologia, Sapienza Università di Roma - Rome, Italy

Abstract

Systemic sclerosis (SSc) is a chronic connective disease in which the musculoskeletal involvement affects especially the hands and feet. Ultrasound (US) represents an important tool in the assessment of the joint and soft tissue involvement in this rheumatic disorder. Few authors have investigated the role of US in the evaluation of joints and peri-articular tissues in SSc patients. The current available literature regarding US applications in the assessment of musculoskeletal involvement in SSc has shown that US seems to be a useful tool in detecting the presence of inflammatory and structural abnormalities involving both joints and soft tissues. The aim of the present paper is to review the role of US in the assessment of musculoskeletal involvement in SSc.

Keywords: systemic sclerosis, ultrasound, musculoskeletal involvement.

Introduction

Systemic sclerosis (SSc) is a chronic autoimmune connective tissue disorder of not completely understood aetiology, affecting commonly women and characterized by vascular and fibrotic abnormalities in the skin and visceral organs. Musculoskeletal involvement represents the major cause of disability in SSc and it is localised especially at the level of the hands and feet [1-4].

In recent years, musculoskeletal ultrasound (US) has become a reference imaging tool in the evaluation of joint and soft tissues abnormalities in rheumatic diseases due to its advantages (non-invasiveness, limited-costs, multiregional joint evaluation during the same scanning session), and to the development of more sophisticated

equipment that offer an improved assessment of musculoskeletal structures. In particular, using US, we are able to define the presence of inflammatory abnormalities, such as synovitis, tenosynovitis, enthesitis and bursitis, and structural bone lesions, such as erosions and osteophytes. Furthermore, the application of Doppler modalities consents an estimation of the pathological vascularisation in active disease [5-7].

The aim of the present paper is to review the role of US in the assessment of musculoskeletal involvement in SSc.

Ultrasound in SSc

Over the last decade, several studies have underlined the role of US in detecting musculoskeletal inflammatory and structural abnormalities in rheumatic disease (arthritis, osteoarthritis and connective tissue disease) [8-12]. Conversely, few studies have investigated the usefulness of US in the assessment of joints and peri-articular tissue in SSc.

In 2009, Cuomo et al conducted a study to investigate the applications of US with power Doppler (PD) for the detection of hand and wrist abnormalities in SSc patients and their correlations with clinical and radiographic (X-

Received 26.03.2012 Accepted 15.04.2012

Med Ultrason

2012, Vol. 14, No 3, 231-234

Corresponding author: Prof. Annamaria Iagnocco,
Dipartimento Medicina Interna e Specialità
Mediche: Reumatologia,
Sapienza Università di Roma,
V.le del Policlinico 155, Rome – 00161, Italy.
Tel: +39 06 49974634
Fax: +39 06 49974642
Email: annamaria.iagnocco@uniroma1.it

ray) findings [13]. Forty-five SSc patients and 15 rheumatoid arthritis (RA) patients as controls, were investigated for the presence of clinically detectable abnormalities (tenderness, swelling and contractures of the MCP, PIP and DIP joints of the hands and wrists); disease activity scores (European Scleroderma Study Group activity index and disability by means of HAQ); laboratory evaluations (ANA profile, ACA or anti-Scl70 positiv) by IIF and ELISA); X-ray assessments (standard antero-posterior views of the hands and wrists); and musculoskeletal US [hand and wrist joints assessed for the presence of bone erosion, synovial effusion, synovial proliferation and PD signal; osteophytes and joint space narrowing (JSN); calcinosis]. Osteophytes were detected in 58% of patients, periarticular calcinosis in 27% JSN in 18%, joint effusions in 49%, synovial proliferation in 42%, which was associated with a PD signal indicative of vascularization in 11; 5 out of the 19 patients with synovial proliferation showed marginal bone erosions. Compared to RA patients, SSc subjects had no difference in the prevalence of joint effusions and osteophytes but demonstrated a significantly lower prevalence of synovial proliferation, PD signal, erosions and JSN. As expected, calcinosis was observed only in SSc patients. The prevalence of synovitis as detected by US was found to be significantly higher than that found by clinical examination (26 vs 15 out of 45 cases). US-detected synovitis showed a positive correlation with the level of CRP, while no correlation with disease duration, clinical subset, activity index, HAQ-DI, profile autoantibodies, presence of the RF was found. Finally, US showed a significantly higher number of joints with osteophytes than X-rays (59 vs 27%). The authors concluded that, in patients affected by SSc, US was able to detect hand/wrist involvement with a high prevalence respect to clinical examination: US synovitis was found in 58% of the 45 SSc patients in comparison with 33% with clinically detectable articular manifestations, according to data from studies conducted on RA patients. However, US did not show a higher sensitivity respect to X-rays in detecting features of joint involvement such as JSN, calcinosis or erosions in SSc patients, probably due to the limited number of SSc patients with erosive disease.

In the study conducted by Generini in 2009, US assessment of the hand and wrist joints was performed [14]. The presence of bone erosions on longitudinal and transverse scans in the MCP and PIP was found in 8/15 patients: two with bone microerosions (<1 mm), 3 with erosions between 2 and 4mm and 3 with erosions >4 mm. Synovitis was detected in 3 patients with erosions. One patient presented synovitis and joint effusion of the II PIP. In five cases, tenosynovitis was detected in longitudinal and transverse planes.

In a recent review Boutry et al described the imaging features of musculoskeletal involvement in SSc, including radiographic, sonographic and magnetic resonance (MR) findings [15]. They concluded that X-ray remains the mainstay technique for diagnosis and monitoring of SSc; MR can be useful to assess bone erosion and synovitis, and in detecting overlap conditions (SSc and RA or SSc and myositis), while US is able to visualize digital calcifications even before conventional X-ray.

More recently, Tagliafico et al evaluated by US the A1 pulley thickness in 28 SSc patients and in 40 healthy controls, to describe the possible usefulness of this measurement in the assessment of hand mobility in SSc [16]. The duration of disease and hand mobility using the HAMIS test (Hand Mobility in Scleroderma Test) was calculated in all patients. US was performed by 2 expert radiologists who assessed volar longitudinal and transverse view of each finger of both hands; pulley thickness was measured on transverse planes at A1 pulley level. The A1 pulley thickness was greater in SSc patients compared to controls (0.38 ± 0.11 mm vs 0.26 ± 0.07 mm; $p < 0.05$); furthermore a strongly correlation was found between pulley thickness and both HAMIS test ($r = 0.78$; $p < 0.018$) and disease duration ($r = 0.54$; $p < 0.05$). On the basis of these results the authors concluded that US can be considered a useful tool in the assessment of hand disability in scleroderma.

In 2010, an interesting ultrasonographic study evaluated the occurrence of carpal tunnel syndrome (CTS) in asymptomatic SSc patients and its correlation with clinical features [17]. Sixty-four SSc patients and 30 healthy controls were recruited. Duration of disease, subset (limited, diffuse), phase of skin involvement, modified Rodnan skin score (mRSS) and friction tendon rub were evaluated by 2 different rheumatologists. By US examination, median nerve cross-sectional area (MNA), transverse (major axis) (MNT) and anteroposterior (minor axis) (MNAP) diameters were measured on a volar scan at the proximal inlet of carpal tunnel in the transverse plane between the scaphoid tubercle and the pisiform bone; furthermore the MN flattening ratio (MNFR) was calculated. The authors used the cut off proposed by Duncan for MNA > 9 mm² and MNFR > 3.3 mm², and by Naranjo for MNA > 12 mm². Statistically significant results were found for MNA ($p < 0.001$), MNT ($p < 0.005$) and MNFR ($p < 0.005$) in SSc patients in comparison with healthy subjects. No correlations between the median nerve and SSc clinical features were found. On the basis of these data the authors concluded that CTS can be present in all disease phases and independently to clinical features in asymptomatic SSc patients.

More recently Chitale and colleagues compared US and magnetic resonance imaging (MRI) in detecting

synovial inflammation in a limited number of SSc patients with arthralgia [18]. Seventeen SSc patients had a baseline US of both hands and wrists. Thirteen of them had a second US six months later; 8 out of these 13 had MRI of their most symptomatic hand. US was performed by a sonographer who evaluated both hand and wrist joints for the occurrence of synovitis, and extensor and flexor tendons at the level of wrist to assess the presence of tenosynovitis. On US, evidence of inflammation were identified in a high proportion of patients; in particular tenosynovitis was present in 8 of 17 (47%) at baseline examination and in 6 of 13 (46%) at second US, while synovitis was found in 1 of 17 (6%) and in 3 of 13 (23%) at baseline and second US, respectively. No erosions were individualized on US. MRI showed signs of synovitis in all 8 (100%) patients and tenosynovitis in 7 out of 8 (88%); furthermore MRI showed bone oedema and erosions in 63% and 75% of the 8 patients, respectively. In conclusion MRI seems to be more sensitive than US in the assessment of synovial inflammation in SSc.

In 2011, Cuomo et al used US to investigate the tendon friction rubs (TFR) in 55 SSc patients [27 with a limited form (lcSSc) and 28 with a diffuse form (dcSSc)] and in 30 healthy controls [19]. Tendon involvement was assessed by physical examination and US to evaluate tendon features, tendon sheath and retinacula in patients with or without clinical features of TFRs. US was performed on MCP areas (extensor and flexor tendons), wrist (extensor and flexor tendons), knees (patellar) and ankles (anterior, posterior, medial and lateral tendons). The thickness of retinacula was calculated using measurement calipers. Tenosynovitis and/or tendinitis were present in 21 patients. Retinacula had a hyperechoic aspect compared to adjacent tendons in SSc patients, while the aspect was hypoechoic respect adjacent tendons in healthy controls. Statistically significant results were found concerning the measurement of thickness of the retinacula on both wrist extensor and ankle anterior in dcSSc patients with TFRs compared to healthy subjects ($p = 0.001$ and $p = 0.002$), in dcSSc with TFRs compared to lcSSc ($p = 0.002$ and $p = 0.003$) and in dcSSc with TFRs in comparison with dcSSc without TFRs ($p = 0.001$ and $p = 0.003$).

In conclusion, this brief analysis of the current available literature about US applications in the assessment of musculoskeletal involvement in SSc, evidences that sonography is a useful imaging technique for evaluating a wide range of inflammatory (fig 1) and structural abnormalities involving both joints and soft tissues. It seems to be of value particularly in the assessment of hand and wrist joints involvement, giving an added value to clinical examination in SSc patients. For the limited

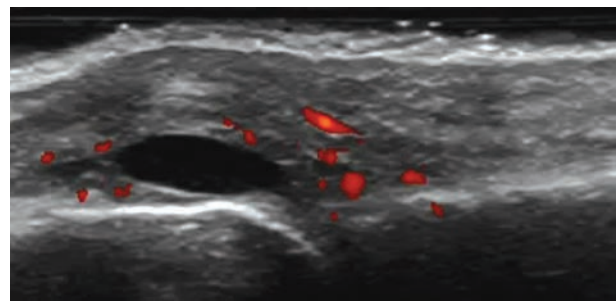


Fig 1. Ultrasound of the II metacarpophalangeal joint in a patient with SSc, demonstrating the presence of joint effusion, synovial hypertrophy and pathological vascularization at power Doppler assessment; these findings are indicative of active synovitis

number of publications on this field, additional studies on a greater number of patients and in multiple joints are recommended.

References

1. Hinchcliff M, Varga J. Systemic sclerosis/scleroderma: a treatable multisystem disease. *Am Fam Physician* 2008; 78: 961-968.
2. La Montagna G, Sodano A, Capurro V, Malesci D, Valentini G. The arthropathy of systemic sclerosis: a 12 month prospective clinical and imaging study. *Skeletal Radiol* 2005; 34: 35-41.
3. Baron M, Lee P, Keystone EC. The articular manifestations of progressive systemic sclerosis (scleroderma). *Ann Rheum Dis* 1982; 41: 147-152.
4. Avouac J, Guerini H, Wipff J, et al. Radiological hand involvement in systemic sclerosis. *Ann Rheum Dis* 2006; 65: 1088-1092.
5. Grassi W, Cervini C. Ultrasonography in rheumatology: an evolving technique. *Ann Rheum Dis* 1998; 57: 268-271.
6. Iagnocco A, Epis O, Delle Sedie A, et al. Ultrasound imaging for the rheumatologist. XVII. Role of colour Doppler and power Doppler. *Clin Exp Rheumatol* 2008; 26: 759-762.
7. Filippucci E, Iagnocco A, Meenagh G, et al. Ultrasound imaging for the rheumatologist. *Clin Exp Rheumatol* 2006; 24: 1-5.
8. Filippucci E, Iagnocco A, Meenagh G, et al. Ultrasound imaging for the rheumatologist VII. Ultrasound imaging in rheumatoid arthritis. *Clin Exp Rheumatol* 2007; 25: 5-10.
9. Naredo E, Bonilla G, Gamero F, Uson J, Carmona L, Laffon A. Assessment of inflammatory activity in rheumatoid arthritis: a comparative study of clinical evaluation with grey scale and power Doppler ultrasonography. *Ann Rheum Dis* 2005; 64: 375-381.

10. Riente L, Delle Sedie A, Filippucci E, et al. Ultrasound imaging for the rheumatologist IX. Ultrasound imaging in spondyloarthritis. *Clin Exp Rheumatol* 2007; 25: 349-353.
11. Meenagh G, Filippucci E, Iagnocco A, et al. Ultrasound imaging for the rheumatologist VIII. Ultrasound imaging in osteoarthritis. *Clin Exp Rheumatol* 2007; 25: 172-175.
12. Riente L, Delle Sedie A, Filippucci E, et al. Ultrasound imaging for the rheumatologist XIV. Ultrasound imaging in connective tissue diseases. *Clin Exp Rheumatol* 2008; 26: 230-233.
13. Cuomo G, Zappia M, Abignano G, Iudici G, Rotondo A, Valentini G. Ultrasonographic features of the hand and wrist in systemic sclerosis. *Rheumatology* 2009; 48: 1414-1417.
14. Generini S, Steiner G, Miniati I, et al. Anti-hnRNP and other autoantibodies in systemic sclerosis with joint involvement. *Rheumatology (Oxford)* 2009; 48: 920-925.
15. Boutry N, Hachulla E, Zanetti-Musielak C, Morel M, Demondion X, Cotten A. Imaging features of musculoskeletal involvement in systemic sclerosis. *Eur Radiol* 2007; 17: 1172-1180.
16. Tagliafico A, Panico N, Serafini G, Ghio M, Martinoli C. The thickness of the A1 pulleys reflects the disability of hand mobility in scleroderma. A pilot study using high-frequency ultrasound. *Eur J Radiol* 2011; 77: 254-257.
17. Bandinelli F, Kaloudi O, Candelieri A, et al. Early detection of median nerve syndrome at the carpal tunnel with high-resolution 18 MHz ultrasonography in systemic sclerosis patients. *Clin Exp Rheumatol* 2010; 28 (5 Suppl 62): S15-S18.
18. Chitale S, Ciapetti A, Hodgson R, et al. Magnetic resonance imaging and musculoskeletal ultrasonography detect and characterize covert inflammatory arthropathy in systemic sclerosis patients with arthralgia. *Rheumatology (Oxford)* 2010; 49: 2357-2361.
19. Cuomo G, Zappia M, Iudici M, Abignano G, Rotondo A, Valentini G. The origin of tendon friction rubs in patients with systemic sclerosis: a sonographic explanation. *Arthritis Rheum* 2012; 64: 1291-1293.