

AperTO - Archivio Istituzionale Open Access dell'Università di Torino

## Quantification of facial movements by surface laser scanning

**This is a pre print version of the following article:**

*Original Citation:*

*Availability:*

This version is available <http://hdl.handle.net/2318/86797> since

*Published version:*

DOI:10.1097/SCS.0b013e3181f6c46d

*Terms of use:*

Open Access

Anyone can freely access the full text of works made available as "Open Access". Works made available under a Creative Commons license can be used according to the terms and conditions of said license. Use of all other works requires consent of the right holder (author or publisher) if not exempted from copyright protection by the applicable law.

(Article begins on next page)

This is the author's final version of the contribution published as:

VERZE' L.; NASI A.; QUARANTA F.; VASINO V.; PRINI V.; RAMIERI G.. Quantification of facial movements by surface laser scanning. THE JOURNAL OF CRANIOFACIAL SURGERY. 22 (1) pp: 60-65.  
DOI: 10.1097/SCS.0b013e3181f6c46d

The publisher's version is available at:

<http://content.wkhealth.com/linkback/openurl?sid=WKPTLP:landingpage&an=00001665-201101000-00013>

When citing, please refer to the published version.

Link to this full text:

<http://hdl.handle.net/2318/86797>

**Journal of Craniofacial Surgery**

**Editor-in-Chief**

**Mutaz B. Habal MD, FRCSC**

**Tampa Bay Craniofacial Center, Inc.**

**Tampa, Florida**

**Manuscript submission**

We have enclosed our manuscript entitled: "A method for the quantification of facial movements by use of surface laser scanning" for publication on the *Journal of Craniofacial Surgery*.

The manuscript describes an easy, non-contact and effective method to quantify facial movements in normal and pathological conditions. It may be usefully applied to the investigation and clinical monitoring of different medical and surgical pathologies.

This paper is unpublished and it is not under current consideration elsewhere.

Best regards.

Laura Verzé

February, 17, 2010

Laura Verzé, MD

Dipartimento di Anatomia, Farmacologia e Medicina Legale - Sede Medicina Legale

C.so Galileo Galilei 22 10126, Torino, Italy

Tel. (39) 011 6705622, Fax (39) 011 6635576

e-mail: [laura.verze@unito.it](mailto:laura.verze@unito.it)

## A METHOD FOR THE QUANTIFICATION OF FACIAL MOVEMENTS BY USE OF SURFACE LASER SCANNING

VERZE' Laura MD, <sup>1</sup>NASI Andrea MD, QUARANTA Federico MD, VASINO Valentina MD, PRINI Virginia PhD, <sup>2</sup>RAMIERI Guglielmo MD DDS

Department of Anatomy, Pharmacology and Legal Medicine;

<sup>1</sup> Santa Croce Hospital, Cuneo, Italy;

<sup>2</sup> Department of Maxillofacial Surgery, University of Turin, Italy

Running title: Quantification of facial movements

Send Correspondence to:

Dr. Laura Verzé, MD

Department of Anatomy, Pharmacology and Legal Medicine, University of Turin

C.so Galileo Galilei 22, 10126 Torino (Italy)

Tel: +39.011.6705622

Fax: +39.011.6635576

E-mail: [laura.verze@unito.it](mailto:laura.verze@unito.it)

Supported by grants from the "Compagnia di San Paolo di Torino" (Turin, Italy) and "Regione Piemonte: Progetti di ricerca sanitaria finalizzata" (Italy).

### ABSTRACT

Quantification of facial mimic ability represents a need for comparative investigation in facial medicine and surgery. The aim of the present study was to develop a simple, non-invasive, repeatable 3D method for measuring facial mobility in clinical and research set-up.

The faces of 20 healthy adult subjects (10 males and 10 females) and 12 primary-school children (6 males and 6 females), without cranio-facial pathologies or previous treatments, were captured by a Cyberware 3030RGB laser scanner in rest position and during voluntary movements. Data were processed by Cyberware Echo and Inus Rapidform 2004 softwares.

Each movement was assigned a main landmark. The facial movements were described in terms of surface displacement using "clearance vector mapping" and 3D tracing of the skin landmarks. The average landmark displacement vector was also calculated for every movement.

The study showed that movements were characterised by similar displacement in the same facial areas in all subjects. Minor differences were recorded between adult subjects and children. Descriptive statistics concerning the amount and direction of movements were provided.

A case of unilateral post-surgical nerve palsy was prospectively analysed to test applicability of the method in clinical investigation. A numerical scale based on the mean movements was constructed and used to monitor recovery of function.

The method developed appears easy, non-contact and effective to quantify facial movements in normal and pathological conditions. It may be usefully applied to the investigation and clinical monitoring of different medical and surgical pathologies.

Key words: 3D imaging, adults, children, facial movements analysis, facial palsy.

## INTRODUCTION

Facial expressions become altered in different pathologies and malformations, either because of organic or neuro-psychological deficits. Clinical staging and evaluation of treatment outcome could be advantaged by the possibility of measuring the changes in facial expression in a repetitive, comparable way that could be handled statistically. Until now, studies of facial expressions have utilised two different approaches: clinical observation (1) and electromyography (2). The limits of the first are subjectivity, lack of quantification, and poor repeatability. Electromyography is free of these drawbacks, but it is invasive and does not allow the evaluation of voluntary facial mobility as a whole.

The study of the facial surface and of its changes has been penalised in the past by the problems deriving from the complex anatomy and postural variability that affect both capture and analysis of quantitative data. Modern three-dimensional [3D] technology (3) has been usefully applied in recent years to support facial morphometry in different clinical conditions (4-12). Among the different methods, surface laser scanning (13), integrated photographic/radiographic technique (14), and stereophotogrammetry (13-16) allow recording of a variety of facial postures which can be compared with the basal resting position.

The 3D displacements of standardised cutaneous points during facial mimic have been also investigated (5,6,17,18). Previous studies have demonstrated the potential of the technique to represent and measure facial surface displacement (19, 8-11, 19, 20).

This paper reports the results obtained by use of an innovative method based on optical scanned data to assess mimic movements in normal and pathological conditions in a non-invasive manner, designed to be employed in adults and children. A case of surgical facial palsy has been also prospectively investigated to test clinical applicability of the method.

## MATERIAL AND METHODS

### Normal subjects

20 adults (10 males and 10 females, aged 18-30 years), and 12 primary-school children (6 boys and 6 girls, aged 7-11 years) were recruited for the study. All subjects were healthy and free from dento-facial anomalies and with no previous history of craniofacial injury or treatment. Informed consent was obtained from all participants.

### Scanning protocol

Facial surface data were acquired using a Head and Face Colour 3D Scanner (3030RGB; Cyberware, Inc., Monterey, California). The scanning method took into consideration previous observations concerning the positioning of the subject and environmental conditions (21), in order to improve dimensional precision and repeatability of scanning models, increase inter-observer consistency, and to reduce artefacts. Before acquisition, anatomical points of the face were marked with sticky paper labels bearing a central red spot (landmarks). The landmarks, chosen from classical anthropometry (4), were: trichion (tr), glabella (g), palpebrale superius (ps), superciliare (sci), endocanthium (en), exocanthium (ex), pronasale (prn), alar curvature point (ac), cheilion (ch), pogonion (pg), and tragion (tg). A further landmark, the midpoint of the axis tr-g ( $_{midtr-g}$ ) was also chosen (Fig. 1A, 1B).

All subjects were scanned several times. They were first acquired with the head in natural position (nhp), the eyes closed and teeth in occlusion (rest scan) and then after assuming six basic facial expressions: brows lift, frowning, eyes closure, grimace, smile, and lip purse (mimic scans).

The data acquired were transferred to a graphics workstation for viewing and elaboration with Cyberware Echo software (Cyberware Inc., Monterey, California).

### 3D model reconstruction and measurement

Facial surface reconstruction, multiple scan alignment and measurements were carried out using Rapid Form 2004 software (INUS Technologies Inc., Seoul, South Korea). For each movement, the mimic scan was recorded on the rest scan, by use of a semi-automated regional registration on the unchanged areas.

Representation of the displacement of homologous points (clearance vector mapping, CVM; Fig. 2) allowed evaluation of the symmetry and direction of soft tissue displacement during movements. Areas identified as the most involved led to selection of the study landmarks (one for each movement) among the 18 landmarks positioned on the subjects' face during scanning. They were: sci for brows lift and frowning, ps for eyes closure, ac for grimace, ch for smile and lip purse (Fig. 1A, 1B).

Means and standard deviations of the landmark displacement, for each movement, were calculated for right and left sides of the face, for adults and children, and for males and females, and statistically compared using the t-test (with p set at 0.05). For every movement, the 3D displacement vector was also represented in each subject (Fig. 3), and expressed on the horizontal x- (outward, inward), vertical y- (upward, downward) and horizontal z-planes (backward, forward).

#### Case study

The recovery of mimic activity was prospectively studied on a 65 year old man presenting a post-surgical left facial nerve palsy. The patient, presenting a negative history for neurological disease, underwent a superficial parotidectomy for pleomorphic adenoma and reconstruction of the defect with fascial-fat graft. There was no intra-operative evidence of direct damage to the facial nerve branches. Complete facial palsy was observed the day after surgery. Steroids (Betametasone 4mg/day for 1 week than 2mg/day) were administered for 3 weeks and physiotherapy was started after 1 week; complete clinical recovery was obtained after 5 months.

Facial scans were obtained 1, 2, 4, 6, and 7 months after the operation. Data were processed as illustrated above and calculated for right and left sides of the face.

## RESULTS

#### Practicability of the method.

During registration, both adults and children were collaborative and the tests could be carried out effectively on all subjects. Children had difficulty in executing some movements upon verbal request; however, they managed to imitate facial expressions, particularly the movements in the upper and middle areas of the face.

The average time required to accomplish all facial scans in a single subject was 30 minutes, including explanation of the procedure, patient and landmarks positioning and scanning. The single facial scan, during which the subject was requested to remain still, lasted 16 seconds. For children some of the explanation took longer, and in some cases, the best method of explanation was imitation.

Elaboration of the recorded data, including shell-shell registration, CVM and linear measurements on each movement, required approximately one hour.

#### 3D model analysis

CVM analysis showed that each movement led to similar soft tissue deformation in the same facial areas in all subjects ("basic mimic movement", Fig. 2). The six selected movements appeared able to represent motility in the whole face; frowning and brows lift involved soft tissue displacements in the upper face. Brows lift notably involved forehead skin displacement, while during frowning only the glabellar area was involved. Eyes closing resulted in movement limited to the orbital region. Voluntary smiling involved the lower two thirds of the face; during lip purse, only tissues of the inferior third of the face were involved (Fig. 2). Grimace appeared the most complex single movement: soft tissue displacement always involved the middle third of the face, but also, in a great number of subjects, oral, ocular and forehead areas.

In adults and children, in a few individuals, CVM revealed specific cutaneous displacements variably present in other areas of the face. These movements were often asymmetric and they were considered "accessory" movements. Frequently they appeared in subjects with greater facial mobility.

Though a slight asymmetry was commonly observed in a specific subject, no significant difference was detected between the two sides or between sexes.

#### Displacement of landmarks for each expression

Study of the landmarks displacement revealed that only a few of these were constantly involved in the movements considered. They were: superciliare (sci), palpebrale superius (ps), alar curvature point (ac), and cheilion (ch). These were called “tracing landmarks” and here we only report the displacements of these landmarks (Fig. 1).

For each subject, tracing landmarks displacement presented few differences between the left and right side and in adult males and females. These differences were found not significant (Table 1).

In children, differences between the left and right side were not found (Table 2). Significant differences between boys and girls were observed during frowning and grimace ( $p < 0.05$ ).

The mean amplitude of landmark displacements was greater in adults than in children. Differences between adults and children were significant (Table 3).

#### Vectors

The direction of landmark displacement (Table 4, Fig. 3) was very similar in adults and children. Variable displacement of landmarks was observed in a few cases in adults and children in brows lift, grimace and lip purse. In general, landmark displacement direction in adults was more constant than in children. Children investigation seemed to be affected by some difficulty in executing the type of movement requested, especially in the upper part of the face.

#### Clinical applicability: patient study

In order to evaluate the clinical applicability of the method, it was used to monitor the recovery of facial activity in a patient suffering from post-surgical complete facial nerve palsy, on the left side (Fig. 4, 5).

The direction of displacement of the tracing landmarks was significantly different on the left (affected) and right (normal) sides of the face. In particular, an abnormal (reverse) movement was evident on the left side during smiling because of the traction of the the contro-lateral muscles (Fig. 4). The direction of displacement of the tracing landmarks was less evident during frowning and knitting brows, while absence of movement was observed on the paralysed side during eye closure and grimace. This difference was associated with enhancement of normal landmark displacement on the right (normal side) in the early postoperative period and absence or reduction, on the left. It was particularly evident during smile, grimace, and lip purse (Fig. 4).

The progressive normalisation of landmark displacement, considering both amplitude and vector, was registered, consistently to the clinical recovery of facial mobility. Seven months after surgery both clinical observation and optical scanning showed complete recovery of facial mobility (Fig. 4, 5).

## DISCUSSION

This study indicates that 3D technologies may be applied to visualise, quantify and archive voluntary facial expression, in normal and pathological conditions. Optical scanning is a simple, relatively low-cost technology, completely non-invasive and well accepted by human subjects and patients.

Problems regarding 3D studies on the face concern acquisition, data registration, movement representation, analysis, and availability of reference normative parameters. The precision of laser colour 3D laser scan acquisition and data registration has already been established (21).

An approach that has been largely used for evaluating facial changes is the comparison of the entire face, through colour analysis of the displacement of the two registered surfaces of the same subject in different conditions (e.g. pre- and post-surgical facial surface) (22). This method allows visualisation and quantification of displacement as a whole; however, it fails to show the displacement of really homologous points. The displacement of landmarks in 3D was found reliable for the study of disturbances in facial movement related to facial asymmetry in normal or pathological conditions (5). Little agreement has been reached on which landmarks are the most representative (23, 24, 25).

The 3D method we present is a prototype, relatively easy and rapid, that integrates comparison of the entire face with clearance vector mapping and landmark displacement, and leads to acquisition of much more complete and complementary data.

CVM allowed to visualise and to quantify repeatable movements constantly involved in facial expressions in all subjects. This method is intuitive and provides a general representation of the movement, its symmetry, and the areas involved. It resulted that facial mimic involves constant areas of the face and shows a characteristic pattern of soft tissue displacement for each expression, largely comparable in adult subjects and children.

Description of the normal landmark displacement vector for each movement allowed to recognise abnormal movements, when present.

Taking into consideration a single landmark for every movement greatly simplifies the analysis of results. The movements in adults were larger than in children. Previous studies indicated that age and gender (19) can affect facial dynamics, and males were found to show the largest facial movements; this was supported by the hypothesis that some differences can be explained by the size of underlying facial bone structures (8, 18).

In adults, differences between sexes and left and right side were not significant. In children, differences between left and right side were noted and were particularly evident in the middle and lower parts of the face (26), but there is no agreement about this observation (10, 11, 19). Throughout our study, we found that adults were much more symmetric and repetitive in the direction of their movements than children.

Previous studies have found that the ability to produce facial movements intentionally, both basic facial actions and complex expressions, improved with age. Improvement was greater between 5 and 9 than between 9 and 13 (27). Accordingly, we observed in primary school children (aged 9-11) that the execution of some movements was not intuitive, like for brows lift, frowning and grimace, while for others, as eye closure, lip purse and smiling, it was very easy. In agreement with previous studies, it was observed that the performance improved when the children had the option to imitate or seeing themselves in a mirror (27).

The application of the method to a clinical case showed that it is possible to use it for monitoring clinical cases. The study of the patient during recovery from facial palsy showed that the mobility of both the paralysed and the healthy side were altered. This was clearly seen with clearance vector mapping. Landmark displacement amplitude and movement direction showed quantitatively how the two sides of the face were differently affected at different times after the surgery. The normalisation of vector directions and of the amount of landmark displacement was found to be easily quantified and it resulted an objective indicator of recovery of mobility over time.

In this study, the problem of facial mobility evaluation using quantitative methods has been tackled. The results call for further investigation to better understand the applicability of this approach in clinical research.

## REFERENCES

1. Paletz JL, Manktelow RT, Chaban R. The shape of a normal smile: implications for facial paralysis reconstruction. *Plast Reconstr Surg* 1994;93:784-9
2. Wolf K, Mass R, Ingenbleek T, Kiefer F, et al. The facial pattern of disgust, appetite, excited joy and relaxed joy: an improved facial EMG study. *Scand J Psychol* 2005; 46(5):403-9
3. Gross M, Trotman CA, Moffat K. A comparison of three dimensional and two dimensional analyses of facial motion. *Angle Orthod* 1996;66:189-194
4. Farkas LG. *Anthropometry of the head and face*. New York: Raven Press 1994



5. Frey M, Jenny A, Giovanoli P, et al. Development of a new documentation system for facial movements as a basis for the international registry for neuromuscular reconstruction in the face. *Plast Reconstr Surg* 1994;93:1334-49
6. Trotman CA, Faraway J, Silvester KT, et al. Sensitivity of a method for the analysis of facial mobility. I. Vector of displacement. *Cleft Palate Craniofac J* 1998;35:132-41
7. Kusnoto B, Evans CA. Reliability of a 3D surface laser scanner for orthodontic applications. *Am J Orthod Dentofacial Orthop* 2002;122:342-8
8. Trotman CA, Faraway JJ. Modelling facial movement: I. A dynamic analysis of differences based on skeletal characteristics. *J Oral Maxillofac Surg* 2004;62:1372-9
9. Trotman CA, Faraway JJ, Phillips C. Visual and statistical modelling of facial movement in patients with cleft lip and palate. *Cleft Palate Craniofac J* 2005;42:245-54
10. Cacou C, Richards R, McGrouther DA. Potential of surface laser scanning to measure facial movement. *Plast Reconstr Surg* 1995;99:982-9
11. Coulson SE, Croxson GR, Gilleard WL. Three-dimensional quantification of the symmetry of normal facial movement. *Otol Neurotol* 2002;23:999-1002
12. Hajeer MY, Ayoub AF, Millet DT. Three-dimensional assessment of facial soft-tissue asymmetry before and after orthognathic surgery. *Br J Oral Maxillofac Surg* 2004;42:396-404
13. Moss JP, Coombes AM, Linney AD. Methods of three dimensional analysis of patients with asymmetry of the face. *Proc Finn Dent Soc* 1991;87:139-49
14. Ferrario VF, Sforza C, Poggio CE, et al. Distance from symmetry: a three-dimensional evaluation of facial asymmetry. *J Oral Maxillofac Surg* 1994; 52:1126-32
15. Ras F, Habets LL, van Ginkel FC, et al. Method for quantifying facial asymmetry in three dimensions using stereophotogrammetry. *Angle Orthod* 1995;65:233-9
16. Ras F, Habets LMH, van Ginkel, et al. Quantification of facial morphology using stereophotogrammetry – demonstration of a new concept. *J of Dentistry* 1996;24:369-374
17. Trotman CA, Faraway JJ. Sensitivity of a method for the analysis of facial mobility. II. Interlandmark separation. *Cleft Palate Craniofac J* 1998;35:132-41
18. Trotman CA, Stohler CS, Johnston LE J. Measurement of facial soft tissue mobility in man. *Cleft Palate Craniofac J* 1998;35:16-25
19. Giovanoli P, Tzou CH, Ploner M, et al. Three-dimensional video-analysis of facial movements in healthy volunteers. *Br J Plast Surg* 2003;56:644-52
20. Nooreyazdan M, Trotman CA, Faraway JJ. Modelling facial movement: II. A dynamic analysis of differences caused by orthognathic surgery. *J Oral Maxillofac Surg* 2004;62:1380-6
21. Ramieri GA, Spada MC, Nasi A, et al. Reconstruction of facial morphology from laser scanned data - Part I: Reliability of the technique. *Dentomaxillofac Radiol* 2006;35:158-64.

22. McCance AM, Moss JP, Fright WR et al. Three-dimensional analysis techniques-Part 3: Color-coded system for three-dimensional measurement of bone and ratio of soft tissue to bone: the analysis. *Cleft Palate Craniofac J* 1997; 34: 52-57
23. Frey M, Giovanoli P, Gerber H, et al. Three-dimensional video analysis of facial movements: a new method to assess the quantity and quality of the smile. *Plast Reconstr Surg* 1999;104:2032-9
24. Ghani S, Mannan A, Kaucer A, et al. Facial motion analysis of acid burn victims--development of a new facial motion impairment index. *Burns* 2007;33:495-504
25. Hontanilla B, Aubá C. Automatic three-dimensional quantitative analysis for evaluation of facial movement. *J Plast Reconstr Aesthet Surg* 2008;61:18-30
26. Ferrario VF, Sforza C, Puleo A, et al. Three-dimensional facial morphometry and conventional cephalometrics: a correlation study. *Int J Adult Orthodont Orthognath Surg* 1996;11:329-338
27. Ekman P, Roper G, Hager JC. Deliberate facial movement. *Child Development* 1980;51:866-891

### Figure legends

Fig 1. Skin landmarks distribution represented in frontal (A) and lateral (B) view. The “tracing landmarks” used in the study were: superciliare (sci), palpebrale superius (ps), alar curvature point (ac), and cheilion (ch).

Fig 2. Clearance vector mapping in adults (in the middle) and children (on the right). A: brows lift, B: frowning, C: eyes closure, D: grimace, E: smile, F: lip purse. In all subjects a similar map of color scale was present for every movement.

Fig 3. Example of average vector representation during smile. A: frontal view. Landmark (ch) displacement and measurement of linear displacement. B: representation of the vector of displacement of ch during smiling. C: representation of the displacement vectors during smile in each subject (green) and the averaged vector (red).

Fig 4. Clinical case of peripheral lesion of the left facial nerve. Facial mobility evaluation during smile: note the reduced mobility (A) and anomalous mobility direction in the left facial area (B) 1, 2, 4, and 7 months after surgery (from left to right).

Fig 5. Clinical case of peripheral lesion of the left facial nerve. Amount of skin landmark movement observed in the normal (right) and paralyzed sides (left) at 1, 2, 4, and 6 months.

Fig 1.




Fig 2.

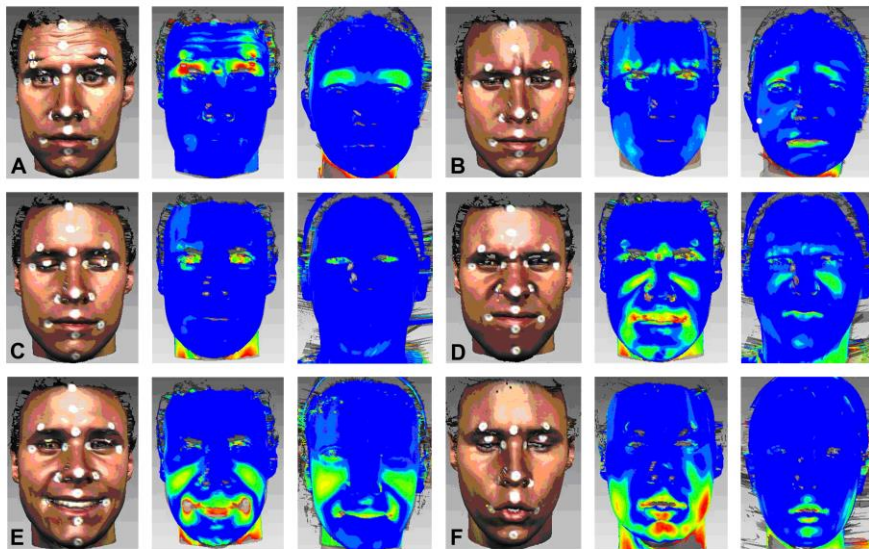


Fig 3.

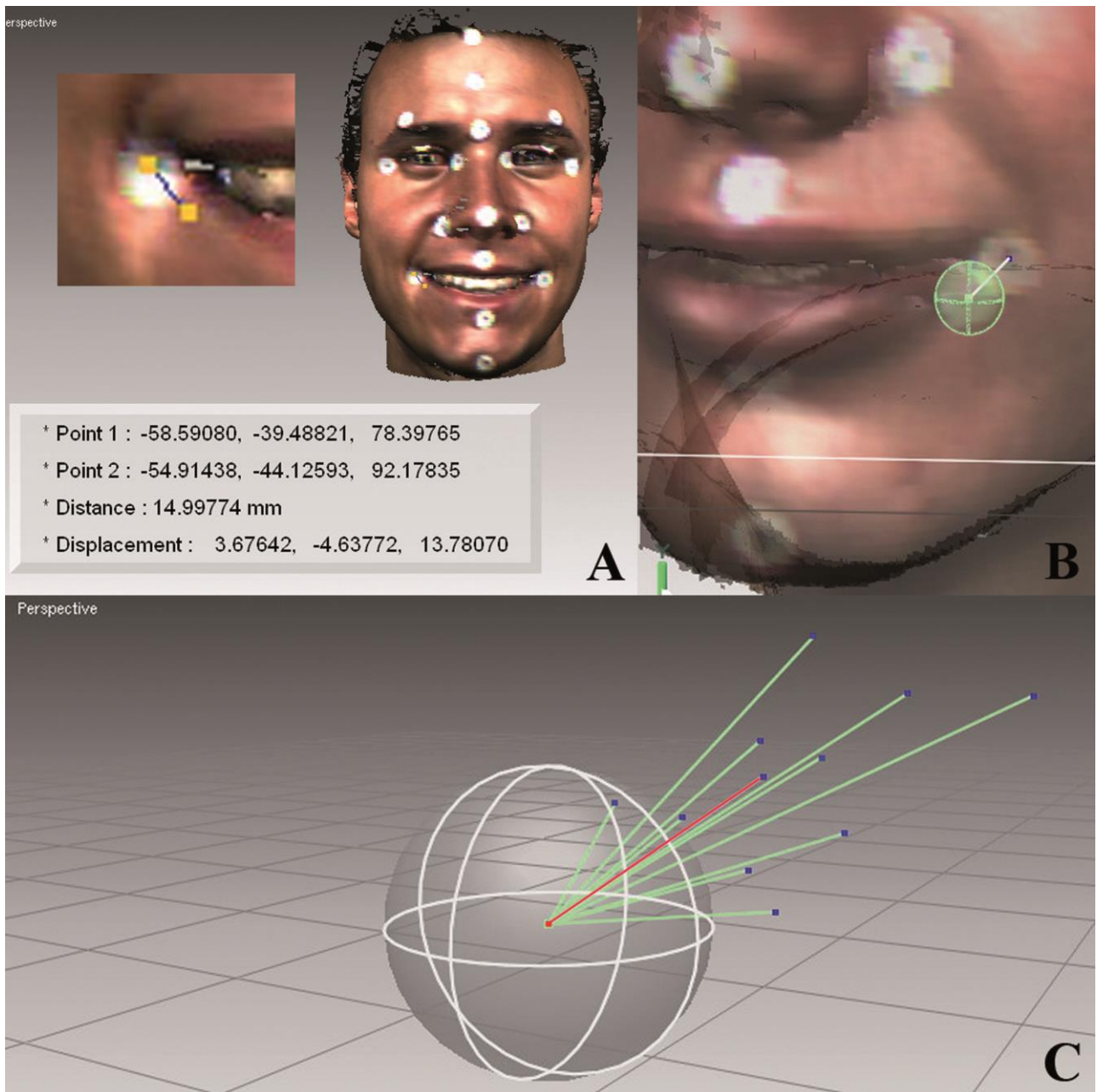


Fig 4.


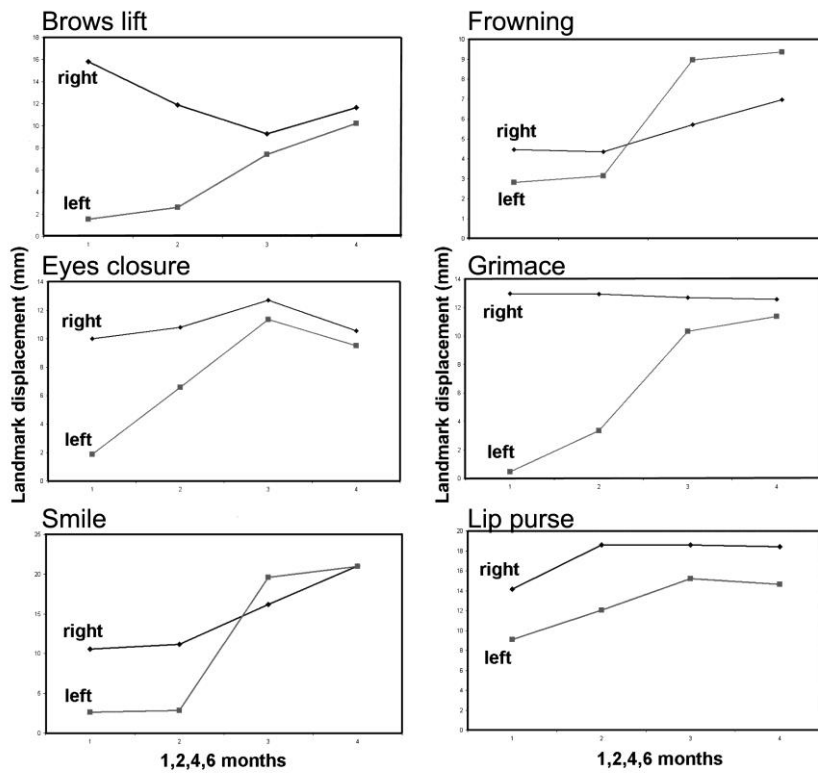


Fig 5.



	Brows lift	Frowning	Eye closure	Grimace	Smile	Lip purse
M right	6.93 ± 2.13	6.65 ± 0.98	8.64 ± 2.35	10.93 ± 2.32	10.96 ± 4.12	8.73 ± 3.07
F right	6.60 ± 2.30	7.96 ± 2.40	9.10 ± 1.75	7.38 ± 1.96	10.20 ± 2.95	7.33 ± 2.71
M left	6.09 ± 2.91	7.25 ± 1.76	7.74 ± 1.80	10.23 ± 2.50	10.09 ± 3.29	8.11 ± 3.21
F left	6.58 ± 1.19	7.45 ± 2.16	8.71 ± 1.37	7.57 ± 1.72	10.33 ± 3.01	7.40 ± 3.04
M	6.51 ± 2.60	6.95 ± 1.44	8.19 ± 2.13	10.58 ± 2.41	10.52 ± 3.70	8.42 ± 3.14
F	6.59 ± 1.74	7.71 ± 2.27	8.91 ± 1.58	7.47 ± 1.85	10.26 ± 2.98	7.37 ± 2.88
MF right	6.76 ± 2.25	7.31 ± 1.96	8.87 ± 2.10	9.15 ± 2.77	10.58 ± 3.46	8.03 ± 2.94
MF left	6.33 ± 2.08	7.35 ± 1.98	8.23 ± 1.66	8.90 ± 2.51	10.21 ± 3.16	7.76 ± 3.09
Total	6.55 ± 2.17	7.33 ± 1.97	8.55 ± 1.91	9.02 ± 2.65	10.39 ± 3.31	7.89 ± 3.00

Table 1. Adults. Mean ± SD of landmark displacement (mm) in males (M) and females (F), in the right and left sides. No significant difference was observed between males and females, and between the two sides.

	Brows lift	Frowning	Eye closure	Grimace	Smile	Lip purse
M right	7.08 ± 2.37	5.11 ± 2.36 *	7.51 ± 1.82	4.84 ± 1.98 *	7.42 ± 2.85	5.06 ± 1.70
F right	5.47 ± 1.85	3.71 ± 2.11 *	8.12 ± 2.30	6.21 ± 2.00 *	9.27 ± 4.93	6.48 ± 2.11
M left	6.70 ± 2.56	5.64 ± 2.55 *	7.23 ± 2.92	4.70 ± 1.79 *	7.82 ± 2.49	5.72 ± 3.99
F left	5.71 ± 1.51	3.75 ± 2.11 *	7.62 ± 2.77	6.67 ± 2.84 *	8.32 ± 5.04	6.56 ± 3.68
M	6.89 ± 3.90	5.37 ± 2.22 *	7.37 ± 2.30	4.27 ± 1.85 *	7.62 ± 2.53	5.39 ± 2.86
F	5.59 ± 1.60	3.73 ± 1.99 *	7.87 ± 2.41	7.45 ± 2.33 *	8.80 ± 4.73	6.52 ± 2.83
MF right	6.28 ± 2.11	4.41 ± 2.24	7.82 ± 2.06	5.26 ± 1.99	8.35 ± 3.89	5.77 ± 1.91
MF left	6.21 ± 2.03	4.70 ± 2.33	7.43 ± 2.85	5.69 ± 2.32	8.07 ± 3.77	6.14 ± 3.84
Total	6.24 ± 2.84	4.55 ± 2.17	7.62 ± 2.31	5.86 ± 2.63	8.21 ± 3.74	5.96 ± 2.82

Table 2. Children. Mean ± SD of landmark displacements (mm) in males (M) and females (F), in the right and left sides. Statistically significant differences ( $p < 0.05$ ) between males and females were observed during frowning and grimace, in both right and left sides (\*).

	Brows lift	Frowning *	Eye closure *	Grimace *	Smile *	Lip purse *
Adults	6.55 ± 2.17	7.33 ± 1.97	8.55 ± 1.91	9.02 ± 2.65	10.39 ± 3.31	7.89 ± 3.00
Children	6.24 ± 2.84	4.55 ± 2.17	7.62 ± 2.31	5.86 ± 2.63	8.21 ± 3.74	5.96 ± 2.82

Table 3. Comparison of movements in adults and children, right and left side (Student's t-test with  $P < 0.05$ ). Except for brows lift, all differences were significant (\*).

	x axis	y axis	z axis
Brows lift	Outward *	Upward *	Backward *
Frowning	Inward	Downward	Forward
Eyes closure	Inward	Downward	Forward
Grimace	Inward *	Upward	Forward *
Smile	Outward	Upward	Backward
Lip purse	Inward *	Downward	Forward

Table 4. Vector of landmark displacement during the investigated movements. \* indicates variable displacement among subjects.