

Computerized axiography in TMD patients before and after therapy with ‘function generating bites’

M. G. PIANCINO*, L. ROBERI*, G. FRONGIA*, M. REVERDITO*, R. SLAVICEK†
& P. BRACCO* *Chair Department of Orthodontics and Gnathology-Masticatory Function, University of Turin, Turin, Italy and
†Center for Interdisciplinary Dentistry, Danube University, Krems, Austria

SUMMARY The study evaluates the temporomandibular joint (TMJ) movements of patients with signs and symptoms of temporomandibular disorders (TMD) before and after therapy with the functional appliances of the ‘function generating bite’ (FGB) type. Thirty subjects suffering from TMD were selected and divided into two groups: group A (young patients: four males, nine females, mean age \pm standard deviation: 13.3 ± 1.5 years); group B (adults: three males, 14 females, mean age \pm standard deviation: 23.2 ± 4.4 years). A control group comprised 13 healthy subjects with perfect normal occlusion, TMD-free, was matched for age and sex with patient groups and was examined at T0 and after 12 months (T1). Computerized axiography was performed before and after therapy (average 13 months) with FGBs to evaluate any difference in condyle border movements. Results showed a statistically significant improvement after treat-

ment, for groups A and B, in length, clicks, tracings with normal morphology, superimposition, deviations, regularity and return to starting position and speed (statistical analysis: chi-squared test) except for the symmetry of tracings which was significantly improved only for the young patient group. No statistically significant differences at time T0/T1 were found in the control group. In conclusion, the study shows that the TMJ tracings of TMD patients before and after therapy with ‘FGB’ significantly improve especially in young patients. FGB may be a useful appliance to improve TMJ function in young and adult TMD patients requiring orthodontic treatment.

KEYWORDS: temporomandibular joint, temporomandibular disorders, axiography, functional appliance

Accepted for publication 31 August 2007

Introduction

Temporomandibular disorders (TMD) are joint and muscle disorders in the orofacial area characterized by pain, joint sounds and impaired jaw function; they are chronic conditions commonly encountered by dentists, who must therefore understand anatomical characteristics and functional status of the temporomandibular joint (TMJ) in patients with signs and/or symptoms of TMD (1–3).

The aetiological factors underlying TMD are still the subject of much controversy. Parafunctional oral habits, dental occlusion, postural problems, muscular

imbalance, unusual neuromuscular chewing patterns, TMJ disease and cranial cephalometric type are some of the factors frequently involved (4–6). The effects of neuromuscular components on occlusal contacts during function have been emphasized in this connection (7, 8). Occlusion may act as both a predisposing and perpetuating factor (9–12). Both functional and structural aspects of occlusion may be important as possible risk factors (13). However, these disorders may arise from an independent association of these and other variables (4, 14); occlusal interference is reportedly able to cause a shift in the position of the condyle in the fossa (15–17), and McNeill *et al.* (9, 10) suggest that

research should broaden its focus from local occlusal factors to the stomatognathic system as a whole (18–22).

It is clear that an interdisciplinary diagnosis is necessary and that therapy must involve the entire stomatognathic system (23). Several comparative studies have evaluated normal condylar movements to determine the diagnostic accuracy of instrumental analysis of the TMJ (24–28). Computerized axiography is a non-invasive diagnostic method through which the hinge axis can be determined, as well as the horizontal condylar inclination and the Bennett angle for articulator setting (29). In 1993, by evaluating interoperator variability of axiographic recording, Piehslinger *et al.* demonstrated the high reproducibility of the condylar reference position (30).

Sagittal recording devices have been shown to exhibit reproducible results between operators (31) and, as such, have been widely used to study the position and movements of the condyles (32). Moreover, through axiography early symptoms of disturbances in the stomatognathic system can be detected by comparing different recordings of the same patient, and the technique may aid further characterization of craniomandibular disorders (33–38).

Characteristic configurations of the condylar path may be correlated with specific conditions of TMJ dysfunction, i.e. reciprocal clicking, anterior disk displacement with reduction (ADD). These phenomena can be visualized with axiography. Gsellmann *et al.* found that patients with ADD with reduction showed significantly shorter range of TMJ movements in comparison with asymptomatic volunteers (39).

The aim of the present study was to evaluate the condylar pathways recorded by computerized axiography, of young and adult patients suffering from TMD, before and after therapy with 'function generating bite' (FGB). We tested the hypothesis that FGB is a reliable appliance to improve the TMJ function without any side effects on the joints.

Material and methods

Subjects

Thirty subject suffering from TMD were selected and divided into two groups: group A before the pubertal growth (13 young patients: four males, nine females,

mean age \pm standard deviation: 13.3 ± 1.5 years); group B after the pubertal growth (17 adult patients: three males, 14 females, mean age \pm standard deviation: 23.2 ± 4.4 years).

A control group of 13 healthy subjects (TMD-free group) was matched for age and sex with the patient groups. Patients were selected from 1 June 2002 to 1 December 2003 from among those referred to the Department of Orthodontics, University of Turin, Italy. Before entering the study, informed consent was obtained from all patients or their parents and control subjects.

Temporomandibular joint functional border movements were recorded by computerized axiography before and after therapy with FGB functional appliances.

Inclusion criteria for the patient's group were as follows:

- absence of any kind of fixed or removable prosthetic restoration;
- absence of periodontal disease;
- presence of all teeth (with the exception of third molars);
- diagnosis of TMD, according to the research diagnostic criteria by Dworkin and LeResche (4). The subdiagnosi for the young patients was 'group IIa' disk displacement with reduction. Adult patients (12%) had pain of muscular origin and the subdiagnosi was 'group Ia' myofascial pain. Adult patients (88%) had clicks with a subdiagnosi 80% 'group IIa' disk displacement with reduction, and 20% 'group IIc' disk displacement without reduction and without limited opening.

Inclusion criteria for the control group were as follows:

- perfect dental occlusion according to angle classification;
- absence of any kind of fixed or removable prosthetic restoration;
- presence of all teeth (with the exception of third molars);
- absence of periodontal disease;
- absence of clinical TMD signs and symptoms.

Any orthodontic or gnathologic device was used by the subjects of the control group during this study.

All patients (both young and adult groups) underwent the following protocol:

- clinical, orthodontic and gnathological examination (European Academy of Craniomandibular Disorders Form) (40);

- radiographic evaluation (panoramic, telerradiography in lateral and postero-anterior projections);
- laterolateral and postero-anterior cephalometry;
- stone casts;
- intra- and extra-oral photos;
- therapy with FGB to treat both the malocclusion and the TMD signs and symptoms;
- complete electrical axiography before therapy (T0) and after therapy (T1).

Appliances

Functional appliances help in the movement of the teeth, with the achievement of good facial muscle function (41); they are useful in TMD patients requiring orthodontic treatment (42, 43). Both TMD groups were treated with one of two types of functional appliance, the FGB for deep bite correction (FGB-D) and the FGB for open bite correction (FGB-O). The choice of appliance depended upon the malocclusion, FGB-D being characterized by anterior and posterior bite planes and the FGB-O by posterior bite planes only. All patients were informed about the importance to wear the appliance always, during the day and the night, except during the meals and sports activity.

The appliances were individually manufactured of acrylic resin and resilient stainless steel, with posterior and anterior metallic bite planes preventing the teeth from intercusp contact (Fig. 1). The principal components for both types of FGB are: (i) buccal arch; (ii) buccal shield; (iii) palatal resin plate; and (iv) metallic bite planes.

These devices are characterized by posterior metallic bite planes that, like gnathological bites, disengage the mandible from occlusion and protect the stomatognathic system from nociceptive inputs (42) (Figs 2 and 3). The effectiveness of FGB appliances is described in the literature: after 1 year of therapy with FGB-D, the TMD patients with deep bite showed the recovery of the asymmetry of the right and left masseters (41–43).

The mean duration of therapy \pm standard deviation was 13.1 ± 8.9 months; patients underwent a second axiographic evaluation after therapy (T1), and the control group after a comparable interval of time. Recordings were made by the same skilled examiner at the same time of day, i.e. during the morning. The variability of the duration of therapy with a functional appliance is normal because it depends on the

characteristics of the subjects, i.e. muscle activity, type of malocclusion, availability to wear the appliance during the day and compliance.

Instruments

Border condylar movements were measured with the Cadiax® Diagnostic axiograph and Gamma Dental Software* (Fig. 4). The Cadiax® Diagnostic axiograph is connected with a Condylgraph face bow and interfaces with a computer for data storage and subsequent analysis.

The axiographic parameter considered and evaluated were:

- length of protrusive, mediotrusive and opening tracings, on the sagittal plane, for both condyles;
- presence of a click as a deviation of the tracing of 3 mm or more, on the sagittal plane, during protrusive, mediotrusive and opening movements, for both condyles;
- morphology of the protrusive, mediotrusive and opening tracings, on the sagittal plane, for both condyles (right and left);
- lack of superimposition (lack of repeatability of the considered movements) of the protrusive and mediotrusive tracings for both condyles;
- presence of deviation of the protrusive and mediotrusive tracings of 1 mm or more, on the frontal and horizontal planes, for both condyles;
- absence of return to the starting point, of the protrusive, mediotrusive and opening tracings, on the sagittal plane, for both condyles;
- presence of irregular velocity of protrusive, mediotrusive and opening tracings, for both condyles;
- asymmetric length of the left and right tracings (>3 mm), on the sagittal plane, of the protrusive, mediotrusive and opening movements.

Reference values used were suggested by Slavicek (29) and Piehslinger *et al.* (31, 33).

Statistical analysis

The statistical analysis was performed by the chi-squared test to evaluate differences before (T0) and after therapy (T1) of the horizontal, sagittal and frontal plane, of each condyle, during protrusive, left and right mediotrusive and opening movements.

*Gamma Dental, Klosterneuburg, Austria.




Fig. 1. Function generating bite open (*) and function generating bite deep. (#) (a) posterior bite plane, (b) palatal resin plate, (c) expansion spring, (d) anterior bite plane.

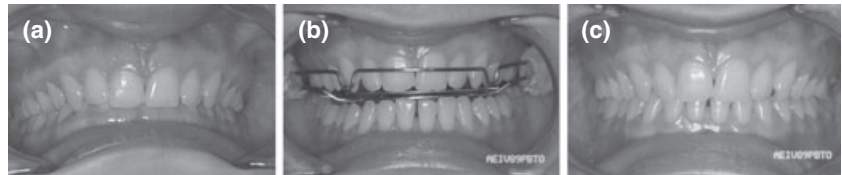


Fig. 2. (a) TMD deep bite patient before therapy; (b) TMD deep bite patient during therapy with FGB deep; (c) TMD deep bite patient after therapy.

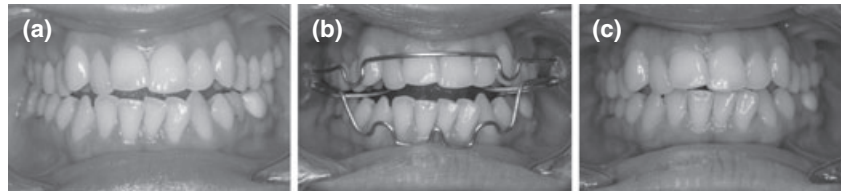


Fig. 3. (a) TMD open bite patient before therapy; (b) TMD open bite patient during therapy with FGB Open; (c) TMD open bite patient after therapy.




Fig. 4. (a) Axiographic tracing of mandibular protrusion before therapy; (b) condylocomp during recording a patient; (c) axiographic tracing of mandibular protrusion after therapy.

Results

The statistically significant results of the axiographic tracings, before (T0) and after (T1) therapy of the young TMD patients (group A) were:

- length of the tracings:
- protrusion → tracings with normal length [according to Slavicek (29) and Piehslinger *et al.* (31, 33)] increased from 46% to 77% (Table 1) ($P = 0.023$);
- mediotrusion → increased from 58% to 81% (Table 1) ($P = 0.071$);
- tracings with clicks decreased from 44% to 0% ($P = 0.000$) (Table 2);
 - from the clinical evaluation, before therapy 13 children of 13 showed a click, after therapy none of the children had a click;
- tracings with normal morphology on the sagittal plane increased from 44% to 71% ($P = 0.001$) (Table 2);

- tracings without superimposition (lack of repeatability of the considered movements) decreased from 65% to 2% ($P = 0.000$) (Table 2);
- tracings with deviations (>1 mm) decreased from 31% to 0% ($P = 0.000$) (Table 2);
- tracings without return to the starting point decreased from 54% to 1% ($P = 0.000$) (Table 2);
- tracings without uniform speed decreased from 49% to 0% ($P = 0.000$) (Table 2);
- tracings with asymmetry (>3 mm) between left and right joint decreased from 33% to 5% ($P = 0.002$) (Table 2).

The statistically significant results of the axiographic tracings before (T0) and after (T1) therapy of the adult TMD patients (group B) were:

- length of tracings:
 - opening → increased from 27% to 53% (Table 1) ($P = 0.048$);

Table 1. Comparison between the % of axiographic tracings with normal length before (T0) and after (T1) therapy of young (group A) and adult (group B) TMD patients, and the control group (group C)

	T0	T1	P
Tracings with normal length (group A) (%):			
Protrusion	46	77	0.023
Mediotrusion	58	81	0.071
Opening	42	62	0.165
Tracings with normal length (group B) (%):			
Protrusion	65	77	0.287
Mediotrusion	50	68	0.451
Opening	27	53	0.048
Tracings with normal length (group C) (%):			
Protrusion	69	81	0.337
Mediotrusion	65	54	0.396
Opening	69	65	0.767

The statistical analysis was performed by chi-squared test.

- tracings with clicks decreased from 37% to 17% ($P = 0.001$) (Table 2);

- from the clinical evaluation, before therapy 15 adult patients of 17 showed a click, after therapy nine of them still had a click.

- tracings with normal morphology on the sagittal plane increased from 49% to 65% ($P = 0.004$) (Table 2);

- tracings without superimposition decreased from 69% to 29% ($P = 0.000$) (Table 2);

- tracings with deviations (>1 mm) decreased from 41% to 24% ($P = 0.028$) (Table 2);

- tracings without return to the starting point decreased from 53% to 16% ($P = 0.000$) (Table 2);

- tracings without uniform speed decreased from 54% to 24% ($P = 0.000$) (Table 2);

No statistically significant differences time T0/T1 were found in the control group.

Discussion

This study evaluated TMJ border movements through computerized axiography (Cadiax[®] Diagnostic plus Gamma Dental Software; Gamma Dental) in patients with signs and symptoms of TMD before and after therapy with FGB functional appliances. Previous studies have focused on diagnosis of TMJ disease using axiography, but none has evaluated TMJ function before and after therapy (25, 27, 28). The results show a significant difference, before and after

Table 2. Comparison between axiographic parameters (number of tracings) before (T0) and after (T1) therapy of young (group A) and adult (group B) TMD patients, and the control group (group C)

	T0	T1	P
Tracings with click: protrusive, mediotrusive and opening left and right joint			
Group A	34/78	0/78	0.000
Group B	38/102	17/102	0.001
Group C	1/78	1/78	1
Tracings with normal morphology: protrusive, mediotrusive and opening left and right joint			
Group A	34/78	55/78	0.001
Group B	50/102	70/102	0.004
Group C	71/78	69/78	0.598
Tracings with absence of superimposition: protrusive and mediotrusive left and right joint			
Group A	34/52	1/52	0.000
Group B	48/68	21/68	0.000
Group C	32/52	29/52	0.550
Tracings with deviations (>1 mm): protrusive and mediotrusive left and right joint			
Group A	16/52	0/52	0.000
Group B	28/68	16/68	0.028
Group C	1/51	1/51	1
Tracings without return to the starting point: protrusive, mediotrusive and opening left and right joint			
Group A	42/78	1/78	0.000
Group B	54/102	16/102	0.000
Group C	13/78	13/78	1
Tracings without homogeneous speed: protrusive, mediotrusive and opening left and right joint			
Group A	38/78	0/78	0.000
Group B	55/102	24/102	0.000
Group C	2/78	2/78	1
Tracings with asymmetry (>3 mm): protrusive, mediotrusive and opening left and right joint			
Group A	13/39	2/39	0.002
Group B	6/51	2/51	0.141
Group C	3/39	7/39	0.176

The statistical analysis was performed by the chi-squared test.

therapy for morphology, superimposition, deviations, clicks, return to the starting point and uniform speed of the tracings, for both the young and adult patients except for the asymmetries of the tracings which significantly improved in young patients only.

The normal TMJ movements depend primarily on the disk freely sliding down the slope of the eminence and aberrations in the lubrication system contribute to TMJ dysfunction. According to Nitzan *et al.*, hyaluronic acid plays an important indirect role in the steady state

of the boundary lubrication process of joints by protecting the surface-active phospholipids from being lysed by phospholipase A (2). When the rate of degradation exceeds that of synthesis, there will be insufficient replacement of hyaluronic acid and/or surface-active phospholipids, resulting in denudation of the articular surfaces. These are then exposed to increasing friction, and hence increased danger of degenerative joint changes (44, 45).

The lack of superimposition, the altered morphology, the clicks, the deviations the incapability to return to the starting point, the unhomogeneous speed of the tracings are different aspects of the alteration of the lubrication system.

The action of the 'FGB' appliances on the TMJ may be due to the metallic bite planes, which disengage the mandible from occlusion, enabling the condyle to regain its physiological position decompressing the joint by applying traction on the ligaments, thus decreasing the load, re-establishing the function of the lubrication system and normalizing the trophism of the meniscus.

Because the patient group was subdivided into two groups, young people (before the pubertal growth) and adults (after the pubertal growth), the results showed that the young people obtained a complete recovering of clicks, a great improving of the tracing morphology, of speed and asymmetries, becoming their tracings normal, while the adult patients obtained a statistical significance of the same parameters even though the clicks did not completely disappear and the asymmetry of the tracings did not recover at all. We know from the literature that asymmetry is an important predisposing and perpetuating factor for TMD (4).

The correction of the asymmetry in young patients may be due to the fact that the condyle undergoes an adaptive type of growth (46) with acceleration around puberty. The therapy produces better results if it is applied during the period of maximum adaptation capability and growth of the condyle. Thus, the earlier the therapy, the better is the functional rehabilitation. It must also be stressed that in our series, after therapy no parameter had worsened, and indeed it may be said that this type of appliance has no side effects.

In conclusion, the study shows that the TMJ tracings of TMD patients before and after therapy with FGB significantly improve especially in young patients. FGB may be a useful appliance to improve TMJ function in

young and adult TMD patients requiring orthodontic treatment. Further investigations are necessary to deeply understand the phenomena.

References

1. Gelb H. Effective management and treatment of the craniomandibular syndrome. In: Gelb H, ed. *Clinical management of head, neck and TMJ pain and dysfunction*. 2nd ed. Philadelphia (PA): WB Saunders Co; 1985:277–367.
2. Mehta N. Muscular disorders. In: Kaplan AS, Assael LA, eds. *Temporomandibular disorders: diagnosis and treatment*. 2nd ed. Philadelphia (PA): W.B.Saunders Co; 1991:118–141.
3. McNeill C. *Temporomandibular disorders: guidelines for classification, assessment and management*. Chicago (IL): Quintessence; 1993.
4. Dworkin SF, LeResche L. Research diagnostic criteria for temporomandibular disorders: review, criteria, examination and specifications, critique. *J Craniomandib Disord*. 1992;6:302–355.
5. Okeson J. Criteria for optimum functional occlusion. In: Okeson J, ed. *Management of temporomandibular disorders and occlusion*. 4th ed. St Louis (MO): Mosby; 1998:109–126.
6. Belser UC, Hamman AG. The influence of altered working-side occlusal guidance on masticatory muscles and related jaw movements. *J Prosthet Dent*. 1985;53:406–413.
7. Metha NR. Understanding the influence of occlusal modifiers as they affect occlusal diagnosis. *KMC Dent J*. 1995;6: 69–78.
8. Dawson P. Occlusal therapy. In: Dawson P, ed. *Evaluation, diagnosis, and treatment of occlusal problems*. 2nd ed. St Louis (MO): CV Mosby; 1989:14–17.
9. McNeill C, Danzig WM, Farrar WB, Gelb H, Lerman MD, Moffet BC. Position paper of the American academy of craniomandibular disorders. *Craniomandibular (TMJ) disorders-the state of the art*. *J Prosthet Dent*. 1980;44:434–437.
10. McNeill C. *Craniomandibular (TMJ) disorders-the state of the art*. Part II: accepted diagnosis and treatment modalities. *J Prosthet Dent*. 1983;49:393–397.
11. MacDonald JW, Hannam AG. Relationship between occlusal contacts and jaw closing muscle activity during tooth clenching; part I. *J Prosthet Dent*. 1984;52:718–728.
12. Seligman DA, Pullinger AG. The role of functional occlusal relationships in temporomandibular disorders: a review. *J Craniomandib Disord*. 1991;5:265–279.
13. Egermark-Eriksson I, Ingervall B, Carlsson GE. The dependence of mandibular dysfunction in children on functional and morphologic malocclusion. *Am J Orthod*. 1983;83:187–194.
14. Pullinger AG, Seligman DA, Solberg WK. Temporomandibular disorders. Part II. Occlusal factors associated with temporomandibular joint tenderness and dysfunction. *J Prosthet Dent*. 1988;59:363–367.
15. Christensen LV, Rassouli NM. Experimental occlusal interferences. Part IV. Mandibular rotations induced by a pliable interference. *J Oral Rehabil*. 1995;22:835–844.

16. Christensen LV, Rassouli NM. Experimental occlusal interferences. Part V. Mandibular rotations versus hemimandibular translations. *J Oral Rehabil.* 1995;22:865–876.
17. Zhang ZK, Ma Xc, Gao S, Gu ZY, Fu KY. Studies on contributing factors in temporomandibular disorders. *Chin J Dent Res.* 1999;2:7–20.
18. Dawson PE. Optimum TMJ condyle position in clinical practice. *Int J Periodont Restor Dent.* 1985;5:10–31.
19. Pertes RA. Occlusal appliance therapy. In: Pertes RA, Gross SG eds. *Temporomandibular disorders and orofacial pain.* Chicago (IL): Quintessence Publishing Co; 1995:197–209.
20. Keller DC. Orthotics and orthodontics. *J Gen Orthod.* 1996;7:6–15.
21. Gelb H, Mehta NR, Forgione AG. The relationship between jaw posture and muscular strength in sport dentistry: a reappraisal. *J Craniomandib Pract.* 1996;14:320–325.
22. Dylina TJ. A common-sense approach to split therapy. *J Prosthet Dent.* 2001;86:539–545.
23. Baragar FA, Osborn JW. A model relating patterns of human jaw movement to biomechanical constraints. *J Biomech.* 1984;10:757–767.
24. McNeill C, Swenson KA, Miller A, Mohn C, Morrish RB Jr, Kenworthy CR. Bilateral condylar movement patterns in adult subjects. *J Orofac Pain.* 1997;11:328–336.
25. Romanelli GC, Harper R, Mock D, Pharoah MJ, Tenenbaum HC. Evaluation of temporomandibular joint internal derangement. *J Orofac Pain.* 1993;7:254–262.
26. Slavicek R. Clinical and instrumental functional analysis for diagnosis and treatment planning. Part 5. Axiography. *J Clin Orthod.* 1998;22:656–666.
27. Van Willigen J. The sagittal condylar movements of the clicking temporomandibular joint. *J Oral Rehabil.* 1979;6:167–175.
28. Theusner J, Plesh O, Curtis DA, Hutton JE. Axiographic tracings of temporomandibular joint movements. *J Prosthet Dent.* 1993;69:209–215.
29. Slavicek R. Clinical and instrumental functional analysis and treatment planning. Part 4. Instrumental analysis of mandibular casts using the mandibular position indicator. *J Clin Orthod.* 1988;2:566–575.
30. Piehslinger E, Celar AG, Celar RM, Jager W, Slavicek R. Reproducibility of the condylar reference position. *J Orofac Pain.* 1993;7:68–75.
31. Piehslinger E, Celar AG, Celar RM, Slavicek R. Computerized axiography: principles and methods. *J Craniomand Pract.* 1991;9:344–355.
32. Mauderli AP, Lundeen HC. Simplified condylar movement recorders for analysing TMJ derangements. *J Craniomand Pract.* 1986;4:208–212.
33. Piehslinger E, Ertl L. Computerized axiography for standardized evaluation of TMJ function and dysfunction. *Medinfo.* 1995;8:1303–1304.
34. Rammelsberg P, Pospiech P, May HC, Gernet W. Evaluation of diagnostic criteria from computerized axiography to detect internal derangements of the TMJ. *Cranio.* 1996;14:286–295.
35. Bernhardt O, Schwahn B, Meyer G. Craniomandibular disorders-comparative investigations with clinical examination and electronic axiography. *Anat Anz.* 1999;181:51–53.
36. Parlett K, Paesani D, Tallents RH, Hatala MA. Temporomandibular joint axiography and MRI findings: a comparative study. *J Prosthet Dent.* 1993;70:521–531.
37. Kohno S. A study on condylar movements with reference to the mandibular movement in sagittal plane. Part 2. Analysis of sagittal axis with the multiple electronic flush apparatus. *J Jpn Prosthodont Soc.* 1968;12:350–380.
38. Tanne K, Ozawa S. Diagnostic accuracy of sagittal condylar movement patterns for identifying internal derangement of the temporomandibular joint. *J Orofac Pain.* 1997;12:222–231.
39. Gsellmann M, Schmid-Schwab M, Piehslinger E, Slavicek R. Lengths of condylar pathways measured with computerized axiography (Cadiax) and occlusal index in patients and volunteers. *J Oral Rehabil.* 1998;25:146–152.
40. Seligman DA. Occlusal risk factors in craniomandibular disorders: recommendations for diagnostic examination and treatment. *European academy of craniomandibular disorders.* Hamburg: Quintessence; 1994.
41. Bracco P, Solinas GF. Orthognathic correction of uni- and bilateral crossbite with a functional appliance. *Mondo Ortod.* 1979;4:8–24.
42. Piancino MG, Talpone F, Dalmaso P, Debernardi C, Lewin A, Bracco P. Reverse-sequencing chewing patterns before and after treatment of children with a unilateral posterior crossbite. *Eur J Orthod.* 2006;28:480–484.
43. Castrolforio T, Talpone F, Deregibus A, Piancino MG, Bracco P. Effects of a functional appliance on masticatory muscles of young adults suffering from muscle-related temporomandibular disorders. *J Oral Rehabil.* 2005;32:411–417.
44. Nitzan DW. Friction and adhesive force-possible underlying causes for temporomandibular joint internal derangement. *Cells Tissues Organs.* 2003;174:6–16.
45. Nitzan DW, Nitzan U, Dan P, Yedgar S. The role of hyaluronic acid in protecting surface-active phospholipids from lysis by endogenous phospholipase A(2). *Rheumatology (Oxford).* 2001;40:336–340.
46. Thilander B. Basic mechanisms in craniofacial growth. *Acta Odontol Scand.* 1995;53:144–151.

Correspondence: Prof. Pietro Bracco, Chair Department of Orthodontics and Gnathology-Masticatory Function, University of Turin, C. Dogliotti 38, 10126 Torino, Italy.
E-mail: pietro.bracco@unito.it