

Review

The role of Doppler ultrasound in rheumatic diseases

Francesco Porta¹, Goran Radunovic², Violeta Vlad³, Mihaela C. Micu⁴,
Rodina Nestorova⁵, Tzvetanka Petranova⁶ and Annamaria Iagnocco⁷

Abstract

The use of Doppler techniques, including power, colour and spectral Doppler, has greatly increased in rheumatology in recent years. This is due to the ability of Doppler US (DUS) to detect pathological vascularization within joints and periarticular soft tissues, thereby demonstrating the presence of active inflammation, which has been reported to be correlated with the local neo-angiogenesis. In synovitis, DUS showed a high correlation with histological and MRI findings, thus it is considered a valid tool to detect pathological synovial vascularization. Moreover, it is more sensitive than clinical examination in detecting active joint inflammation and in the evaluation of response to treatment. In addition, DUS may be considered as a reference imaging modality in the assessment of enthesitis, MRI being not sensitive and histology not feasible. Moreover, it has been demonstrated to be able to detect changes in asymptomatic enthesitis. In conclusion, DUS is a useful and sensitive tool in the evaluation and monitoring of active inflammation. Its widespread use in clinical rheumatological practice is recommended. The aim of this article is to review the current literature about the role of DUS in rheumatic diseases, analysing its validity, reliability and feasibility.

Key words: Doppler, synovitis, arthritis, enthesitis.

Introduction

The growing role of US in rheumatology

In the last decade, the employment of US in rheumatic diseases has greatly increased, with improvement and widespread diffusion of US machines and an increasing number of rheumatologists who are able to perform musculoskeletal US. Considering the capacity of US to image several anatomical structures and its higher sensitivity in the detection of joint and periarticular soft tissue abnormalities compared with physical examination, US has now been integrated in daily clinical practice and its fields of application are increasing [1]. Doppler modalities are currently considered an integral part of the global

sonographic assessment of the rheumatic patient. This is mainly due to their capability to detect pathological flow within musculoskeletal soft tissues, thereby demonstrating the presence of local active inflammation [2].

Doppler modalities: colour Doppler, power Doppler and spectral Doppler

Three modalities of Doppler US (DUS) are currently used in the assessment of rheumatic diseases (Table 1). Colour Doppler (CD) US is obtained by the mean Doppler shift of the moving red cells, so it shows the direction and the speed of flow, without giving any information about the number of moving cells. No flow is detected if a vessel is perpendicular to the US beam [3, 4]. Power Doppler (PD) US, instead, evaluates the total number of Doppler shifts of the moving cell, regardless of direction and speed, thereby detecting flow also in case of perpendicularity of the flow to the US beam, and hence is a very sensitive tool for detecting slow flows [3, 4]. Spectral Doppler (SD) US provides an analysis of the flow in a selected vascularized site (i.e. a single vessel), giving information about its speed and direction and analysing them in a time-integrated image that allows the differentiation of the single components of the flow (systole and diastole). As the musculoskeletal structures are characterized by high-resistance flows, the resistance index (RI), which is

¹Department of Internal Medicine, Section of Rheumatology, University of Florence, Florence, Italy, ²Institute of Rheumatology, Medical School, University of Belgrade, Belgrade, Serbia, ³Sf. Maria Clinical Hospital, Bucharest, ⁴Division of Rheumatology, Department of Rehabilitation II, Rehabilitation Clinical Hospital Cluj- Napoca, Romania, ⁵Clinic of Rheumatology, Medical University, ⁶Centre of Rheumatology "St. Irina", Sofia, Bulgaria and ⁷Dipartimento Medicina Interna e Specialità Mediche: Reumatologia, Sapienza Università di Roma, Rome, Italy.

Submitted 26 July 2011; revised version accepted 22 November 2011.

Correspondence to: Annamaria Iagnocco, Dipartimento Medicina Interna e Specialità Mediche: Reumatologia, Sapienza Università di Roma, V. le del Policlinico 155, Rome 00161, Italy.
E-mail: annamaria.iagnocco@uniroma1.it

TABLE 1 Characteristics of Doppler modalities used in rheumatology

CD	<p>Combines Doppler effect and real-time imaging</p> <p>Assesses the mean velocity of blood flow overlapping colour and B-mode images</p> <p>A colour signal is displayed—different colour according to the direction of flow (red: the flow directs towards the probe; blue: away from it)</p>
PD	<p>Displays the power of Doppler signal in a large range of Doppler shifts</p> <p>Small flow is detected (but NOT its direction and velocity)</p> <p>The capability to highlight flow depends on the quality of the US equipment</p> <p>Is a mainstay in assessing inflammation in joints and periarticular tissues in rheumatic diseases</p>
SD	<p>Provides an analysis of the flow in a selected vascularized site</p> <p>The RI decreases in case of synovial inflammation</p>

the ratio between the systolic peak minus the end diastolic flow and the systolic peak, has a value of 1 in normal conditions; a decrease in the RI is registered in case of inflammation or neo-angiogenesis [5].

The role of DUS in the assessment of synovitis

Doppler vs MRI and histopathology

In the whole of the literature, there are few works comparing synovial DUS with histopathological findings and the majority of them concerns large joints, before prosthetic substitution. The first study comparing DUS with histology was done to perform a differential diagnosis on IA echoic structures in 10 patients with RA and 10 with OA before prosthetic replacement. In nine patients, histology showed a vascularized pannus and DUS demonstrated synovial vascularization. No significant differences were demonstrated between the use of PD and CD, thereby suggesting a similar role of PD and CD in improving the differentiation of IA structures [6].

In 2001, Walther *et al.* [8] compared PD and synovial histopathology of the knee joint in 23 patients (10 affected by RA, 13 by OA) who were undergoing total knee arthroplasty. They evaluated both grey-scale and PD synovitis, quantifying them on a 4-point scale, according to the Newman score [7], and adding an automatic quantification of red pixels as sign of vascularization. Both the qualitative and the quantitative estimation of vascularization correlated with the histopathological findings, leading to the conclusion that PD is a valid tool for the detection and quantification of synovial vascularization [8]. One year later, a similar work was done on the hip using the same protocol (24 patients, 15 with OA and 9 with RA); the results showed a good correlation between histological findings and PD in the detection of synovial vascularity [9].

The difference in equipment capacity to determine very slow flows and the correlation of PD with histopathology was tested in 44 synovial sites (25 knees, 7 wrists, 3 tibio-talar joints, 2 MTP joints, 1 glenohumeral, 1 MCP, 1 elbow, 2 subdeltoid bursae and 2 tendon sheaths). A difference in the lowest detectable flow was found testing the machines on phantoms. In 83% of patients who showed histological signs of active synovial inflammation, a positivity of PD was detected without any correlation between the amount of PD signal and the overall histopathological score, but with a good correlation between the amount of sub-synovial infiltration of PMNs and the amount of surface fibrin. The authors concluded that a negative PD flow cannot exclude an active synovitis, whereas a positive one is a good indicator of it, regardless of its degree [10].

When contrast-enhanced MRI (CE-MRI) has been used for assessing the validity of PD, a good correlation between the two techniques has been shown. Indeed, in a study performed in 54 MCP joints of RA patients, a positive PD signal was demonstrated in 17 joints and CE-MRI showed increased flow in 18 joints; in this study, the sensitivity of PD was 88.8% and the specificity was 97.9% [11].

Terslev *et al.* [12] evaluated the qualitative and quantitative CD signal, the RI and the CE-MRI data in a larger number of joints (29 wrist and 167 finger joints). There was a significant correlation between MRI post-contrast synovial thickness, Doppler colour fraction and RI. Vascularized synovial membrane was found also in some asymptomatic joints, thus demonstrating a high sensitivity of CD [12]. In 2007, a comparison between PD, MRI and radiography (X-ray) was done in the hands and feet of 15 PsA patients, 5 RA patients and 5 controls; the data showed a good correlation between PD and MRI in depicting bone changes and synovitis both in RA and PsA [13].

Few papers have evaluated the validity and reliability of PDUS to detect synovitis in the shoulder of patients with RA. In the first one, comparing PDUS before and after administration of echo-enhancing contrast agent with CE-MRI in 24 RA patients' shoulders, less encouraging results were found [14]. Indeed, US detected synovial effusion/hypertrophy in 42% of the patients showing synovitis with CE-MRI, whereas a positive PD signal was not found in any of them, leading the authors to the conclusion that PD is not a valid tool to assess the synovial activity in this joint [14].

However, these findings are not in agreement with those obtained later by two studies that compared grey-scale US and PD with MRI in a small number of RA patients, evaluating also the inter-observer reliability, and found that PDUS was reliable and is a valid tool for the assessment of shoulder synovitis in RA [15, 16]. These apparent contradictory results can be explained by the different US definitions of synovitis, the different cut-off values for pathological findings and the different MRI protocols, including the variable use of contrast.

Doppler vs clinical assessment and its role in the assessment of disease progression and response to therapy

Doppler vs clinical assessment

In 2007, a comparison of PD and traditional clinical assessment of joints in RA patients did not show significant correlations between clinically detected (tenderness, swelling or none of these) and PD-detected synovitis. Indeed, synovitis was also found in some asymptomatic patients, raising the question about the role of the traditional clinical assessment of joints in RA [17].

Despite clinical remission, radiological damage progression can be found in RA patients; this led to the evaluation of 107 RA patients, asymptomatic for joint pain and in remission according to DAS-28 and ACR criteria, with MRI and PD. Synovitis was found in the majority of these patients, both with MRI and PD, giving a possible explanation for the radiological progression and confirming the importance of sonography in the management of RA [18].

Later on, a longitudinal study evaluated 102 patients in clinical remission with PD and MRI at baseline and after 12 months, finding a significant correlation between the baseline synovitis and the further occurrence of radiological damage; a relevant finding seemed to be the detection of a PD signal, which was associated with a very increased risk of developing bone erosions (odds ratio 12.21) [19].

The role of Doppler in therapy monitoring

In 2003, a pilot study was conducted to depict the role of PD in the follow-up of RA patients treated with infliximab; a small number of patients were enrolled, and the sonographic analysis was performed at the level of small joints. A good correlation between the clinical response to therapy and the decrease in synovial thickness and the PD signal was found, demonstrating that PD is a feasible and sensitive tool to measure the response to therapy in RA [20].

The role of PD in monitoring the response to therapy was confirmed the same year in 13 RA patients treated with i.v. methylprednisolone [21]. In 2004, Taylor *et al.* [22] compared the results obtained in RA patients treated with MTX + infliximab vs MTX + placebo, evaluating them with PD at Weeks 0, 2, 6 and every 8 weeks until Week 46. A difference in the response rate in the two groups and a correlation between the baseline PD US condition and the radiological progression at Week 54 were found [22].

Similar results were obtained 2 years later with the same drug, confirming the importance of PD in monitoring therapy response [23]. After this, DUS was applied on knee synovitis both in RA and in PsA to evaluate the response to etanercept; a decrease in synovial vascularization was detected in the responder patients, and this correlated with the improvement of clinical assessment and biochemical markers, without any significant difference between PsA and RA [24].

In 2006, treatment with adalimumab was monitored for 2 weeks with PD that demonstrated a rapid decrease in synovial pathological flow after treatment [25]. In 2008, the

same authors confirmed the results in a follow-up period of 2 years [26]. In the same year, sensitivity to change in PDUS in 28 joints of RA patients on anti-TNF therapy was demonstrated in a larger cohort, showing a correlation with the improvement in DAS-28 and a predictive value for radiological progression [27].

The ability in detecting short-time modifications was also evaluated in 20 patients with PD-proven active synovitis treated with IA steroid injections; 2 weeks after a steroid injection a decrease in pathological vascularity and synovial thickening were found [28].

For the follow-up of RA patients, both the extensive PDUS evaluation of 44 joints and the reduced evaluation of 12 joints have shown to be sensitive to change and to correlate with the composite indexes of disease activity; however, the reduced count results have been found to be more feasible [29].

Later on, a 78-joint PDUS count also demonstrated a correlation with the modifications of the clinical and biochemical parameters during therapy with adalimumab in a follow-up of 12 months [30]. In 2010, a prospective study showed not only the usefulness of PD in monitoring infliximab therapy, but also demonstrated the possibility of detecting a decrease in Doppler signal as early as Week 2 and established Week 38 as the best time to perform follow-up in order to predict the successive response to therapy [31].

Predictive value of Doppler

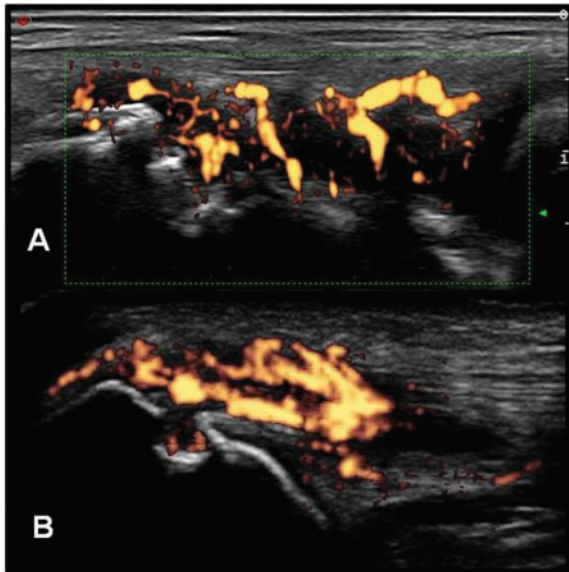
Ozgoçmen *et al.* [32] compared the sonographic assessment of inflammation in MCP joints of RA patients (evaluated with grey scale, PD and SD) with the articular BMD. The results demonstrated a significant correlation between PD and erosive scores and an inverse correlation between RI and BMD and erosive scores; these results therefore seem suggestive of a possible role of flow measurement techniques in RA follow-up. The role of PD signal at baseline as a predictive index for erosion [33] and for short-term relapse [34] was then confirmed by other research studies, not only in RA but also in JIA [35].

In 2007, 42 patients with early RA underwent PDUS assessment of 28 joints at baseline, 3 months, 6 months and 1 year and radiographic assessment at baseline and 1 year. The US joint count for active synovitis and an overall joint index for power Doppler signal correlated with radiographic progression, leading to the conclusion that PDUS findings may have a predictive value in disease activity and radiographic outcome [36].

The association of PD vascularization in a single MCP or PIP joint, where inflammation was then confirmed by MRI, with radiological progression has been evaluated in 19 RA patients (190 MCP joints and 190 PIP joints). The presence of pathological vascularization (Fig. 1A) in a single joint at baseline was associated with the radiographic onset of erosions after 20 weeks of therapy, whereas a decrease of vascularity was not associated with X-ray disease progression after 8 weeks of treatment [37].

These data were in agreement with another study about a 2-year follow-up of RA patients, showing that the degree of synovial hyperaemia at baseline and the number of

Fig. 1 Positive PD signal indicating active inflammation. (A) Synovitis of the radiocarpal joint in an RA patient. (B) Enthesitis of the tricipital tendon in a PsA patient.



ACR criteria were the only predictive factors for the development of erosions [38]. More recently, a study applying MRI, PDUS, CT scan and radiography on 52 RA patients on therapy with adalimumab and MTX demonstrated the lack of clear evidence that subclinical synovitis is responsible for radiological progression; however, PDUS-detected synovitis as well as bone oedema at baseline have been found to be risk factors for erosions [39].

The role of DUS in enthesitis

Doppler vs clinical assessment and its role in the assessment of disease progression and response to therapy

In 2003, D'Agostino *et al.* [40] evaluated 164 SpA patients and 64 controls (34 with mechanical low back pain and 30 with RA), with particular attention towards lower limb entheses vascularization at the cortical bone insertion, junction between the tendon and entheses, body of the tendon and bursa. The majority of SpA patients showed at least one US-detected abnormality at enthesal level on grey scale or PD, compared with only a few patients with RA or mechanical low back pain. A high number of SpA patients showed abnormal entheses vascularization, and the most remarkable point was the site of PD positivity: the cortical bone insertion showed flow in almost all the patients, whereas none of the RA patients and mechanical low back pain patient had flow in that area (Fig. 1B). The vascularization also correlated with the clinical presentation, with a more sustained vascularization in the mixed form than in the axial one [40].

Later on, a comparison between PD evaluation of 390 entheses (30 AS patients) and the Modified American Shoulder and Elbow Surgeons (MASES) score [41] obtained by palpation and algometric pain threshold was done, together with the collection of biohumoral parameters. The sonographic evaluation was carried out, registering both grey-scale and PD abnormalities by a semiquantitative (0–3) grading system. A cumulative PD score was then calculated for each patient by summing the scores of any single entheses. A positive correlation was found between the cumulative PD score and MASES score, whereas no correlation was found between these data and age, disease duration, morning stiffness and anthropometric measures. Highly vascularized entheses on PD were found to be a possible cause of pain [42].

Recently, an attempt to standardize enthesitis by DUS and improve inter- and intra-observer reliability has been done by applying a multi-step process, which produced an improvement in the reliability over the time [43] and has been recently demonstrated to be a useful tool in monitoring therapy. After a short report about the use of PD to monitor the effects of infliximab on enthesitis in two patients [44], in 2010 a larger series of 43 patients was evaluated, with the results demonstrating a decrease in vascularization detected by PD in the treated patients at the enthesal level [45].

The same year, a study on a larger cohort of 327 SpA patients with enthesitis confirmed that PDUS is sensitive to change in assessing the response to anti-TNF- α therapy [46].

Comparison of different Doppler modalities

No study comparing PD and CD in rheumatic disease has been performed so far. However, based on the apparent increased sensitivity of PD in detecting slow flows over CD, currently a wider application of it has been registered and a greater number of studies on its uses are available. However, it seems that the recent technical improvements of US equipment have led to increased performances of CD and to its widespread use [47]. Conversely, studies comparing PD and CD with SD, in particular with the RI and the pulsatility index, have been performed over the last decade.

In 2001, an analysis on 18 inflamed joints in RA evaluated the results obtained by clinical assessment, CD and SD; a significant correlation between CD fraction and ESR and between the RI with ESR and HAQ was found. Interestingly, whereas an increase in vascularization at CD was detected after injection of contrast medium, no differences were seen with SD, indicating that contrast enhancement is not necessary with this technique [48].

The response to treatment has been evaluated with different Doppler modalities. In 2003, 11 RA patients treated with etanercept were assessed before and after the treatment both with PD and with SD (RI): after the treatment, a decrease in the PD score and an increase in the RI were

detected, showing that both methods can be useful in the follow-up of RA patients [49]. Similar results were obtained by the use of CD and SD after IA steroid injections [50].

That same year, results from qualitative/quantitative CD assessment were correlated with MRI evaluation in 196 joints of RA patients. DUS was able to depict inflammation in 52 joints, with significant differences between both CD and RI and the degree of swelling, but with a correlation of RI only with the degree of tenderness. The analysis of CE-MRI showed the signs of local inflammation in 79 joints, as well as a global 75% of agreement with DUS; in addition, a significant correlation between post-contrast synovial thickness and both CD and RI was found [12].

Conclusions

In recent years, DUS has gained increasing applications and a relevant role in the assessment of inflammatory arthritis, being now used also in the evaluation of disease activity. Currently there are three DUS modalities that seem to be appropriate for rheumatological applications: PD, CD and SD. However, none of them has clearly been demonstrated to be superior to the others.

PD, which is the most used DUS technique, has some theoretical advantages over CD, mostly represented by its supposed higher sensitivity in the detection of slow flows, such as those present at the level of inflamed tissues. In addition, it is able to show pathological vascularization independently of the angle of insonation between the US beam and the vessels, thus being more appropriate for the analysis of neo-angiogenesis. However, due to recent technological advances in new US equipment, it seems that CD and PD have similar levels of sensitivity in the detection of synovitis.

The use of spectral Doppler, in particular the evaluation of RI, allows a quantification of the degree of vasodilation of single vessels. At the joint level, the value of the RI is usually 1 in healthy individuals; in case of inflammation this parameter drops to <0.8 and can be applied to analyse local pathology. Recently the predictive value of DUS in the detection of active synovitis and consequent erosive progression has been assessed [31, 37, 38], demonstrating the relevant role of Doppler modalities in disease follow-up. The use of DUS in disease monitoring is therefore fundamental, sonography being more sensitive than clinical assessment in the demonstration of active synovitis [17, 18] and able to predict the onset of erosion [19].

Rheumatology key messages

- DUS is a valid and reliable tool for the assessment of synovitis and enthesitis.
- No significant difference in sensitivity has been found between colour and PD.

Disclosure statement: The authors have declared no conflicts of interest.

References

- 1 Kane D, Balint PV, Sturrock R, Grassi W. Musculoskeletal ultrasound—a state of the art review in rheumatology. Part 1: current controversies and issues in the development of musculoskeletal ultrasound in rheumatology. *Rheumatology* 2004;43:823–8.
- 2 Cyteval C. Doppler ultrasonography and dynamic magnetic resonance imaging for assessment of synovitis in the hand and wrist of patients with rheumatoid arthritis. *Semin Musculoskelet Radiol* 2009;13:66–73.
- 3 Burns PN. Principles of Doppler and color flow. *Radiol Med* 1993;85(5 Suppl. 1):3–16.
- 4 Newman JS, Adler RS, Bude RO, Rubin JM. Detection of soft-tissue hyperemia: value of power Doppler sonography. *AJR Am J Roentgenol* 1994;163:385–9.
- 5 Rubin JM. Spectral Doppler US. *Radiographics* 1994;14:139–50.
- 6 Schmidt WA, Völker L, Zacher J *et al.* Colour Doppler ultrasonography to detect pannus in knee joint synovitis. *Clin Exp Rheumatol* 2000;18:439–44.
- 7 Newman JS, Laing TJ, McCarthy CJ, Adler RS. Power Doppler sonography of synovitis: assessment of therapeutic response—preliminary observations. *Radiology* 1996;198:582–4.
- 8 Walther M, Harms H, Krenn V *et al.* Correlation of power Doppler sonography with vascularity of the synovial tissue of the knee joint in patients with osteoarthritis and rheumatoid arthritis. *Arthritis Rheum* 2001;44:331–8.
- 9 Walther M, Harms H, Krenn V *et al.* Synovial tissue of the hip at power Doppler US: correlation between vascularity and power Doppler US signal. *Radiology* 2002;225:225–31.
- 10 Koski JM, Saarakkala S, Helle M *et al.* Power Doppler ultrasonography and synovitis: correlating ultrasound imaging with histopathological findings and evaluating the performance of ultrasound equipments. *Ann Rheum Dis* 2006;65:1590–5.
- 11 Szkudlarek M, Court-Payen M, Strandberg C *et al.* Power Doppler ultrasonography for assessment of synovitis in the metacarpophalangeal joints of patients with rheumatoid arthritis: a comparison with dynamic magnetic resonance imaging. *Arthritis Rheum* 2001;44:2018–23.
- 12 Terslev L, Torp-Pedersen S, Savnik A *et al.* Doppler ultrasound and magnetic resonance imaging of synovial inflammation of the hand in rheumatoid arthritis: a comparative study. *Arthritis Rheum* 2003;48:2434–41.
- 13 Wiell C, Szkudlarek M, Hasselquist M *et al.* Ultrasonography, magnetic resonance imaging, radiography, and clinical assessment of inflammatory and destructive changes in fingers and toes of patients with psoriatic arthritis. *Arthritis Res Ther* 2007;9:R119.
- 14 Wamser G, Bohndorf K, Vollert K *et al.* Power Doppler sonography with and without echo-enhancing contrast agent and contrast-enhanced MRI for the evaluation of rheumatoid arthritis of the shoulder joint: differentiation between synovitis and joint effusion. *Skeletal Radiol* 2003;32:351–9.
- 15 Bruyn GA, Naredo E, Moller I *et al.* Reliability of ultrasonography in detecting shoulder disease in

- patients with rheumatoid arthritis. *Ann Rheum Dis* 2009; 68:357–61.
- 16 Bruyn GA, Pineda C, Hernandez-Diaz C *et al.* Validity of ultrasonography and measures of adult shoulder function and reliability of ultrasonography in detecting shoulder synovitis in patients with rheumatoid arthritis using magnetic resonance imaging as a gold standard. *Arthritis Care Res* 2010;62:1079–86.
 - 17 Rees JD, Pilcher J, Heron C, Kiely PD. A comparison of clinical vs ultrasound determined synovitis in rheumatoid arthritis utilizing gray-scale, power Doppler and the intravenous microbubble contrast agent 'Sono-Vue'. *Rheumatology* 2007;46:454–9.
 - 18 Brown AK, Quinn MA, Karim Z *et al.* Presence of significant synovitis in rheumatoid arthritis patients with disease-modifying antirheumatic drug-induced clinical remission: evidence from an imaging study may explain structural progression. *Arthritis Rheum* 2006;54:3761–73.
 - 19 Brown AK, Conaghan PG, Karim Z *et al.* An explanation for the apparent dissociation between clinical remission and continued structural deterioration in rheumatoid arthritis. *Arthritis Rheum* 2008;58:2958–67.
 - 20 Ribbens C, Andre B, Marcelis S *et al.* Rheumatoid hand joint synovitis: gray-scale and power Doppler US quantifications following anti-tumor necrosis factor-alpha treatment: pilot study. *Radiology* 2003;229:562–9.
 - 21 Teh J, Stevens K, Williamson L *et al.* Power Doppler ultrasound of rheumatoid synovitis: quantification of therapeutic response. *Br J Radiol* 2003;76:875–9.
 - 22 Taylor PC, Steuer A, Gruber J *et al.* Comparison of ultrasonographic assessment of synovitis and joint vascularity with radiographic evaluation in a randomized, placebo-controlled study of infliximab therapy in early rheumatoid arthritis. *Arthritis Rheum* 2004;50:1107–16.
 - 23 Iagnocco A, Perella C, Ceccarelli F *et al.* Ultrasonographic assessment of the response to etanercept treatment in patients with rheumatoid arthritis. *Reumatismo* 2006;58:233–8.
 - 24 Fiocco U, Ferro F, Vezzu M *et al.* Rheumatoid and psoriatic knee synovitis: clinical, grey scale, and power Doppler ultrasound assessment of the response to etanercept. *Ann Rheum Dis* 2005;64:899–905.
 - 25 Filippucci E, Iagnocco A, Salaffi F *et al.* Power Doppler sonography monitoring of synovial perfusion at the wrist joints in patients with rheumatoid arthritis treated with adalimumab. *Ann Rheum Dis* 2006;65:1433–7.
 - 26 Iagnocco A, Filippucci E, Perella C *et al.* Clinical and ultrasonographic monitoring of response to adalimumab treatment in rheumatoid arthritis. *J Rheumatol* 2008;35:35–40.
 - 27 Naredo E, Moller I, Cruz A *et al.* Power Doppler ultrasonographic monitoring of response to anti-tumor necrosis factor therapy in patients with rheumatoid arthritis. *Arthritis Rheum* 2008;58:2248–56.
 - 28 Filippucci E, Farina A, Carotti M *et al.* Grey scale and power Doppler sonographic changes induced by intra-articular steroid injection treatment. *Ann Rheum Dis* 2004;63:740–3.
 - 29 Naredo E, Rodriguez M, Campos C *et al.* Validity, reproducibility, and responsiveness of a twelve-joint simplified power doppler ultrasonographic assessment of joint inflammation in rheumatoid arthritis. *Arthritis Rheum* 2008; 59:515–22.
 - 30 Hammer HB, Sveinsson M, Kongtorp AK, Kvien TK. A 78-joints ultrasonographic assessment is associated with clinical assessments and is highly responsive to improvement in a longitudinal study of patients with rheumatoid arthritis starting adalimumab treatment. *Ann Rheum Dis* 2010;69:1349–51.
 - 31 Kamishima T, Sagawa A, Tanimura K *et al.* Semi-quantitative analysis of rheumatoid finger joint synovitis using power Doppler ultrasonography: when to perform follow-up study after treatment consisting mainly of antitumor necrosis factor alpha agent. *Skeletal Radiol* 2010;39:457–65.
 - 32 Ozgocmen S, Kiris A, Kocakoc E *et al.* Evaluation of metacarpophalangeal joint synovitis in rheumatoid arthritis by power Doppler technique: relationship between synovial vascularization and periarticular bone mineral density. *Joint Bone Spine* 2004;71:384–8.
 - 33 Platzgummer H, Schueller G, Grisar J *et al.* Quantification of synovitis in rheumatoid arthritis: do we really need quantitative measurement of contrast-enhanced ultrasound? *Eur J Radiol* 2009;71:237–41.
 - 34 Scire CA, Montecucco C, Codullo V *et al.* Ultrasonographic evaluation of joint involvement in early rheumatoid arthritis in clinical remission: power Doppler signal predicts short-term relapse. *Rheumatology* 2009; 48:1092–7.
 - 35 Magni-Manzoni S, Epis O, Ravelli A *et al.* Comparison of clinical versus ultrasound-determined synovitis in juvenile idiopathic arthritis. *Arthritis Rheum* 2009;61:1497–504.
 - 36 Naredo E, Collado P, Cruz A *et al.* Longitudinal power Doppler ultrasonographic assessment of joint inflammatory activity in early rheumatoid arthritis: predictive value in disease activity and radiologic progression. *Arthritis Rheum* 2007;57:116–24.
 - 37 Fukae J, Kon Y, Henmi M *et al.* Change of synovial vascularity in a single finger joint assessed by power Doppler sonography correlated with radiographic change in rheumatoid arthritis: comparative study of a novel quantitative score with a semiquantitative score. *Arthritis Care Res (Hoboken)* 2010;62:657–63.
 - 38 Pascual-Ramos V, Contreras-Yanez I, Cabiedes-Contreras J *et al.* Hypervascular synovitis and American College of Rheumatology Classification Criteria as predictors of radiographic damage in early rheumatoid arthritis. *Ultrasound Q* 2009;25:31–8.
 - 39 Dohn UM, Ejlberg B, Boonen A *et al.* No overall progression and occasional repair of erosions despite persistent inflammation in adalimumab-treated rheumatoid arthritis patients: results from a longitudinal comparative MRI, ultrasonography, CT and radiography study. *Ann Rheum Dis* 2011;70:252–8.
 - 40 D'Agostino MA, Said-Nahal R, Hacquard-Bouder C *et al.* Assessment of peripheral enthesitis in the spondylarthropathies by ultrasonography combined with power Doppler: a cross-sectional study. *Arthritis Rheum* 2003;48:523–33.
 - 41 Heuft-Dorenbosch L, Spoorenberg A, van Tubergen A *et al.* Assessment of enthesitis in ankylosing spondylitis. *Ann Rheum Dis* 2003;62:127–32.

- 42 Kiris A, Kaya A, Ozgocmen S, Kocakoc E. Assessment of enthesitis in ankylosing spondylitis by power Doppler ultrasonography. *Skeletal Radiol* 2006;35:522-8.
- 43 D'Agostino MA, Aegerter P, Jousse-Joulin S *et al.* How to evaluate and improve the reliability of power Doppler ultrasonography for assessing enthesitis in spondylarthritis. *Arthritis Rheum* 2009;61:61-9.
- 44 D'Agostino MA, Breban M, Said-Nahal R, Dougados M. Refractory inflammatory heel pain in spondylarthropathy: a significant response to infliximab documented by ultrasound. *Arthritis Rheum* 2002;46:840-1, author reply 1-3.
- 45 Aydin SZ, Karadag O, Filippucci E *et al.* Monitoring Achilles enthesitis in ankylosing spondylitis during TNF-alpha antagonist therapy: an ultrasound study. *Rheumatology* 2010;49:578-82.
- 46 Naredo E, Batlle-Gualda E, Garcia-Vivar ML *et al.* Power Doppler ultrasonography assessment of entheses in spondyloarthropathies: response to therapy of enthesal abnormalities. *J Rheumatol* 2010;37:2110-7.
- 47 Torp-Pedersen ST, Terslev L. Settings and artefacts relevant in colour/power Doppler ultrasound in rheumatology. *Ann Rheum Dis* 2008;67:143-9.
- 48 Qvistgaard E, Rogind H, Torp-Pedersen S *et al.* Quantitative ultrasonography in rheumatoid arthritis: evaluation of inflammation by Doppler technique. *Ann Rheum Dis* 2001;60:690-3.
- 49 Terslev L, Torp-Pedersen S, Qvistgaard E *et al.* Effects of treatment with etanercept (Enbrel, TNRF:Fc) on rheumatoid arthritis evaluated by Doppler ultrasonography. *Ann Rheum Dis* 2003;62:178-81.
- 50 Terslev L, Torp-Pedersen S, Qvistgaard E *et al.* Estimation of inflammation by Doppler ultrasound: quantitative changes after intra-articular treatment in rheumatoid arthritis. *Ann Rheum Dis* 2003;62:1049-53.