

Ultrasound imaging for the rheumatologist XVIII. Ultrasound measurements

G. Meenagh¹, E. Filippucci², A. Delle Sedie³, L. Riente³, A. Iagnocco⁴, O. Epis⁵,
C.A. Scirè⁵, C. Montecucco⁵, S. Bombardieri³, G. Valesini⁴, W. Grassi²

¹Antrim Hospital, Antrim, United Kingdom;

²Cattedra di Reumatologia, Università Politecnica delle Marche, Jesi, Italy;

³Unità Operativa di Reumatologia, Università di Pisa, Pisa, Italy;

⁴Cattedra di Reumatologia, Sapienza - Università di Roma, Roma, Italy;

⁵Cattedra di Reumatologia, IRCCS Policlinico S. Matteo, Università di Pavia, Pavia, Italy.

Please address correspondence to:

Prof. Walter Grassi,

Cattedra di Reumatologia,

Università Politecnica delle Marche,

Ospedale "A. Murri", Via dei Colli 52,

60035 Jesi (AN), Italy.

E-mail: walter.grassi@univpm.it

Received and accepted on December 10,

2008.

Clin Exp Rheumatol 2008; 26: 982-985.

© Copyright CLINICAL AND

EXPERIMENTAL RHEUMATOLOGY 2008.

Key words: Ultrasonography, synovitis, power Doppler, rheumatoid arthritis, osteoarthritis.

ABSTRACT

One of the largest challenges to the field of musculoskeletal ultrasonography is attempting to accurately quantify the changes seen in chronic arthritis. With advances in ultrasound technology, researchers have been increasingly exploring ways of more accurately assessing these changes and attempting to reach consensus with agreed scoring systems. This review presents the main scoring systems developed for quantifying sonographic findings indicative of synovitis and joint damage in patients with rheumatoid arthritis. Further investigation is required to attain international consensus on such scoring systems and to evaluate their impact on therapeutic decision-making.

Introduction

One of the largest challenges to the field of musculoskeletal ultrasonography (US) is attempting to accurately quantify the changes seen in inflammatory diseases such as rheumatoid arthritis (RA). The hallmark changes seen in inflammatory arthritis with US include synovitis and bone erosion (1). With advances in US technology, researchers have been increasingly exploring ways of more accurately assessing these changes and attempting to reach consensus with agreed scoring systems. In more recent times there has also been a move towards quantifying US findings characteristically seen in other musculoskeletal disorders *e.g.*, osteoarthritis (OA).

Quantification of joint synovitis

It is well recognised in the literature that the metacarpo-phalangeal (MCP) and proximal inter-phalangeal (PIP) joints are amongst the most common targets for synovitis in early RA (2, 3). Using plain radiography standardised

scoring systems for MCP and PIP joint damage exist and are in regular usage but there is no reliable index of soft tissue involvement (4-6).

A semi-quantitative scoring system, known as the RAMRIS, has already been agreed to by the Outcome Measures in Rheumatology Clinical Trials (OMERACT) group for synovitis in RA using magnetic resonance imaging (MRI) (7). This evaluates 3 compartments of the wrist and all MCP joints and excludes PIP joints.

Increasingly US is being used to identify early changes in inflammatory arthritis and would appear to be as sensitive as MRI for detecting synovitis and joint erosion (8-11) given that US is more accessible than MRI and more practical a modality for patient follow-up. However, US sensitivity is strongly related to the width of the acoustic windows.

Several methods for quantifying joint synovitis in RA have been described, most of them employing a semi-quantitative scale from 0 to 3. Szkudlarek's methods evaluated only 5 different joints (second and third MCP, second PIP and first and second metatarsophalangeal (MTP) joints) and made no allowance for the common co-existence of synovitis and effusion (12).

One of the most commonly used methods for evaluation of joint synovitis in RA is the one described by Scheel as follows:

- The second-fifth MCP and PIP joint was examined using high frequency linear US probe.
- Two views were evaluated in each joint: longitudinal and transverse.
- The degree of synovial hypertrophy and joint effusion were scored
0 = no effusion/ hypertrophy,
1 = minimal effusion/ hypertrophy,
2 = moderate effusion/ hypertrophy,
3 = extensive effusion/ hypertrophy.

Competing interests: none declared.

Quantification of power Doppler signal

Power Doppler (PD) has been investigated in several studies and has a positive correlation with synovial blood flow and therefore linked intimately with disease activity in inflammatory arthritis (14-16). It also appears to correlate well with contrast enhanced MRI (17, 18).

There are essentially two different methods available for quantifying PD: visual and computerised. Within the clinical setting the visual semi-quantitative score is the most useful and readily available one. Different semi-quantitative scoring systems have been proposed which involve the visual estimation of either pixilation (19) or number of visible vessels (20).

The method described by Szkudlarek

et al. is perhaps the most universally recognised scoring system and is performed as follows:

- The joint to be examined is scanned to obtain the standardised views in both the longitudinal and transverse planes.
- Accidental vessel compression must be ensured and either a thick gel layer (gel-bath) or a small jelly stand-off pad applied to the overlying skin
- PD settings were standardized for each patient and optimized for detection of synovial blood flow by adjusting colour gain, pulse repetition and flow optimization parameters
- The colour gain threshold was set at the level just above which no signal was seen within bone
- The degree of PD signal was graded thus:

- 0 = no flow in the synovium,
- 1 = single vessel signals,
- 2 = confluent vessel signal in less than half of the area of the synovium,
- 3 = vessel signal in more than half of the area of the synovium

Computerised methods involve capturing the US colour image, importing it into a dedicated photo-package and using the software to differentiate and count the number of colour pixels against the greyscale background (21, 22). The software method requires standardisation of magnification and field of view. The serial use of this computerised method of PD quantification is therefore fraught with methodological peril and for that reason there has been limited diffusion of this outwardly impressive development.

Three dimensional (3D) US has recently been introduced into the technological repertoire of rheumatologist sonographers and investigators have begun to explore its capabilities with PD (23, 24). 3D US generates volumetric images containing the entire PD signal within the acoustic window representing the summation of a virtually infinite number of conventional two-dimensional images. The peculiar automatic process of acquisition in 3D US significantly reduces the margin for error and it is likely to be increasingly used as an imaging tool for the monitoring of synovial perfusion in inflammatory arthritis (25).

Quantification of bone erosion

A sinister development for any patient with inflammatory arthritis, especially RA, is the appearance of bone erosion (26). It is well recognised that US can clearly identify bony erosion within the small joints (MCP, PIP and MTP joints) in patients with early RA and at a stage where conventional radiography is unable to (27). In RA the commonest joints affected are the second, third and fifth MCP and the fifth MTP joints. This may partly be explained by the physical restrictions to the substantial investigation of certain joints with US.

The OMERACT group has defined bone erosion as an intra-articular discontinuity of the bone surface that is visible in two perpendicular planes.

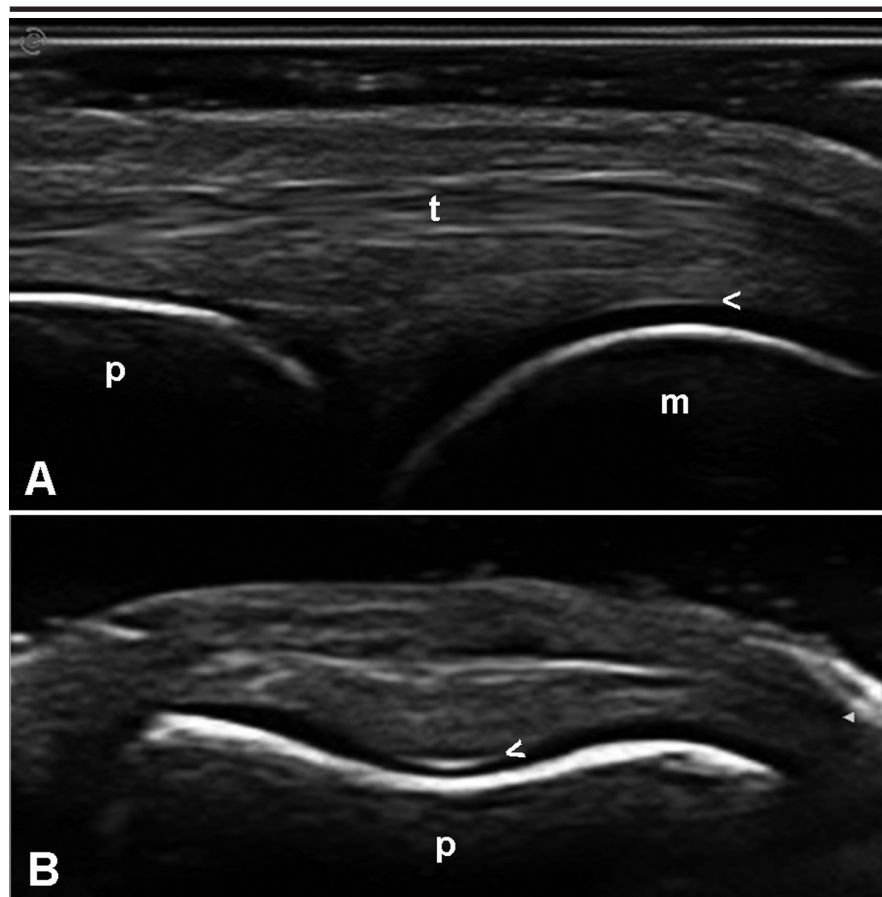


Fig. 1. Healthy subject. High-resolution grey-scale ultrasound using a 18 MHz linear probe showing anatomic details less than 1 mm in size. **A.** Longitudinal dorsal view of the metacarpophalangeal joint in maximal flexion visualizing a subtle anechoic layer of 0.4 mm covering the metacarpal head. **B.** Transverse dorsal view of the head of the proximal phalanx. The hyaline cartilage is 0.12 mm thick. The **arrowheads** indicate the chondro-synovial interface appearing as a thin hyperechoic line at the areas of the cartilage surface perpendicular to the ultrasound beam direction. **m** = metacarpal head; **p** = proximal phalanx; **t** = finger extensor tendon.

For further ultrasound images, go to www.clinexprheumatol.org/ultrasound

Wakefield *et al.* suggested a simple quantitative scoring system for estimating the dimensions of bone erosions seen in RA using the widest measured break in cortical continuity in millimetres:

- Small erosion = <2mm
- Moderate erosion = 2-4mm
- Large erosion = >4mm

With the advent of new generation very high frequency linear transducers erosions can now be seen at dimensions <1mm. Furthermore, detailed exploration of articular cartilage is also now possible permitting early and subtle changes within its echotexture to be clearly defined thereby heralding the arrival of 'acoustic microscopy' (Fig. 1).

Quantification of response to treatment: short term monitoring

In the last few years the medical literature has become more populated with studies specifically addressing the area of US in short-term therapy monitoring of inflammatory arthritis (28-36). Treatment with direct intra-articular infiltration with corticosteroid and systemic therapy with anti-tumour necrosis factor (TNF) agents have been investigated using US as an index of response.

Ribbens *et al.* investigated 11 patients with active RA commencing treatment with anti-TNF therapy (infliximab) and monitored changes in synovial thickness and PD in MCP, PIP and wrist joints at 6 weeks (31). The most significant improvement was seen with reduction in synovial thickness using grey-scale measurement ($p < 0.1$). A longer term US follow up of RA patients treated with an alternative anti-TNF agent, etanercept, was performed by Terslev *et al.* and showed that whilst a reduction in PD activity could be seen at 2 weeks there was no sustained reduction seen at one year (32). Again PD signal was used by Filippucci *et al.* to assess response to adalimumab therapy in the wrist joints of 24 RA patients (34). Using the standard 4-point semi-quantitative scale for PD signal significant reductions in activity were seen over a 12-week period which appeared to correlate with clinical improvement. There would therefore appear to be a quantifiable change in synovial vascularity which occurs rapidly after

institution of potent immunomodulators in RA and this appears to correlate with clinical improvement. The challenge to investigators currently is defining the role of US and PD in the more medium term follow-up of patients with inflammatory arthritis and the influence upon subsequent management decisions based on US findings.

Ultrasound measurements in osteoarthritis

The US study of OA has always interested rheumatologist sonographers and studies dating back over the last decade demonstrate (37-42). Many of the characteristic features of OA seen on plain radiography are easily identified with US including joint space narrowing and, osteophytosis (42). Researchers have postulated for many years on the potential inflammatory component in the pathogenesis of OA and recently investigators have been able to depict this using PD US and quantify it.

A pan-European multi-centre study investigated 600 patients with knee OA and defined knee synovitis as synovial thickness ≥ 4 mm and joint effusion as effusion ≥ 4 mm within the supra-patellar recess. By these parameters 2.7% had synovitis alone, 14.2% had both synovitis and effusion, 29.5% had joint effusion alone and 53.7% no inflammation detected (43).

Further interest has centred on using US in hand OA. An expert group of rheumatologists, under the auspices of the Disease Characteristics in Hand OA Group (DICHOA), has initiated the primordial stages in the development of a US hand scoring system via an iterative internet exercise (44). They decided that the most important features of hand OA to be included in this system were grey-scale synovitis, power Doppler and osteophytosis. US changes within articular cartilage and joint space narrowing were not felt to be reliable measures and have been excluded from further deliberation. The final report from this group will be much anticipated.

Conclusion

US is now a well established investigative tool within the rheumatologists' armamentarium and the pathological

features which it displays will continue to play an important role in influencing patient management. Establishing accurate measurement of these findings seems vital particularly when clinical comparators are necessary at follow-up. The growing number of scales and grading systems in musculoskeletal US will require further validation and their impact on therapeutic decision-making fully explored.

Links

For ultrasound images, go to:
www.clinexp Rheumatol.org/ultrasound

References

1. FILIPPUCCI E, IAGNOCCO A, MEENAGH G *et al.*: Ultrasound imaging for the rheumatologist VII. Ultrasound imaging in rheumatoid arthritis. *Clin Exp Rheumatol* 2007; 25: 5-10.
2. DROSSAERS-BAKKER KW, KROON HM, ZWINDERMAN AH, BREEDVELD FC, HAZES JM: Radiographic damage of large joints in long-term rheumatoid arthritis and its relation to function. *Rheumatology* 2000; 39: 998-1003.
3. BROWN AK, QUINN MA, KARIM Z *et al.*: Presence of significant synovitis in rheumatoid arthritis patients with disease-modifying antirheumatic drug-induced clinical remission: evidence from an imaging study may explain structural progression. *Arthritis Rheum* 2006; 54: 3761-73.
4. VAN DER HEIJDE D, DANKERT T, NIEMAN F, RAU R, BOERS M: Reliability and sensitivity to change of a simplification of the Sharp/van der Heijde radiological assessment in rheumatoid arthritis. *Rheumatology* 1999; 38: 941-7.
5. SHARP JT, YOUNG DY, BLUHM GB *et al.*: How many joints in the hands and wrists should be included in a score of radiologic abnormalities used to assess rheumatoid arthritis? *Arthritis Rheum* 1985; 28: 1326-35.
6. RAU R, WASSENBERG S, HERBORN G, STUCKI G, GEBLER A: A new method of scoring radiographic change in rheumatoid arthritis. *J Rheumatol* 1998; 25: 2094-107.
7. SCHEEL A, HERMANN K-G, KAHLER E, PASEWALDT D, FRITZ J, AMM B: A novel ultrasonographic synovitis scoring system suitable for analyzing finger joint inflammation in rheumatoid arthritis *Arthritis Rheum* 2005; 52: 733-43.
8. ALASAARELA E, SURAMO I, TERVONEN O, LAHDE S, TAKALO R, HAKALA M: Evaluation of humeral head erosions in rheumatoid arthritis: a comparison of ultrasonography, magnetic resonance imaging, computed tomography and plain radiography. *Rheumatology* 1998; 37: 1152-6.
9. SZKUDLAREK M, COURT-PAYEN M, STRANDBERG C, KLARLUND M, KLAUSEN T, ØSTERGAARD M: Power Doppler ultrasonography for assessment of synovitis in

- the metacarpophalangeal joints of patients with rheumatoid arthritis: a comparison with dynamic magnetic resonance imaging. *Arthritis Rheum* 2001; 44: 2018-23.
10. HERMANN KG, BACKHAUS M, SCHNEIDER U *et al.*: Rheumatoid arthritis of the shoulder joint: comparison of conventional radiography, ultrasound, and dynamic contrast-enhanced magnetic resonance imaging. *Arthritis Rheum* 2003; 48: 3338-49.
 11. TERSLEV L, TORP-PEDERSEN S, SAVNIK A *et al.*: Doppler ultrasound and magnetic resonance imaging of synovial inflammation of the hand in rheumatoid arthritis: a comparative study. *Arthritis Rheum* 2003; 48: 2434-41.
 12. SZKUDLAREK M, COURT-PAYEN M, JACOBSEN S, KLARLUND M, THOMSEN H, ØSTERGAARD M: Interobserver Agreement in Ultrasonography of the Finger and Toe Joints in Rheumatoid Arthritis. *Arthritis Rheum* 2003; 48: 955-62.
 13. SCHEEL A, BACKHAUS M: Ultrasonographic assessment of finger and toe joint inflammation in rheumatoid arthritis: comment on the article by Szkudlarek *et al.* *Arthritis Rheum* 2004; 50: 1008.
 14. NEWMAN J, ADLER R, BUDE R, RUBIN J: Detection of soft-tissue hyperemia: value of power Doppler sonography. *Am J Roentgenol* 1994; 163: 385-9.
 15. NEWMAN J, LAING T, MCCARTHY C, ADLER R: Power Doppler sonography of synovitis: assessment of therapeutic response – preliminary observations. *Radiology* 1996; 198: 582-4.
 16. WALTHER M, HARMS H, KRENN V, RADKE S, FAEHNDRICH TP, GOHLKE F: Correlation of power Doppler sonography with vascularity of the synovial tissue of the knee joint in patients with osteoarthritis and rheumatoid arthritis. *Arthritis Rheum* 2001; 44: 331-8.
 17. MCNALLY E: Ultrasound of the small joints of the hands and feet: current status. *Skeletal Radiol* 2008; 37: 99-113.
 18. IAGNOCCO A, EPIS O, DELLE SEDIE A *et al.*: Ultrasound imaging for the rheumatologist. XVII. Role of colour Doppler and power Doppler. *Clin Exp Rheumatol* 2008; 26: 759-62.
 19. SZKUDLAREK M, COURT-PAYEN M, STRANDBERG C, KLARLUND M, KLAUSEN T, ØSTERGAARD M: Contrast-enhanced power Doppler ultrasonography of the metacarpophalangeal joints in rheumatoid arthritis. *Eur Radiol* 2003; 13: 163-8.
 20. KLAUSER A, FRAUSCHER F, SCHIRMER M *et al.*: The value of contrast-enhanced color Doppler ultrasound in the detection of vascularisation of finger joints in patients with rheumatoid arthritis. *Arthritis Rheum* 2002; 46: 647-53.
 21. QVISTGAARD E, ROGIND H, TORP-PEDERSEN S, TERSLEV L, DANNESKIOLD-SAMSOE B, BLIDDAL H: Quantitative ultrasonography in rheumatoid arthritis: evaluation of inflammation by Doppler technique. *Ann Rheum Dis* 2001; 60: 690-3.
 22. TEH J, STEVENS K, WILLIAMSON L, LEUNG J, MCNALLY EG: Power Doppler ultrasound of rheumatoid synovitis: quantification of therapeutic response. *Br J Radiol* 2003; 76: 875-9.
 23. FILIPPUCCI E, MEENAGH G, EPIS O *et al.*: Ultrasound imaging for the rheumatologist. XIII. New trends. Three-dimensional ultrasonography. *Clin Exp Rheumatol* 2008; 26: 1-4. Abstract: Erratum in *Clin Exp Rheumatol* 2008; 26: 388.
 24. STRUNK J, STRUBE K, KLINGENBERGER P, MULLER-LADNER U, LANGE U: Two and three-dimensional Doppler sonographic evaluation of the effect of local cryotherapy on synovial perfusion in wrist arthritis. *Rheumatology* 2006; 45: 637-40.
 25. MEENAGH G, FILIPPUCCI E, ABBATTISTA T, BUSILACCHI P, GRASSI W: Three-dimensional power Doppler sonography in short-term therapy monitoring of rheumatoid synovitis. *Rheumatology* 2007; 46: 1736.
 26. FILIPPUCCI E, IAGNOCCO A, MEENAGH G *et al.*: Ultrasound imaging for the rheumatologist II. Ultrasonography of the hand and wrist. *Clin Exp Rheumatol* 2006; 24: 118-22.
 27. WAKEFIELD R, GIBBON W, CONAGHAN P *et al.*: The value of sonography in the detection of bone erosions in patients with rheumatoid arthritis: a comparison with conventional radiography. *Arthritis Rheum* 2000; 43: 2762-70.
 28. TEH J, STEVENS K, WILLIAMSON L, LEUNG J, MCNALLY EG: Power Doppler ultrasound of rheumatoid synovitis: quantification of therapeutic response. *Br J Radiol* 2003; 76: 875-9.
 29. FILIPPUCCI E, FARINA A, CAROTTI M, SALAFFI F, GRASSI W: Grey scale and power Doppler sonographic changes induced by intra-articular steroid injection treatment. *Ann Rheum Dis* 2004; 63: 740-3.
 30. NAREDO E, MÖLLER I, CRUZ A, CARMONA L, GARRIDO J: Power Doppler ultrasonographic monitoring of response to anti-tumor necrosis factor therapy in patients with rheumatoid arthritis. *Arthritis Rheum* 2008; 58: 2248-56.
 31. RIBBENS C, ANDRE B, MARCELIS S *et al.*: Rheumatoid hand joint synovitis: gray-scale and power Doppler US quantifications following anti-tumor necrosis factor- α treatment: pilot study. *Radiology* 2003; 229: 562-9.
 32. TERSLEV L, TORP-PEDERSEN S, QVISTGAARD E *et al.*: Effects of treatment with etanercept (Enbrel, TNRFc) on rheumatoid arthritis evaluated by Doppler ultrasonography. *Ann Rheum Dis* 2003; 62: 178-81.
 33. FIOCCO U, FERRO F, VEZZU M *et al.*: Rheumatoid and psoriatic knee synovitis: clinical, grey scale, and power Doppler ultrasound assessment of the response to etanercept. *Ann Rheum Dis* 2005; 64: 899-905.
 34. FILIPPUCCI E, IAGNOCCO A, SALAFFI F, CERIONI A, VALESINI G, GRASSI W: Power Doppler sonography monitoring of synovial perfusion at the wrist joints in patients with rheumatoid arthritis treated with adalimumab. *Ann Rheum Dis* 2006; 65: 1433-7.
 35. IAGNOCCO A, PERELLA C, NAREDO E *et al.*: Etanercept in the treatment of rheumatoid arthritis: clinical follow-up over one year by ultrasonography. *Clin Rheumatol* 2008; 27: 491-6.
 36. TAYLOR PC, STEUER A, GRUBER J *et al.*: Ultrasonographic and radiographic results from a two-year controlled trial of immediate or one-year-delayed addition of infliximab to ongoing methotrexate therapy in patients with erosive early rheumatoid arthritis. *Arthritis Rheum* 2006; 54: 47-53.
 37. GRASSI W, LAMANNA G, FARINAA, CERVINI C: Sonographic imaging of normal and osteoarthritic cartilage. *Semin Arthritis Rheum* 1999; 28: 398-403.
 38. IAGNOCCO A, COARI G: Usefulness of high resolution US in the evaluation of effusion in osteoarthritic first carpometacarpal joint. *Scand J Rheumatol* 2000; 29: 170-3.
 39. IAGNOCCO A, FILIPPUCCI E, OSSANDON A *et al.*: High resolution ultrasonography in detection of bone erosions in patients with hand osteoarthritis. *J Rheumatol* 2005; 32: 2381-3.
 40. KEEN H, WAKEFIELD R, GRAINGER A, HENSOR E, EMERY P, CONAGHAN P: An ultrasonographic study of osteoarthritis of the hand: Synovitis and its relationship to structural pathology and symptoms. *Arthritis Rheum* 2008; 59: 1756-63.
 41. PENDLETON A, MILLAR A, O'KANE D, WRIGHT GD, TAGGART AJ: Can sonography be used to predict the response to intra-articular corticosteroid injection in primary osteoarthritis of the knee? *Scand J Rheumatol* 2008; 37: 395-7.
 42. MEENAGH G, FILIPPUCCI E, IAGNOCCO A *et al.*: Ultrasound imaging for the rheumatologist VIII. Ultrasound imaging in osteoarthritis. *Clin Exp Rheumatol* 2007; 25: 172-5.
 43. D'AGOSTINO M, CONAGHAN P, LE BARS M *et al.*: EULAR report on the use of ultrasonography in painful knee osteoarthritis. Part I: prevalence of inflammation in osteoarthritis. *Ann Rheum Dis* 2005; 64: 1703-9.
 44. KEEN H, LAVIE F, WAKEFIELD R *et al.*: The development of a preliminary ultrasonographic scoring system for features of hand osteoarthritis. *Ann Rheum Dis* 2008; 67: 651-5.