

Ultrasound imaging for the rheumatologist

XXXI. Sonographic assessment of the foot in patients with rheumatoid arthritis

L. Riente¹, A. Delle Sedie¹, C.A. Scirè², E. Filippucci³, G. Meenagh⁴, A. Iagnocco⁵,
N. Possemato¹, G. Valesini⁵, W. Grassi³, C. Montecucco², S. Bombardieri¹

¹Unità Operativa di Reumatologia, Università di Pisa, Pisa, Italy;

²Cattedra di Reumatologia, IRCCS Policlinico San Matteo, Università di Pavia, Pavia, Italy;

³Clinica Reumatologica, Università Politecnica delle Marche, Ancona, Italy;

⁴Department of Rheumatology, Antrim Hospital, Antrim, United Kingdom;

⁵Cattedra di Reumatologia, Sapienza Università di Roma, Roma, Italy.

Lucrezia Riente, MD

Andrea Delle Sedie, MD

Carlo Alberto Scirè, MD

Emilio Filippucci, MD

Gary Meenagh, MD

Annamaria Iagnocco, MD

Nicola Possemato, MD

Guido Valesini, MD, Professor of Rheumatology

Walter Grassi, MD, Professor of Rheumatology

Carlo Maurizio Montecucco, MD, Professor of Rheumatology

Stefano Bombardieri, MD, Professor of Rheumatology

Please address correspondence to:

Lucrezia Riente, MD,

U.O. Reumatologia,

Dipartimento di Medicina Interna, Università di Pisa,

Via Roma 67, 56126 Pisa, Italy.

E-mail: lucrezia.riente@med.unipi.it

Received and accepted on January 16, 2011.

Clin Exp Rheumatol 2011; 29: 1-5.

© Copyright CLINICAL AND

EXPERIMENTAL RHEUMATOLOGY 2011.

Key words: rheumatoid arthritis, ultrasound, foot, synovitis, enthesopathy, erosion

Competing interests: none declared.

ABSTRACT

Objective. The aims of our study were to investigate the prevalence of ultrasound (US) abnormalities in the foot of patients with rheumatoid arthritis (RA) and to compare them with the clinical findings.

Methods. One hundred RA patients were enrolled in the study. Bilateral US examination of metatarsophalangeal (MTP) joints, proximal interphalangeal (PIP) joints, midfoot joints (talonavicular, calcaneo-cuboid, medial, intermediate and lateral navicular-cuneiform and cuneiform-metatarsal joints and cuboid-4th and 5th metatarsal joints) were examined for synovitis and erosion. In addition the plantar fascia and the insertion of the anterior and posterior tibialis and peroneous brevis tendons were imaged.

Results. Effusion with synovial proliferation was visualised only at MTP joints in 84 out of 200 (42%) feet, at MTP plus at least one joint of the midfoot in other 41 out of 200 (20%) feet (making a total of 125 out of 200 (62%) MTP joints) exclusively in one or more joints of the midfoot in 7 out of 200 (3%) feet, in the PIP joint of the 2nd and 3rd toes in 3 (1.5%) and 4 (2%) feet respectively, while no effusion with synovial proliferation was visualised in the PIP joint of the 4th and 5th toes. Synovitis was present most frequently in the 2nd MTP joint whilst erosions were most frequently imaged in the 5th MTP joint.

Conclusion. US examination appears to be a useful imaging technique to study joint and tendon involvement of the foot in RA patients. Moreover, US examination of the foot is more sensitive than clinical examination in the detection of joint inflammation and allows for

a better understanding of the features and the progression of the disease.

Introduction

The hallmark of rheumatoid arthritis (RA), a systemic autoimmune disorder characterised by inflammation and synovial proliferation, is the involvement of the small joints of the hands and feet resulting in painful swelling and joint deformity.

It is known that musculoskeletal ultrasound (US) plays a key role in the detection of joint and tendon abnormalities in rheumatic diseases (1-7). It has become an established method to evaluate joint effusion, synovitis, tendon pathology and erosive bone changes in RA and is being increasingly used in rheumatological practice (8, 9)

The metatarsophalangeal (MTP), metacarpophalangeal (MCP) and proximal interphalangeal (PIP) joints have been the subjects of several US studies in arthritis and standardised US scores based on such joints and wrist examination have been developed to evaluate disease activity and therapeutic response (10-13). Few studies have, however, used the US tool to focus on the articular and periarticular alterations in the tarsal joints in RA (14, 15).

The aims of our study were to investigate the prevalence of US pathologic abnormalities in the foot of RA patients and to compare them with the clinical findings.

Methods and patients

This multicentre study was conducted in 4 Italian Rheumatology Units (Rheumatology Unit of University of Pisa, Università Politecnica delle Marche, University of Pavia, the Sapienza University of Rome) and

in the Rheumatology Department of Antrim Hospital, Northern Ireland, UK. In each unit, gray-scale and power Doppler examinations were performed by a rheumatologist well experienced in musculoskeletal US who was blind to both clinical and laboratory patients data. US examinations were carried out using a Logiq 9 (General Electrics Medical Systems, Milwaukee, WI) with a linear probe operating at 14 MHz and a My Lab70 XVG (Esaote SpA, Genoa, Italy) equipped with a multifrequency linear probe (16 MHz). At baseline an agreement was obtained by the sonographers on both the scanning technique to adopt and the definition of the pathological findings sought.

Clinical assessment

Prior to US examination all the patients were clinically assessed, according to standard techniques (16), for the presence/absence of pain, tenderness (elicited by palpation and/or active or passive mobilisation) and swelling of MTP, PIP and midfoot joints by a rheumatologist not involved in US examination. In total, 200 feet of 100 patients were examined.

Patients

One hundred RA patients (28 males and 72 females, mean age: 56 ± 14.8 years, ranging from 21 to 80 years; mean disease duration: 65 ± 75 months, ranging from 6 to 372 months), attending the out-patient and the in-patients of the Rheumatology Units involved in the study, were enrolled. RA was diagnosed according to the American College of Rheumatology classification criteria (17). Patients with previous joint surgery or who had received corticosteroid injection of the foot within the previous 3 months were excluded.

US scanning technique

Using a multiplanar scanning technique, according to EULAR guidelines for musculoskeletal US in rheumatology, bilateral US examination of foot was performed as follows:

a) MTP joints of the 2nd, 3rd, 4th and 5th toes were examined for synovitis from the dorsal and plantar aspects. Erosions were detected from the dorsal

Table I. Pathological findings detected by US examination of the metatarsophalangeal joints in rheumatoid arthritis patients.

US findings	MTP2	MTP3	MTP4	MTP5
Joint effusion	70/200 (35%)	63/200 (31%)	36/200 (18%)	32/200 (16%)
Proliferative synovitis	53/200 (26%)	47/200 (23%)	25/200 (12%)	30/200 (15%)
Intra-articular power Doppler	23/200 (11%)	17/200 (8%)	9/200 (4.5%)	11/200 (5.5%)
Bone erosions	9/200 (4.5%)	10/200 (5%)	3/200 (1.5%)	101/200 (50.5%)

Metatarsophalangeal joint of the 2nd, 3rd, 4th and 5th toes = MTP2, MTP3, MTP4, MTP5

Table II. Relationship between US and clinical findings indicative of joint inflammation in all groups of feet examined.

US findings	Clinical findings		
	Presence	Absence	Total
Joint effusion (MTP, PIP, midfoot joints)	Presence	107	135
	Absence	30	65
	Total	137	200

Foot joint inflammation: effusion with synovial proliferation at least at one MTP and/or PIP, and/or midfoot joints.

Clinical findings: pain and/or swelling at least at one MTP and/or PIP, and/or midfoot joints.

and plantar aspects in the 2nd, 3rd and 4th MTP and from the dorsal, plantar, and lateral in the MTP joint of the 5th toe. The big toe was not included in the examination, as effusion and bone irregularity are frequently encountered in the asymptomatic population (10).

b) PIP joints of the 2nd, 3rd, 4th and 5th toes were examined for synovitis and erosions from the dorsal aspect.

c) the talonavicular (TN), the calcaneocuboid joints (CC), the medial, intermediate and lateral navicular-cuneiform (NC) and cuneiform-metatarsal joints (CM) and the cuboid-4th and 5th metatarsal joints (CMT4 and CMT5 respectively) were also evaluated for synovitis and erosions. For the purposes of this study we termed the complex of such joints as "joints of the midfoot".

d) the plantar fascia was imaged and thickening and/or power Doppler signal, or the presence of enthesophytes and rupture were recorded where appropriate.

e) the insertion of anterior tibialis tendon at the 1st metatarsal bone, the posterior tibialis tendon at navicular bone

and of peroneus brevis tendon at the 5th metatarsal bone were examined for thickening and/or power Doppler signal and for the presence of enthesophytes and rupture.

The study was conducted according to the Declaration of Helsinki and local regulations and informed consent was obtained from all patients.

US image interpretation

Joint effusion, synovial hypertrophy, bone erosion, enthesopathy and tendinopathy were diagnosed by US according to the preliminary definitions provided by the Outcome Measures in Rheumatoid Arthritis Clinical Trials (OMERACT) Special Interest Group for Musculoskeletal Ultrasound in Rheumatology (18). A semi-quantitative grading method (0–3) for scoring joint effusion, synovial proliferation and intra-articular power Doppler (PD) signal was used (19).

Results

Effusion with synovial proliferation was visualised only at MTP joints in 84

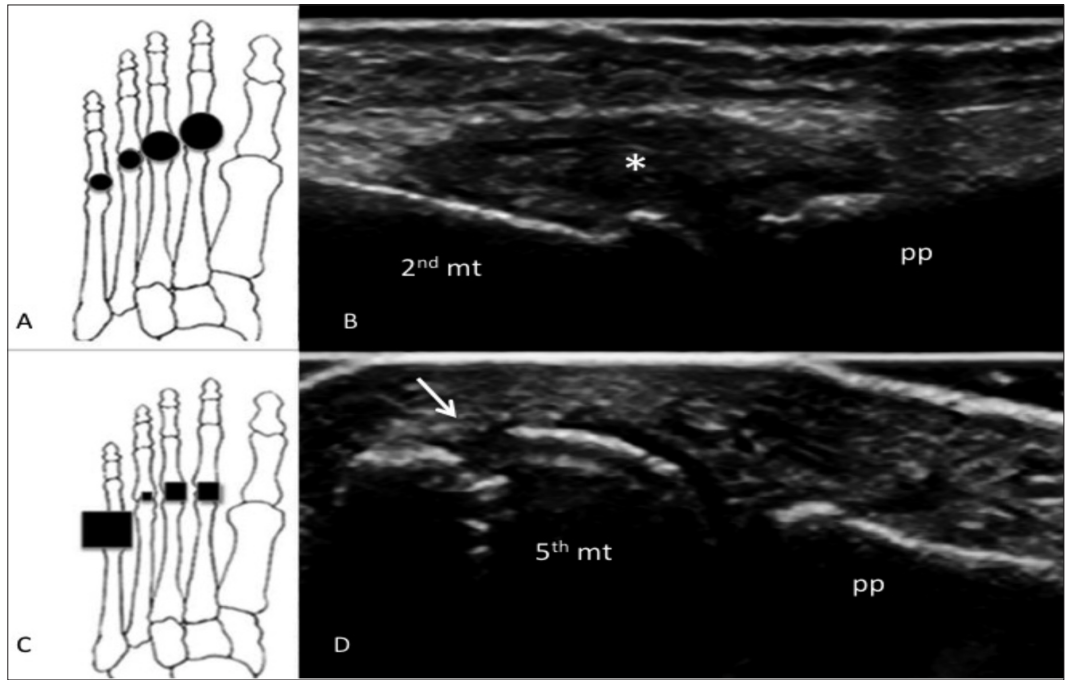
Fig. 1. Rheumatoid arthritis. **A.** Frequency of synovitis in metatarsophalangeal joints. The dimension of the circles are representative of the frequency of synovitis.

B. Dorsal longitudinal scan of the 2nd metatarsophalangeal joint: joint cavity widening due to effusion with synovial proliferation.

C. Frequency of erosions in metatarsophalangeal joints. The dimension of the boxes are representative of the frequency of erosions.

D. Lateral longitudinal scan of the 5th metatarsophalangeal joint: bone erosion on the metatarsal head (arrows).

mt = metatarsal bone
pp = proximal phalanx
* = synovial proliferation
Grey scale US using a Logiq 9 (General Electrics Medical Systems, Milwaukee, WI) with a 9-14 MHz linear probe.



out of 200 (42%) feet, at MTP plus at least one joint of the midfoot in other 41 out of 200 (20%) feet [making a total of 125 out of 200 (62%) MTP joints] exclusively in one or more joints of the midfoot in 7 out of 200 (3%) feet, in the PIP joint of the 2nd and 3rd toes in 3 (1.5%) and 4 (2%) feet, respectively, while no effusion with synovial proliferation was visualised in the PIP joint of the 4th and 5th toes. In Table I we reported the prevalence of effusion with synovial proliferation and erosions in the MTP joints.

The most frequently involved joint in our patients was the 2nd MTP with synovitis in 70 (35%) feet (in 24 patients bilaterally) with PD signal in 23 and erosions in 9 feet. As previously reported, we examined MTP joints for synovitis from the dorsal and plantar aspect. Very interestingly, in the 2nd and 3rd MTP joints, effusion with synovial proliferation was visualised in 3 and 7 feet, respectively, exclusively by US examination performed from the plantar aspect.

Among the joints of the midfoot, TN joint was the more frequently involved with synovitis imaged in 36 feet (in 11 patients bilaterally) with PD signal in 17 and erosive changes in 27. Effusion was rarely seen at the intermediate and lateral CM joint and the CMT4 and

CMT5 (in 2 and 1 and in 1 and 4 feet, respectively) and erosion only in lateral CM joint and CMT5 of 2 feet.

In 65 feet, no effusion and/or synovial proliferation were detected in any joint. Bone erosions could be visualised at each joint examined, both at the midfoot and forefoot level, but the most common were seen at the 5th MTP joint since erosive changes have been shown in almost half the feet, in 101 feet to be precise.

We observed plantar fascia-thickening in 16 feet (bilaterally in 4 patients) with no sign of rupture and plantar calcaneal enthesophytes in 20 out of 200 feet.

Anterior and posterior tibialis tendon insertion thickening was shown in 10 and 6 feet respectively. Bilateral partial tears of the posterior tibialis tendon were detected in one patient. No abnormalities of the peroneus brevis tendon were visualised.

At the time of the US examination, 85 out of 100 (85%) patients reported symptoms of pain in the midfoot and/or forefoot and 55 out of 100 (55%) also showed swelling of MTP and 38 of 100 (38%) at midfoot region. The exact agreement between clinical and US findings was 71%. Table II illustrates the relationship between US and clinical findings indicative of feet joint inflammation.

Discussion

Foot involvement is an important cause of disability in RA and imaging techniques, such as US and MRI, have been used to evaluate chronic inflammatory changes in the joints and tendons at foot level (11, 13, 15, 20). Szkudlarek *et al.* showed that the use of US allows detection and grading of destructive and inflammatory changes in the MTP joints of patients with RA and the results are concordant with those of MRI (13). A comparative study of clinical examination, US and high field MRI for the detection of rearfoot and mid-tarsal joint synovitis (including TN and CC joints) reported that US was more specific in identifying pathology in RA when compared to the reference standard of MRI (15).

Higher prevalence rates of forefoot pathology detectable by US than by clinical examination have been reported by Bowen *et al.* (21) suggesting that US imaging of the foot would be more beneficial than clinical examination alone in the refinement of diagnosis and the therapy monitoring.

Furthermore, in RA patients, treated with tumour necrosis factor blockades (adalimumab, etanercept, infliximab), PD US of the foot has been successfully applied to evaluate the therapeutic response of these agents (22).

In our study, foot joints of 100 RA patients were evaluated by US examination. Effusion associated to synovial proliferation was imaged at least in one MTP joint of a large number of feet (125 feet), in 10 MTP joints detectable only from the plantar side. Also the joints of midfoot are frequently involved mostly in association with MTP joint involvement. However, in 7 feet, only some joints of the midfoot, more frequently the TN joint, and no MTP or PIP joints appeared to be involved. Both these eventualities, which are the visualisation of effusion in MTP joint from the plantar side and the detection of inflammatory changes exclusively in some joints of the midfoot, even if rare must be kept in mind in order to avoid a US examination of the foot leading to erroneous conclusions.

Bone erosion is a typical manifestation of RA and US is undoubtedly more sensitive than plain radiograph in the early detection of erosions. We observed erosions scattered in most articular sites most commonly at the 5th MTP. Interestingly there was little evidence of effusion seen at this joint (32/200) but at least one erosion was present in almost half of the feet. This observation correlates well with those of Grassi *et al.* and Sheane *et al.* (23, 24). In fact, such Authors have previously reported that the 5th MTP joint is the most common site of sonographic erosion in patients with RA suggesting that, in the daily practice of the rheumatologist, US assessment of the 5th MTP joint must be included in the baseline approach to patients with arthritis. The rather low prevalence of effusion with synovial proliferation at the 5th MTP compared to the high frequency of erosions is unexpected and not an easily explainable phenomenon at the moment. We hypothesize that disease duration could play a role in the appearance of such a manifestation.

Plantar fascial and tendon involvement did not appear frequently in our patients with a lower prevalence of plantar fasciitis and calcaneal enthesophytosis than that reported by Falsetti *et al.*, who found plantar fasciitis in 26% and calcaneal entesophytosis in

34% of RA patients (25). Of note, in our study plantar fascia resulted the only site of active inflammation by US in 9 patients.

In 58 feet, discrepancies between the results of clinical examination and sonographic evaluations have been observed. In particular, in 30 feet, clinical examination reported joint tenderness but, by US, synovitis or tendon abnormalities were not imaged. On the contrary, in 28 feet, clinical examination failed to show pain and/or swelling at articular and periarticular districts but, by US, inflammatory synovitis was disclosed. Foot anatomy is complex and often it is difficult to differentiate between adjacent structures, for example at the joints of midfoot. Studies by Wakefield *et al.* and Bowen *et al.* (14, 21) suggest that clinical examination alone is unable to diagnose the precise features and extent of joint involvement in RA patients, thus leading to incorrect and ineffective therapies.

Patients were examined by 5 different sonographers and for a limited number of patients also a different machine was used. This may represent a limitation to this study because US is still considered to be operator dependent. However, all the sonographers involved in this study have a long experience in the assessment of synovitis and agreement on both the scanning technique and the definition of the pathological findings sought was obtained prior to the study commencing. Furthermore, it is known that moderate to good interreader agreement was shown in the first interobserver reliability study performed by 14 experts of the EULAR working group and these findings were confirmed in a larger study by Naredo *et al.* (26, 27).

US examination appears to be a useful imaging technique to study joint and tendon involvement of the foot of RA patients. Moreover, US examination of the foot is more sensitive than clinical examination in the detection of joint inflammation and allows for a better understanding of the features and the progression of the disease.

Future comparisons between US and MRI could help further understanding of this disease.

References

1. RIENTE L, DELLE SEDIE A, FILIPPUCCI E *et al.*: Ultrasound imaging for the rheumatologist IX. Ultrasound imaging in spondyloarthritis. *Clin Exp Rheumatol* 2007; 25: 349-53.
2. MEENAGH G, FILIPPUCCI E, IAGNOCCO A *et al.*: Ultrasound imaging for the rheumatologist VIII. Ultrasound imaging in osteoarthritis. *Clin Exp Rheumatol* 2007; 25: 172-5.
3. DELLE SEDIE A, RIENTE L, IAGNOCCO A *et al.*: Ultrasound imaging for the rheumatologist X. Ultrasound imaging in crystal-related arthropathies. *Clin Exp Rheumatol* 2007; 25: 513-7.
4. RIENTE L, DELLE SEDIE A, FILIPPUCCI E *et al.*: Ultrasound imaging for the rheumatologist XIV. Ultrasound imaging in connective tissue diseases. *Clin Exp Rheumatol* 2008; 26: 230-3.
5. DELLE SEDIE A, RIENTE L, FILIPPUCCI E *et al.*: Ultrasound imaging for the rheumatologist XV. Ultrasound imaging in vasculitis. *Clin Exp Rheumatol* 2008; 26: 391-4.
6. RIENTE L, SCIRÈ CA, DELLE SEDIE A *et al.*: Ultrasound imaging for the rheumatologist XXIII. Sonographic evaluation of hand joint involvement in primary Sjögren's syndrome. *Clin Exp Rheumatol* 2009; 27: 747-50.
7. DELLE SEDIE A, RIENTE L, SCIRE' CA *et al.*: Ultrasound imaging for the rheumatologist XXIV. Sonographic evaluation of wrist and hand joint and tendon involvement in systemic lupus erythematosus. *Clin Exp Rheumatol* 2009; 27: 897-901.
8. FILIPPUCCI E, IAGNOCCO A, MEENAGH G *et al.*: Ultrasound imaging for the rheumatologist VII. Ultrasound imaging in rheumatoid arthritis. *Clin Exp Rheumatol* 2007; 25: 5-10.
9. FILIPPUCCI E, MEENAGH G, DELLE SEDIE A *et al.*: Ultrasound imaging for the rheumatologist XX. Sonographic assessment of hand and wrist joint involvement in rheumatoid arthritis: comparison between two- and three-dimensional ultrasonography. *Clin Exp Rheumatol* 2009; 27: 197-200.
10. MCNALLY EG: Ultrasound of the small joints of the hands and feet: current status. *Skeletal Radiol* 2008; 37: 99-113.
11. BACKHAUS M: Ultrasound and structural changes in inflammatory arthritis: synovitis and tenosynovitis. *Ann NY Acad Sci* 2009; 1154: 139-51.
12. BACKHAUS M, OHRNDORF S, KELLNER H *et al.*: Evaluation of a novel 7-joint ultrasound score in daily rheumatologic practice: a pilot project. *Arthritis Rheum* 2009; 61: 1194-1201.
13. SZKUDLAREK M, NARVESTAD E, KLARLUND M, COURT-PAYEN M, THOMSEN HS, ØSTERGAARD M: Ultrasonography of the metatarsophalangeal joints in rheumatoid arthritis. *Arthritis Rheum* 2004; 50: 2103-12.
14. KOSKI JM: Ultrasonography of the subtalar and midtarsal joints. *J Rheumatol* 1993; 20: 1753-5.
15. WAKEFIELD RJ, FREESTON JE, O'CONNOR P *et al.*: The optimal assessment of the rheumatoid arthritis hindfoot: a comparative study of clinical examination, ultrasound and high field MRI. *Ann Rheum Dis* 2008 67: 1678-82.

16. DOHERTY M, DOHERTY J: Clinical examination in rheumatology. Vol 1, London, Wolfe Publishing; 1992.
17. ARNETT FC, EDWORTHY SM, BLOCH DA *et al.*: The American Rheumatism Association 1987 revised criteria for the classification of rheumatoid arthritis. *Arthritis Rheum* 1988; 31: 315-24.
18. WAKEFIELD RJ, BALINT PV, SZKUDLAREK M *et al.*: Musculoskeletal ultrasound including definitions for ultrasonographic pathology. *J Rheumatol* 2005; 32: 2485-7.
19. IAGNOCCO A, EPIS O, DELLE SEDIE A *et al.*: Ultrasound imaging for the rheumatologist XVII. Role of colour Doppler and power Doppler. *Clin Exp Rheumatol* 2008; 26: 759-62.
20. RIENTE L, DELLE SEDIE A, IAGNOCCO A *et al.*: Ultrasound imaging for the rheumatologist V. Ultrasonography of the ankle and foot. *Clin Exp Rheumatol* 2006; 24: 493-8.
21. BOWEN CJ, CULLIFORD D, DEWBURY K *et al.*: The clinical importance of ultrasound detectable forefoot bursae in rheumatoid arthritis. *Rheumatology* (Oxford). 2010; 49: 191-2.
22. BOWEN CJ, EDWARDS CJ, HOOPER L *et al.*: Improvement in symptoms and signs in the forefoot of patients with rheumatoid arthritis treated with anti-TNF therapy. *J Foot Ankle Res* 2010; 3: 10.
23. GRASSI W, FILIPPUCCI E, FARINA A, SALAFFI F, CERVINI C: Ultrasonography in the evaluation of bone erosions. *Ann Rheum Dis* 2001; 60: 98-103.
24. SHEANE BJ, BEDDY P, O'CONNOR M, MILLER S, CUNNANE G: Targeted ultrasound of the fifth metatarsophalanheal joint in an early inflammatory arthritis cohort. *Arthritis Rheum* 2009; 61: 1004-8.
25. FALSETTI P, FREDIANI B, FIORAVANTI A *et al.*: Sonographic study of calcaneal entheses in erosive osteoarthritis, nodal osteoarthritis, rheumatoid arthritis and psoriatic arthritis. *Scand J Rheumatol* 2003; 32: 229-34.
26. SCHEEL AK, SCHMIDT WA, HERMANN KG *et al.*: Inter-observer reliability of rheumatologists performing musculoskeletal ultrasonography: results from a EULAR "Train the Trainers" course. *Ann Rheum Dis* 2005; 64: 1043-9.
27. NAREDO E, MOLLER I, MORAGUES C *et al.*: Interobserver reliability in musculoskeletal ultrasonography: results from a "Teach the Teachers" rheumatologist course. *Ann Rheum Dis* 2006; 65: 14-9.