

# The Journal of Rheumatology

The Journal of Rheumatology

Volume 35, no. 1

Clinical and ultrasonographic monitoring of response to adalimumab treatment in rheumatoid arthritis.

Annamaria Iagnocco, Emilio Filippucci, Chiara Perella, Fulvia Ceccarelli, Emanuele Cassarà, Cristiano Alessandri, Emanuela Sabatini, Walter Grassi and Guido Valesini

J Rheumatol 2008;35;35-40

<http://www.jrheum.org/content/35/1/35>

1. Sign up for our monthly e-table of contents  
<http://www.jrheum.org/cgi/alerts/etoc>
2. Information on Subscriptions  
<http://jrheum.com/subscribe.html>
3. Have us contact your library about access options  
[Refer\\_your\\_library@jrheum.com](mailto:Refer_your_library@jrheum.com)
4. Information on permissions/orders of reprints  
<http://jrheum.com/reprints.html>

*The Journal of Rheumatology* is a monthly international serial edited by Earl D. Silverman featuring research articles on clinical subjects from scientists working in rheumatology and related fields.

# Clinical and Ultrasonographic Monitoring of Response to Adalimumab Treatment in Rheumatoid Arthritis

ANNAMARIA IAGNOCCO, EMILIO FILIPPUCCI, CHIARA PERELLA, FULVIA CECCARELLI, EMANUELE CASSARÀ, CRISTIANO ALESSANDRI, EMANUELA SABATINI, WALTER GRASSI, and GUIDO VALESINI

**ABSTRACT.** *Objective.* To evaluate by clinical, laboratory, and sonographic assessment the effects of adalimumab therapy in patients with rheumatoid arthritis (RA) over 24 months of treatment.

*Methods.* Twenty-five patients with RA were commenced on adalimumab therapy. Before the beginning of the therapy (Time 0) and after 3 (T1), 12 (T2), and 24 (T3) months we evaluated erythrocyte sedimentation rate, C-reactive protein, physician and patient visual analog scale for disease activity, number of tender and swollen joints, Health Assessment Questionnaire, and Disease Activity Score in 28 joints. In addition, musculoskeletal ultrasound (US) was performed bilaterally in the 2nd and 5th metacarpophalangeal, 3rd interphalangeal, wrist, and knee joints and in the tendon sheaths and bursae of those areas. A semiquantitative score (0–3) was used to indicate the presence of a localized inflammatory process and/or structural damage. The summed total was used as an indicator of global change in each joint (single joint score). The sum of the single joint scores was used as an indicator of overall polyarticular involvement in each patient (total score).

*Results.* Patients who did not submit to the planned examinations strictly on time were excluded from the study. Then 25 patients were examined at T0 and T1, 20 at T2, and 9 at T3. All clinical and laboratory measures as well as the US scores were significantly reduced during the followup.

*Conclusion.* A positive response to treatment with adalimumab was demonstrated by clinical, laboratory, and US evaluation by both short- and longterm followup. (First Release Nov 15 2007; J Rheumatol 2008;35:35–40)

## Key Indexing Terms:

BIOLOGICAL THERAPY  
ULTRASONOGRAPHY

RHEUMATOID ARTHRITIS

SYNOVITIS  
ADALIMUMAB

Rheumatoid arthritis (RA) is a chronic polyarthritis characterized by aggressive synovitis determining progressive joint destruction<sup>1</sup>. The inflammatory process results in permanent damage with consequent loss of physical function and ankylosis. In the progression of the disease a key role is played by tumor necrosis factor- $\alpha$  (TNF- $\alpha$ ), which represents the target of recent pharmacological strategies, such as the biologic drug adalimumab, aiming to limit its activities<sup>2</sup>. Adalimumab is used for its capacity to bind specifically to TNF- $\alpha$  and block its interaction with the p55 and p75 cell-surface TNF receptors, determining inhibition of TNF- $\alpha$ <sup>3-7</sup>.

Musculoskeletal ultrasonography (US) is a useful imaging technique in the diagnosis and followup of rheumatic dis-

eases. It is able to demonstrate the presence of inflammation in the joint and periarticular soft tissues as well as to show the presence of structural damage<sup>8</sup>. Using US it is possible to detect different changes related to synovitis, tenosynovitis, bursitis, bone erosions, and cartilaginous abnormalities starting in early disease<sup>9</sup>. The application of power Doppler US provides an accurate estimate of synovial perfusion, which has been shown to correlate with the presence of active synovitis<sup>10</sup>. Only a few studies about US evaluation of the response to biologic therapy have been published<sup>11-18</sup>. The results have, however, underlined the key role played by US as a reliable imaging modality in evaluation of the antiinflammatory effects of biologic therapy.

We assessed the response to adalimumab therapy by means of clinical, laboratory, and US indices of disease activity over 2 years of treatment.

## MATERIALS AND METHODS

Twenty-five consecutive patients, 21 women and 4 men, with RA fulfilling the American Rheumatology Association diagnostic criteria were studied. Patients were receiving adalimumab (40 mg subcutaneously, once every 2 wks) plus methotrexate (10–15 mg weekly) and/or hydroxychloroquine (400 mg daily) and/or cyclosporine A (3–5 mg/kg daily) and/or leflunomide (20 mg/daily) and nonsteroidal antiinflammatory drugs (diclofenac 50–100 mg daily or indomethacin 50–100 mg daily or nimesulide 100–200 mg daily) and steroids (methylprednisolone 4–8 mg daily). The mean age was 55.6 years (range 20.16–72.25) with mean disease duration of 11 years (range 3.8–30).

From the Rheumatology Unit, Sapienza Università di Roma, Rome; and the Rheumatology Department, Università Politecnica delle Marche, Ancona, Italy.

A. Iagnocco, MD, Assistant Professor; C. Perella, MD; F. Ceccarelli, MD, Research Fellow; E. Cassarà, MD; C. Alessandri, MD, Research Fellow; E. Sabatini, MD; G. Valesini, MD, PhD, Professor, Rheumatology Unit, Sapienza Università di Roma; E. Filippucci, MD, Assistant Professor; W. Grassi, MD, PhD, Professor, Rheumatology Department, Università Politecnica delle Marche.

Address reprint requests to Dr. A. Iagnocco, Dipartimento Clinica e Terapia Medica Applicata, Cattedra di Reumatologia, Sapienza Università di Roma, Viale del Policlinico 155, Roma, 00161, Italy.  
E-mail: annamaria.iagnocco@uniroma1.it

Accepted for publication August 23, 2007.

Personal non-commercial use only. The Journal of Rheumatology Copyright © 2008. All rights reserved.

US, clinical, and laboratory examinations were performed just before starting adalimumab (Time 0) and after 3, 12, and 24 months (T1, T2, and T3, respectively). Patients who did not submit to the planned examinations invariably and strictly on time were excluded from the study. For this reason with respect to 25 patients examined at T0 and T1, the number reduced to 20 at T2 and to only 9 at T3.

Our study was carried out at the Rheumatology Unit of La Sapienza University in Rome, Italy, and was conducted in compliance with good clinical practices, following the routine monitoring procedures performed in our unit for patients with arthritis.

**Clinical and laboratory evaluation.** The clinical and laboratory values measured at T0, T1, T2, and T3 are listed in Table 1. Clinical evaluation was performed by an experienced rheumatologist (FC) who was blinded to the US assessment and the laboratory data.

**US examination.** The joints, periarticular structures, and measures studied by US are listed in Table 1. The joints evaluated were chosen because they are commonly involved in RA and they can be reliably assessed by US. The US examination was performed using a Philips/HP Image Point HX machine with a 10 MHz linear probe for knee joints and a 14 MHz probe for the hands and wrists. In addition, power Doppler US was used with the following settings: frequency 7 MHz, PRF varying from 700 to 1000 (according to the joint studied), gain 18–30 dB, low filter. The US study was performed by an experienced rheumatologist sonographer (AI) who was blinded to the clinical and laboratory findings.

Using a multiplanar scanning technique<sup>19,20</sup>, the presence of any inflammation-related change in the joints and/or in the adjacent tendon sheaths and bursae (effusion, synovial proliferation, increased local perfusion by power Doppler US) was assessed. The presence of permanent joint damage (bone and cartilaginous erosions) was also registered. The changes within each articular and periarticular structure were recorded as being present in accord with definitions in the literature<sup>21</sup> and registering the highest score during the multiplanar scanning evaluation. For all the changes a semiquantitative score (0–3) was used for each structure examined, where 0 was to indicate the absence of any change and 1 to 3 the presence, respectively, of a slight, moderate, and severe change (single-measure score). The subsequent summed

total was used as an indicator of global change at each timepoint in each joint (single-joint score). The sum of the single-joint scores was used as an indicator of overall polyarticular involvement in each patient (total score).

**Statistical analysis.** Data were reported as median values with the interquartile ranges in cases of variables with nonstandard distribution.

Data were analyzed using McNemar test and Wilcoxon paired test. Statistical significance was taken at a p value < 0.05.

## RESULTS

Our results are reported in Tables 2 and 3 and in Figures 1 and 2.

Erythrocyte sedimentation rate (ESR) fell significantly from a median value of 34, to 24 (p < 0.0001) at T1, 25 (p < 0.0001) at T2, and 20 (p < 0.003) at T3. C-reactive protein (CRP) also decreased, from a median value of 19.9 at T0 to 3.6 at T1 (p < 0.0001), 3.5 at T2 (p < 0.0003), and 3.5 at T3 (p < 0.01).

Median Health Assessment Questionnaire (HAQ) values fell significantly, from 1.62 at baseline to 0.62 at 3 months (p < 0.0001), 0.5 at 12 months (p < 0.0001), and 0.5 at 24 months (p < 0.0001).

The number of tender joints changed significantly, from a median of 15 at T0 to 2 at T1 (p < 0.0001), 2 at T2 (p < 0.0001), and 1 at T3 (p < 0.003). Similarly, the median number of swollen joints also fell significantly, from 9 at baseline to 0 at T1 (p < 0.0001), 0 at T2 (p < 0.0001), and 0 at T3 (p < 0.007).

The median physician VAS decreased significantly, from 67 at T0 to 20 at T1 (p < 0.0001), 19 at T2 (p < 0.0001), and 20 at T3 (p < 0.007). Also the median patient VAS decreased significantly from 65 at T0 to 21 at T1 (p < 0.0001), 15 at T2 (p < 0.0001), and 15 at T3 (p < 0.007).

The mean Disease Activity Score for 28 joints (DAS28) fell significantly, from 6.3 at baseline to 3.5 at 3 months (p < 0.0001), 2.8 at 12 months (p < 0.0001), and 3 at 24 months (p < 0.003).

US showed a significant reduction in the total score during the followup, from T0 to T1 (p < 0.0001), T2 (p < 0.0001), and T3 (p < 0.0001). In particular, the median total score was 11 (range 4–19) at baseline and decreased to 6.1 (range 0–14) at T1, 5.8 (range 1–17) at T2, and 6.1 (range 1–15) at T3. During the whole 24 months' followup, even the single-joint scores decreased significantly in most cases, ranging from p < 0.0001 to p < 0.03. The only nonsignificant reduction was present at T3 for the third proximal interphalangeal joint score and for the second metacarpophalangeal joint score.

As reported in Figure 1, the reduction of the total score during the followup corresponded to a similar and parallel decrease in DAS28.

In Figure 2, a reduction of joint effusion in the knee (A and B) and in the wrist (C and D) is shown after 3 months of treatment (T1).

## DISCUSSION

The use of biologic agents as a treatment of RA has increased markedly over the last few years and it has been the subject of

**Table 1.** Clinical, laboratory, and ultrasound (US) measures studied.

Clinical and laboratory measures
Erythrocyte sedimentation rate
C-reactive protein
Patient visual analog score (VAS)
Physician VAS
Health Assessment Questionnaire
Number of tender joints
Number of swollen joints
Disease Activity Score 28
Joints and periarticular structures studied by US (bilaterally)
II metacarpophalangeal (MCP)
V MCP
III proximal interphalangeal
Wrist
Knee
II-III-V digits flexor tendons
Wrist flexor and extensor tendons
Gastrocnemius-semimembranosus bursa
US measures evaluated (score 0–3)
Synovial membrane: proliferation/thickening/hyperperfusion (power Doppler)
Synovial fluid: effusion
Bone and cartilage: erosions
Tendon sheath and gastrocnemius-semimembranosus bursa: local effusion/synovial proliferation ± hyperperfusion

Table 2. Results at T0, T1, T2, and T3. Data are expressed as median values, interquartile, and ranges (p value).

	T0	T1	T2	T3
No. of patients	25	25	20	9
ESR	34; 4–96	24; 2–56 ( $< 0.0001$ )	25; 3–97 (0.0001)	20; 8–30 (0.003)
CRP	19.9; 3–227	3.6; 3–112 (0.0001)	3.5; 2–98 (0.0003)	3.5; 3–84 (0.01)
HAQ	1.62; 0.12–2.87	0.62; 0–2.87 ( $< 0.0001$ )	0.5; 0–2.5 ( $< 0.0001$ )	0.5; 0–2 (0.003)
No. of tender joints	15; 3–26	2; 0–12 ( $< 0.0001$ )	2; 0–25 ( $< 0.0001$ )	1; 0–10 (0.003)
No. of swollen joints	9; 1–24	0; 0–8 ( $< 0.0001$ )	0; 0–11 ( $< 0.0001$ )	0; 0–8 (0.007)
Physician VAS	67; 25–94	20; 0–69 ( $< 0.0001$ )	19; 0–94 ( $< 0.0001$ )	20; 0–40 (0.007)
Patient VAS	65; 21–94	21; 0–81 ( $< 0.0001$ )	15; 0–76 ( $< 0.0001$ )	15; 5–40 (0.007)
DAS28	6.3; 4.2–7.9	3.5; 0–6.5 ( $< 0.0001$ )	2.8; 0–6.9 ( $< 0.0001$ )	3; 1.6–4.8 (0.003)
US scores				
knee + Baker's cyst	4; 1–7	2; 0–6 ( $< 0.0001$ )	2; 0–5 (0.0001)	2; 1–5 (0.006)
wrist + flexor and extensor tendons	3; 0–6	2; 0–5 ( $< 0.0001$ )	2; 0–5 (0.0002)	1; 0–4 (0.003)
5th MCP + flexor tendons	1; 0–4	1; 0–2 ( $< 0.0001$ )	1; 0–2 ( $< 0.0001$ )	0; 0–7 (0.02)
3rd PIP + flexor tendons	0.5; 0–3	0; 0–3 (0.03)	0; 0–1 ( $< 0.0001$ )	1; 0–3 NS
2nd MCP + flexor tendons	1; 0–4	1; 0–3 (0.0004)	1; 0–6 (0.004)	1; 0–4 NS
Total Score	11; 4–19	6.1; 0–14 ( $< 0.0001$ )	5.8; 1–17 ( $< 0.0001$ )	6.1; 1–15 ( $< 0.0001$ )

ESR: erythrocyte sedimentation rate; CRP: C-reactive protein; HAQ: Health Assessment Questionnaire; VAS: visual analog scale; DAS: Disease Activity Score; US: ultrasound; MCP: metacarpophalangeal; PIP: proximal interphalangeal.

increasing interest for the documented evidence of positive effects in patients who are nonresponders or partial responders to disease modifying antirheumatic drug therapy<sup>22–26</sup>.

Over the last few decades the application of US in the assessment of joint and soft tissues changes in rheumatic diseases has progressively widened. Recently, the use of Doppler and the technological improvement of US equipment have further shown the usefulness of this diagnostic tool in the evaluation of arthritis<sup>27,28</sup>. In particular, some recent articles have documented the reliability of gray-scale US and power/color Doppler to monitor the response to biologic therapy in RA and spondyloarthritis<sup>17</sup>. In the first publication about this topic, Hau, *et al* demonstrated a significant reduction in the synovial perfusion with power Doppler US at the level of the second metacarpophalangeal joint<sup>15</sup> in 5 patients with RA treated with etanercept. Subsequently, a decrease in power Doppler US signal within the Achilles tendon insertion in 2 patients treated with infliximab was reported<sup>11</sup>. A reduction was shown in the signs of synovitis by gray-scale and power Doppler US in hand joints of patients with RA treated with infliximab<sup>12</sup>. Then, a relevant decrease in the synovial

perfusion in hand and wrist joints in patients with RA treated with etanercept was demonstrated<sup>19</sup>. In patients with RA treated with methotrexate and infliximab or placebo a reduction in inflammation and retardation of joint destruction in those who received infliximab was documented by both radiography and US<sup>13</sup>. A significant decrease in power Doppler signal and thinning of the synovial membrane in patients with RA and psoriatic arthritis treated with etanercept has been described<sup>17</sup>. Finally, we have also recently documented the response to adalimumab therapy in RA, demonstrating a reduction in the synovial perfusion by power Doppler US over 12 weeks of treatment<sup>18</sup>.

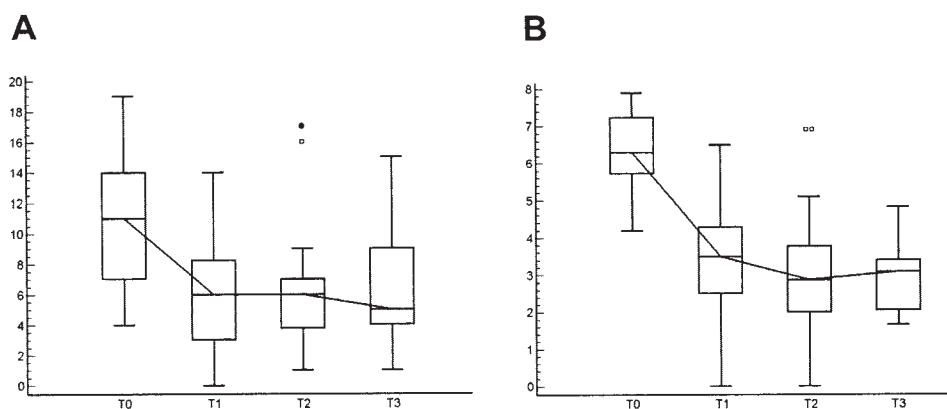
To our knowledge, this study represents the first attempt to investigate by clinical, laboratory, and US assessment the short- and longterm effects of adalimumab therapy on multiple measures in various joints in patients with RA. Until now the response to biologic treatment had been documented in very few studies, which were limited by the number of patients evaluated, the low number of joints examined, and the short period of followup<sup>11–18</sup>.

We observed a good short- and longterm response to treat-

**Table 3.** Ultrasound (US) variations of the single measure scores at T0, T1, T2, and T3. Significance values are in relation to baseline values (T0; McNemar test). Number of joints out of the total assessed that had a detectable US abnormality at T0, T1, T2, and T3 is reported. Values refer to the number of joints in which the different findings are present.

No. Joints Involved (%)	Ultrasonographic Changes	T0	T1	p	T2	p	T3	p
Knee joint	Synovial proliferation	27 (54)	20 (40)	NS	16 (42)	NS	5 (28)	< 0.05
	Power Doppler	10 (20)	4 (8)	NS	3 (8)	NS	2 (11)	NS
	Joint effusion	26 (52)	10 (20)	0.004	8 (21)	0.005	6 (33)	NS
	Erosions	37 (74)	40 (80)	NS	34 (89)	NS	14 (78)	NS
Gastrocnemius-semimebranosus bursa	Baker's cyst	12 (24)	6 (12)	NS	7 (18)	NS	7 (39)	NS
Wrist joint	Synovial proliferation	37 (74)	22 (44)	0.008	18 (47)	0.0009	6 (33)	0.004
	Power Doppler	28 (56)	6 (12)	0.0001	7 (18)	NS	1 (6)	0.002
	Joint effusion	29 (58)	6 (12)	0.0001	7 (18)	0.001	3 (17)	0.001
	Erosions	43 (86)	44 (88)	NS	39 (103)	0.003	18 (100)	NS
Wrist flexor and extensor tendons	Tendon sheath distension	24 (48)	3 (6)	0.0001	6 (16)	0.0008	6 (33)	NS
3rd PIP joint	Synovial proliferation	8 (16)	1 (2)	0.04	2 (5)	NS	1 (6)	NS
	Power Doppler	0 (0)	0 (0)	NS	2 (5)	NS	0 (0)	NS
	Joint effusion	10 (20)	3 (6)	NS	2 (5)	NS	2 (11)	NS
	Erosions	19 (38)	20 (40)	NS	19 (50)	NS	8 (44)	NS
3rd finger flexor tendons	Tendon sheath distension	6 (12)	1 (2)	NS	2 (5)	NS	0 (0)	NS
5th MCP joint	Synovial proliferation	17 (34)	2 (4)	0.001	2 (5)	0.002	3 (17)	NS
	Power Doppler	2 (4)	0 (0)	NS	0 (0)	NS	0 (0)	NS
	Joint effusion	23 (46)	4 (8)	0.0001	0 (0)	0.0001	2 (11)	0.02
	Erosions	31 (62)	32 (64)	NS	26 (68)	NS	7 (39)	NS
5th finger flexor tendons	Tendon sheath distension	7 (14)	0 (0)	0.02	0 (0)	0.04	0 (0)	NS
2nd MCP joint	Synovial proliferation	17 (34)	5 (10)	0.04	5 (13)	0.006	2 (11)	NS
	Power Doppler	4 (8)	0 (0)	NS	2 (5)	NS	1 (6)	NS
	Joint effusion	17 (34)	3 (6)	0.003	2 (5)	0.004	5 (28)	NS
	Erosions	28 (56)	29 (58)	NS	23 (61)	NS	11 (61)	NS
2nd finger flexor tendons	Tendon sheath distension	8 (16)	3 (6)	NS	1 (3)	NS	0 (0)	NS

NS: nonsignificant.



**Figure 1.** A. Total joint scores by US. The sum of single-joint scores was used as an indicator of overall polyarticular involvement in each patient and expressed as total score.  $p < 0.01$ , T0 compared to T1, T2, T3. B. DAS28 scores.  $p < 0.01$ , T0 compared to T1, T2, T3. Median, quartiles, range, and extreme values are shown. °: outliers.

ment by clinical, laboratory, and US evaluation. In particular, referring to US, the reduction in the total score as well as in the single-joint scores attests to the positive effects of the therapy both systemically and locally. The short-term response to adalimumab appeared immediately evident in all patients and was confirmed after 1 year. The positive trend was subse-

quently maintained after 2 years in the 9 subjects in which the followup was performed. The importance of these data is confirmed by a parallel and significant reduction in all the clinical and laboratory indices of disease activity.

The low number of patients in whom the longterm followup was performed represents a limitation of our study,

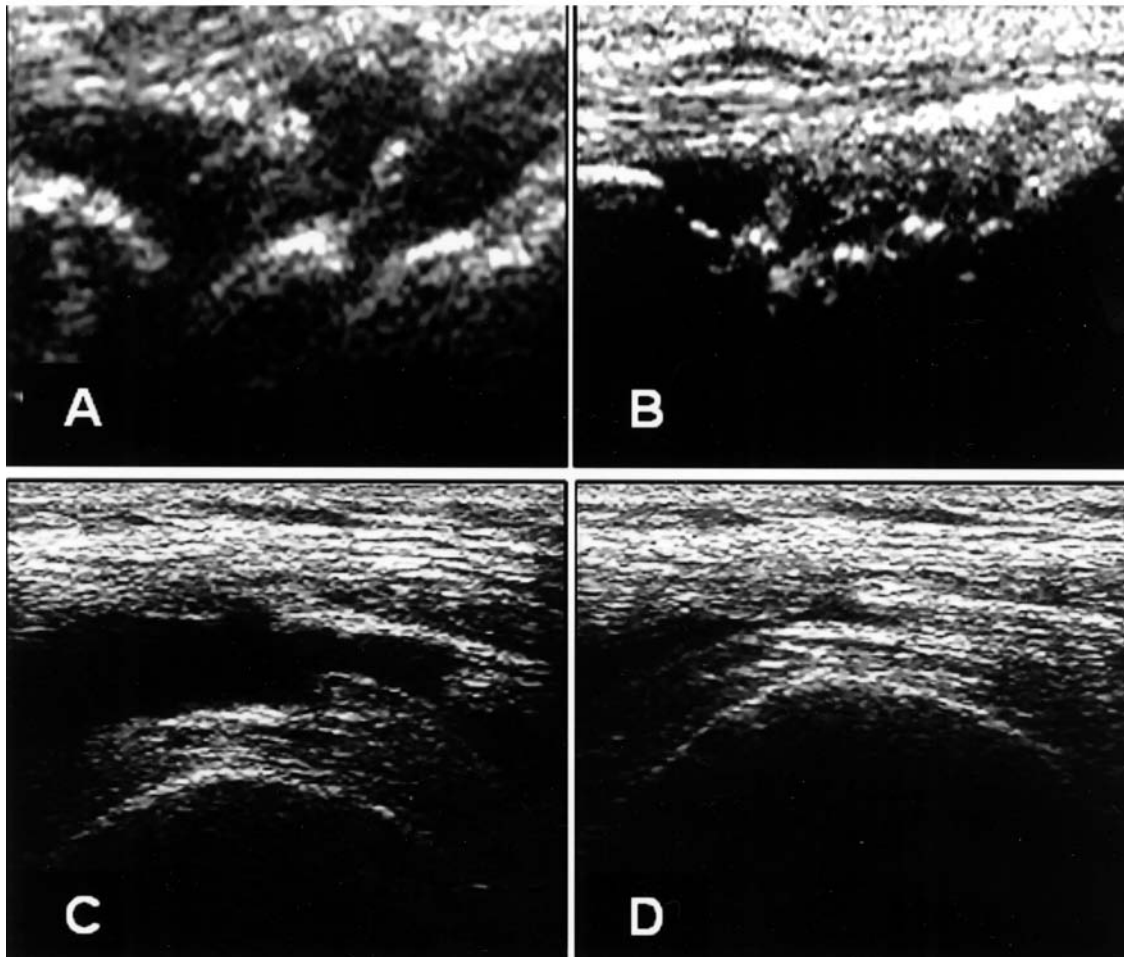


Figure 2. Reduction of joint effusion in the knee (A and B) and in the wrist (C and D) after 3 months' treatment (T1). A and B: transverse scan of the suprapatellar bursa (A: T0; B: T1). C and D: longitudinal scan of the wrist (C: T0; D: T1).

although it is an interesting finding that needs further confirmations on larger cohorts of patients.

The fact that we have not examined by US some frequently involved articular sites such as the foot and the second proximal interphalangeal joints represents another limitation of our study. More extended evaluations on multiple joints are recommended.

An interesting finding was that US is a valuable tool for analysis of the response to treatment in RA. This diagnostic tool has many advantages over other techniques and procedures and by clinical indices of disease activity. Indeed, it is characterized by low cost, noninvasiveness, and the possibility of a contemporaneous assessment of many different joints, making it possible to analyze both inflammatory and structural changes<sup>29-31</sup>. We documented a close relationship between US findings and the commonly used clinical and serological indices of disease activity, confirming and strengthening the case for using US as one of the investigations of choice in the monitoring of biologic therapy in RA<sup>32-36</sup>.

## REFERENCES

1. Goronzy JJ, Weyand CM. Rheumatoid arthritis. *Immunol Rev* 2005;204:55-73.
2. Macias I, Garcia-Perez S, Ruiz-Tudela M, Medina F, Chozas N, Giron-Gonzalez JA. Modification of pro- and antiinflammatory cytokines and vascular-related molecules by tumor necrosis factor- $\alpha$  blockade in patients with rheumatoid arthritis. *J Rheumatol* 2005;32:2102-8.
3. Navarro-Sarabia F, Ariza-Ariza R, Hernandez-Cruz B, Villanueva I. Adalimumab for treating rheumatoid arthritis. *Cochrane Database Syst Rev* 2005 20;3:CD005113.
4. Rau R. Adalimumab (a fully human anti-tumor necrosis factor a monoclonal antibody) in the treatment of active rheumatoid arthritis: the initial results of five trials. *Ann Rheum Dis* 2002;61:70-3.
5. Moreland L. Adalimumab in rheumatoid arthritis. *Curr Rheumatol Rep* 2004;6:333-4.
6. Keystone E, Haraoui B. Adalimumab therapy in rheumatoid arthritis. *Rheum Dis Clin North Am* 2004;30:349-64.
7. Keystone EC, Haraoui B, Bykerk VP. Role of adalimumab in the treatment of early rheumatoid arthritis. *Clin Exp Rheumatol* 2003;21:198-9.
8. Filippucci E, Iagnocco A, Meenagh G, et al. Ultrasound imaging

- for the rheumatologist. *Clin Exp Rheumatol* 2006;24:1-5.
9. Filippucci E, Iagnocco A, Meenagh G, et al. Ultrasound imaging for the rheumatologist. II. Ultrasonography of the hand and wrist. *Clin Exp Rheumatol* 2006;24:118-22.
  10. Szkudlarek M, Court-Payen M, Strandberg C, Klarlund M, Klausen T, Østergaard M. Power Doppler ultrasonography for assessment of synovitis in the metacarpophalangeal joints of patients with rheumatoid arthritis: a comparison with dynamic magnetic resonance imaging. *Arthritis Rheum* 2001;44:2018-23.
  11. D'Agostino MA, Breban M, Said-Nahal R, Dougados M. Refractory inflammatory heel pain in spondylarthropathy: a significant response to infliximab documented by ultrasound. *Arthritis Rheum* 2002;46:840-1.
  12. Ribbens C, Andre B, Marcelis S, et al. Rheumatoid hand joint synovitis: gray-scale and power Doppler US quantifications following anti-tumor necrosis factor-alpha treatment: pilot study. *Radiology* 2003;229:562-9.
  13. Taylor PC, Steuer A, Gruber J, et al. Comparison of ultrasonographic assessment of synovitis and joint vascularity with radiographic evaluation in a randomized, placebo-controlled study of infliximab therapy in early rheumatoid arthritis. *Arthritis Rheum* 2004;50:1107-16.
  14. Taylor PC, Steuer A, Gruber J, et al. Ultrasonographic and radiographic results from a two-year controlled trial of immediate or one-year-delayed addition of infliximab to ongoing methotrexate therapy in patients with erosive early rheumatoid arthritis. *Arthritis Rheum* 2006;54:47-53.
  15. Hau M, Kneitz C, Tony H-P, et al. High resolution ultrasound detects a decrease in pannus vascularisation of small finger joints in patients with rheumatoid arthritis receiving treatment with soluble tumor necrosis factor a receptor (etanercept). *Ann Rheum Dis* 2002;61:55-8.
  16. Terslev L, Torp-Pedersen S, Qvistgaard E, et al. Effects of treatment with etanercept (Enbrel, TNFR:Fc) on rheumatoid arthritis evaluated by doppler ultrasonography. *Ann Rheum Dis* 2003;62:178-81.
  17. Fiocco U, Ferro F, Vezzu M, et al. Rheumatoid and psoriatic knee synovitis: clinical, grey scale, and power Doppler ultrasound assessment of the response to etanercept. *Ann Rheum Dis* 2005;64:899-905.
  18. Filippucci E, Iagnocco A, Salaffi F, Cerioni A, Valesini G, Grassi W. Power Doppler sonography monitoring of synovial perfusion at wrist joint in rheumatoid patients treated with adalimumab. *Ann Rheum Dis* 2006;65:1433-7. Epub 2006 Feb 27.
  19. Backhaus M, Burmester G-R, Gerber T, et al. Guidelines for musculoskeletal ultrasound in rheumatology. *Ann Rheum Dis* 2001;60:641-9.
  20. Schmidt WA, Schmidt H, Schicke B, Gromnica-Ihle E. Standard reference values for musculoskeletal ultrasonography. *Ann Rheum Dis* 2004;63:988-94.
  21. Wakefield RJ, Balint PV, Szkudlarek M, et al. OMERACT 7 Special Interest Group. Musculoskeletal ultrasound including definitions for ultrasonographic pathology. *J Rheumatol* 2005;32:2485-7.
  22. Furst DE, Breedveld FC, Kalden JR, et al. Updated consensus statement on biological agents for the treatment of rheumatoid arthritis and other rheumatic diseases. *Ann Rheum Dis* 2002;61:2-7.
  23. Bresnihan B. Effects of anakinra on clinical and radiological outcomes in rheumatoid arthritis. *Ann Rheum Dis* 2002;61:74-7.
  24. Maini RN, Taylor PC, Paleolog E, et al. Anti-tumor necrosis factor specific antibody (infliximab) treatment provides insights into the pathophysiology of rheumatoid arthritis. *Ann Rheum Dis* 1999;58:156-60.
  25. van der Heijde D, Klareskog L, Singh A, et al. Patient-reported outcomes in a trial of combination therapy with etanercept and methotrexate for rheumatoid arthritis: the TEMPO trial. *Ann Rheum Dis* 2006;65:328-34.
  26. Moreland L. Etanercept and methotrexate combination in rheumatoid arthritis. *Curr Rheumatol Rep* 2004;6:333.
  27. Naredo E, Gamero F, Bonilla G, Uson J, Carmona L, Laffon A. Ultrasonographic assessment of inflammatory activity in rheumatoid arthritis: comparison of extended versus reduced joint evaluation. *Clin Exp Rheumatol* 2005;23:881-4.
  28. Iagnocco A, Cerioni A, Coari G, Ossandon A, Masciangelo R, Valesini G. Intra-articular methotrexate in the treatment of rheumatoid arthritis and psoriatic arthritis: a clinical and sonographic study. *Clin Rheumatol* 2006;25:159-63.
  29. Filippucci E, Farina A, Carotti M, Salaffi F, Grassi W. Grey scale and power Doppler sonographic changes induced by intra-articular steroid injection treatment. *Ann Rheum Dis* 2004;63:740-3.
  30. Walther M, Harms H, Krenn V, Radke S, Faehndrich TP, Gohlke F. Correlation of power Doppler sonography with vascularity of the synovial tissue of the knee joint in patients with osteoarthritis and rheumatoid arthritis. *Arthritis Rheum* 2001;44:331-8.
  31. Szkudlarek M, Court-Payen M, Strandberg C, Klarlund M, Klausen T, Østergaard M. Power doppler ultrasonography for assessment of synovitis in the metacarpophalangeal joints of patients with rheumatoid arthritis. *Arthritis Rheum* 2001;44:2018-23.
  32. Cardinal E, La Fortune M, Burns P. Power doppler US in synovitis: reality or artifact? *Radiology* 1996;200:868.
  33. Klauser A, Frauscher F, Schirmer M, et al. The value of contrast-enhanced color Doppler ultrasound in the detection of vascularization of finger joints in patients with rheumatoid arthritis. *Arthritis Rheum* 2002;46:647-53.
  34. Klocke R, Glew D, Cox N, Blake DR. Sonographic erosions of the rheumatoid little toe. *Ann Rheum Dis* 2001;60:896-904.
  35. Magarelli N, Guglielmi G, Di Matteo L, Tartaro A, Mattei PA, Bonomo L. Diagnostic utility of an echo-contrast agent in patients with synovitis using power doppler ultrasound: a preliminary study with comparison to contrast-enhanced MRI. *Eur Radiol* 2001;11:1039-46.
  36. Stone M, Bergin D, Whelan B, Maher M, Murray J, McCarthy C. Power doppler ultrasound assessment of rheumatoid hand synovitis. *J Rheumatol* 2001;28:1979-82.