

AperTO - Archivio Istituzionale Open Access dell'Università di Torino

Chronic acquired hepatocerebral degeneration, pallidal T1 MRI hyperintensity and manganese in a series of cirrhotic patients.

This is the author's manuscript

Original Citation:

Availability:

This version is available <http://hdl.handle.net/2318/151063> since

Published version:

DOI:10.1007/s10072-013-1458-x

Terms of use:

Open Access

Anyone can freely access the full text of works made available as "Open Access". Works made available under a Creative Commons license can be used according to the terms and conditions of said license. Use of all other works requires consent of the right holder (author or publisher) if not exempted from copyright protection by the applicable law.

(Article begins on next page)



UNIVERSITÀ DEGLI STUDI DI TORINO

This is an author version of the contribution published on:

Questa è la versione dell'autore dell'opera:

Neurological Sciences 35 (4) 2014 : 523–530

DOI : [10.1007/s10072-013-1458-x](https://doi.org/10.1007/s10072-013-1458-x)

The definitive version is available at:

La versione definitiva è disponibile alla URL:

<http://link.springer.com/article/10.1007%2Fs10072-013-1458-x>

Introduction

Chronic acquired hepatocerebral degeneration (CAHD) is a neurological disorder characterized by parkinsonism and cognitive impairment [1]. CAHD accompanies chronic liver failure when associated with cirrhosis and is poorly responsive to levo-dopa treatment. The condition is rare and the prevalence of CAHD in patients with cirrhosis is approximately 2 % [2].

A T1 hyperintensity of the globus pallidum is found in the brain MRI of most patients with CAHD [3, 4]. Elevated concentrations of manganese (Mn) in the basal ganglia have been measured in patients with liver diseases [5] and are consistent with the basal ganglia hyperintense signal in the T1-weighted MRI [6]. The role of Mn as the origin of the MRI signal is also supported by its preferential accumulation in the globus pallidum of manganese-intoxicated monkeys [7]. In addition, chronic Mn intoxication in humans, secondary to professional exposure, is responsible for Mn accumulation in the basal ganglia, pallidal T1 hyperintensity on MRI and development of a parkinsonian syndrome [8].

A similar pallidal T1 hyperintense signal is also reported in the brain MRI of patients with chronic liver diseases that have no central nervous system symptoms [9]. The resolution of both the T1 hyperintense signal and CAHD after orthotopic liver transplantation (OLT) is reported in anecdotic cases [9±14].

Chronic acquired hepatocerebral degeneration, Mn, and MRI pallidal signals in patients with chronic liver failure thus seem to be interconnected, but the correlation between the MRI signal and CAHD in a series of liver patients has not been evaluated. There is little information on the long-term follow-up of liver patients with a brain MRI signal in the globus pallidus. The possible role of the T1 signal as a predictor of CAHD also has not been addressed.

The aim of the present study was to observe a large series of patients affected by chronic liver disease with cirrhosis. The following were evaluated in this study: the association between pallidal T1 hyperintensity, CAHD, and blood levels of Mn; the effect of liver transplantation on the MRI signal and neurological findings; and the possible role of the pallidal signal as a predictor of CAHD.

Patients and methods

Patients with pallidal T1 hyperintensity as revealed by brain MRI were selected out of the liver patients that were consecutively referred to the Transplant Neurology Clinic over the time period 2005±2012. A brain MRI was performed as part of the diagnostic work-up in some patients; other referred patients had previously received a brain MRI for variable reasons. The neurological examination of the patients was specifically aimed to assess and graduate movement disorders. The severity index of 13 signs and symptoms (see Table 2) was expressed by a grade of 3; the maximum global impairment was 35. Functional imaging by SPECT and PET was performed when necessary for the diagnosis. The neuropsychological examination investigated cognitive domains, such as attention, memory and language, as suggested for liver patients [15]. The texts shown in Table 6 were employed.

This type of study did not permit a standardized analysis of the signal intensity. We were not able to objectively quantify the T1-weighted pallidal signal by the pallidal index [16] because the images were produced at different times and in different systems. The intensity of the T1-weighted bilateral pallidal signal, which was absent in the T2-weighted images, was subjectively evaluated by a

QXURUDGLRORJLVWZLWKRXWSULRUNRZOHGJHRIWKHSDWLHQVFRQHWLGRQKHLQHQWLW
JUDGHGDVIZKHQEVHQZKHQLVLEOHZKHQVHQHDQ GZKHQHULQHQH

The blood manganese concentrations were determined by atomic absorption spectrometry [17]. The concentration in controls was 0.15 ± 0.02 g/L (value provided by the laboratory).

Included neurological, neuropsychological, and MRI examinations and was not limited to the subgroup of patients who underwent OLT. The decision to rule patients on or off the liver transplantation list was made by the hepatologists and was independent from the neurological condition of the patients.

The time interval between the earliest MRI with a pallidal signal and CAHD presentation was recorded. In addition, the time between the day of OLT and the day of the last neurological examination was recorded and ranged from 7 to 166 months (median 33 months). The time between the day of the earliest MRI with a positive signal and the day of the last neurological examination was also considered and ranged between 7 and 69 months (median 18 months).

Results

Ninety patients with cirrhosis were referred for a neurological consultation.

The reasons for which the patients were referred to the Neurologic Clinic were either variable neurological symptoms or signs (such as tremor, pain, weakness, depressive mood, and epileptic seizures); neurological conditions (such as focal brain lesions, traumatic scars, lacunar infarcts, vascular malformations, and meningioma); and subacute polyneuropathies or traumatic mononeuropathies.

In 26 out of 90 patients, the brain MRI showed bilaterally increased signal intensities at the globus pallidus in the T1-weighted image, which was absent in the T2 images. The pallidal signal change was visible in the sagittal and axial sequences (Fig. 1 a, b).

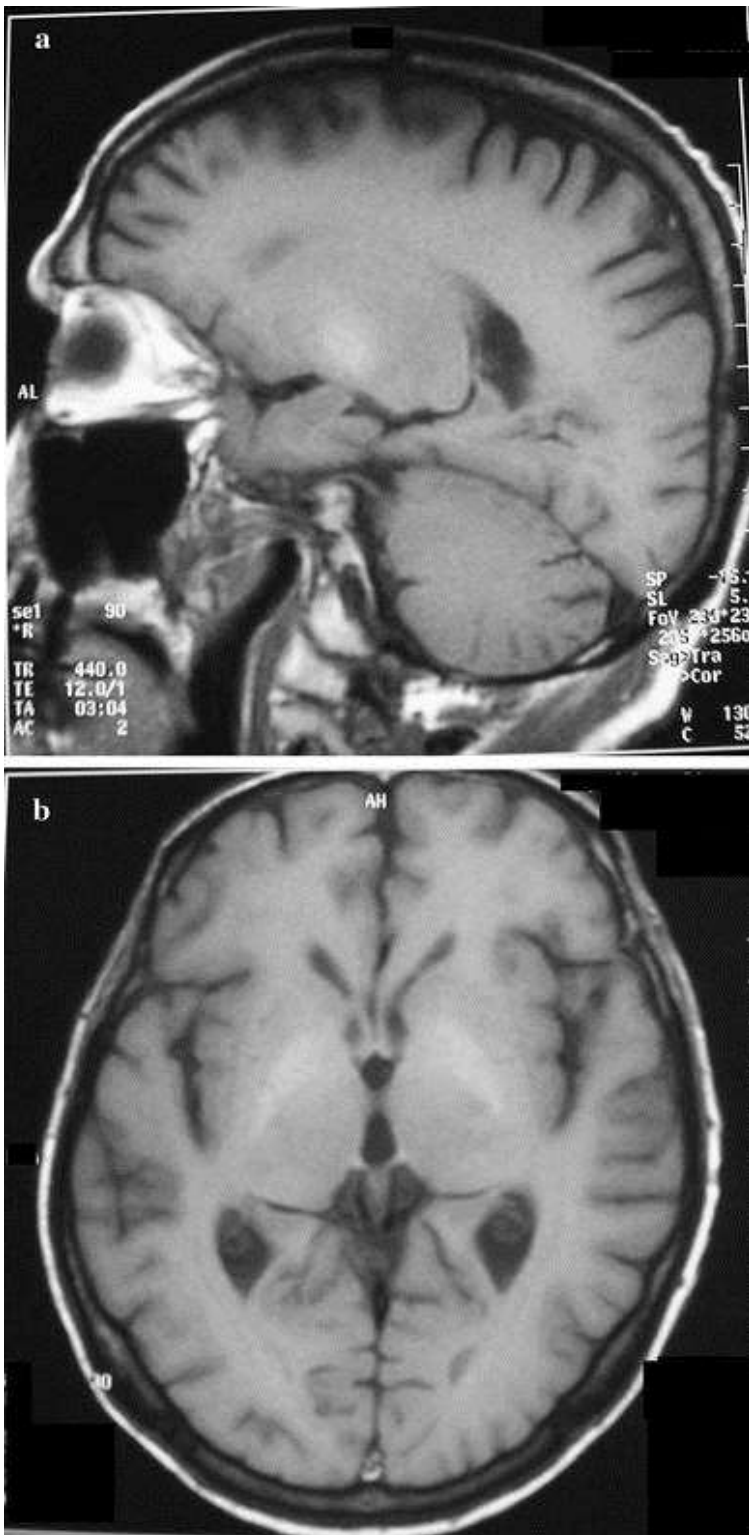


Fig 1. T1-weighted images of brain MRI showing bilateral pallidal hyperintensity in Patient 10; **a** sagittal image, **b** axial image.

The cause of cirrhosis was viral hepatitis in 18 patients (HBV 3 patients, HCV 14 patients, and HBV + HCV 1 patient) and was associated with alcohol abuse in 9 patients. Three patients had alcohol-related cirrhosis, three patients had cryptogenic cirrhosis, one patient had primitive biliary cirrhosis, and one patient had fulminant hepatitis due to ingestion of poisonous mushrooms. Seventeen out of

the 26 patients underwent OLT. The transplanted patients (13 males and 4 females) had a median age of 57 years at the time of OLT (range 43±73 years). Eight out of the 17 patients had experienced episodes of acute hepatic encephalopathy (HE) at some time during their illness before OLT. Nine patients (6 males and 3 females) did not undergo OLT. Median age was 54 years and the age range 52±73 years. Episodic acute hepatic encephalopathy occurred in six patients (see Tables 1, 3).

Table 1. Clinical features of seven cirrhotic patients with CAHD.

Patient	Age (years)	Sex	Cause of cirrhosis	HE	OLT	Symptoms or signs of CAHD
4	59	M	HCV	Yes	Yes	Rigidity Bradykinesia
11	64	M	HCV and alcohol abuse	No	Yes	Postural tremor Rigidity Bradykinesia
23	48	M	HCV	Yes	No	Resting tremor Postural tremor Rigidity Bradykinesia
26	69	M	Alcohol abuse	Yes	No	Resting tremor Postural tremor Rigidity Facial amimia Oscillation reduction
1	73	M	HBV	No	Yes	Resting tremor Postural tremor Rigidity Bradykinesia Facial amimia Oscillation reduction Camptocormia Small steps walk Gait disturbance
2	63	M	HCV	Yes	Yes	Bradykinesia Facial amimia Oscillation reduction
15	61	M	HBV and HCV	No	Yes	Postural tremor Rigidity Bradykinesia Facial amimia

HE episodes of acute hepatic encephalopathy

CAHD

Seven out of 26 patients had signs and symptoms of CAHD (Table 1). The scores of symptoms and signs are shown in Table 2. The most frequent signs were bradykinesia and rigidity, followed by tremor and facial amimia; ataxia was not observed in any of the patients. Mental slowness was also noted; none of the patients were demented.

Table 2. Patients with CAHD: scores of signs.

Patient	11	4	1	2	15	23	26
OLT	Yes	Yes	Yes ^a	Yes ^a	Yes ^a	No	No
Symmetry/asymmetry of extrapyramidal signs	L = R	L < R	L > R	L = R	R = L	R > L	R = L
Resting tremor	0	0	2	0	0	2	1
Postural tremor	1	0	2	0	2	2	1
Rigidity	2	2	2	0	2	2	2
Bradykinesia	2	1	2	2	2	2	0
Facial amimia	0	0	2	2	2	0	2
Oscillation reduction	0	0	2	2	0	0	2
Camptocormia	0	0	2	0	0	0	0
Small steps walk	0	0	2	0	0	0	0
Dysarthria	0	0	0	0	0	0	0
Ataxia	0	0	0	0	0	0	0
Dystonia	0	0	0	0	0	0	0
Gait disturbance (0±1) ^b	0	0	1	0	0	0	1
Falls (0±1) ^b	0	0	1	1	0	1	0
Total	5/35	3/35	18/35	7/35	8/35	9/35	9/35

^aCAHD presenting after OLT. *L* left, *R* right. 0 = absent; 1 = mild; 2 = moderate; 3 = severe; (maximum global impairment = 35)

^b0 = absent, 1 = present

Two patients with CAHD subsequently received a liver transplantation and the resolution of the signs and symptoms was recorded after OLT. Two patients with CADH did not undergo OLT. The two transplanted patients had moderately lower neurological scores before OLT than the others: 3±5/35 versus 9/35 and they were asymptomatic after OLT (Table 2).

In three patients, the signs and symptoms of CAHD (score 7/35, 8/35, and 18/35), and concomitant pallidal T1 hyperintensities presented at a variable time distance after OLT (37±103 months); the pallidal signal was not visible in their pre-OLT brain MRI. Only 1 out of 3 was reported to have dysfunction of the transplanted liver concomitant with the presentation of CAHD and the MRI signal.

In the other 19 patients, neither signs nor symptoms associated with CAHD were found along the time period to follow-up (7 ± 69 months, median 18 months). The characteristics of the 19 patients with T1-weighted pallidal signal and without CAHD are shown in Table 3.

Table 3. Clinical features of 19 cirrhotic patients without CAHD.

Patient	Age (years)	Sex	Cause of cirrhosis	HE	OLT	Symptoms or signs of CAHD
3	60	M	Cryptogenic	No	Yes	No
5	46	F	HCV and alcohol abuse	Yes	Yes	No
6	54	F	HCV and alcohol abuse	Yes	Yes	No
7	58	M	HCV and alcohol abuse	No	Yes	No
8	68	F	Primary biliary cirrhosis	No	Yes	No
9	48	M	HCV and alcohol abuse	No	Yes	No
10	71	M	HCV	Yes	Yes	No
12	61	M	HBV	No	Yes	No
13	45	M	HCV and alcohol abuse	Yes	Yes	No
14	56	M	HCV	Yes	Yes	No
16	50	M	HCV and alcohol abuse	No	Yes	No
17	43	F	Fulminant hepatitis	Yes	Yes	No
18	54	F	Cryptogenic	No	No	No
19	73	F	Cryptogenic	Yes	No	No
20	58	M	HCV	No	No	No
21	52	M	Alcohol abuse	No	No	No
22	53	M	HCV and alcohol abuse	Yes	No	No
24	55	F	Alcohol abuse	Yes	No	No
25	47	M	HBV and alcohol abuse	Yes	No	No

HE episodes of acute hepatic encephalopathy

Semiquantitative analysis of signal intensity in relation to CAHD and OLT

The intensity of the MRI signal in the 26 patients is shown in Table 4. In the seven patients with ~~8~~ transplanted patients, the signal intensity before 2/7 ~~UD~~ ~~Q~~ ~~H~~ ~~G~~ ~~I~~ ~~U~~ ~~R~~ ~~P~~ ~~Y~~ ~~L~~ ~~V~~ ~~L~~ ~~E~~ ~~O~~ ~~H~~ ~~W~~ ~~R~~ ~~Y~~ ~~H~~ ~~U~~ ~~L~~ ~~Q~~ ~~H~~ ~~Q~~ ~~H~~ ~~7~~ ~~D~~ ~~E~~ ~~O~~ ~~H~~ After OLT, the pallidal signal disappeared in 8 out of 13 patients (see an example in Fig. 2). In five transplanted patients, the MRI signal was still visible at the last follow-up (Table 5).

Table 4. Intensity of MRI T1 pallidal signal in 26 patients.

Patient	Signal intensity before OLT	Signal intensity after OLT	Signs and symptoms of CAHD
4	++	±	Yes
11	++	±	Yes
23	+	No OLT	Yes
26	+	+	Yes ^a
1	±	+	Yes ^a
2	±	+	Yes ^a
15	±	No OLT	Yes
8	++	±	No
9	+++	±	No
10	++	±	No
5	++	±	No
6	+	±	No
7	+	±	No
12	++	++	No
13	++	++	No
14	++	++	No
3	+	+	No
16	+	+	No
17	±	++	No
18	++	No OLT	No
19	+++	No OLT	No
20	++	No OLT	No
21	+	No OLT	No
22	+	No OLT	No
24	+	No OLT	No
25	+	No OLT	No

í = absent; + = visible; ++ = intense; +++ = very intense

^aCAHD presenting after OLT

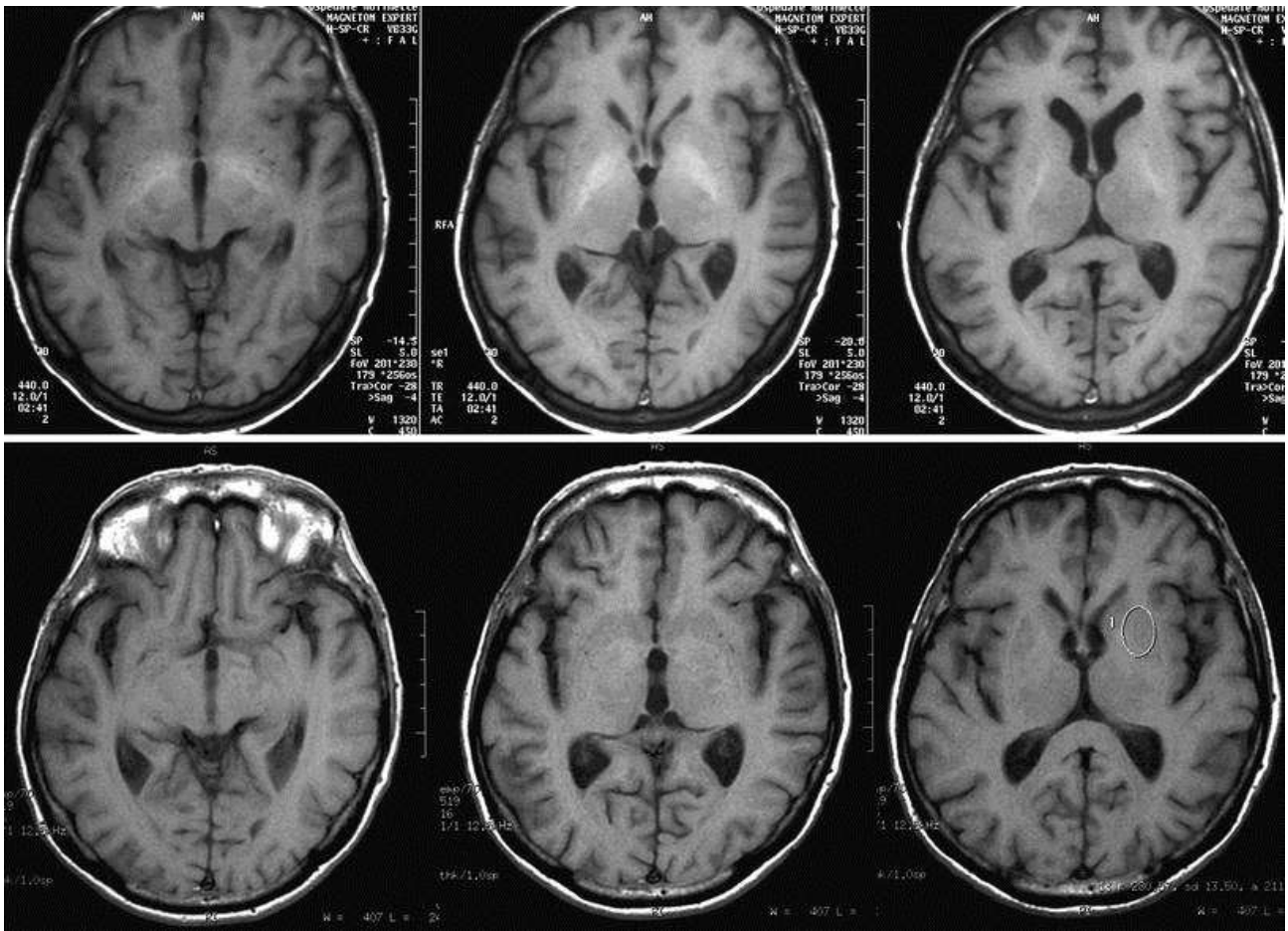


Fig 2. T1-weighted brain MRI of Patient 4, before OLT (*upper images*), and 9 months after OLT (*lower images*).

Table 5. Time of disappearance of CAHD and/or pallidal MRI signal in the patients who underwent OLT.

Patient	4	11	8	9	10	5	6	7	12	13	14	3	16
Resolution of signal after OLT	Yes	Yes	Yes	Yes	Yes	Yes	Yes	Yes	No	No	No	No	No
Time of resolution of signal after OLT (months)	9	29	78	13	78	24	15	55	±	±	±	±	±
CAHD before OLT	Yes	Yes	No	No	No	No	No	No	No	No	No	No	No
Time of resolution of CAHD after OLT (months)	9	17	±	±	±	±	±	±	±	±	±	±	±
Follow-up time longer than 24 months	Yes	Yes	Yes	Yes	Yes	Yes	Yes	Yes	No	No	No	No	No

Analysis of time intervals between the MRI signal, CAHD and OLT

In all the patients, a temporal overlap of the appearance of the MRI signal and presentation of CAHD before OLT was recorded. In the three patients with CAHD presenting after OLT, the pallidal T1 hyperintensity presented at the same time as the neurological manifestations of CAHD.

The time of resolution of CAHD and/or pallidal signal after OLT is shown in Table 5. The neurological manifestations improved at 9 and 17 months after OLT, concomitant with, or earlier than the pallidal signal.

In the six transplanted patients without CAHD, the pallidal signal disappeared 13 ± 78 months after OLT (median 24 months). The follow-up time of the five patients with a persisting pallidal signal after OLT was shorter than 24 months (Table 5).

Neuropsychological status and MRI signal

Nine patients received a structured neuropsychological assessment (Table 6). Seven patients (10, 4, 6, 9, 5, 7, 8) belonged to the subgroup in which the MRI signal had disappeared after OLT and were tested after OLT. Patient 4 had CAHD before OLT. Two patients (1 and 19) had the MRI signal at the time of neuropsychological assessment; patient 1 had CAHD.

Table 6. Neuropsychological evaluation of nine patients.

Patient	MMSE (≥ 23.8)	Phonological fluency (≥ 17.2)	Semantic fluency (≥ 24)	Span (≥ 3.5)	Matrices (≥ 31)	TMT A (≤ 93)	TMT B (≤ 282)	Raven (≥ 18.9)	FAB (≥ 13.4)	Story recall (IR + DR) (≥ 4.75)	Rey figure (copy) (≥ 28.87)	Rey figure (recall) (≥ 9.46)	Stroop W 10 ± 3	Stroop C 10 ± 3	Stroop CW 10 ± 3	HADS (< 16)
10	27.85	39.5	52	5.75	47	33	59	29	17.4	6.9	35.5	15	//	//	//	25
4	27.97	37.5	60	3.75	52	27	47	26	17.3	9.05	34	18	14	8	8	16
19	30	31	48	5.5	35	64	181	19	12.3	13.2	31.5	6.25	7	4	4	23
6	29.97	28	45	4.75	27	64	87	31	15.1	12.3	32.5	11	9	7	3	18
9	29.62	35	54	5.5	47	28	140	26	15.9	11.65	34.75	8.25	10	2	6	6
1	26.03	23	29	//	20	//	//	//	10.3	6.8	9.5	4.25	//	//	//	16
5	27.62	19	42	3.5	49	28	123	21	13.9	12.55	21.25	0	3	4	8	20
7	29.97	35	40	4.75	57	38	135	27	15.3	12.65	27	15	9	5	3	10
8	29.49	42	59	5.75	35	34	13	33	16.9	13.1	35	20.75	//	//	//	15

// = test unperformed

All patients had minor impairment in the attentional domains; Patients 1 and 19 showed a greater impairment in both attentional and executive domains than the other patients.

Mn levels in blood and MRI signal

The blood levels of Mn were analyzed in 12 patients. The values ranged from 0.46 to 2.34 g/L and were within the normal range (Table 7).

Table 7. Blood level of manganese in 12 patients.

Patient	Blood levels of manganese (µg/L)	CAHD*	MRI Signal*
1	2.34	Yes	+
2	1.14	Yes	+
6	0.46	No	±
11	0.56	No	±
8	0.59	No	±
4	0.75	No	±
5	0.82	No	±
16	1.04	No	+
7	1.17	No	±
10	1.59	No	±
9	1.78	No	±
19	1.24	No	+

Normal range of manganese blood levels: 0.43 ± 2.86 g/L

*At the time of Mn analysis

At the time of Mn analysis, two patients had CAHD and the pallidal signal, two patients had the pallidal signal and no symptoms of CAHD, and eight patients had no pallidal signal.

Discussion

Determining the association of pallidal T1 hyperintensity with CAHD, blood levels of Mn and OLT over a long follow-up time in a large series of cirrhotic patients has not yet been reported.

Although a statistical analysis of the results is not reliable in such a small number of patients, some conclusions can be drawn. The hyperintense pallidal MRI signal is a necessary prerequisite for the clinical manifestations of CAHD, but it is not sufficient. The MRI pallidal signal is not predictive

of CAHD. The liver transplantation attenuates and, in the long run, cancels the MRI signal and can be beneficial in CAHD. The blood levels of Mn, as routinely assessed, do not reflect the MRI signal or the neurological sequelae of CAHD. The MRI signal can correspond to an isolated minor impairment of frontal executive functions when specifically tested.

These observations in a large series confirm the observations that were previously reported in isolated few patients (9±14) and can be of help in the clinical evaluation of candidate to OLT.

In our study, the prevalence of CAHD within the group of patients with a pallidal signal in a brain MRI is 26 %. This value is lower than the prevalence reported in a series of differently recruited liver patients, which was 43 % [9]. In both reports, a large subgroup of patients with a typical MRI signal does not have CAHD.

It is believed that Mn accumulation in the basal ganglia is responsible for the MRI signal [16, 18, 19]. The portosystemic shunting in cirrhotic patients may be responsible of this accumulation, by increasing the exposure of brain tissue to Mn. What is unknown is whether the pallidal T1 hyperintensity indicates intoxication or is an adaptive process of detoxification of ammonium by astrocytes [16]. However, evidence directly linking Mn with neurological symptoms in cirrhotic patients is scarce [18, 19]. Our results do not support a direct link.

On one end, the temporal overlap between the presence of signal and CAHD in the present series of patients confirms the link between Mn in the basal ganglia and CAHD. On the other end, the persistence of the neuroimaging abnormality in patients for several months after OLT as well as in non-transplanted patients, which is not accompanied by presence of neurological symptoms and signs, shows that the pallidal hyperintensity neither warrants nor predicts CAHD. The cause of cirrhosis, episodes of acute hepatic encephalopathy and intensity of the signal do not appear to be factors promoting the development of CAHD in our series of patients.

The pathogenesis of CADH still has some unknown components, even if Mn in the basal ganglia is involved [13]. Liver failure seems to be directly responsible for both Mn accumulation and the MRI signal: CAHD has not been reported in the absence of the MRI T1 pallidal signal. Liver transplantation is effective in attenuating or eliminating CAHD, as previously reported [11]. Cirrhosis is therefore involved in the pathogenesis of CAHD via Mn accumulation in the basal ganglia [5], but additional undefined events lead to an overt CAHD. The recurrence of CAHD after OLT and the occurrence of a novel CAHD after OLT are very rare [13, 20]. In the present study, three patients with a novel CAHD after OLT were observed, confirming this new condition. The failure of the transplanted organ may be responsible, even if no severe synthetic dysfunction of the graft is demonstrated.

From a practical point of view, our study confirms the futility of using serum Mn levels as an index of the Mn body burden and accumulation in the basal ganglia, as already suggested [5, 18]. Mn blood levels do not predict the presence of a neurological disease [18]. What is notable is that technical bias may interfere. While blood Mn levels correlate with signal intensity [18], the plasma Mn concentration does not correlate with the signal intensity on the T1-weighted MRI in patients with cirrhosis [6]. Therefore, the utility of a low Mn diet for patients with chronic liver failure for the prevention of CAHD is not supported.

Acknowledgments

The authors thank Mario Coriasco for his technical help.

References

1. Klos KJ, Ahlskog JE, Josephs KA et al (2005) Neurologic spectrum of chronic liver failure and basal ganglia T1 hyperintensity on magnetic resonance imaging: probable manganese neurotoxicity. *Arch Neurol* **62**:1385±1390.
2. Pinarbasi B, Kaymakoglu S, Matur Z et al (2009) Are acquired hepatocerebral degeneration and hepatic myelopathy reversible? *J Clin Gastroenterol* **43**:176±181.
3. Lee J, Lacomis D, Comu S et al (1998) Acquired hepatocerebral degeneration: MR and pathologic findings. *Am J Neuroradiol* **19**:485±487.
4. Ferrara J, Jankovic J (2009) Acquired hepatocerebral degeneration. *J Neurol* **256**:320±322.
5. Klos KJ, Ahlskog JE, Kumar N et al (2006) Brain metal concentrations in chronic liver failure patients with pallidal T1 MRI hyperintensity. *Neurology* **67**:1984±1989.
6. Park NH, Park JK, Choi Y et al (2003) Blood manganese correlates with high signal intensities in T1-weighted MRI in patients with liver cirrhosis. *NeuroToxicology* **24**:909±915.
7. Dastur DK, Mangahania DK, Raghavendran KV (1968) Distribution and fate of Mn in the monkey: studies of different parts of the central nervous system and other organs. *J Clin Invest* **50**:9±20.
8. Olanow CW (2004) Manganese-LQXFHG3DUNLQRQVDPQ3DUNLQRQGLVHDDWH *Acad Sci* **1012**:209±223.
9. Long LL, Li XR, Huang ZK et al (2009) Relationship between changes in brain MRI and ¹H-MRS, severity of chronic liver damage, and recovery after liver transplantation. *Exp Biol Med* **234**:1075±1085.
10. Stracciari A, Guarino M, Pazzaglia P et al (2001) Acquired hepatocerebral degeneration: full recovery after liver transplantation. *J Neurol Neurosurg Psychiatry* **70**:136±137.
11. Stracciari A, Baldin E, Cretella L et al (2011) Chronic acquired hepatocerebral degeneration: effects of liver transplantation on neurological manifestations. *Neurol Sci* **32**:411±415.
12. Powell EE, Pender MP, Chalk JB et al (1990) Improvement in chronic hepatocerebral degeneration following liver transplantation. *Gastroenterology* **98**:1079±1082.
13. Servin-Abad L, Tzakis A, Schiff ER, Regev A (2006) Acquired hepatocerebral degeneration in a patient with HCV cirrhosis: complete resolution with subsequent recurrence after liver transplantation. *Liver Transpl.* **7**:1161±1165.
14. Shulmann LM, Minagar A, Weiner WJ (2003) Reversal of parkinsonism following liver transplantation. *Neurology* **60**:519.
15. Mattarozzi K, Stracciari A, Vignatelli L et al (2004) Minimal hepatic encephalopathy: longitudinal effects of liver transplantation. *Arch Neurol* **61**:242±247.
16. Krieger D, Krieger S, Theilmann L et al (1995) Manganese and chronic hepatic encephalopathy. *Lancet* **346**:270±274.
17. Francois B, Oliver G, Josiane A, Francis P (1988) Determination of manganese in biological material by electrothermal atomic absorption spectrometry: a review. *Clin Chem* **34**:227±234.
18. Spahr L, Butterworth RF, Fontaine S et al (1996) Increased blood manganese in cirrhotic patients: relationship to pallidal magnetic resonance signal hyperintensity and neurological symptoms. *Hepatology* **24**:1116±1120.
19. Krieger S, Jauss M, Jansen O et al (1996) Neuropsychiatric profile and hyperintense globus pallidus on T1-weighted magnetic resonance images in liver cirrhosis. *Gastroenterology* **111**:147±155.
20. Papapetropoulos S, Singer C (2005) Management of the extrapyramidal syndrome in chronic acquired hepatocerebral degeneration (CAHD). *Mov Disord* **20**:088±1089.