

# Ultrasound imaging for the rheumatologist

## IX. Ultrasound imaging in spondyloarthritis

L. Riente<sup>1</sup>, A. Delle Sedie<sup>1</sup>, E. Filippucci<sup>2</sup>, A. Iagnocco<sup>3</sup>, G. Meenagh<sup>4</sup>,  
W. Grassi<sup>2</sup>, G. Valesini<sup>3</sup>, S. Bombardieri<sup>1</sup>

<sup>1</sup>Unità Operativa di Reumatologia, Università di Pisa, Pisa, Italy.

<sup>2</sup>Cattedra di Reumatologia, Università Politecnica delle Marche, Jesi, Italy;

<sup>3</sup>Cattedra di Reumatologia, Sapienza Università di Roma, Roma, Italy;

<sup>4</sup>Department of Rheumatology, Weston General Hospital, Weston-super-Mare, Bristol, UK.

Lucrezia Riente, MD; Andrea Delle Sedie, MD; Emilio Filippucci, MD; Annamaria Iagnocco, MD; Gary Meenagh, MD; Walter Grassi, MD, Professor of Rheumatology; Guido Valesini, MD, Professor of Rheumatology; Stefano Bombardieri, MD, Professor of Rheumatology.

Please address correspondence to:  
Dr. Lucrezia Riente, U.O. Reumatologia, Dipartimento di Medicina Interna, Università di Pisa, Via Roma 67, Pisa 56126, Italy.

E-mail address: l.riente@int.med.unipi.it

Received on May 18, 2007; accepted on May 22, 2007.

Clin Exp Rheumatol 2007; 25: 349-353.

© Copyright CLINICAL AND EXPERIMENTAL RHEUMATOLOGY 2007.

**Key words:** Ultrasonography, spondyloarthritis, enthesitis, dactylitis, synovitis, tenosynovitis.

### ABSTRACT

*Musculoskeletal ultrasound (US) has an increasingly important role in the assessment of spondyloarthritis (SpA) not only for its ability to detect synovial and tendon involvement but also for the accurate imaging of enthesitis, the clinical hallmark feature of SpA. As already known, most cases of enthesitis are subclinical in SpA and US is an effective technique used to detect them. Also, in cases of dactylitis, US can accurately delineate the underlying pathology. US allows clinicians to guide needle positioning within inflamed joints, tendon sheaths and entheses in order to inject steroids or other drugs. This is particularly important for patients with SpA, because of the frequency of mono or oligoarthritis, tendon and enthesal involvement, who may have great benefit from intrarticular or intralesional therapy.*

*The clinical application of US in SpA extends to the monitoring of therapy efficacy, particularly when coupled with power Doppler imaging. Very slight changes in vascularity are easily detected in joints, entheses or tendons, aiding the rheumatologist in the assessment of the effects of local or systemic therapies.*

*The present review provides an update of the available data and discusses research issues of US imaging in SpA.*

### Introduction

Spondyloarthropathies (SpA) are diseases characterized by inflammation of enthesal insertions and synovium. Typical pathological changes are present in the sacroiliac, spinal and peripheral joints. Ankylosing spondylitis (AS), psoriatic arthritis (PsA), reactive arthritis (ReA), arthritis associated with inflammatory bowel disease and

undifferentiated spondyloarthropathy (uSpA) are the principal clinical subtypes described. Correctly identifying synovitis, tendonitis/tenosynovitis and enthesopathy together with the exclusion of differential diagnoses may be difficult by clinical examination and plain radiograph alone in this setting. Access to Magnetic Resonance Imaging (MRI) or Computed Tomography (CT) is often restricted because of high costs and restricted availability. Musculoskeletal ultrasound (US) has an increasingly important role in the assessment of SpA for its ability not only to detect synovial and tendon involvement but also for the accurate imaging of enthesitis, the clinical hallmark feature of SpA (1-4). In the last decade, a great number of papers regarding the role of US in SpA have been published. In this review we provide an overview of the available data and discuss the research agenda of US in this group of disorders.

### Clinical applications

In patients affected by SpA, an experienced sonographer can visualise joint effusion, even when clinical examination fails, hyperplasia of the synovium, bone erosions, tendonitis, tenosynovitis, tendon tears, enthesitis and bursitis (5-8). Power Doppler sonography (PDS) provides information on the perfusion of the synovial tissue, tendon and entheses (9-11).

Plantar fasciitis is a common cause of foot pain in patients with SpA and thickening, hypoechogenicity and surrounding oedema can be detected by US (12). In cases of dactylitis, characterized by a diffuse painful swelling of the fingers and toes, US can accurately delineate the underlying pathology (13, 14).

It is well-known that US allows cli-

Competing interests: none declared.

nicians to guide needle positioning within inflamed joints, tendon sheaths and entheses to inject steroids or other drugs (15, 16). This is particularly important for patients with SpA, because of the frequency of mono or oligoarthritis, tendon and enthesal involvement, who may have great benefit from intrarticular or intralesional (i.e. in tenosynovitis) therapy. It is important to remember that blinded puncture based upon clinical examination often results in therapeutic failure (17).

The clinical application of US in SpA extends to the monitoring of therapy efficacy, particularly when coupled with PDS imaging (18, 19). In recent years, PDS technique has improved greatly so that even very slight changes in vascularity are easily detected in joints, entheses or tendons aiding the rheumatologist in the assessment of the effects of local or systemic therapies.

### Sonographic findings

#### Joints

In patients with SpA, effusion and synovial proliferation in peripheral joints can easily be imaged. PDS provides further useful information regarding the degree of inflammatory activity (2, 7). The detection of bone erosions can help to differentiate erosive from non-erosive disease, thus distinguishing subtypes of SpA even in early phases of the disease. Sacroiliitis can be imaged with color Doppler (CD) and contrast-enhanced CD US whilst spinal inflammation is best visualised with CD US (20-23).

#### Tendons

US can detect tenosynovitis in SpA, particularly in the ankle region. US examination has demonstrated marked involvement of the posterior tibialis and peroneal synovial sheaths in a large number of subjects with PsA even those who were asymptomatic (5). Dactylitis or "sausage-like" digits may be present in all forms of SpA, although more frequently observed in PsA. US examination in both finger and toe dactylitis can show flexor tenosynovitis often associated with arthritis of interphalangeal and metacarpo-phalangeal joints and marked adjacent soft tissue swelling

(13, 14). Tendonitis, paratendonitis and even tears of the Achilles tendon as well as plantar fasciitis and bursitis can be frequently imaged in all types of SpA.

#### Enthesal insertions

Enthesitis, i.e. the inflammation of the insertions of tendons, ligaments, aponeuroses and joint capsules on bones, is a common feature of all types of SpA. US can detect signs of enthesitis in SpA patients most commonly in the lower limbs (4, 6, 24) but also at other more unusual locations e.g. proximal insertion of the deltoid (25). PDS adds further information about the degree of vascularization of the involved entheses. A quantitative US score, the Glasgow Ultrasound Enthesitis Scoring System (GUESS), of lower limb enthesitis has been proposed by Balint *et al.* (4). The superior pole of the patella (quadriceps tendon insertion), the inferior pole of the patella (patellar ligament origin), the patellar ligament insertion at the tibial tuberosity, the Achilles tendon and the plantar aponeuroses are examined in both lower limbs. US assessment of structural thickness, presence of bony erosions, enthesophytes and bursitis are evaluated at each site, scoring one point for each abnormality at each site examined.

US findings in joints, tendons and entheses in SpA patients are summarized in Table I.

### Literature review

Enthesal inflammation is considered the primary lesion in SpA, thus US evaluation of this entity has been the subject of many studies. In 2002 Balint *et al.* (4) compared US with clinical examination in the detection of enthesopathies in the lower limbs of 27 patients with AS, 7 with PsA, 1 with ReA. By using the US score of lower limb enthesitis (GUESS score), they concluded that most cases of enthesitis are subclinical in SpA and that US is an effective technique used to detect them. This has been confirmed by other authors including Lehtinen *et al.* (26). In 2000 Galluzzo *et al.* (5) studied ankle involvement in 31 patients with PsA using US and discovered pathological findings at both enthesal and tendon level in a high proportion of subjects, most of whom exhibited no ankle pain or swelling. Subclinical enthesitis has also been described in the quadriceps tendon in a group of patients with PsA (24). Recently enthesal involvement in the foot was evaluated by US in 44 subjects with SpA (19 with AS, 5 with PsA, 8 with ReA and 12 with uSpA) (6). Pathological findings were disclosed in 25 patients, most of whom did not complain of foot symptoms. A comparison of tendon and enthesal involvement in SpA and rheumatoid arthritis (RA) failed to detect a statistically significant difference in the preva-

**Table I.** Ultrasound (US) findings in spondyloarthritis.

Anatomic structures	US findings
Joint	<ul style="list-style-type: none"> <li>a) Effusion: anechoic or hypoechoic intra-capsular collection which bows the capsule.</li> <li>b) Synovitis: echogenic tissue proliferating within the joint cavity which can show PDS signal.</li> <li>c) Bone erosions: an interruption of the bone surface visible in two planes.</li> </ul>
Tendon	<ul style="list-style-type: none"> <li>a) Tenosynovitis: anechoic or hypoechoic halo around the tendon; in chronic tenosynovitis non-homogeneous or even hyperechoic material (synovial tissue hyperplasia) may be observed within the distended sheath. Increased vascularity may be visualized with PDS.</li> <li>b) Tendinitis/tendinosis: swelling of the tendon with loss of the normal fibrillar pattern and areas of decreased echogenicity.</li> <li>c) Tendon rupture: hypoechoic gap in the body of the tendon in partial tear, full-thickness discontinuity in complete tear.</li> </ul>
Enthesis	Enthesitis: loss of normal fibrillar echogenicity, increasing thickness or intralesional focal changes of tendon insertion, calcific deposits at insertion of the tendon, periosteal changes (erosions or new bone formation).

**Table II.** Ultrasound imaging in spondyloarthritis: research agenda.

To develop international consensus on scanning protocol.
To develop international consensus on scoring systems for assessing enthesitis, synovitis in small and large joints, tenosynovitis, bone erosions.
To evaluate the role of ultrasound with power Doppler in the assessment of disease activity, in particular in the assessment of enthesopathy.
To investigate the potential of 3D ultrasound with the volumetric probe.

lence of US pathology and showed that the most frequently affected enthesal sites in the lower limbs were the same (suprapatellar, infrapatellar and Achilles tendon) (27).

D'Agostino *et al.* (28) assessed the prevalence and severity of peripheral enthesitis using US combined with PDS in a large group of SpA patients. Using a 5-point classification of US enthesitis graded according to different combinations of abnormal gray-scale and PDS signal, they found evidence of enthesitis at one site in 98% of patients with 81% of cases demonstrating abnormal vascularization localized near the cortical bone. The number of abnormal entheses imaged by US was significantly

higher than those detected by clinical examination.

Enthesitis has been detected at the proximal insertion of the deltoid, clinically mimicking impingement syndrome in 9% of a large group of patients with SpA (25).

Degenerative-atrophic changes of the heel fat pad frequently associated with abnormalities of the plantar fascia and of its entheses have been observed in SpA (29). Plantar fasciitis has been detected in 37% of patients with PsA (30).

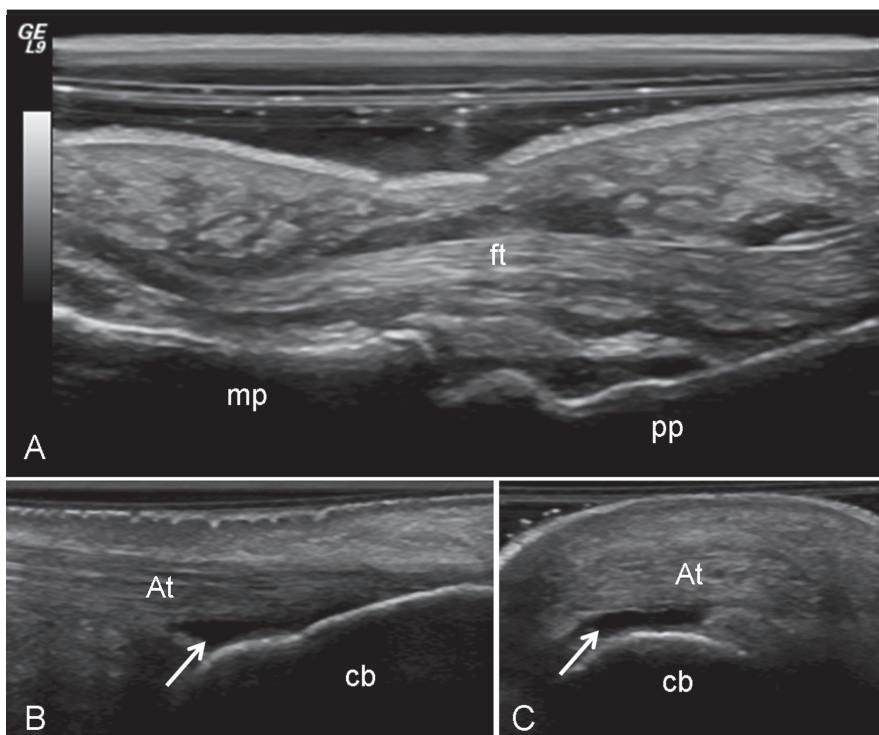
US with PDS has also been used in therapy monitoring and has documented a positive response to anti-TNF- $\alpha$  therapy for refractory inflammatory

heel pain in 2 patients with SpA and for knee arthritis in 8 patients with PsA (18, 19).

US is one of the methods of choice for the evaluation dactylitis or "sausage digit". Sonographic examination has shown evidence of flexor tenosynovitis with coexistent adjacent soft tissue swelling, while joint synovitis was observed in 17-62% of patients (13).

Conflicting data exist regarding the extrasynovial abnormalities detectable by US in the fingers of patients with PsA and particularly the presence of enthesopathy at the site of deep flexor tendon insertion on the distal phalanx. Fourniè *et al.* showed capsular enthesophyte, iuxtaarticular periosteal reaction, enthesopathy at the site of deep flexor tendon insertion on the distal phalanx and subcutaneous soft tissue thickening of the finger pad or entire finger in 25 patients with PsA (31). In four cases, pseudotenosynovitis due to diffuse inflammation of the soft tissue was discovered. Similar results were also obtained by Lalande Champetier de Ribes *et al.* (32). Grassi *et al.* have observed an abnormal signal at the site of flexor tendon attachment (33) whilst Kane *et al.* (14) and Olivieri *et al.* (34) did not show evidence of enthesitis in psoriatic dactylitis using US and MRI respectively.

To date, very few papers on US evaluation of the sacroiliac joints have been published. Using duplex and color Doppler (CDD) imaging, vascularization around the posterior portions of sacroiliac joints has been detected in patients with active sacroiliitis (20). Microbubble contrast-enhanced CD US has been shown to be a highly sensitive technique for the detection of active sacroiliitis compared with MRI in a group of 103 patients with inflammatory low back pain (21). More recently, CDD US of sacroiliac joints, thoracolumbar and paraspinal areas was performed in 39 patients affected by AS; 11 of the 39 patients were examined before and after 12 weeks of anti TNF- $\alpha$  therapy. Vascularization was increased in patients with active disease compared to controls and significantly lowered after anti TNF- $\alpha$  therapy. The authors suggested that CDD US might



**Fig. 1.** Psoriatic arthritis. A. Dactylitis. Longitudinal volar scan of the proximal interphalangeal joint showing a wide spectrum of pathological changes explaining the clinical picture: synovitis of the proximal interphalangeal joint; tenosynovitis of the finger flexor tendon (ft) and edema of the subcutaneous tissue. B-C. Retrocalcanal bursitis (arrow). Moderate anechoic enlargement of the retrocalcanal bursa detectable both on longitudinal (B) and transverse (C) scans. mp = middle phalanx; pp = proximal phalanx; cb = calcaneal bone; At = Achilles' tendon.

For further ultrasound images, go to [www.clinexprheumatol.org/ultrasound](http://www.clinexprheumatol.org/ultrasound)



be an alternative to MRI in order to evaluate response to therapy (22).

### Research agenda

The applications of US in SpA present the same limitations reported for its use in RA and other arthritides. These limitations need to be considered by the researcher as the main priorities to be resolved.

In Table II we report the principle questions still to be addressed.

It is well established that the reliability of US examination depends on the operator's experience and expertise and this is one of the limits of this imaging tool. The fact that US is an operator-dependent technique is, in part, due also to the lack of a standardized scanning protocol. The recent introduction of 3-D imaging is a particular interesting innovation which will help in the acquisition of images of very high quality. The interest in this new technique relies not solely on the amazing features of the images, but also on its operator-independence - unlike "classical" sonography.

In SpA sonographic analysis is performed at different anatomical sites: small and large joints, superficial entheses and deeper tendons. This requires the use of probes which permit the correct visualization of such different structures.

The OMERACT special interest group on US is currently developing a comprehensive approach for scoring both synovitis and bone erosions in the small joints of patients with RA. A reliable method for scoring synovitis in both small and large joints (i.e. ankle or knee), frequently involved in SpA, is still lacking.

PDS is a very useful tool in the assessment of SpA showing not only the vascularization of synovial tissue but also the degree of inflammation at the entheses and the changes in signal after local or systemic therapy. The lack of standardization of the procedure, however, may lead to inter and intra-observer variability and difficulties in quantifying PDS signal could prevent recognition of the real degree of hyperemia and therapy monitoring, i.e. in longitudinal studies. Intravenous

microbubble echo-contrast agents increase the sensitivity of the PDS and may help in the detection of inflamed entheses and synovium but due to high costs their use is still limited.

All these problems require addressing in the near future and great efforts are necessary on the part of the researchers who work in the field of US to provide answers as soon as possible.

### Link

For further ultrasound images, go to [www.clinexprheumatol.org/ultrasound](http://www.clinexprheumatol.org/ultrasound)

### References

- KANE D, GRASSI W, STURROCK R, BALINT PV: Musculoskeletal ultrasound-a state of the art review in rheumatology. Part 2: Clinical indications for musculoskeletal ultrasound in rheumatology. *Rheumatology* 2004; 43: 829-38.
- FILIPPUCCI E, IAGNOCCO A, MEENAGH G *et al.*: Ultrasound imaging for the rheumatologist. *Clin Exp Rheumatol* 2006; 24: 1-5.
- D'AGOSTINO MA, OLIVIERI I: Enthesitis. *Best Pract Res Clin Rheumatol* 2006; 20: 473-86.
- BALINT PV, KANE D, WILSON H, MCINNES IB, STURROCK RD: Ultrasonography of enthesal insertions in the lower limb in spondyloarthropathy. *Ann Rheum Dis* 2002; 61: 905-10.
- GALLUZZO E, LISCHI DM, TAGLIONE E *et al.*: Sonographic analysis of the ankle in patients with psoriatic arthritis. *Scand J Rheumatol* 2000; 29: 52-5.
- BORMAN P, KOPARAL S, BABAOGU S, BODUR H: Ultrasound detection of enthesal insertions in the foot of patients with spondyloarthropathy. *Clin Rheumatol* 2006; 25: 373-7.
- GRASSI W, FILIPPUCCI E: Ultrasonography and the rheumatologist. *Curr Opin Rheumatol* 2007; 19: 55-60.
- WAKEFIELD RJ, BALINT PV, SZKUDLAREK M *et al.*: OMERACT 7 Special Interest Group. Musculoskeletal ultrasound including definitions for ultrasonographic pathology. *J Rheumatol* 2005; 32: 2485-7.
- WAKEFIELD RJ, BROWN AK, O'CONNOR PJ, EMERY P: Power Doppler sonography: improving disease activity assessment in inflammatory musculoskeletal disease. *Arthritis Rheum* 2003; 48: 285-8.
- SCHMIDT WA: Technology Insight: the role of color and power Doppler ultrasonography in rheumatology. *Nat Clin Pract Rheumatol* 2007; 3: 35-42.
- GRASSI W, FILIPPUCCI E: Is power Doppler sonography the new frontier in therapy monitoring? *Clin Exp Rheumatol* 2003; 21: 424-8.
- RIENTE L, DELLE SEDIE A, IAGNOCCO A *et al.*: Ultrasound imaging for the rheumatologist V. Ultrasonography of the ankle and foot. *Clin Exp Rheumatol* 2006; 24: 493-8.
- OLIVIERI I, SCARANO E, PADULA A, GIASI V, PRIOLO F: Dactylitis, a term for different digit diseases. *Scand J Rheumatol* 2006; 35: 333-40.
- KANE D, GREANEY T, BRESNIHAN B, GIBNEY R, FITZGERALD O: Ultrasonography in the diagnosis and management of psoriatic dactylitis. *J Rheumatol* 1999; 26: 1746-51.
- GRASSI W, FARINA A, FILIPPUCCI E, CERVINI C: Sonographically guided procedures in rheumatology. *Semin Arthritis Rheum* 2001; 30: 347-53.
- RAZAK, LEE CY, PILLING D *et al.*: Ultrasound guidance allows accurate needle placement and aspiration from small joints in patients with early inflammatory arthritis. *Rheumatology* 2003; 42: 976-9.
- D'AGOSTINO M A, AYRAL X, BARON G, RAVAUD P, BREBAN M, DOUGADOS M: Impact of ultrasound imaging on local corticosteroid injections of symptomatic ankle, hind- and mid-foot in chronic inflammatory diseases. *Arthritis Rheum* 2005; 53: 284-92.
- D'AGOSTINO MA, BREBAN M, SAID-NAHAL R, DOUGADOS M: Refractory inflammatory heel pain in spondylarthropathy: a significant response to infliximab documented by ultrasound. *Arthritis Rheum* 2002; 46: 840-1.
- FIOCCO U, FERRO F, VEZZU M *et al.*: Rheumatoid and psoriatic knee synovitis: clinical, grey scale, and power Doppler ultrasound assessment of the response to etanercept. *Ann Rheum Dis* 2005; 64: 899-905.
- ARSLAN H, SAKARYA ME, ADAK B, UNAL O, SAYARLIOGLU M: Duplex and color Doppler sonographic findings in active sacroiliitis. *AJR Am J Roentgenol* 1999; 173: 677-80.
- KLAUSER A, HALPERN EJ, FRAUSCHER F *et al.*: Inflammatory low back pain: high negative predictive value of contrast-enhanced color doppler ultrasound in the detection of inflamed sacroiliac joints. *Arthritis Rheum* 2005; 53: 440-4.
- UNLU E, PAMUK ON, CAKIR N: Color and duplex Doppler sonography to detect sacroiliitis and spinal inflammation in ankylosing spondylitis. Can this method reveal response to anti-tumor necrosis factor therapy? *J Rheumatol* 2007; 34: 110-6.
- DELLE SEDIE A, RIENTE L, IAGNOCCO A *et al.*: Ultrasound imaging for the rheumatologist. VI. Ultrasonography of the elbow, sacroiliac, parasternal, and temporomandibular joints. *Clin Exp Rheumatol* 2006; 24: 617-21.
- FREDIANI B, FALSETTI P, STORRI L *et al.*: Ultrasound and clinical evaluation of quadriceps tendon enthesitis in patients with psoriatic arthritis and rheumatoid arthritis. *Clin Rheumatol* 2002; 21: 294-8.
- FALSETTI P, FREDIANI B, FILIPPOU G *et al.*: Enthesitis of proximal insertion of the deltoid in the course of seronegative spondyloarthritis. An atypical enthesitis that can mime impingement syndrome. *Scand J Rheumatol* 2002; 31: 158-62.
- LEHTINEN A, TAAVITSAINEN M, LEIRISALO-REPO: Sonographic analysis of enthesopathy in the lower extremities of patients with spondylarthropathy. *Clin Exp Rheumatol* 1994; 12: 143-8.
- GENC H, CAKIR BD, TUNCBILEK I, ERDEM HR: Ultrasonographic evaluation of tendons

- and enthesal sites in rheumatoid arthritis: comparison with ankylosing spondylitis and healthy subjects. *Clin Rheumatol* 2005; 24:272-7.
28. D'AGOSTINO MA, SAID-NAHAL R, Hacquard-Bouder C, BRASSEUR JL, DOUGADOS M, BREBAN M: Assessment of peripheral enthesitis in the spondylarthropathies by ultrasonography combined with power Doppler: a cross-sectional study. *Arthritis Rheum* 2003; 48: 523-33.
  29. FALSETTI P, FREDIANI B, ACCIAI C, BALDI F, FILIPPOU G, MARCOLONGO R: Heel fat pad involvement in rheumatoid arthritis and in spondyloarthropathies: an ultrasonographic study. *Scand J Rheumatol* 2004; 33: 327-31.
  30. FALSETTI P, FREDIANI B, FIORAVANTI A *et al.*: Sonographic study of calcaneal entheses in erosive osteoarthritis, nodal osteoarthritis, rheumatoid arthritis and psoriatic arthritis. *Scand J Rheumatol* 2003; 32: 229-34.
  31. FOURNIE B, MARGARIT-COLL N, CHAMPETIER DE RIBES TL *et al.*: Extrasynovial ultrasound abnormalities in the psoriatic finger. Prospective comparative power-doppler study versus rheumatoid arthritis. *Joint Bone Spine* 2006; 73: 527-31.
  32. LALANDE CHAMPETIER DE RIBES T, MARGARIT-COLL N, SANS N *et al.*: Ultrasound features of entesopathy in patients with psoriatic dactylitis *J Radiol* 2006; 87: 639-45.
  33. GRASSI W, FILIPPUCI E, FARINA A, CERVINI C: Sonographic imaging of the distal phalanx. *Semin Arthritis Rheum* 2000; 29: 379-84.
  34. OLIVIERI I, SALVARANI C, CANTINI F *et al.*: Fast spin echo-T2-weighted sequences with fat saturation in dactylitis of spondylarthritis. No evidence of enthesal involvement of the flexor digitorum tendons. *Arthritis Rheum* 2002; 46: 2964-7.