

AperTO - Archivio Istituzionale Open Access dell'Università di Torino

Total Anatomical Reconstruction during Robot-assisted Radical Prostatectomy: Implications on Early Recovery of Urinary Continence

This is the author's manuscript

Original Citation:

Availability:

This version is available <http://hdl.handle.net/2318/1623606> since 2017-01-30T11:29:51Z

Published version:

DOI:10.1016/j.eururo.2015.08.005

Terms of use:

Open Access

Anyone can freely access the full text of works made available as "Open Access". Works made available under a Creative Commons license can be used according to the terms and conditions of said license. Use of all other works requires consent of the right holder (author or publisher) if not exempted from copyright protection by the applicable law.

(Article begins on next page)

This Accepted Author Manuscript (AAM) is copyrighted and published by Elsevier. It is posted here by agreement between Elsevier and the University of Turin. Changes resulting from the publishing process - such as editing, corrections, structural formatting, and other quality control mechanisms - may not be reflected in this version of the text. The definitive version of the text was subsequently published in EUROPEAN UROLOGY, 69 (3), 2016, 10.1016/j.eururo.2015.08.005.

You may download, copy and otherwise use the AAM for non-commercial purposes provided that your license is limited by the following restrictions:

- (1) You may use this AAM for non-commercial purposes only under the terms of the CC-BY-NC-ND license.
- (2) The integrity of the work and identification of the author, copyright owner, and publisher must be preserved in any copy.
- (3) You must attribute this AAM in the following format: Creative Commons BY-NC-ND license (<http://creativecommons.org/licenses/by-nc-nd/4.0/deed.en>), 10.1016/j.eururo.2015.08.005

The publisher's version is available at:

<http://linkinghub.elsevier.com/retrieve/pii/S0302283815007484>

When citing, please refer to the published version.

Link to this full text:

<http://hdl.handle.net/>

Total Anatomical Reconstruction During Robot-assisted Radical Prostatectomy: Implications on Early Recovery of Urinary Continence

- Francesco Porpiglia^a, Riccardo Bertolo^a, Matteo Manfredi^a, Stefano De Luca^a, Enrico Checcucci^a, Ivano Morra^a, Roberto Passera^b, Cristian Fiori^a
-

Abstract

Background

The introduction of robotics revolutionized prostate cancer surgery because the magnified three-dimensional vision system and wristed instruments allow microsurgery to be performed. The advantages of robotic surgery could lead to improved continence outcomes in terms of early recovery compared with the traditional surgical methods.

Objective

To describe the total anatomical reconstruction (TAR) technique during robot-assisted radical prostatectomy (RARP). Primary endpoint: evaluation of the continence rate at different time points. Secondary endpoint: evaluation of urine leakage and anastomosis stenosis rates related to the technique.

Design, setting, and participants

June, 2013 to November, 2014; prospective consecutive series of patients with localized prostate cancer (cT1-3, cN0, cM0).

Surgical procedure

RARP with TAR was performed in all cases. Lymph node dissection was performed if the risk of lymph nodal metastasis was over 5%, according to the Briganti updated nomogram.

Measurements

Preoperative, intraoperative, postoperative, and pathological variables were analyzed. Enrolled patients were arbitrarily divided into three groups according to a time criterion. The relationships between the learning curve and the trend of the above-mentioned variables were analyzed using LOESS analysis. Continence was rigorously analyzed preoperatively and at 24 h, 1 wk, 4 wk, 12 wk, and 24 wk after catheter removal.

Results and limitations

In total, 252 patients were analyzed. The continence rates immediately after catheter removal and at 1 wk, 4 wk, 12 wk, and 24 wk after RARP were 71.8%, 77.8%, 89.3%, 94.4%, and 98.0%, respectively. Multivariate analysis revealed that the nerve sparing technique, D'Amico risk groups,

lymph node dissection, and prostate volume were involved in the early recovery of urinary continence. One ileal perforation requiring reoperation was recorded. The transfusion rate was 0.8%. Thirty-one (12.3%) postoperative complications were recorded up to 6 mo after surgery. Among these, eight acute urinary retentions (3.2%) and three urine leakages (1.2%) were recorded. There was a lack of randomization and comparison with other techniques. Both anatomical dissection of the prostatic apex and TAR were used. The results may not be generalized to low-volume centers.

Conclusions

The TAR technique showed promising results in the early recovery of urinary continence, as well as watertight anastomosis and a low rate of urine leakage. The oncologic results were not affected. Comparative studies are needed to support the quality of reported results.

Patient summary

On the basis of our findings, it seems that the risk of urinary incontinence following radical prostatectomy can be lowered via meticulous anatomical reconstruction using a robotic system. Comparative studies are required to support the reported results.

Keywords

- Anatomical reconstruction;
- Apex dissection;
- Continence;
- Continence recovery;
- Posterior reconstruction;
- Prostate cancer;
- Robot-assisted radical prostatectomy

1. Introduction

The ideal radical prostatectomy (RP) is realized when achieving the concurrent presence of urinary continence and sexual potency, with no evidence of positive surgical margins, early complications, or biochemical recurrence, which form the so-called 'pentafecta' [1].

Among these factors, incontinence is a particularly feared side effect of RP because it can significantly compromise the quality of life in patients who undergo RP [2]. Although the physiology of the mechanisms related to urinary continence following RP is still not completely understood, it is known that both the functional and anatomical changes associated with prostate removal coincide with alterations in the urinary sphincter complex and pelvic floor musculature. Moreover, preexisting unmodifiable factors such as age, prostate volume, bladder dysfunction, and other morbidities can influence the achievement and timing of urinary continence recovery after RP [3], [4], [5], [6] and [7].

The introduction of a robotic system revolutionized prostate cancer surgery. Indeed, the magnified three-dimensional high-definition vision system and the miniaturized wristed instruments allow for microsurgery and the respect of the most delicate anatomical structures. Thus, robotic surgery could

lead to improved continence outcomes in terms of early recovery compared with the traditional surgical methods [2].

In this prospective study, we described our total anatomical reconstruction (TAR) technique during robot-assisted RP (RARP), and we reported our results concerning urinary continence recovery in a consecutive series of patients. The primary endpoint was to evaluate the continence rate at different early time points. The secondary endpoint was to evaluate the urine leakage and anastomosis stenosis rates related to the described technique.

2. Materials and methods

2.1. Study population and design

The present study was performed between June, 2013 and November, 2014 at San Luigi Hospital in Orbassano (Turin), Italy, after obtaining approval from our Institutional Ethics Committee. To standardize the surgical procedure and postoperative care (ie, the catheter removal), 20 procedures were performed before starting patient enrolment.

After concluding this phase, the prospective enrolment of the present consecutive series began. The inclusion criteria were patients with localized prostate cancer (clinical stages cT1-3, cN0, cM0) that was suitable for RP. Preoperative assessment included multiparametric magnetic resonance imaging (mp-MRI) of the prostate in all cases.

The exclusion criteria were contraindications for undergoing RARP, neo-adjuvant hormone therapy, and anterior tumors with suspected extracapsular extension on mp-MRI.

All patients underwent RARP performed with the transperitoneal approach. A skilled laparoscopic surgeon with ample experience in pure and robot-assisted laparoscopic surgery for prostate cancer (F. P.) performed all of the prostate apical dissections and TARs.

2.2. Surgical technique

Details of the proposed surgical technique are shown in the accompanying video. A summary of the steps is reported below.

2.2.1. Patient positioning

The patient is placed in the supine position and secured to the operating table; the legs are then spread apart to allow for allocation of the robotic system. The bed is placed in the Trendelenburg position.

2.2.2. Induction of pneumoperitoneum, port placement, and docking of robotic system

Pneumoperitoneum is achieved using a Veress needle inserted in the peri-umbilical area.

Six ports (12 mm port for the optic, three 8 mm ports for robotic instruments, and both 10 mm and 5 mm ports for the assistant) are introduced and placed in a classical fan configuration. Finally, the robot is docked.

2.2.3. Preliminary time and preparation of the endopelvic fascia

After a preliminary exploration of the abdominal cavity, an incision of the parietal peritoneum is made to access the retropubic space. After the prostate is identified, the periprostatic fatty tissue is removed. The endopelvic fascia is incised while preserving the pubo-prostatic ligaments. At the end of these steps, the prostate apex is outlined.

2.2.4. Suture of the deep venous complex

The deep venous complex (DVC) is sutured using two separated 2/0 monofilament sutures, which is performed while preserving the pubo-prostatic ligaments.

2.2.5. Incision of the bladder neck

The visceral layer of the endopelvic fascia is sliced cranially, and the bladder neck dissection then begins. Once it is exposed, the catheter is pulled up using the fourth robotic arm to identify the dorsal attack of the trigone.

The incision is continued posteriorly at the level of the circumference ridge by following a vertical course to dissect the muscular fibers that anchor the bladder to the base of the prostate.

A lingula of muscular tissue that is encountered at the posterior aspect of the bladder neck (ie, the so-called retrotrigonal fascia) is dissected to gain access to the retrotrigonal space. The anterior layer of Denonvilliers' fascia is incised; the seminal vesicles are identified and then completely dissected.

2.2.6. Posterior Denonvilliers' fascia incision

The posterior layer of Denonvilliers' fascia is incised in an inverse U-shape in the proximity of the prostate gland to gain access to the perirectal space.

2.2.7. Anatomical dissection of the prostatic apex

The visceral layer of the endopelvic fascia and the underlying apron that still covers the anterior surface of the prostate are incised while sparing the pubo-prostatic ligaments. The smooth muscular fibers that arise from the peri-urethral structures and enter the apex of the prostate are microdissected via both blunt and sharp dissection, with minimal use of electrocauterization to ensure the maximum preservation of anatomical structures.

Finally, the apex is freed even in its lateral aspects, and the urethra is incised at the level of the genital ridge (Fig. 1).

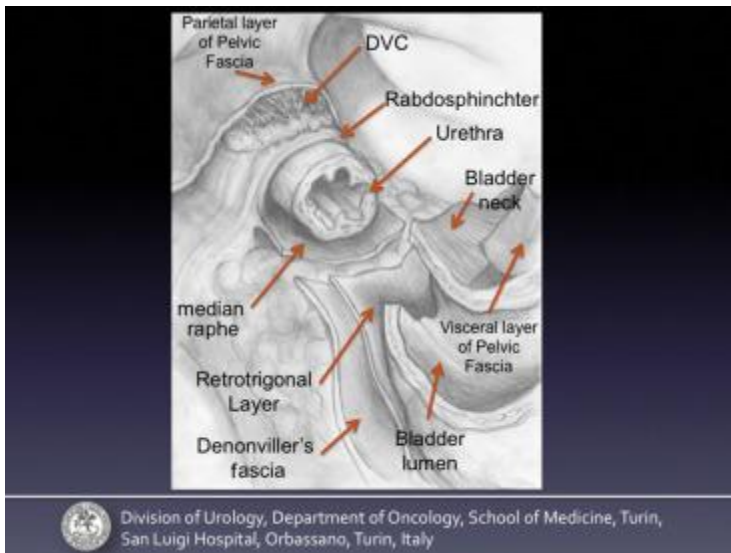


Fig. 1.

Operative field at the end of the extirpative phase. Anatomical landmarks are reported in the figure.

DVC = deep venous complex.

Figure options

2.2.8. Reconstructive phase: the posterior reconstruction

The posterior reconstruction is performed in a triple layer by using a 3/0 “barbed” suture. To create the first layer, the needle is passed into the cranial portion of the previously sectioned Denonvilliers’ fascia and the median raphe (Fig. 2 and Fig. 3) and is moved from right to left.

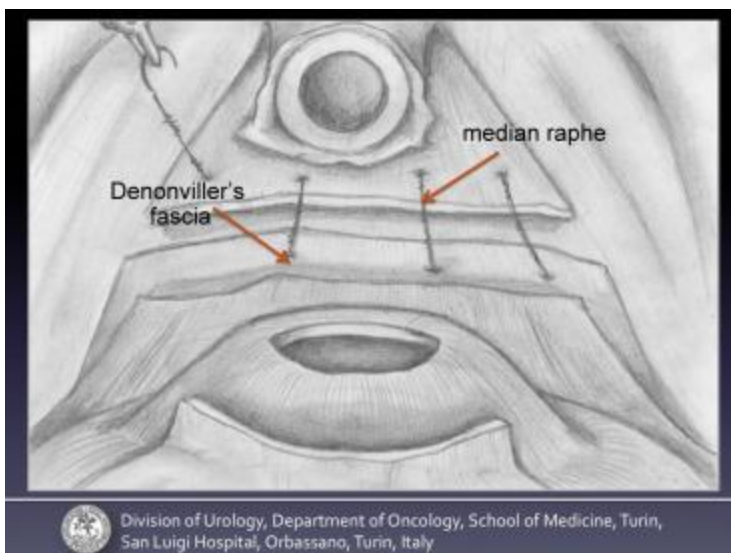


Fig. 2.

Frontal view. First layer of posterior reconstruction: the needle is passed through the cranial portion of previously sectioned Denonvilliers’ fascia and the median raphe moving from right to left.

Figure options

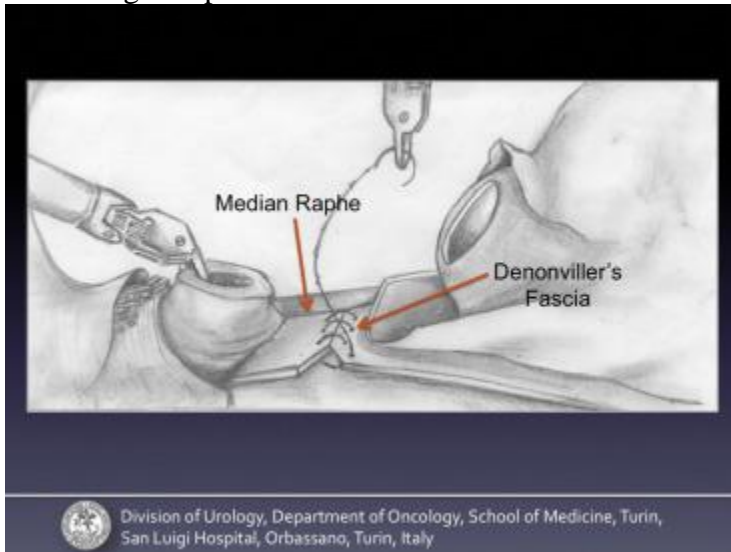


Fig. 3.

Lateral view. First layer of posterior reconstruction: the needle is passed through the cranial portion of previously sectioned Denonvilliers' fascia and the median raphe moving from right to left.

Figure options

The second layer involves the retrotrigonal fascia and the median raphe (Fig. 4 and Fig. 5) and is moved from left to right. The third layer involves the bladder neck (excluding the mucosa of the bladder) and the posterior aspect of the rhabdosphincter (Fig. 6 and Fig. 7), which again move from right to left.

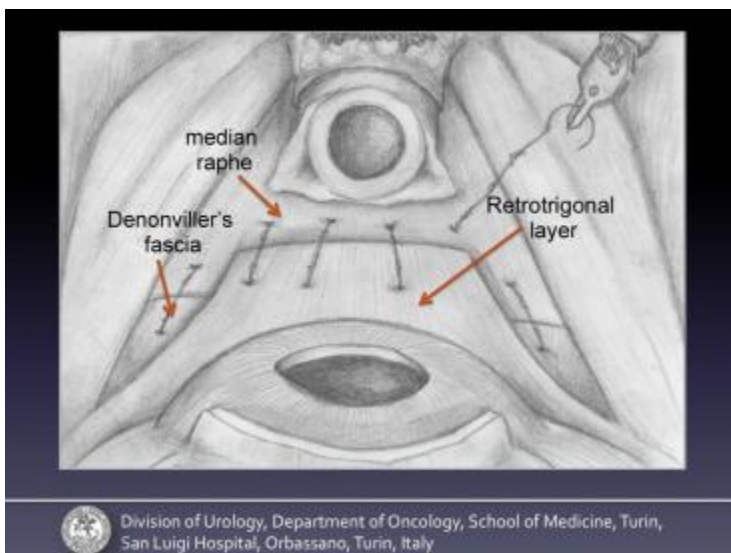


Fig. 4.

Frontal view. The second layer involves the retrotrigonal fascia and the median raphe moving from left to right.

Figure options

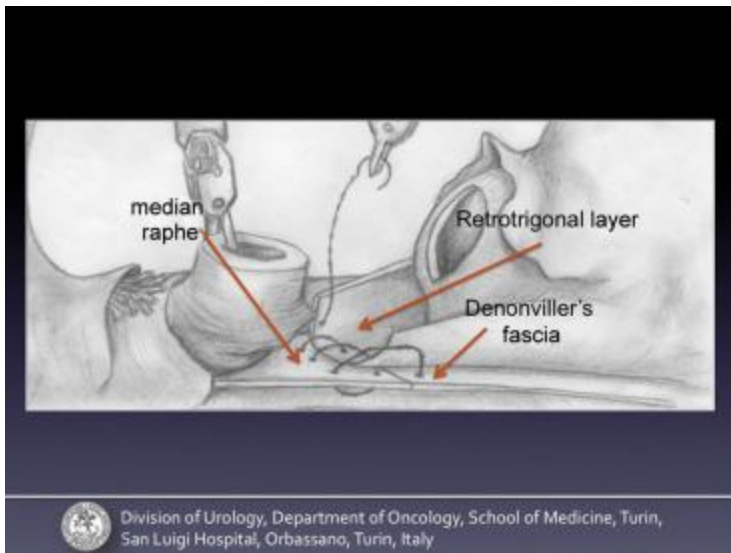


Fig. 5.

Lateral view. The second layer involves the retrotrigonal fascia and the median raphe moving from left to right.

Figure options

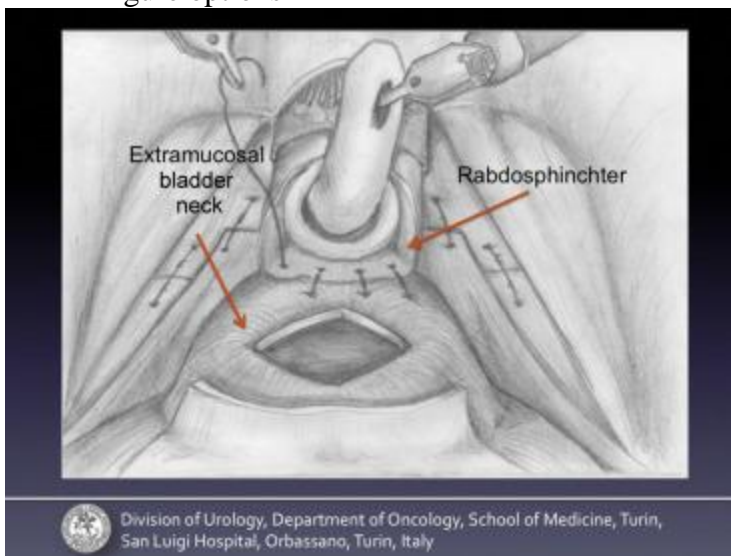


Fig. 6.

Frontal view. The third layer involves the bladder neck (excluding the mucosa of the bladder) and the posterior aspect of the rhabdosphincter again moving from right to left.

Figure options

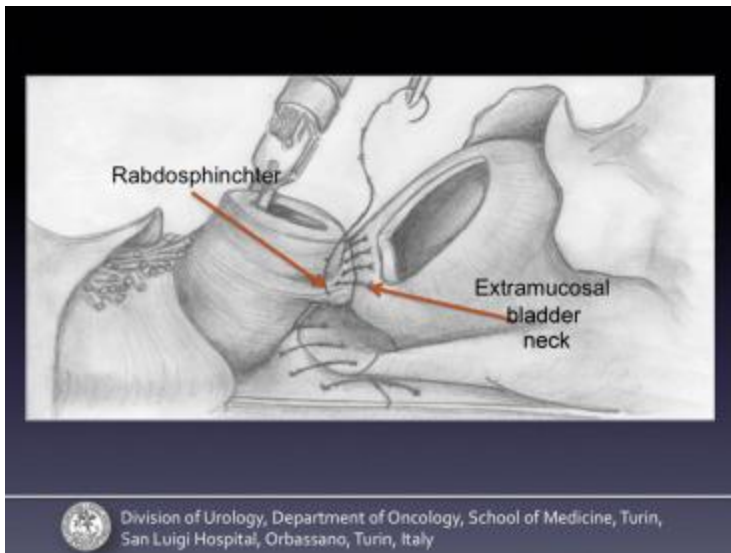


Fig. 7.

Lateral view. The third layer involves the bladder neck (excluding the mucosa of the bladder) and the posterior aspect of the rhabdosphincter again moving from right to left.

Figure options

2.2.9. Urethro-vesical anastomosis

The urethro-vesical anastomosis is performed by using a 3/0 “barbed” running suture, starting at 4 o’clock on the urethra and then proceeding clockwise. Such a suture involves the full thickness of either the bladder or the urethra (Fig. 8 and Fig. 9). When required, a single stitch is passed to reinforce the anastomosis. In the case of a large bladder neck, two hemi-running sutures are performed. Moreover, the suture is eventually completed on its anterior by reabsorbable 3/0 monofilament single stitches.

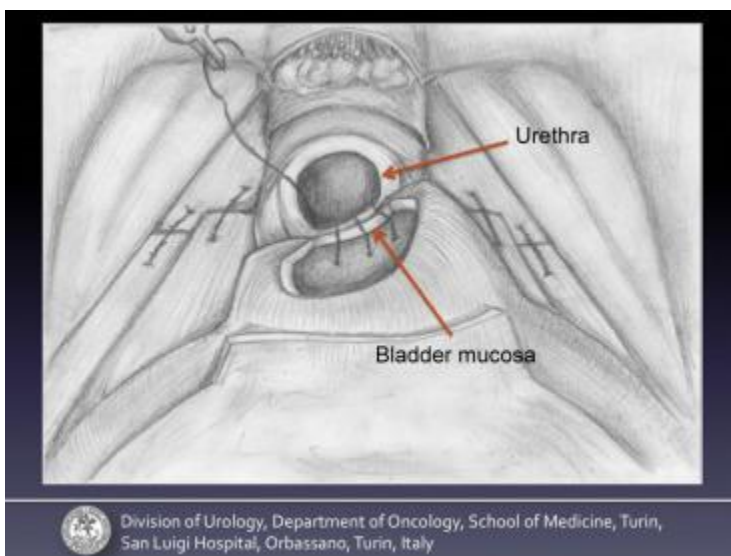


Fig. 8.

Frontal view. The urethro-vesical anastomosis performed by a 3/0 “barbed” running suture, starting at 4 o’clock on the urethra and proceeding clockwise. The suture involves the full thickness of either the bladder or the urethra.

Figure options

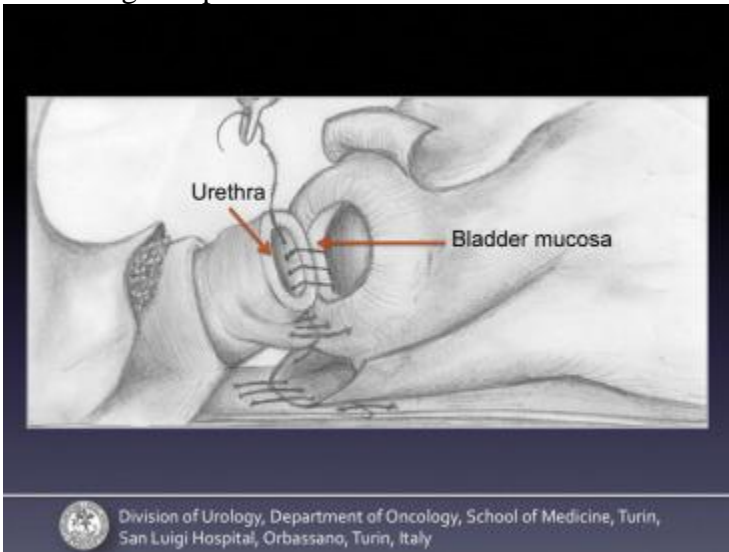


Fig. 9.

Lateral view. The urethro-vesical anastomosis performed by a 3/0 "barbed" running suture, starting at 4 o'clock on the urethra and proceeding clockwise. The suture involves the full thickness of either the bladder or the urethra.

Figure options

2.2.10. Reconstructive phase: the anterior reconstruction

Beginning from the right side and moving left, the muscular fibers of the bladder are 3/0 "barbed" running sutured to the previously dissected peri-urethral tissue, which is located between the urethra and the DVC (Fig. 10 and Fig. 11), both to restore the original anatomy by reallocating it towards the abdominal cavity and to reinforce the anastomosis.

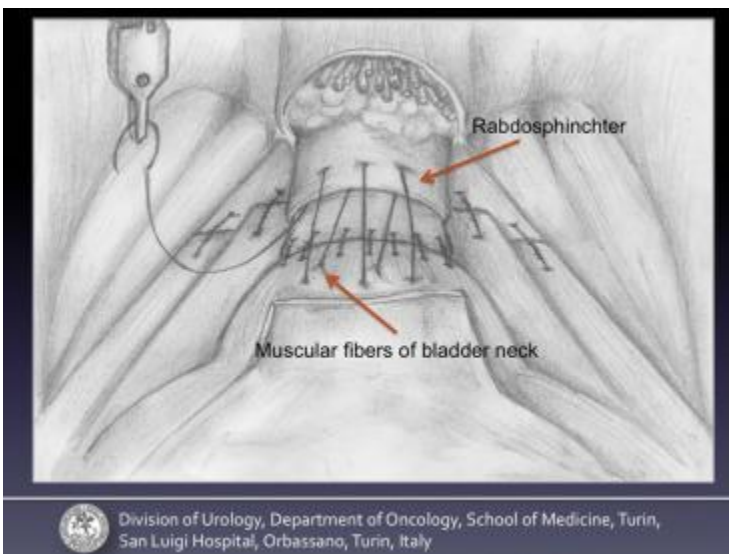


Fig. 10.

Frontal view. Beginning from the right side and moving to the left, the muscular fibers of the bladder are 3/0 "barbed" running sutured to the previously dissected peri-urethral tissue

located between the urethra and the deep venous complex both to restore the original anatomy by reallocating it towards the abdominal cavity and to reinforce the anastomosis.

Figure options

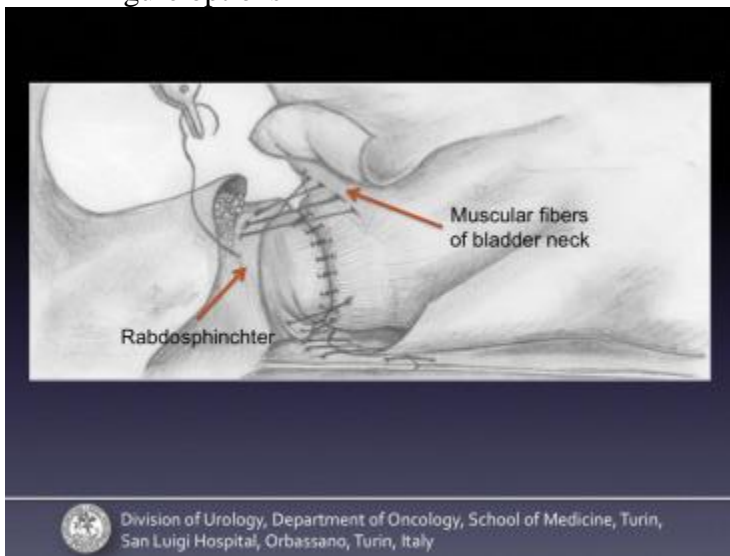


Fig. 11.

Lateral view. Beginning from the right side and moving to the left, the muscular fibers of the bladder are 3/0 "barbed" running sutured to the previously dissected peri-urethral tissue located between the urethra and the deep venous complex both to restore the original anatomy by reallocating it towards the abdominal cavity and to reinforce the anastomosis.

Figure options

Finally, using the same suture and returning to the starting point, the visceral layer of the endopelvic fascia and the underlying apron, which still covers the anterior surface of the bladder, are sutured to the portion of the endopelvic fascia that covers the DVC while involving the pubo-prostatic ligaments (Fig. 12 and Fig. 13) such that they can be renamed as "pubo-vescical" ligaments.

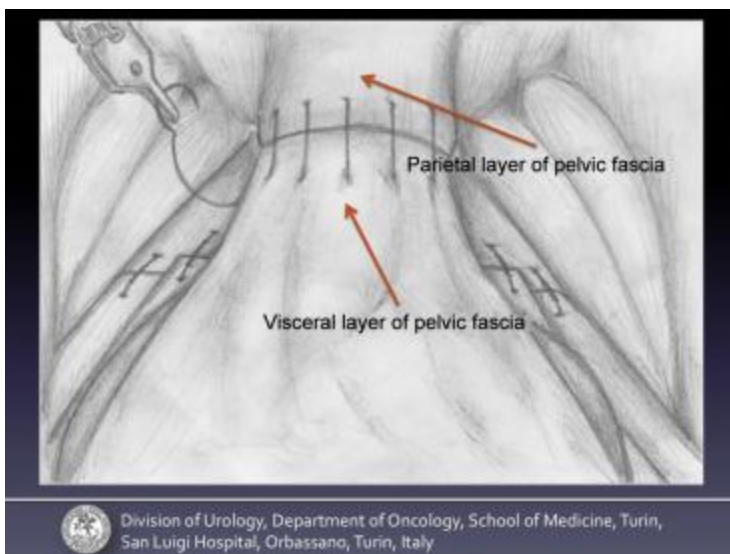


Fig. 12.

Frontal view. Moving from left to right, the visceral layer of the endopelvic fascia and the underlying apron, still covering the anterior surface of the bladder, are sutured to the portion of the endopelvic fascia that covers the deep venous complex while involving the pubo-prostatic ligaments such that they can be renamed “pubo-vescical” ligaments.

Figure options

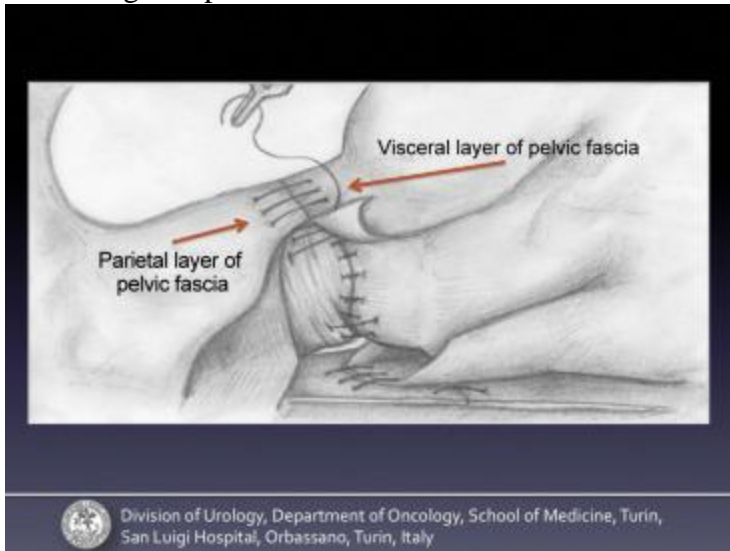


Fig. 13.

Lateral view. Moving from left to right, the visceral layer of the endopelvic fascia and the underlying apron, still covering the anterior surface of the bladder, are sutured to the portion of the endopelvic fascia that covers the deep venous complex while involving the pubo-prostatic ligaments such that they can be renamed “pubo-vescical” ligaments.

Figure options

A single 3/0 monofilament stitch can be performed at the end of the running suture to secure it.

In summary, at the end of the reconstructive phase, the anastomosis is protected by three posterior layers and two anterior layers, with full restoration of the anatomy of the peri-urethral structures (Fig. 14).

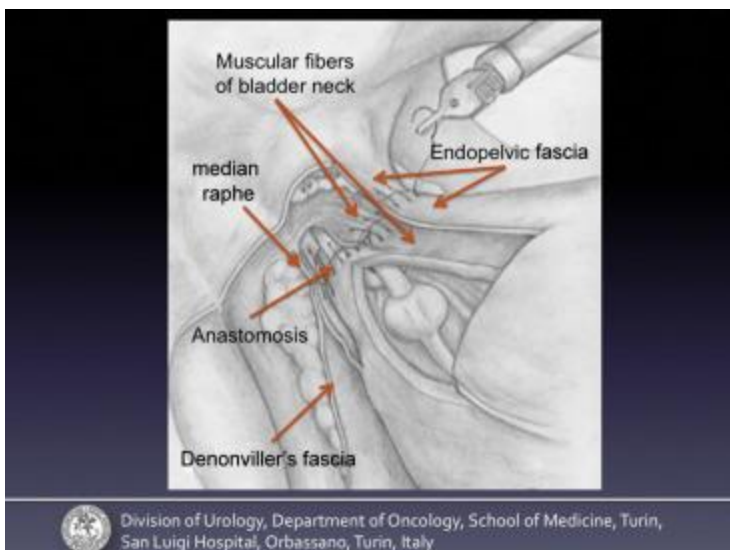


Fig. 14.

At the end of the reconstructive phase, the anastomosis is protected by three posterior layers and two anterior layers, with a full restoration of the anatomy of the peri-urethral structures.

Figure options

2.2.11. Hemostasis, reconstruction of the peritoneum, drainage placement

Hemostasis is performed using bipolar robotic forceps and hemostatic agents. An independent tubular drainage is placed through a small suprapubic incision. The peritoneum is reconstructed using a 3/0 “barbed” running suture fixed with Hem-o-lok, thereby restoring the anatomy of the peritoneal sac.

2.2.12. Extended lymph node dissection

An extended pelvic lymph node dissection (ePLND, which includes iliac, obturator, and presacral lymph node removal) is performed in selected cases (according to the Briganti updated nomogram [8]) with bilateral preservation of the lateral side of the prevesical fascia. At the end of this phase, an independent tubular drainage is inserted through the skin for the fourth robotic arm. The reconstruction of the peritoneum is performed only at its ventral aspect while leaving the incisions lateral to the umbilical ligament unclosed on both sides. In this way, the retropubic space does not communicate with the intraperitoneal cavity, which is why the two spaces are drained separately.

2.2.13. Extraction of the specimen; wounds suture

The specimen is retrieved using an endobag through the skin for the optic trocar. At the end of the procedure, the skin wounds are sutured.

2.2.14. Postoperative care

The intraperitoneal drainage is removed on the 2nd postoperative day (POD), and the extraperitoneal drainage is removed on the 3rd POD. The catheter is removed on the 5th POD after pelvic ultrasonography (US).

If there is evidence of urine leakage in the drainage sac or if such leakage suspected at US, a cystography is performed before catheter removal.

2.3. Data analysis

Collected data included preoperative variables, including patient age, serum prostate specific antigen at diagnosis, body mass index, American Society of Anesthesiologists score, digital rectal examination, Gleason Score at biopsy, D’Amico risk stratification, prostate volume estimated with trans-rectal ultrasonography; intraoperative variables, including estimated blood loss, skin-to-skin operative time (since the insertion of the Veress needle to the suture of surgical wounds), time to complete the anastomosis and time to complete the posterior and the anterior reconstruction, ePLND rate and number of full, partial, and minimal nerve sparing (NS) procedures (according to the Pasadena's classification); postoperative variables, including duration of catheterization and hospitalization, postoperative complications (according to modified Clavien's classification); and pathological variables, including prostate volume, tumor volume, and percentage of cancer on the

whole prostate, pathologic stage (according to TNM), Gleason Score at final histopathological analysis, and positive surgical margin rate.

The enrolled patients were arbitrarily divided into three groups according to a time criterion (#1–84, #85–168; # 169–252). The relationships between the learning curve and the trend of the above-mentioned variables were analyzed.

2.4. Analysis of continence

The preoperative functional parameters were assessed by validated questionnaires, namely the International Continence Society male and the International Prostatic Symptoms Score with Urinary Incontinence Quality of Life Scale questionnaires.

The continence rate was assessed at 24 h, 1 wk, 4 wk, 12 wk, and 24 wk after catheter removal. After surgery, all patients were instructed to undergo proper pelvic-floor rehabilitation, which started at the time of catheter removal and was performed daily with a gradual increase in training load for a period of 8 wk.

Continence was evaluated using the Expanded Prostate Cancer Index Composite survey question: “How many pads or adult diapers per d did you usually use to control leakage during the last 4 wk?” To measure continence at catheter removal and 1 wk after removal, the question was modified. The patient was defined as continent if they answered “zero pad” or “one safety pad” per d. At both 12 wk and 24 wk after catheter removal, all patients were reviewed with the International Prostatic Symptoms Score questionnaire and Urinary Incontinence Quality of Life Scale.

The patients who were still incontinent at the 12th wk were instructed to perform both the 24-h pad weight test for 7 d and the standard 1-h pad test. Moreover, to determine the type of incontinence, these patients underwent urodynamics. The patients who were still incontinent at the 24th wk were instructed to perform the same second-level tests, excluding the urodynamics.

Finally, the relationships between the surgeon's learning curve and the recovery of continence were analyzed by comparing the three groups according to a time criterion.

Concerning the secondary end-points, urine leakage was defined as perianastomotic leakage of fluid at transcatheter retrograde cystourethrogram. At 3 mo, all continent patients underwent uroflowmetry to exclude stenosis of the anastomosis. If they had a Q_{\max} below 15 ml/s and a normal voided volume, patients underwent retrograde and voiding cystourethrogram and flexible cystoscopy.

2.5. Statistical analysis

Patient characteristics were tested using Fisher's exact test for categorical variables and the Mann-Whitney test for continuous ones. All results for continuous variables were expressed as medians (range), and the frequencies and proportions were reported as percentages. The analysis of the functional learning curve for a single surgeon's experience associated with the best recovery for urinary continence was performed using the LOESS regression (locally weighted scatterplot smoothing) after dividing the entire cohort into subgroups of 10 consecutive patients. The recovery of urinary continence (dependent variable), as measured with the Expanded Prostate Cancer Index Composite questionnaire, was tested at four different time points (at catheter removal and at Wk 1, Wk 4, and Wk 12 after surgery) using four independent uni-/multivariate binary logistic regression models. The following covariates were tested as risk factors (independent variables): age at surgery

(≥ 65 yr vs < 65 yr), body mass index (≥ 27 vs < 27), diabetes (yes vs no), smoking (present/past vs never), prostatic volume (≥ 47 ml vs < 47 ml), NS Pasadena (no sparing vs intermediate vs full) and D'Amico (low vs medium vs high) scores. All reported p -values were obtained using the two-sided exact method at the conventional 5% significance level. Data were analyzed as of May, 2015 using R 3.2.0 (R Foundation for Statistical Computing, Vienna-A, <http://www.R-project.org>).

3. Results

3.1. Demographics

The study included 252 patients. The preoperative variables are summarized in Table 1. The three groups were created according to a time criterion and were comparable in terms of demographic variables (data not shown).

Table 1.

Preoperative variables

Patients' characteristics	Data
No. of patients	252
Age, median (IQR), yr	64.5 (59–68.25)
BMI, median (IQR)	27.3 (25.5–27.7)
PSA, median (IQR), ng/ml	6.2 (5–9.7)
ASA score, median (IQR)	2 (2–2)
IPSS score, median (IQR)	7 (4–12)
IIEF-5 score, median (IQR)	20 (1–23)
TRUS prostate volume, median (IQR)	47.0 (37.7–58.3)
GS, median (IQR)	7 (6–7)
Positive DRE, number (%)	55 (21.8)
D'Amico classification, number (%)	
• Low risk	102 (40.5)
• Intermediate risk	114 (45.2)
• High risk	36 (14.3)

ASA score = American Society of Anesthesiologist score; BMI = body mass index; DRE = digital rectal exploration; GS = Gleason Score; IIEF = International Index of Erectile Function; IPSS = International Prostate Symptoms Score; IQR = interquartile range; PSA = prostate specific antigen; TRUS = transrectal ultrasound.

Table options

3.2. Operative outcomes

Concerning the intraoperative findings (Table 2), the median operative time was 130 min. Comparing the intraoperative variables after arbitrarily stratification according to time criterion, a statistically significant difference was observed among the groups in terms of the reduction in operative time ($p < 0.001$), decrease in the time required to complete the anastomosis ($p < 0.001$),

decrease in the time required to complete the posterior and anterior reconstruction ($p < 0.001$) and reduction of blood loss ($p = 0.022$). The differences in the operative parameters were confirmed using the LOESS analysis showing that learning curve did not end within the 252 procedures considered (Fig. 15). The median lengths of the catheterization time and hospital stay were 5 d, with no differences among the groups.

Table 2.

Intraoperative variables

Intraoperative parameters	Data
Operative time, median (IQR), min	130 (120–150)
Anastomosis time, median (IQR), min	6.5 (4.7–7)
Time of anterior reconstruction, median (IQR) min	10.2 (7.5–12.2)
Time of posterior reconstruction, median (IQR) min	9.3 (7.2–10.5)
Blood loss, median (IQR), ml	250 (225–280)
Full NS, no. (%)	31 (12.3)
Partial NS, no. (%)	88 (34.9)
No NS, no. (%)	133 (52.8)
Lymp-nodes dissections, no. (%)	126 (50.0)

DRE = digital rectal exploration; IQR = interquartile range; NS = nerve sparing.

Table options

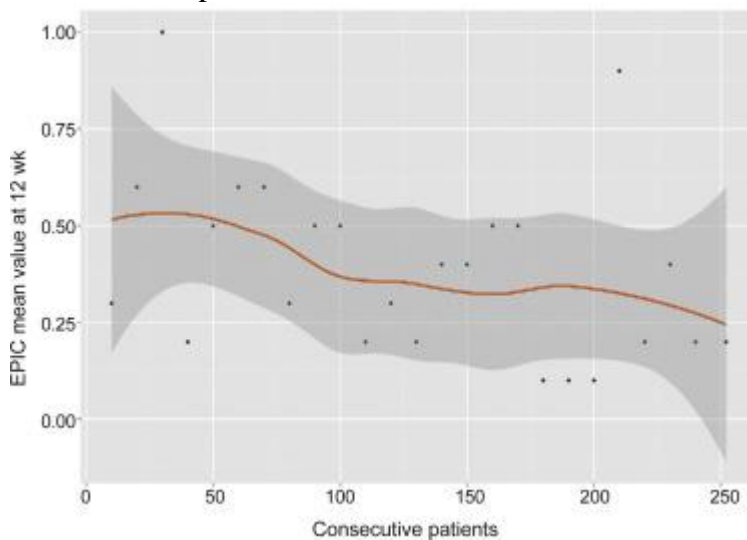


Fig. 15.

LOESS regression performed at 12th wk time point.

EPIC = Expanded Prostate Cancer Index Composite.

Figure options

3.3. Complications

One intraoperative complication was registered, namely an ileal perforation requiring reoperation. The transfusion rate was 0.8% (two cases). There were 31 (12.3%) postoperative complications recorded up to 6 mo after surgery. Of these, eight acute urinary retentions (3.2%) and three urine leakages (1.2%) were recorded. All of them had a low Clavien grade (1–2), except for two (Clavien 3 grade): a paravesical urinoma and a suprapubic hematoma that required US-guided percutaneous drainage. No strictures of anastomosis were registered. Urine leakages were recorded in three cases (1.2%).

3.4. Pathological findings

Histopathological data are reported in Table 3. The overall positive margin rate was 20.6%, and in 14.7% of the cases, the positive margin was located at the apex.

Table 3.

Histopathological data

Pathologic findings	Data
Positive margins, no. (%)	52 (20.6)
• Apex positive margins, no. (%)	37 (14.7)
• pT2 positive margins, no. (%)	15 (5.9)
• <3 mm long margins, no. (%)	40 (76.9)
Prostate volume, median (IQR), ml	42.0 (35.2–47.5)
Tumor size, median (IQR), ml	2.5 (2.2–3.4)
% of tumor, median (IQR)	5.6 (4.1–8.3)
Stage, no. (%)	
pT2	145 (57.5)
pT3	98 (38.9)
Pathological GS, no. (%)	
2–6	60 (23.8)
7	168 (66.7)
8–10	24 (9.5)

GS = Gleason Score; IQR = interquartile range.

Table options

The positive margin rate decreased to 5.9% (15/252) in the cohort of pT2-staged patients.

Forty of the 52 positive surgical margins (76.9%) were <3 mm long and were thus considered nonsignificant.

3.5. Continence outcomes

At the time of catheter removal, 181 patients (71.8%) were continent. The continence rate gradually improved at the 1st wk (196/252, 77.8%), at 4 wk (225/252, 89.3%), at 12 wk (238/252, 94.4%), and at 24 wk (247/252, 98.0%) after catheter removal (Fig. 16). Regarding the learning curve analysis, a

trend towards a progressive increase in the number of continent patients at each time point was recorded from Group 1 to Group 3, though the trend did not reach statistical significance.

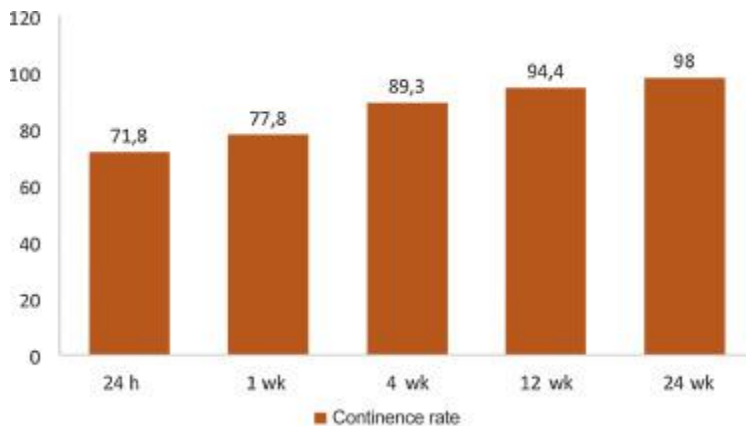


Fig. 16.

Histogram showing continence rates at different time points.

Figure options

According to the previously described criteria, five patients remained incontinent at the 24-wk follow-up. Among these, in two cases (0.8%), a high loss of urine (>75 g) was registered at the 24-h pad weight test, and a >50 g loss was registered at the standard 1-h pad test that was performed in the 12th wk. In these patients, the degree of incontinence was retested with the 24-h pad weight test, with a urine loss below 20 g (mild incontinence) recorded in one patient (0.4%). The only patient with urine loss over 20 g underwent urodynamic investigation, which demonstrated detrusor hyperactivity. The evaluation of the quality of life by Urinary Incontinence Quality of Life Scale questionnaire reported a median score of 1 in patients with a 24-h pad test result of <75 g. Conversely, in patients with losses over 75 g, the median score was 4. In summary, at the 24-wk follow-up, five patients were incontinent: one case was due to detrusor hyperactivity (severe incontinence), and the remaining four cases were due to postoperative stress (three low, one mild).

Univariate analysis highlighted a statistically significant difference in the recovery of continence at the time of catheter removal in relation to the different NS Pasadena categories ($p = 0.034$), with major continence registered for full nerve-sparing procedures. The D'Amico risk classification appeared to influence the continence recovery at 1 wk ($p = 0.049$), 4 wk ($p = 0.004$), and 12 wk ($p = 0.034$). When it was performed, LND influenced continence recovery a wk after catheter removal ($p = 0.042$).

Multivariate analysis showed that the patients in the D'Amico low-risk group and the patients who underwent a full nonsurgical procedure had a statistically significant advantage in terms of continence recovery at the time of catheter removal ($p = 0.019$). At 1 wk, the only independent predictor variable was a lack of LND ($p = 0.042$). At 4 wk, a prostate volume <47 g and the D'Amico low risk group indicated patients with continence recovery ($p = 0.05$ and $p = 0.003$, respectively), whereas at 12 wk, the only independent predictor variable was a low or intermediate D'Amico risk group ($p = 0.027$).

4. Discussion

The presence of urinary incontinence after RP can significantly impact patient quality of life [9]. Over the last decade, the desire to reduce the invasiveness of open surgery and the search for better functional results have been driving factors for the popularity of laparoscopic techniques. Optical magnification has been considered one of the strongest advantages of laparoscopy, and this is particularly true in the case of surgery for prostate cancer. Robotic technology provides further advantages, including binocular three-dimensional visualization with magnification, physiologic tremor of the surgeon's hand filtration with demultiplication of movements, and wristed instrumentation. Meticulous, precise, and accurate surgical movements are fundamental for minimizing perioperative complications and preserving the key anatomical structures that are involved in urinary continence [2].

Indeed, many published papers have shown the advantages of robotics in terms of functional results [10], [11], [12], [13] and [14].

Although the mechanism of continence recovery after surgery is complex and not wholly understood, it is universally accepted that the main aim of the surgeon must be to preserve the anatomical structures involved in continence (ie, the bladder neck, the rhabdosphincter, and the surrounding peri-urethral supporting tissue) and to precisely conduct the NS approach and reconstruction phase.

In recent years, several technical modifications aimed to improve postoperative continence after RP have been proposed, including bladder neck preservation, intussusception of the bladder neck, approximation of anterior supporting structures with sparing or reconstruction of the puboprostatic ligaments, creation of posterior urethral support (posterior reconstruction of the rhabdosphincter), and variations of suspension sutures [15], [16], [17], [18], [19], [20], [21], [22], [23], [24], [25], [26] and [27].

According to Patel et al [21], anterior support provides anatomical support for the urethra, which allows the urethral length to be maximized during apex dissection and either the urethra or the rhabdosphincter to be stabilized in their anatomical position. The notion of stabilizing the urethra on the periurethral structures to achieve better continence rates was first applied by Sugimura et al [28] during open RP. Noguchi et al [29] evolved the technique to include the anterior suspension stitch anchored to the pubic bone, which resulted in significantly improved continence rates in the patients who received this treatment [29]. Subsequently, the technique was simplified and reproduced during RARP in a nonrandomized prospective study by Patel et al [27], who reported significant differences in the continence rates at the 3rd mo postoperation in patients who received anterior suspension.

Rocco et al [24] were the first to propose a different technique that involved posterior fixation of the anastomosis; this procedure also resulted in better continence rates compared with the simple anastomotic techniques.

This technical modification has been widely used by RARP surgeons [16], [17], [19], [20], [22], [26] and [27].

In contrast to the previously cited reports, Menon et al [30] did not find any improvement in the early continence rates in a randomized study that combined the anterior suspension stitch with posterior reconstruction. Sutherland et al [31] did not find any advantage in the early continence recovery following the reconstruction of the musculofascial plate dorsal to the urethra.

In the present study, we reported a “tension-free” anastomosis technique that aimed to restore the anterior and posterior supports to the sphincter. The proposed technique obtained promising outcomes in terms of early continence immediately after catheter removal and at 1 mo, 3 mo, and 6 mo postoperatively. The reported results were possible because of the standardized combination of previously reported techniques. Some features should be emphasized in our technique.

Firstly, we believe that the preservation of pubo-prostatic ligaments at the time of the preparation of the prostate with incision of endopelvic fascia is crucial because it allows for better apex dissection. As such, even the DVC suture is performed while preserving the pubo-prostatic ligaments.

Secondly, it is important that incision of the bladder neck be performed in a bloodless operative field to meet the previously cited lingula of muscular tissue at the posterior aspect of the bladder neck, the so-called retrotrigonal fascia. This structure is important because it will be anchored to the median raphe and will reinforce the posterior reconstruction.

Thirdly, in our experience, the incision of the posterior Denonvillers’ fascia should be done in an inverse U-shape to allow for better reconstruction.

Fourth, we believe that the management of the prostatic apex should be done step-by-step, with meticulous dissection of muscular fibers while limiting the use of cauterization as much as possible. Surgeons should remember that the anatomy of the prostate apex varies by case. However, it is important to preserve the anatomical structures that are involved in the support of the urethra and to maximize urethral length. To obtain negative surgical margins, it is crucial to adapt the dissection based on the anatomy of the prostate apex.

During the anterior reconstruction, in our technique the apron will be restored and reanchored to the muscular fibers that arise from the anterior aspect of the rhabdosphincter.

In summary, the two cornerstones of our technique are the anatomical dissection of the prostatic apex (which allows for the maximum preservation of the peri-urethral tissue and urethral length) and the restoration of the anatomy of the peri-urethral structures by protecting the anastomosis using three posterior layers and two anterior layers, which allows for “tension-free” anastomosis.

Our series showed mean continence rates immediately after catheter removal and at 1 wk, 4 wk, 12 wk, and 24 wk after RARP of 71.8%, 77.8%, 89.3%, 94.4%, and 98.0%, respectively.

We opted to arbitrarily divide patients into different groups according to a time criterion to test whether the learning curve would affect the continence results. Before starting patient enrolment, we conducted 20 procedures that were not considered in the analysis to standardize the steps of the technique. When dividing patients according to a time criterion to evaluate the effects of the learning curve on the results, we found a progressive significant decrease in the operative times required to complete all of the steps described in our technique but did not find a significant difference in the continence outcomes.

Based on this finding, we concluded that after being rigorous in standardizing the steps during a “preenrolment” phase that lasted for a couple of procedures, encouraging functional results were obtained because the beginning and learning curve affect only the surgeon's ability to complete the reconstruction in a shorter operative time.

Using LOESS regression, we improved the quality of the assessment of learning curve influence on the results. We discovered that learning curve did not end after 250 procedures confirming previous

findings [32]. This finding partially explained the improvement in the operations across the created eras. However, because the learning curve plateau was not reached yet, it was impossible to use surgeon experience as a covariate in the binary logistic model.

As discovered in the multivariate analysis, the nerve sparing technique, D'Amico risk groups, eventual ePLND, and prostate volume were involved in the early recovery of urinary continence because they reasonably affected the preservation of anatomical structures and the involvement of the sacral plexus.

Concerning the secondary end-points of the study, we recorded a low rate of urine leakage (1.2%) and no stenosis of the anastomosis. This finding allowed us to conclude that the meticulous urethrovesical anastomosis and reconstruction of the peri-urethral structures ensured a watertight anastomosis without increasing the risk of strictures in almost all the cases.

In summary, our total anatomical reconstruction technique demonstrated promising results in terms of the early recovery of urinary continence and in the performance of watertight anastomosis because it prevented the occurrence of urine leakage without increasing the risk of strictures of the anastomosis. Moreover, the use of a novel technique did not seem to have an influence on the oncologic results, if compared with the ones available in literature. The strengths of our study include the use of a standardized surgical technique and a rigorous evaluation of incontinence via validated self-administered questionnaires and urodynamics. Moreover, the preoperative selection of patients using mp-MRI, excluding patients with anterior cancers with suspected extracapsular extension, allowed for the performance of a conservative apical dissection while ensuring a rate of positive surgical margins comparable to previously published results.

A limitation of the study was the lack of randomization and the lack of a comparison with other techniques. Comparative studies are needed to draw definitive conclusions. In the proposed technique, both an anatomical dissection of the prostatic apex and TAR were used. We are unable to state whether the results in terms of early recovery of continence were attributable to the sum of the two surgical steps or to only one of them. In addition, excluding the presence of diabetes mellitus and smoking status, preexisting comorbidities that could potentially affect continence status were not recorded in our prospective database. Finally, our results may not be generalized to low-volume RARP centers, though the study provides all of the technique descriptions that are required to duplicate the procedure.

Notwithstanding the limitations of the study, the present study was performed in a prospective fashion and was based on a consecutive series of patients, who showed encouraging results about early continence recovery after RARP, to be supported by further studies.

Author contributions: Francesco Porpiglia had full access to all the data in the study and takes responsibility for the integrity of the data and the accuracy of the data analysis.

Study concept and design: Porpiglia.

Acquisition of data: Checcucci.

Analysis and interpretation of data: Manfredi, Bertolo.

Drafting of the manuscript: Bertolo, Manfredi, De Luca.

Critical revision of the manuscript for important intellectual content: Porpiglia, Morra, Fiori.

Statistical analysis: Passera.

Obtaining funding: None.

Administrative, technical, or material support: None.

Supervision: Porpiglia.

Other: None.

Financial disclosures: Francesco Porpiglia certifies that all conflicts of interest, including specific financial interests and relationships and affiliations relevant to the subject matter or materials discussed in the manuscript (eg, employment/affiliation, grants or funding, consultancies, honoraria, stock ownership or options, expert testimony, royalties, or patents filed, received, or pending), are the following: None.

Funding/Support and role of the sponsor: None.

Appendix A. Supplementary data

Help with MP4 files
Options

References

1.
 - [1]
 - V.R. Patel, H.M. Abdul-Muhsin, O. Schatloff, R.F. Coelho, R. Valero, Y.H. Ko, A. Sivaraman, K.J. Palmer, S. Chauhan
 - Critical review of ‘pentafecta’ outcomes after robot-assisted laparoscopic prostatectomy in high-volume centres
 - BJU Int, 108 (2011), pp. 1007–1017
 - [SD-008]
2.
 - [2]
 - V. Ficarra, G. Novara, R.C. Rosen, W. Artibani, P.R. Carroll, A. Costello, M. Menon, F. Montorsi, V.R. Patel, J.U. Stolzenburg, H. Van der Poel, T.G. Wilson, F. Zattoni, A. Mottrie
 - Systematic review and meta-analysis of studies reporting urinary continence recovery after robot-assisted radical prostatectomy
 - Eur Urol, 62 (2012), pp. 405–417
 - [SD-008]
3.
 - [3]
 - G. Novara, V. Ficarra, C. D’elia, S. Secco, A. Cioffi, S. Cavalleri, W. Artibani

- Evaluating urinary continence and preoperative predictors of urinary continence after robot assisted laparoscopic radical prostatectomy
- J Urol, 184 (2010), pp. 1028–1033
- [SD-008]
- 4.
- [4]
- S. Shikanov, V. Desai, A. Razmaria, G.P. Zagaja, A.L. Shalhav
- Robotic radical prostatectomy for elderly patients: probability of achieving continence and potency 1 year after surgery
- J Urol, 183 (2010), pp. 1803–1807
- [SD-008]
- 5.
- [5]
- B.A. Link, R. Nelson, D.Y. Josephson, J.S. Yoshida, L.E. Crocitto, M.H. Kawachi, T.G. Wilson
- The impact of prostate gland weight in robot assisted laparoscopic radical prostatectomy
- J Urol, 180 (2008), pp. 928–932
- [SD-008]
- 6.
- [6]
- T.A. Skolarus, R.C. Hedgepeth, Y. Zhang, A.Z. Weizer, J.S. Montgomery, D.C. Miller, D.P. Wood Jr., B.K. Hollenbeck
- Does robotic technology mitigate the challenges of large prostate size?
- Urology, 76 (2010), pp. 1117–1121
- [SD-008]
- 7.
- [7]
- S.J. Jeong, J. Yi, M.S. Chung, D.S. Kim, W.K. Lee, H. Park, C.Y. Yoon, S.K. Hong, S.S. Byun, S.E. Lee
- Early recovery of urinary continence after radical prostatectomy: correlation with vesico-urethral anastomosis location in the pelvic cavity measured by postoperative cystography
- Int J Urol, 18 (2011), pp. 444–451
- [SD-008]
- 8.
- [8]
- A. Briganti, A. Larcher, F. Abdollah, U. Capitanio, A. Gallina, N. Suardi, M. Bianchi, M. Sun, M. Freschi, A. Salonia, P.I. Karakiewicz, P. Rigatti, F. Montorsi
- Updated nomogram predicting lymph node invasion in patients with prostate cancer undergoing extended pelvic lymph node dissection: the essential importance of percentage of positive cores
- Eur Urol, 61 (2012), pp. 480–487
- [SD-008]
- 9.
- [9]
- M. Jønler, F.A. Madsen, P.R. Rhodes, M. Sall, E.M. Messing, R.C. Bruskewitz
- A prospective study of quantification of urinary incontinence and quality of life in patients undergoing radical retropubic prostatectomy
- Urology, 48 (1996), pp. 433–440
- [SD-008]

10.

- [10]
- A. Tewari, A. Srivasatava, M. Menon
- Members of the VIP Team. A prospective comparison of radical retropubic and robot-assisted prostatectomy: experience in one institution
- *BJU Int*, 92 (2003), pp. 205–210
- [SD-008]

11.

- [11]
- V. Ficarra, G. Novara, S. Fracalanza, C. D’Elia, S. Secco, M. Iafrate, S. Cavalleri, W. Artibani
- A prospective, non-randomized trial comparing robot-assisted laparoscopic and retropubic radical prostatectomy in one European institution
- *BJU Int*, 104 (2009), pp. 534–539
- [SD-008]

12.

- [12]
- B. Rocco, D.V. Matei, S. Melegari, J.C. Ospina, F. Mazzoleni, G. Errico, M. Mastropasqua, L. Santoro, S. Detti, O. de Cobelli
- Robotic vs open prostatectomy in a laparoscopically naive center: a matched-pair analysis
- *BJU Int*, 104 (2009), pp. 991–995
- [SD-008]

13.

- [13]
- G.B. Di Pierro, P. Baumeister, P. Stucki, J. Beatrice, H. Danuser, A. Mattei
- A prospective trial comparing consecutive series of open retropubic and robot-assisted laparoscopic radical prostatectomy in a centre with a limited caseload
- *Eur Urol*, 59 (2011), pp. 1–6
- [SD-008]

14.

- [14]
- F. Porpiglia, I. Morra, M. Lucci Chiarissi, M. Manfredi, F. Mele, S. Grande, F. Ragni, M. Poggio, C. Fiori
- Randomized controlled trial comparing laparoscopic and robot-assisted radical prostatectomy
- *Eur Urol*, 63 (2013), pp. 606–614
- [SD-008]

15.

- [15]
- J. Sammon, T.K. Kim, Q.D. Trinh, A. Bhandari, S. Kaul, S. Sukumar, C.G. Rogers, J.O. Peabody
- Anastomosis during robot-assisted radical prostatectomy: randomized controlled trial comparing barbed and standard monofilament suture
- *Urology*, 78 (2011), pp. 572–579
- [SD-008]

16.

- [16]
- A.A. Vora, D. Dajani, J.H. Lynch, K.J. Kowalczyk
- Anatomic and technical considerations for optimizing recovery of urinary function during robotic-assisted radical prostatectomy

- Curr Opin Urol, 23 (2013), pp. 78–87
- [SD-008]
- 17.
- [17]
- X. Hurtes, M. Rouprêt, C. Vaessen, H. Pereira, B. Faivre d’Arcier, L. Cormier, F. Bruyère
- Anterior suspension combined with posterior reconstruction during robot-assisted laparoscopic prostatectomy improves early return of urinary continence: a prospective randomized multicenter trial
- BJU Int, 110 (2012), pp. 875–883
- [SD-008]
- 18.
- [18]
- A. Mottrie, A. Gallina, P. De Wil, D. Thüer, G. Novara, V. Ficarra
- Balancing continence function and oncological outcomes during robot-assisted radical prostatectomy (RARP)
- BJU Int, 108 (2011), pp. 999–1006
- [SD-008]
- 19.
- [19]
- Y.C. You, T.H. Kim, G.T. Sung
- Effect of bladder neck preservation and posterior urethral reconstruction during robot-assisted laparoscopic radical prostatectomy for urinary continence
- Korean J Urol, 53 (2012), pp. 29–33
- [SD-008]
- 20.
- [20]
- R.F. Coelho, S. Chauhan, M.A. Orvieto, A. Sivaraman, K.J. Palmer, G. Coughlin, V.R. Patel
- Influence of modified posterior reconstruction of the rhabdosphincter on early recovery of continence and anastomotic leakage rates after robot-assisted radical prostatectomy
- Eur Urol, 59 (2011), pp. 72–80
- [SD-008]
- 21.
- [21]
- V.R. Patel, R.F. Coelho, K.J. Palmer, B. Rocco
- Periurethral suspension stitch during robot-assisted laparoscopic radical prostatectomy: description of the technique and continence outcomes
- Eur Urol, 56 (2009), pp. 472–478
- [SD-008]
- 22.
- [22]
- G. Gautam, B. Rocco, V.R. Patel, K.C. Zorn
- Posterior rhabdosphincter reconstruction during robot-assisted radical prostatectomy: critical analysis of techniques and outcomes
- Urology, 76 (2010), pp. 734–741
- [SD-008]
- 23.
- [23]

- M.P. Freire, A.C. Weinberg, Y. Lei, J.R. Soukup, S.R. Lipsitz, S.M. Prasad, F. Korke, T. Lin, J.C. Hu
 - Anatomic bladder neck preservation during robotic-assisted laparoscopic radical prostatectomy: description of technique and outcomes
 - *Eur Urol*, 56 (2009), pp. 972–980
 - [SD-008]
- 24.
- [24]
 - F. Rocco, L. Carmignani, P. Acquati, F. Gadda, P. Dell’Orto, B. Rocco, S. Casellato, G. Gazzano, D. Consonni
 - Early continence recovery after open radical prostatectomy with restoration of the posterior aspect of the rhabdosphincter
 - *Eur Urol*, 52 (2007), pp. 376–383
 - [SD-008]
- 25.
- [25]
 - A. Tewari, J. Jhaveri, S. Rao, R. Yadav, G. Bartsch, A. Te, E. Ioffe, M. Pineda, S. Mudaliar, L. Nguyen, J. Libertino, D. Vaughan
 - Total reconstruction of the vesico-urethral junction
 - *BJU Int*, 101 (2008), pp. 871–877
 - [SD-008]
- 26.
- [26]
 - N. Joshi, W. de Blok, E. van Muilekom, H. van der Poel
 - Impact of posterior musculofascial reconstruction on early continence after robot-assisted laparoscopic radical prostatectomy: results of a prospective parallel group trial
 - *Eur Urol*, 58 (2010), pp. 84–89
 - [SD-008]
- 27.
- [27]
 - V.R. Patel, R. Thaly, K. Shah
 - Robotic radical prostatectomy: outcomes of 500 cases
 - *BJU Int*, 99 (2007), pp. 1109–1112
 - [SD-008]
- 28.
- [28]
 - Y. Sugimura, T. Hioki, Y. Yamada, M. Fumino, T. Inoue
 - An anterior urethral stitch improves urinary incontinence following radical prostatectomy
 - *Int J Urol*, 8 (2001), pp. 153–157
 - [SD-008]
- 29.
- [29]
 - M. Noguchi, S. Noda, O. Nakashima, K. Matsuoka, M. Kojiro
 - Suspension technique improves rapid recovery of urinary continence following radical retropubic prostatectomy
 - *Kurume Med J*, 51 (2004), pp. 245–251
 - [SD-008]
- 30.
- [30]

- M. Menon, F. Muhletaler, M. Campos, J.O. Peabody
 - Assessment of early continence after reconstruction of the periprostatic tissues in patients undergoing computer assisted (robotic) prostatectomy: results of a 2 group parallel randomized controlled trial
 - J Urol, 180 (2008), pp. 1018–1023
 - [SD-008]
- 31.
- [31]
 - D.E. Sutherland, B. Linder, A.M. Guzman, M. Hong, H.A. Frazier II, J.D. Engel, F.J. Bianco Jr.
 - Posterior rhabdosphincter reconstruction during robotic assisted radical prostatectomy: Results from a Phase II randomized clinical trial
 - J Urol, 185 (2011), pp. 1262–1267
 - [SD-008]
- 32.
- [32]
 - D.W. Good, G.D. Stewart, J.U. Stolzenburg, S.A. McNeill
 - A literature-based analysis of the learning curves of laparoscopic radical prostatectomy
 - EMJ Urol, 1 (2014), pp. 90–96
 - [SD-008]