IRIS AperTO

UNIVERSITÀ DEGLI STUDI DI TORINO

AperTO - Archivio Istituzionale Open Access dell'Università di Torino

**Italian multicenter experience with flow-diverter devices for intracranial unruptured aneurysm treatment with periprocedural complications-a retrospective data analysis.**

**This is the author's manuscript**

*Original Citation:*

*Availability:*

This version is available http://hdl.handle.net/2318/135885 since 2017-01-17T15:03:59Z

*Published version:*

DOI:10.1007/s00234-012-1047-3

*Terms of use:*

Open Access

Anyone can freely access the full text of works made available as "Open Access". Works made available under a Creative Commons license can be used according to the terms and conditions of said license. Use of all other works requires consent of the right holder (author or publisher) if not exempted from copyright protection by the applicable law.

(Article begins on next page)

12 October 2024

This is the author's final version of the contribution published as:

Briganti F;Napoli M;Tortora F;Solari D;Bergui M;Boccardi E;Cagliari E;Castellan L;Causin F;Ciceri E;Cirillo L;De Blasi R;Delehaye L;Di Paola F;Fontana A;Gasparotti R;Guidetti G;Divenuto I;Iannucci G;Isalberti M;Leonardi M;Lupo F;Mangiafico S;Manto A;Menozzi R;Muto M;Nuzzi NP;Papa R;Petralia B;Piano M;Resta M;Padolecchia R;Saletti A;Sirabella G;Bolgè LP. Italian multicenter experience with flow-diverter devices for intracranial unruptured aneurysm treatment with periprocedural complications-a retrospective data analysis.. NEURORADIOLOGY. 54 (10) pp: 1145-1152.
DOI: 10.1007/s00234-012-1047-3

The publisher's version is available at:
http://link.springer.com/content/pdf/10.1007/s00234-012-1047-3

When citing, please refer to the published version.

Link to this full text:
http://hdl.handle.net/2318/135885

This full text was downloaded from iris - AperTO: https://iris.unito.it/

iris - AperTO

University of Turin's Institutional Research Information System and Open Access Institutional Repository

# Italian multicenter experience with flow-diverter devices for intracranial unruptured aneurysm treatment with periprocedural complications—a retrospective data analysis

Francesco BrigantiEmail authorManuela NapoliFabio TortoraDomenico SolariMauro BerguiEdoardo BoccardiEnrico CagliariLucio CastellanFrancesco CausinElisa CiceriLuigi CirilloRoberto De BlasiLuigi DelehayeFrancesco Di PaolaAndrea FontanaRoberto GasparottiGiulio GuidettiIgnazio DivenutoGiuseppe IannucciMaurizio IsalbertiMarco LeonardiFernando LupoSalvatore MangiaficoAndrea MantoRoberto MenozziMario MutoNunzio Paolo NuzziRosario PapaBenedetto PetraliaMariangela PianoMaurizio RestaRiccardo PadolecchiaAndrea SalettiGiovanni SirabellaLuca Piero Valvassori Bolgè

Abstract

Introduction

We report the experiences of 25 Italian centers, analyzing intra- and periprocedural complications of endovascular treatment of intracranial aneurysms using Silk (Balt Extrusion, Montmorency, France) and pipeline embolization devices (EV3 Inc, Irvine California).

Methods

Two hundred seventy-three patients with 295 cerebral aneurysms, enrolled in 25 centers in Italy and treated with the new flow-diverter devices, were evaluated; 142 patients were treated with Silk and 130 with pipeline (in one case, both devices were used). In 14 (5.2 %) cases devices were used with coils. Aneurysm size was >15 mm in 46.9 %, 5–15 mm in 42.2 %, and <5 mm in 10.8 %. Aneurysm locations were supraclinoid internal carotid artery (ICA) in 163 cases (55.2 %), cavernous ICA in 76 (25.7 %), middle cerebral artery in 11 (3.7 %), PCoA in 6 (2 %), and ACoA in 2 (0.7 %); the vertebrobasilar system accounted for 32 cases (10.8 %) and PCA in 5 (1.7 %).

Results

Technical adverse events occurred with 59 patients (21.6 %); 5 patients died after ischemic events, 10 to hemorrhagic complications, and 1 from external ventricular drain positioning. At 1 month, morbidity and mortality rates were 3.7 % and 5.9 %, respectively

Conclusion

Our retrospective study confirms that morbidity and mortality rates in treatment with FDD of unruptured wide-neck or untreatable cerebral aneurysms do not differ from those reported in the largest series.

Keywords

Flow diverter devicePipeline embolization deviceSilk embolization deviceIntracranial aneurysmsEndovascular treatment

## Introduction

Treatment of intracranial aneurysms has changed over the last decades, with the endovascular approach emerging as the first choice treatment for many lesions. Using coils to occlude the aneurismal sac renders this treatment simple and repeatable with a low rate of complications. Despite this development, many published series report recanalization of the sac in large and giant aneurysms as a major problem seen in mid- and long-term follow-up [3, 10, 19]. The strategy of treatment recently evolved, so that stents are used to achieve aneurysm occlusion by reconstruction of the wall (intima)
[1, 5, 6, 11, 12, 16, 18, 22, 24, 29, 30].

The use of stents during intracranial aneurysm embolization has significantly expanded the spectrum of aneurysms amenable to endovascular therapy [1, 5, 6, 12, 16, 18, 22, 24, 30]. This device ensures parent vessel protection during the embolization, and promotes the progressive thrombosis in the aneurysm's sac, even though these devices are unable to achieve occlusion as a sole therapy. Flow diverter devices represent the first endovascular construct specifically engineered to function as a standalone device for unruptured aneurysm's treatment [15, 17]. We present periprocedural outcomes (i.e., within the first 3 months after the procedure) in 273 patients treated in 25 Italian centers.

Materials and methods

Subject and methods

Between January 2009 and June 2010, 273 patients harboring 295 intracranial aneurysms were treated in 25 Italian centers with new flow-diverter endovascular devices, the Silk, and the pipeline embolization device or PED; only one patient was treated with both devices in the same procedure. There were 216 female and 57 male patients, with a mean age of 60 (range, 45–70 years). Indications of flow-diverter device use included mainly complex unruptured aneurysms such as fusiform, large and/or giant, or wide neck; additionally, small aneurysms, which might be untreatable by conventional coiling and recurrences, can be considered amenable to such a technique. The data were collected, analyzed, and elaborated by the corresponding author (F.B.) and a coauthor (M.N.).

The aneurysms were located in supraclinoid internal carotid artery (ICA) in 163 cases (55.2 %), the cavernous ICA in 76 cases (25.7 %), middle cerebral artery (MCA) in 11 cases (3.7 %), PCoA in 6 cases (2.0 %), ACoA in 2 (0.7 %), vertebrobasilar system in 32 cases (10.8 %), and PCA in 5 cases (1.7 %) (Table 1). We also implanted flow-diverter devices for 35 fusiform aneurysms (11.8 %). Only 14 patients (5.2 %) were treated with combinations of flow-diverter devices and coils; all patients treated also with coils had giant aneurysms; nevertheless, the choice was based on personal judgment.

**Table 1**

Localization of intracranial aneurysms

| | | |
|---|---|---|
| Anterior circulation | Sopraclinoid ICA segment | 163 (55.2 %) |
| | Cavernous ICA segment | 76 (25.7 %) |
| | MCA | 11 (3.7 %) |
| | PCoA | 6 (2.0 %) |
| | ACoA | 2 (0.7 %) |
| Posterior circulation | Vertebrobasilar | 32 (10.8 %) |
| | Posterior cerebral artery | 5 (1.7 %) |

Interventional procedure and medication

Medical platelet inhibition strategies that were used consisted mainly of 75 mg of clopidogrel or 500 mg of ticlopidin in association with 100 mg of aspirin 4 days prior to procedure. As an alternative, 600 mg of

clopidogrel was given out the day of the surgery. A dual antiplatelet therapy was administered thereafter for a period ranging from 1–6 months. In 24 centers, intravenous heparin was administered during the procedure and stopped after that. All procedures were performed under general anesthesia.

Aneurysm characteristics (localization, size, dome/neck ratio, relationship with parent vessel, and parent artery diameter) were evaluated by means of CT-angiography or angiography.

The targeted parent vessels were accessed using a variety of guiding catheters or long-sheathes and placing neurovascular microcatheters across the aneurysms' necks. The choice between the two devices (Silk or PED) was made according to each operator's judgement and after careful evaluations of aneurysm neck, vessel diameter, and length of segment to rebuild.

The device is attached to a flexible delivery wire with radiopaque end markers and is packaged in an introducer sheath that can be pushed through a 0.027-in. microcatheter (PED) or 0.021-in. microcatheter (Silk). Once positioned across the aneurysmal segment, the delivery wire is held while the distal device is carefully unsheathed. Once the device is fully in place, it may be recrossed by advancing the microcatheter over the indwelling delivery wire, which can then be exchanged for a second flow-diverter device. This provides a safer option for the deployment of multiple devices through the same microcatheter when necessary.

Statistical analysis

Random effect meta-analysis was performed for morbidity and mortality rates separately. This work included both cases observed in the present study and those retrieved from recent literature, concerning the use of both flow-diverter devices. The presence of between-study heterogeneity was accounted for in the analysis and was tested by likelihood ratio test statistic, according to the DerSimonian and Laird approach to the normal mixture model framework [28]. Furthermore, consistency of rates observed in the present study and the overall rates derived from combining all studies (except the present) was evaluated through a suitable contrast defined into each model. $P < 0.05$ was considered statistically significant. All analysis was performed using SAS Release 9.1 (SAS Institute, Cary, NC, USA).

Results

During a 24-month period, we deployed a total of 333 FDD, 151 Silk and 182 pipeline, in 273 patients: 142 patients were treated with Silk, 130 with PED, and 1 in whom both devices were deployed. In 44 patients, 2 devices were used (6 Silk, 38 PED); in 3 patients, 3 devices were used (all PED); and in 2 cases, 4 PEDs were implanted in the same patient.

We classified the adverse events in two major categories, in regard to the first injury mechanism: the ischemic events (13 patients) and the hemorrhagic complications (15 patients). We also observed a single patient (0.4 %) with an intracerebral hemorrhage after external ventricular drain placement, probably related to double antiplatelet therapy; this patient developed an acute hydrocephalus due to mass effect caused by intra-aneurysmal thrombosis of a giant basilar-tip aneurysm treated with Silk (Table 2).

**Table 2**

Incidence of complications and clinical outcomes

| | Total number of patients (%) | Patients treated with Silk | Patients treated with PED | Clinical outcome | |
|---|---|---|---|---|---|
| | | | | No deficits | Permanent deficits |
| Cases treated | 273 | 143[a] | 131[a] | | |
| Hemorrhagic events | 15 (5.5 %) | 5 | 10 | 2 | 3 |
| Ischemic/thromboembolic events | 13 (4.8 %) | 8 | 5 | 1 | 7 |
| Acute hydrocephalus with intraventricular drainage | 1 (0.4 %) | 1 | – | – | – |
| Total clinical complications | 29 (10. 6 %) | 14(5.1 %) | 15(5.5 %) | 3(1.1 %) | 10(3.7 %) |

[a]One patient was treated with Silk and PED

To gain a better understanding of the issue, we further classified them into two categories: procedure-related and device-related. We identified the events that occurred in endovascular aneurysms procedures regardless of the devices employed; device-related events were strictly associated with the flow-diverter device features.

We define as hemorrhagic complications the incidence of intracerebral or subarachnoid bleeding as confirmed by post-operative CT scan or intraoperatively by contrast extravasation; in our series it occurred in 15 patients (5.5 %; 5 Silk, 10 PED). Seven patients had hemorrhagic complications considered to be procedure-related: five of these reported vessels perforated by guidewire and two intracerebral hemorrhages related to dual antiplatelet therapy. Another eight patients (two Silk, six PED) experienced device-related hemorrhagic events: seven were delayed aneurysms rupture after treatment (two Silk, five PED) and one was vessel (MCA) perforation during PED retrieval after distal migration. Of these 15 patients with hemorrhagic complications, 2 had no clinical manifestations, and 3 developed permanent neurological deficits (one amaurosis, one hemiparesis, and one breathing disorder needing permanent tracheostomy and resulting in a serious movement handicap); 10 of these patients died (Table 3).

**Table 3**

Clinical complications with related devices

| Clinical complication | Devices | Class of complication | | Clinical outcome | | |
|---|---|---|---|---|---|---|
| | | Procedure-Related | Device-Related | Silent | Clinical sign | Death |
| Ischemic events | Silk | 4 | 4 | 1 | 5 | 2 |

| Clinical complication | Devices | Class of complication | | Clinical outcome | | |
|---|---|---|---|---|---|---|
| | | Procedure-Related | Device-Related | Silent | Clinical sign | Death |
| | PED | – | 5 | – | 2 | 3 |
| Hemorrhagic events | Silk | 3 | 2 | – | 1 | 4 |
| | PED | 4 | 6 | 2 | 2 | 6 |
| Hydrocephalus | Silk | 1 | – | – | – | 1 |
| Total | Silk | 8 | 6 | 1 | 6 | 7 |
| | PED | 4 | 11 | 2 | 4 | 9 |
| | | 12 | 17 | 3 (1.1 %) | 10 (3.7 %) | 16 (5.9 %) |

Ischemic or thromboembolic events occurred in 13 patients (4.8 %), 8 treated with Silk and 5 with PED. We defined ischemic events as the incidence of symptoms related to radiological manifestation of vessel's occlusion, detected with MRI, CT, or angiography, with or without parenchymal ischemic area. Four cases (Silk) were considered procedure-related and nine cases were device-related: three side-branch occlusions (one with Silk, two with PED) and six in-stent thromboses (three Silk and three PED). The ischemic complications resulted in one case with no clinical symptoms (Silk), five (four Silk, one PED) with permanent neurological deficits (two visual deficits, two hemiparesis and one vegetative state) and two with transient symptoms (one third cranial nerve palsy and one hand–fingers lack of coordination); five patients died (two Silk, three PED).

In anterior circulation, we recorded a 3.5 % mortality rate (9/258 patients) and a 2.3 % morbidity rate (6/258 patients); in posterior circulation, we recorded a 19 % mortality rate (7/37 patients) and a 5.4 % morbidity rate (2/37 patients). Furthermore if we analyze extradural aneurysms (76 cases), we report a mortality rate of 4 % (three cases: two ICA thrombosis and one vessel perforation for giant intracavernous aneurysms).

The mortality in the subgroup of patients treated with coil is higher (35.7 %, 5/14 patients) if compared with the total group; this difference is related to use of coils in giant complex aneurysms and the incidence of aneurysm rupture after treatment despite the coils.

We also reported 30 unexpected events without any clinical correlation: 6 device deployment failures (five Silk and one PED) requiring the use of another stent, 12 device mispositioning (five in patients treated with Silk and seven with PED), 8 small intrastent aggregation (four Silk and four PED) resolved with pharmacological or mechanical thrombolysis, and 4 guidewire ruptures (four PED) (Table 4).

**Table 4**

Technical complications

| Technical complications without clinical or radiological correlations | Device | |
|---|---|---|
| | Silk | PED |
| Failed to deploy | 5 | 1 |
| Uncorrected positioning | 5 | 7 |
| Aggregation | 4 | 4 |
| Guidewire rupture | – | 4 |
| Total | 14 | 16 |

In these series, 180 patients had already undergone the 3 months follow-up, by digital angiography (Fig. 1); 85 % achieved a total occlusion of the aneurysm sac (76 % of them were represented by anterior circulation aneurysms; 9 % by posterior circulation lesions). In 15 % where we had subtotal occlusions, all aneurysms were located in the anterior circulation.

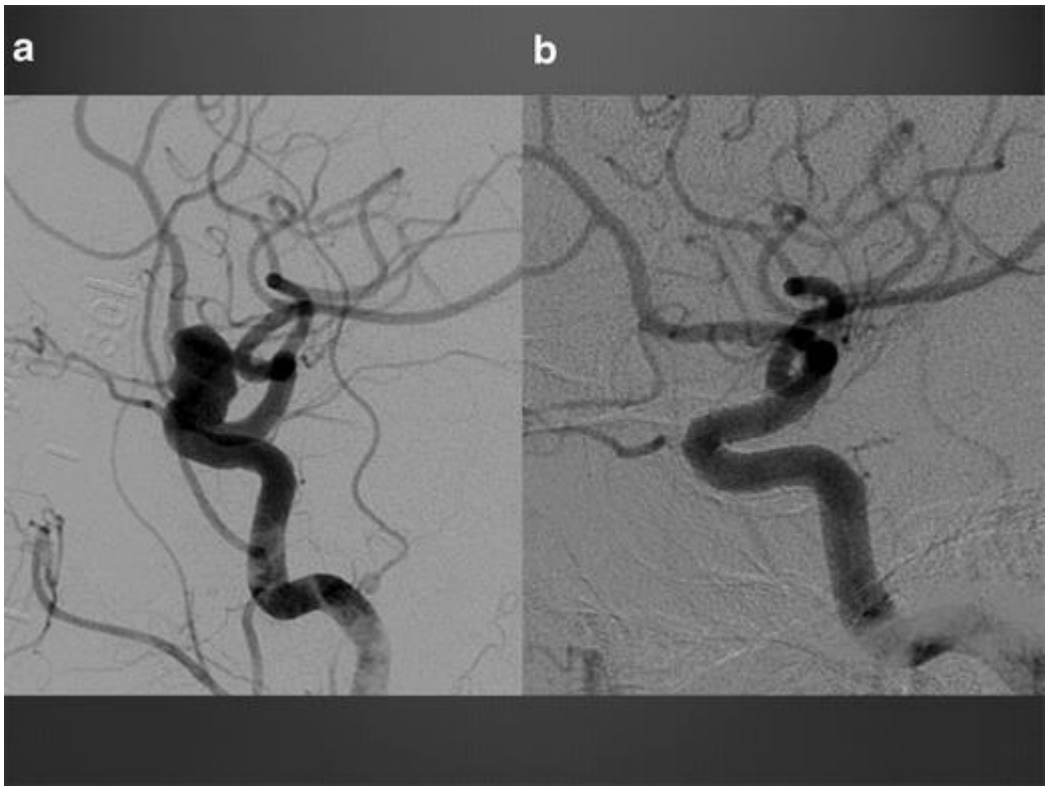


**Fig. 1**

**a** A 60-year-old woman harboring a 9.4-mm ophthalmic aneurysm. **b** Three-month follow-up angiography shows complete occlusion of the aneurysm, with a small translucent rim due to a neointimal layer

Discussion

This study confirms that the use of flow-diverter devices may be useful for the endovascular treatment of different intracranial aneurysms. However, the analysis of series complications indicates that caution is necessary when using a flow-diverter device. The authors are aware that the retrospective nature of the study and the collection and interpretation of data by the single operators represent a source of bias, but we consider the data to offer better understanding of the peculiarities of flow-diverter devices.

So far, a number of single institution case series have demonstrated that flow-diverter devices allow endovascular treatment of wide neck and fusiform cerebral aneurysms [2, 4, 7–9, 14, 21, 23, 25] (Table 5). This is the first multicentric study to evaluate complications related to the flow-diverter device's endovascular placement in a large series of patients, analyzing technical issues of two different devices, i.e., the Silk and PED. The number of patients in this investigation represents 30 % of the annual case load of endovascular procedures among Italian interventional neuroradiology centers.

**Table 5**

Literature of non-flow-diverter stents

| Author | No. of patients | Morbidity | Mortality |
|---|---|---|---|
| Fiorella et al. [6] | 284 | 5.3 % | 2.8 % |
| Piotin et al. [22] | 216 | 7.4 % | 4.6 % |
| Lylyk et al. [17] | 46 | 8.6 % | 2.1 % |
| Kis et al. [12] | 57 | 0 % | 5.2 % |
| Yang et al. [30] | 84 | 0 % | 1.2 % |
| Mocco et al. [18] | 141 | 2.8 % | 2 % |

Notwithstanding the unavailability of long-term results, it is very important to detail and describe complications that can somehow affect the FDD use in the treatment of intracranial aneurysms—technical, device-related, or not. Importantly, most patients treated have been discharged in unchanged or improved clinical status.

Our results in terms of morbidity and mortality rates seem to be reasonable, especially when compared with data retrieved from recent literature concerning the use of both flow-diverter devices, i.e., the Silk and the Pipeline (Table 6). Also, this manuscript aims to evaluate safety and efficacy of the use of flow-diverter devices in the treatment of intracranial aneurysms.

**Table 6**

Literature on flow-diverter stents

| Author | No. patients | Morbidity | Mortality |
|---|---|---|---|
| Silk experience | | | |

| Author | No. patients | Morbidity | Mortality |
|---|---|---|---|
| Lubiez et al. [15] | 26 | 15 % | 4 % |
| Byrne et al. [2] | 70 | 4 % | 8 % |
| PED experience | | | |
| Lylyk et al. [17] | 53 | 0 % | 0 % |
| Szikora et al. [26] | 18 | 5.5 % | 5.5 % |
| Nelson et al. [21] | 31 | 6.4 % | 0 % |
| Silk and PED experience | | | |
| Briganti et al. | 273 | 3.7 % | 5.9 % |

We had an overall of 3.7 % morbidity rate with a 5.9 % mortality rate; symptomatic complications occurred in ten patients: seven ischemic and three hemorrhagic. Considering the etiology, we recognized three of them being procedure-related and seven device-related.

Mortality rate in the intracavernous aneurysm subgroup is very high (4 %; 3/76 patients); probably the extradural aneurysms must be treated only if symptomatic and in expert hands. We reported high incidence of aneurysm ruptures after treatment in large and giant aneurysms even though the FDD were used in combination with coils; the data suggest that the use of coils do not prevent delay aneurysm rupture.

In the pertinent literature, Szikora [26], reported 18 patients with 19 aneurysms treated with 39 PED, with a 22.2 % rate of clinical complications: two patients (11.1 %) complained of a transient neurological deficit (both of them hemiparesis), one (5.5 %) experienced a permanent small visual field deficit, and one died (5.5 %) due to a massive SAH caused by perforation of another small aneurysm with the microwire during the endovascular procedure. In the report of Lylyk [17], of 53 patients with 63 aneurysms treated with 72 PED, alone or in association with coils, no major clinically evident complications (stroke or death) were encountered within 30 days and minor complications occurred in 6 of 53 patients (11 %), without clinical signs. Lubicz [15] studied the use of Silk in 29 patients, with three (10 %) thromboembolic events, one death (4 %) due to a delayed aneurysm rupture related to FDD migration, and three (10 %) technical failures described. Finally, the trial of Byrne [2] reported a 4 % morbidity rate and 8 % mortality rate, and 21 % technical difficulties in Silk deployment.

Concerning the non-diverter stents, Fiorella [6] in an experience with Neuroform reported a total of 25 ischemic strokes (8.8 %), a morbidity rate of 5.3 %, and a mortality rate of 2.8 %. Piotin [22] reported using stent-assisted coils for aneurysm treatment; in this study, of 216 patients treated, 16 (7.4 %) had permanent neurological deficits and 10 (4.6 %) died.

Meta-analysis of data reported in all studies selected from literature showed an overall morbidity rate of 6.2 % (CI 95 % 4.7–8.1 %). No significant between-study heterogeneity was found ($P = 0.456$). Further,

inclusion of the present study (observed morbidity rate of 3.7 % (CI 95 % 2.0–6.7 %)) into the random effect meta-analysis can be considered consistent in terms of morbidity rates with the others previously included ($P = 0.145$) and did not provide a substantial change of between-study heterogeneity, as it still remained statistically not significant ($P = 0.310$).

Likewise, meta-analysis of data reported in all studies selected from literature showed an overall mortality rate of 3.4 % (CI 95 % 2.4–4.7 %). No significant between-studies heterogeneity was found ($P = 0.825$). The further inclusion of the present study showed a mortality rate of 5.9 % (CI 95 % 3.6–9.3 %) into the random effect meta-analysis, which in terms of mortality rates can also be considered consistent with the other results previously included ($P = 0.07$) and did not provide a substantial change of between-studies heterogeneity as it remained statistically not significant ($P = 0.355$).

Collectively, these data indicate that proper management of FDD is needed to avoid complications. Aside from the aneurysm's inner features, there is also the possibility of aneurysm rupture after endovascular treatment with FDD, as reported in 14 cases in the literature [13, 20, 27]. It has been suggested that, after FDD deploying, rapid flow decrease could cause massive intra-aneurismal platelets aggregation; usually after 48 h, lytic enzymes released from platelets cause rupture of the aneurysm wall. Moreover, increased turbulence at the neck level, or peripheral persistent fresh thrombus, might promote rupture.

During a short period of observation (mean 10 days, range 1–30 days), we observed seven (2.6 %) giant aneurysms rupture after treatment; six (2.2 %) of these patients died from their hemorrhage and the last patient developed hemiparesis. However, in our experience, the use of FDD allows better treatment of cerebral aneurysms, therefore obtaining safer and more reliable procedures.

## Conclusion

This retrospective study reflects the experience of 90 % of Italian neuroradiological divisions and represents the largest series evaluating the use of the new flow-diverter devices for the treatment of intracranial aneurysms. We know the potential interest of this new material, particularly in the treatment of giant and fusiform aneurisms. In this early experience, we reported technical complications in 21.5 % of patients; probably, the number of adverse events in our trial is related to the recent introduction of the new devices and initial inexperience in their use. Furthermore, complications occurred mostly in complex aneurysms and in posterior circulation otherwise untreatable; indeed, 62 % of deaths in this series (10/16) occurred in large and giant aneurysms even though coils were used. Our statistical analysis confirms that the rates of morbidity (3.7 %) and mortality (5.9 %) do not differ from those reported in the major series, concerning the use of flow-diverter stents to treat non-ruptured aneurysms. In the early follow-up (3 months), we achieved occlusion in 85 % of a total of 185 patients; even though this is preliminary, we believe that it to be an encouraging result. Nevertheless more studies are needed, in randomized trials or registry in order to evaluate indications and results of these new devices.

## References

1.

Augsburger L, Farhat M, Reymond P, Fonck E, Kulcsar Z, Stergiopulos N, Rufenacht DA (2009) Effect of flow diverter porosity on intraaneurysmal blood flow. Klin Neuroradiol 19(3):204–214. doi:10.1007/s00062-009-9005-0

2.

Byrne JV, Beltechi R, Yarnold JA, Birks J, Kamran M (2010) Early experience in the treatment of intra-cranial aneurysms by endovascular flow diversion: a multicentre prospective study. PLoS One 5 (9). doi:10.1371/journal.pone.0012492

3.

Campi A, Ramzi N, Molyneux AJ, Summers PE, Kerr RS, Sneade M, Yarnold JA, Rischmiller J, Byrne JV (2007) Retreatment of ruptured cerebral aneurysms in patients randomized by coiling or clipping in the International Subarachnoid Aneurysm Trial (ISAT). Stroke 38(5):1538–1544. doi:10.1161/STROKEAHA.106.466987

4.

Fiorella D, Albuquerque F, Gonzalez F, McDougall CG, Nelson PK (2010) Reconstruction of the right anterior circulation with the Pipeline embolization device to achieve treatment of a progressively symptomatic, large carotid aneurysm. J Neurointerv Surg 2(1):31–37. doi:10.1136/jnis.2009.000554

5.

Fiorella D, Albuquerque FC, Deshmukh VR, McDougall CG (2005) Usefulness of the Neuroform stent for the treatment of cerebral aneurysms: results at initial (3-6-mo) follow-up. Neurosurgery 56(6):1191–1201, discussion 1201-1192

6.

Fiorella D, Albuquerque FC, Woo H, Rasmussen PA, Masaryk TJ, McDougall CG (2010) Neuroform stent assisted aneurysm treatment: evolving treatment strategies, complications and results of long term follow-up. J Neurointerv Surg 2(1):16–22. doi:10.1136/jnis.2009.000521

7.

Fiorella D, Kelly ME, Albuquerque FC, Nelson PK (2009) Curative reconstruction of a giant midbasilar trunk aneurysm with the pipeline embolization device. Neurosurgery 64(2):212–217. doi:10.1227/01.NEU.0000337576.98984.E4, discussion 217

8.

Fiorella D, Lylyk P, Szikora I, Kelly ME, Albuquerque FC, McDougall CG, Nelson PK (2009) Curative cerebrovascular reconstruction with the Pipeline embolization device: the emergence of definitive endovascular therapy for intracranial aneurysms. J Neurointerv Surg 1(1):56–65. doi:10.1136/jnis.2009.000083

9.

Fiorella D, Woo HH, Albuquerque FC, Nelson PK (2008) Definitive reconstruction of circumferential, fusiform intracranial aneurysms with the pipeline embolization device. Neurosurgery 62(5):1115–1120. doi:10.1227/01.neu.0000325873.44881, discussion 1120-1111

10.

Johnston SC, Dowd CF, Higashida RT, Lawton MT, Duckwiler GR, Gress DR (2008) Predictors of rehemorrhage after treatment of ruptured intracranial aneurysms: the Cerebral Aneurysm Rerupture After Treatment (CARAT) study. Stroke 39(1):120–125. doi:10.1161/STROKEAHA.107.495747

11.

Kallmes DF, Ding YH, Dai D, Kadirvel R, Lewis DA, Cloft HJ (2007) A new endoluminal, flow-disrupting device for treatment of saccular aneurysms. Stroke 38(8):2346–2352. doi:10.1161/STROKEAHA.106.479576

12.

Kis B, Weber W, Gotz F, Becker H, Berlit P, Kuhne D (2007) Endovascular treatment of cerebral aneurysms using the Leo stent: long term follow-up and expansion of indications. Clin Neuradiol 17:167–179

13.

Kulcsar Z, Houdart E, Bonafe A, Parker G, Millar J, Goddard AJ, Renowden S, Gal G, Turowski B, Mitchell K, Gray F, Rodriguez M, van den Berg R, Gruber A, Desal H, Wanke I, Rufenacht DA (2011) Intra-aneurysmal thrombosis as a possible cause of delayed aneurysm rupture after flow-diversion treatment. AJNR Am J Neuroradiol 32(1):20–25. doi:10.3174/ajnr.A2370

14.

Leonardi M, Cirillo L, Toni F, Dall'olio M, Princiotta C, Stafa A, Simonetti L, Agati R (2011) Treatment of intracranial aneurysms using flow-diverting silk stents (BALT): a single centre experience. Interv Neuroradiol 17(3):306–315. doi:IN.v17.i3

15.

Lubicz B, Collignon L, Raphaeli G, Pruvo JP, Bruneau M, De Witte O, Leclerc X (2010) Flow-diverter stent for the endovascular treatment of intracranial aneurysms: a prospective study in 29 patients with 34 aneurysms. Stroke 41(10):2247–2253. doi:10.1161/STROKEAHA.110.589911

16.

Lylyk P, Ferrario A, Pasbon B, Miranda C, Doroszuk G (2005) Buenos Aires experience with the Neuroform self-expanding stent for the treatment of intracranial aneurysms. J Neurosurg 102(2):235–241. doi:10.3171/jns.2005.102.2.0235

17.

Lylyk P, Miranda C, Ceratto R, Ferrario A, Scrivano E, Luna HR, Berez AL, Tran Q, Nelson PK, Fiorella D (2009) Curative endovascular reconstruction of cerebral aneurysms with the pipeline embolization device: the Buenos Aires experience. Neurosurgery 64(4):632–642. doi:10.1227/01.NEU.0000339109.98070.65, discussion 642-633; quiz N6

18.

Mocco J, Snyder KV, Albuquerque FC, Bendok BR, Alan SB, Carpenter JS, Fiorella DJ, Hoh BL, Howington JU, Jankowitz BT, Liebman KM, Rai AT, Rodriguez-Mercado R, Siddiqui AH, Veznedaroglu E, Hopkins LN, Levy EI (2009) Treatment of intracranial aneurysms with the Enterprise stent: a multicenter registry. J Neurosurg 110(1):35–39. doi:10.3171/2008.7.JNS08322

19.

Molyneux AJ, Kerr RS, Yu LM, Clarke M, Sneade M, Yarnold JA, Sandercock P (2005) International subarachnoid aneurysm trial (ISAT) of neurosurgical clipping versus endovascular coiling in 2143 patients with ruptured intracranial aneurysms: a randomised comparison of effects on survival, dependency, seizures, rebleeding, subgroups, and aneurysm occlusion. Lancet 366(9488):809–817. doi:10.1016/S0140-6736(05)67214-5

20.

Mustafa W, Kadziolka K, Anxionnat R, Pierot L (2010) Direct carotid-cavernous fistula following intracavernous carotid aneurysm treatment with a flow-diverter stent. A case report Interv Neuroradiol 16(4):447–450. doi:IN.v16.i4

21.

Nelson PK, Lylyk P, Szikora I, Wetzel SG, Wanke I, Fiorella D (2011) The pipeline embolization device for the intracranial treatment of aneurysms trial. AJNR Am J Neuroradiol 32(1):34–40. doi:10.3174/ajnr.A2421

22.

Piotin M, Blanc R, Spelle L, Mounayer C, Piantino R, Schmidt PJ, Moret J (2010) Stent-assisted coiling of intracranial aneurysms: clinical and angiographic results in 216 consecutive aneurysms. Stroke 41(1):110–115. doi:10.1161/STROKEAHA.109.558114

23.

Pumar JM, Garcia-Dorrego R, Nieto A, Vazquez-Herrero F, Blanco-Ulla M, Vazquez-Martin A (2010) Vascular reconstruction of a fusiform basilar aneurysm with the Silk embolization system. J Neurointerv Surg 2(3):242–244. doi:10.1136/jnis.2010.002725

24.

Sedat J, Chau Y, Mondot L, Vargas J, Szapiro J, Lonjon M (2009) Endovascular occlusion of intracranial wide-necked aneurysms with stenting (Neuroform) and coiling: mid-term and long-term results. Neuroradiology 51(6):401–409. doi:10.1007/s00234-009-0502-2

25.

Shapiro M, Becske T, Sahlein D, Babb J, Nelson PK (2012) Stent-supported aneurysm coiling: a literature survey of treatment and follow-up. AJNR Am J Neuroradiol 33(1):159–163. doi:10.3174/ajnr.A2719

26.

Szikora I, Berentei Z, Kulcsar Z, Marosfoi M, Vajda ZS, Lee W, Berez A, Nelson PK (2010) Treatment of intracranial aneurysms by functional reconstruction of the parent artery: the Budapest experience with the pipeline embolization device. AJNR Am J Neuroradiol 31(6):1139–1147. doi:10.3174/ajnr.A2023

27.

Turowski B, Macht S, Kulcsar Z, Hanggi D, Stummer W (2011) Early fatal hemorrhage after endovascular cerebral aneurysm treatment with a flow diverter (SILK-Stent): do we need to rethink our concepts? Neuroradiology 53(1):37–41. doi:10.1007/s00234-010-0676-7

28.

van Houwelingen HC, Arends LR, Stijnen T (2002) Advanced methods in meta-analysis: multivariate approach and meta-regression. Stat Med 21(4):589–624. doi:10.1002/sim

29.

Wakhloo AK, Deleo MJ 3rd, Brown MM (2009) Advances in interventional neuroradiology. Stroke 40(5):e305–e312. doi:10.1161/STROKEAHA.109.548438

30.

Yang X, Wu Z, Mu S, Li Y, Lv M (2008) Endovascular treatment of giant and large intracranial aneurysms using the neuroform stent-assisted coil placement. Neurol Res 30(6):598–602. doi:10.1179/174313208X319017